

Multi-vesicular pulmonary hydatid cyst, the potent underestimated factor in the formation of daughter cysts of pulmonary hydatid disease

Mohsen Sokouti, Babak Sokouti¹, Behrooz Shokouhi², Mohammad Hossein Rahimi-Rad³

Departments of Cardiothoracic Surgery, ¹Biotechnology Research Center, ²Department of Pathology, Tabriz University of Medical Sciences, Tabriz, Iran and ³Lung division of Department of Medicine, Urmia University of Medical Sciences, Urmia, Iran

ABSTRACT

Pulmonary multi-vesicular hydatid disease (HD) with *Echinococcus granulosus* is rare. A 28-year-old woman presented to our center with cough and respiratory distress. Chest x-ray and computerized tomography scan revealed bilateral giant cysts with water-lily sign (ruptured hydatid cysts). The left cyst was in vicinity of heart. With thoracotomy cysts of both lungs were removed. Thousands of translucent, homogenized small daughter cysts were discovered from the left side cyst. Pathologic examinations revealed the ruptured hydatid cysts of both lungs with daughter cysts on the left lung cyst. To best of our knowledge probably this is the first report of multi-vesicular HD in lung. We suppose that the heart pulsation was effective in the formation of daughter cysts.

KEY WORDS: Daughter cyst, lungs, multi-vesicular hydatid cyst, ruptured

Address for correspondence: Dr. Mohammad Hossein Rahimi-Rad, Bronchoscopy Unit, Imam Khomeini Hospital, Ershad Avenue, Urmia, Iran. (Postal Code 5715781351) E-mail: rahimirad@hotmail.com

INTRODUCTION

Hydatid disease is a major health problem in the eastern Mediterranean countries.^[1] Two types of Echinococcosis exist in this endemic area, *Echinococcus granulosus* and *E. multilocularis*, which is rare.^[2] A multivesicular hydatid cyst most often is reported from cardiac hydatid disease.^[3,4]

CASE REPORT

A 28-year-old woman was admitted to our referral hospital in July 2013 with complaint of mucopurulent productive cough for 6 months. The onset of symptoms was after sudden expectoration salty and clear fluid. In examination the respiratory sounds were decreased, and crackles were present in both hemithoraces. Chest roentgenogram and computed tomography (CT scan) demonstrated a giant cyst

in the right upper lobe (15 × 14 × 13 cm) and the second cyst in the lingula lobe (8 × 7 cm) located on the anterior and lateral border of the heart, with air fluid and water lily sign in both cysts [Figure 1]. Firstly, a giant ruptured hydatid cyst was operated by the right thoracotomy. After pericystostomy and extraction of the ruptured laminated membrane, no salvageable pulmonary parenchyma was remained in the right upper lobe. Lobectomy was performed and two chest tubes were inserted in the right pleural cavity, and then the chest was closed. The patient discharged on the fifth day postoperatively without any complications. Productive cough was decreased interestingly after surgery. After 23 days, the patient prepared for the second surgery with left anterior thoracotomy. Then, the ruptured pulmonary hydatid cyst along with thousands of small (1-3 mm) young healthy translucent daughter cysts of the lingula lobe located over the anterolateral surface of heart excised completely with lingula resection. As a result, the pathologic examinations of ruptured laminated membranes and daughter cysts confirmed a hydatid cyst [Figure 2a and b]. On 1 year follow up patient condition is well.

DISCUSSION

Giant ruptured hydatid cysts were more common in the adolescents in endemic areas and was associated with

Access this article online	
Quick Response Code:	Website: www.lungindia.com
	DOI: 10.4103/0970-2113.159583

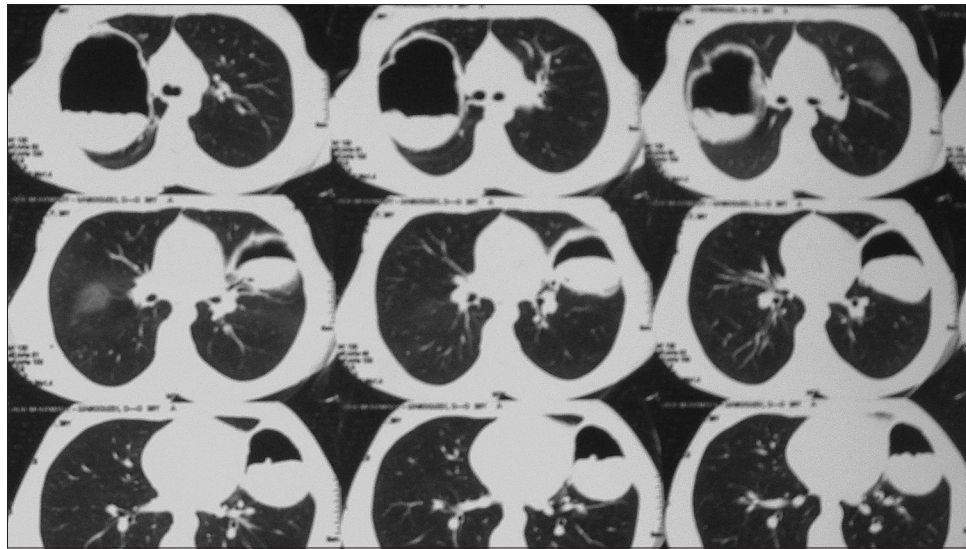


Figure 1: CT scan of the patient showing giant ruptured hydatid cysts of the right lung and air fluid level with water-lily sign in both ruptured hydatid cysts

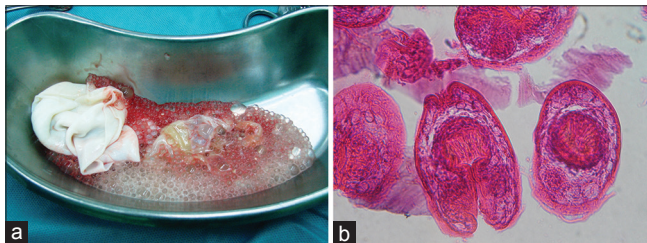


Figure 2: (a) Macroscopic appearances of laminated membranes of hydatid cysts, and thousands of daughter cysts of left lung hydatid cysts. (b) Microscopic appearances of laminated membranes of hydatid cysts of thousands of daughter cysts of left lung hydatid cysts

cough, with or without sputum, chest pain, dyspnea, hemoptysis, nausea and vomiting and even chest wall deformities.^[5] Daughter cysts can also sporadically be seen in pulmonary hydatid cysts. The germinative layer secretes hydatid fluid and generates brood capsule. If the inner layer and the brood capsules spitted up, daughter cysts can be produced.^[6]

Due to early presentation of symptoms of giant pulmonary hydatid cysts and treatment, it seems no time remains for forming the daughter cysts. Because of early presentation of symptoms of pulmonary hydatid cysts and surgery, no time remains for the formation of daughter cysts, hence the occurrences of daughter cysts in the pulmonary hydatid cysts are uncommon.^[1,2] We present two ruptured lung hydatid cysts: One in the giant form of the right upper lobe and second in the lingula with thousands of daughter cysts rarely reported in the literature. And it was also discussed about the potential factor in the formation of daughter cysts. All hydatid cysts of *E. granulosus* are called “unilocular.” Unilocular cysts may contain no daughter cysts, and are called “univesicular” and those with daughter cysts are called “multivesicular.”^[2] Chest X-ray can show the giant and non-giant hydatid cyst as a round opacity occupying a part of a hemithorax. Cyst

may rupture and produce some characteristic signs which include^[7] (a) Water-lily sign (endocyst membrane floating on surface of fluid) which is seen in this patient chest CT scan; (b) crescent sign; (c) inverse crescent sign, a crescent-like rim of air at the lower end of the cyst; (d) signet ring sign, a bleb of air dissecting into the wall of the cyst, giving it the shape of a ring; (e) Cumbo's sign, air fluid level in the endocyst capped with air between pericyst and endocyst occurring on rupture of the endocyst.^[6] CT scan can detect pulmonary hydatosis with or without daughter cysts^[8] but due to very small sizes of daughter cysts presented in this patient it was not detected before surgery.

There are basically two theories regarding this formation: Repeated mechanical trauma such as effect of pulsation of heart beats and respiratory motions and separation of some parts of laminated membrane due to opening of bronchioles of pericyst layer into the cyst cavity and formation of daughter cysts due to defensive mechanism of the host.^[2]

In this case, daughter cysts were present in the ruptured hydatid cyst of the lingula lobe, located adjacent the heart pulsations, while along with second ruptured univesicular giant pulmonary hydatid cysts in the right upper lobe.

These ruptured hydatid cysts were positioned differently, the left one was located over the heart and the right one far from the heart. Respiratory motions force affects over the both cysts.

Opening of bronchioles theories into the cysts probably had more affected right giant cysts than left non-giant one and it seems this theory has no or little effect on the phenomenon of rupture and formation of daughter cyst. Giant hydatid cyst is complicated and easier than non-giant cyst^[3] and in

this patient right lung hydatid cyst probably had longer time to become giant or forming daughter cysts than left one, hence this factor is also supposed to be not important. In this patient it can be concluded that the effect of repeated cardiac beat on the lingula hydatid cyst in the formation of daughter cysts is more potential factor than other ones that has been confirmed by Dew's theory presented in 1928.^[9,10]

It is required to differentiate *Echinococcus granulosus* cysts from *E. multilocularis* which most commonly present with malaise, weight loss, and right upper quadrant discomfort due to hepatomegaly and may mimic hepatocellular carcinoma. Extrahepatic primary disease is very rare (1% of cases). Immunodeficiency, such as HIV or transplantation, may accelerate the manifestations of alveolar echinococcosis.^[11] On ultrasound or CT, *E. multilocularis* cysts usually have an irregular contour with no well-defined wall. They may be difficult to distinguish from a tumor. The cysts of this patient were well defined and easily differentiated from multilocularis cysts.

REFERENCES

1. Sokouti M, Golzari SE, Kayhan S, Sabermarouf B. Recurrence following pulmonary hydatid disease surgery. *World J Surg* 2014;38:266.
2. Saidi F. *Surgery of Hydatid Disease*. 1st ed. Philadelphia: WB Saunders; 1976. p. 156-281.
3. Goz M, Hazar A, Demirbag R. Multivesicular intrapericardial hydatidosis. *Eur J Cardiothorac Surg* 2011;39:605.
4. Uysalel A, Yazicioglu L, Aral A, Akalin H. A multivesicular cardiac hydatid cyst with hepatic involvement. *Eur J Cardiothorac Surg* 1998;14:335-7.
5. Arroud M, Afifi MA, EL Ghazi K, Nejari C, Bouabdollah Y. Lung hydatid cysts in children: Comparison study between giant and non-giant cysts. *Pediatr Surg Int* 2009;25:37-40.
6. Bonfrate L, Giuliente F, Palasciano G, Lamont JT, Portincasa P. Unexpected discovery of massive liver echinococcosis. A clinical, morphological, and functional diagnosis. *Ann Hepatol* 2013;12:634-41.
7. Koul PA, Koul AN, Wahid A, Mir FA. CT in pulmonary hydatid disease: Unusual appearances. *Chest* 2000;118:1645-7.
8. Gouliamos AD, Kalovidouris A, Papailiou J, Vlahos L, Papavasiliou C. CT appearances of pulmonary hydatid diseases. *Chest* 1991;100:1578-81.
9. Goinard P, Pegulla J, Pelissier G. *Le Kyste Hydatique (Therapeutique Chirurgicale)*. Paris: Masson Et Cie Publisher; 1960. p. 34.
10. Dew HR. *Hydatid disease: Its pathology, diagnosis and treatment*. Sydney: Australian Medical Publishing Company; 1928.
11. Kern P, Bardonnnet K, Renner E, Auer H, Pawlowski Z, Ammann RW, et al.; European Echinococcosis Registry. European echinococcosis registry: Human alveolar echinococcosis, Europe, 1982-2000. *Emerg Infect Dis* 2003;9:343.

How to cite this article: Sokouti M, Sokouti B, Shokouhi B, Rahimi-Rad MH. Multi-vesicular pulmonary hydatid cyst, the potent underestimated factor in the formation of daughter cysts of pulmonary hydatid disease. *Lung India* 2015;32:375-7.

Source of Support: Nil, **Conflict of Interest:** None declared.