

Gemcitabine-induced skin necrosis

SAGE Open Medical Case Reports
Volume 6: 1–4
© The Author(s) 2018
Article reuse guidelines:
sagepub.com/journals-permissions
DOI: 10.1177/2050313X18809268
journals.sagepub.com/home/sco



Maria Monica Haydock¹ , Saroj Sigdel² and Toni Pacioles²

Abstract

Since its emergence as a chemotherapy agent, gemcitabine has been associated with cutaneous adverse reactions. Rash is reported to be the most common cutaneous adverse effect. Other reported cutaneous reactions in the literature include bullous dermatosis, pseudocellulitis, subacute cutaneous lupus alopecia, and palmar–plantar erythrodysesthesia. Skin necrosis is a very rare adverse effect of this otherwise well-tolerated chemotherapeutic agent. In searching the literature, only one other case has been reported. In our report, we present a 74-year-old male with adenocarcinoma of the pancreas, status-post pancreaticoduodenectomy (Whipple procedure), who developed a rare case of skin necrosis of the lower leg 2 weeks after completing six cycles of monotherapy gemcitabine treatment.

Keywords

Oncology, gastroenterology/hepatology, pharmacoepidemiology/drug safety, chemotherapy, gemcitabine, pancreatic cancer, adverse skin reactions

Date received: 9 March 2018; accepted: 4 October 2018

Introduction

Gemcitabine is an antimetabolite nucleoside chemotherapy agent approved for the treatment of solid tumours such as pancreatic, ovarian, breast, and non-small cell lung cancer. It has a milder toxicity profile in comparison with another pyrimidine analogue, cytarabine.

Rash is a well-documented cutaneous adverse effect of gemcitabine. Other cutaneous adverse reactions that have been reported include bullous dermatosis, pseudocellulitis, subacute cutaneous lupus, alopecia, and palmar–plantar erythrodysesthesia.^{1–4} In our review of the available literature, we found that skin necrosis is a rare adverse effect. In fact, only one other documented case has a similar presentation as our patient and the potential cause has yet to be established.⁵ Necrosis, an irreversible inflammatory form of cell death is described as an uncontrolled process resulting from physical or chemical stress. Recognised patterns of necrosis may offer clues to the underlying causes but do not reflect the pathological mechanisms by which the damage occurs.⁶ In this report, we present a 74-year-old male with adenocarcinoma of the pancreas, status-post pancreaticoduodenectomy (Whipple procedure), who developed a rare case of skin necrosis of the lower leg shortly after completing six cycles of monotherapy gemcitabine.

Case presentation

A 74-year-old Caucasian male with pancreatic adenocarcinoma presented to the medical oncology clinic to initiate

chemotherapy, 3 months after a successful pancreaticoduodenectomy (Whipple procedure). At the initial visit, he was retired, lived with his wife, and was independent in performing his activities of daily living. He had a performance status of 1 (i.e. symptomatic and ambulatory; cares for self) prior to treatment. His past medical history included diet-controlled type 2 diabetes mellitus with periodic glucose checks, hypertension, benign prostatic hyperplasia, gastro-oesophageal reflux disease, osteoarthritis, and a 40-pack year smoking history but quit 20 years ago. His medications were amlodipine, losartan/hydrochlorothiazide, omeprazole, tamsulosin, oxycodone/acetaminophen, and pancrelipase.

A 2.3 cm tumour arising from the pancreatic head was initially found and extended through the duodenal wall into the surrounding peripancreatic soft tissue and the common bile duct. There was positive perineural and lymphovascular invasion, with 6/20 nodes positive. Thus, this was a T3N1M0 well-differentiated adenocarcinoma of the pancreas. His planned chemotherapy regimen was in accordance with the current National Comprehensive Cancer Network (NCCN) guidelines entailing six cycles of gemcitabine 1000 mg/m²

¹Gloucestershire Hospitals NHS Foundation Trust, Cheltenham, UK

²Joan C. Edwards School of Medicine, Marshall University, Huntington, WV, USA

Corresponding Author:

Maria Monica Haydock, Gloucestershire Hospitals NHS Foundation Trust, Sanford Road, Cheltenham GL53 7AN, UK.

Email: mtag@gmail.com



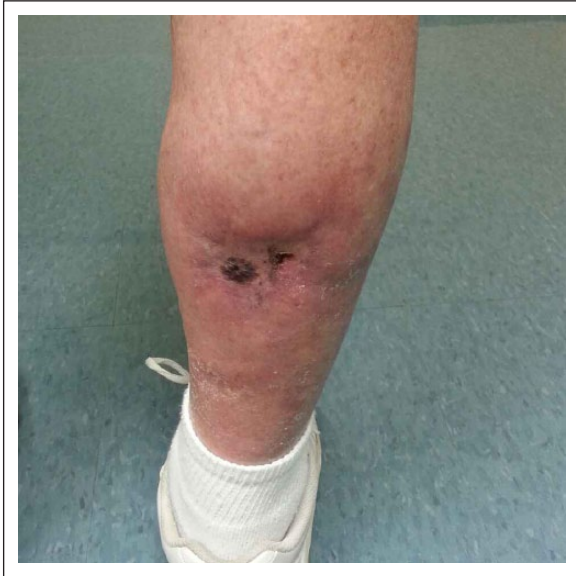

Figure 1. Initial presentation of wound at the medical oncology clinic.

IV infusion over 30min on days 1, 8, and 15 of a 28-day cycle.

Threedays after the first cycle, he presented to the emergency room and was admitted for fever, neutropenia, and bilateral ankle inflammation; initially suspected as either infective cellulitis or pseudocellulitis due to gemcitabine treatment. Complete resolution of symptoms was achieved after treatment with cefepime. The second treatment cycle resumed with the addition of 10mg dexamethasone prior to treatment to reduce the risk of recurrence. Day 8 and Day 15 of the fifth cycle were both postponed for a week due to thrombocytopenia and the gemcitabine dosage was subsequently reduced by 25%. During this time, a right lower extremity deep venous thromboembolism (DVT) was treated initially with enoxaparin and later with rivaroxaban.

Two weeks after completing the six-cycle regimen, the patient presented with a wound on the posterior aspect of the right calf with no evidence of underlying fluid collection, mass, or active bleeding. He also complained of right knee pain and swelling and denied any recent trauma to the leg. These symptoms were distinctly different from the infective cellulitis treated 5 months ago. Although he had hypertension and a smoking history, his symptoms were inconsistent with peripheral vascular disease or arteriosclerosis obliterans as he did not have signs of circulatory insufficiency and did not have symptoms of intermittent claudication. Full blood count revealed mild anaemia but did not reveal an ongoing infective or allergic process. However, his erythrocyte sedimentation rate (ESR) was elevated at 85mm/h. His CA 19-9 was mildly elevated at 60 μ /mL. However, immune complex deposition was not examined in these samples and an autoimmunity screen was not performed (Figures 1 and 2).

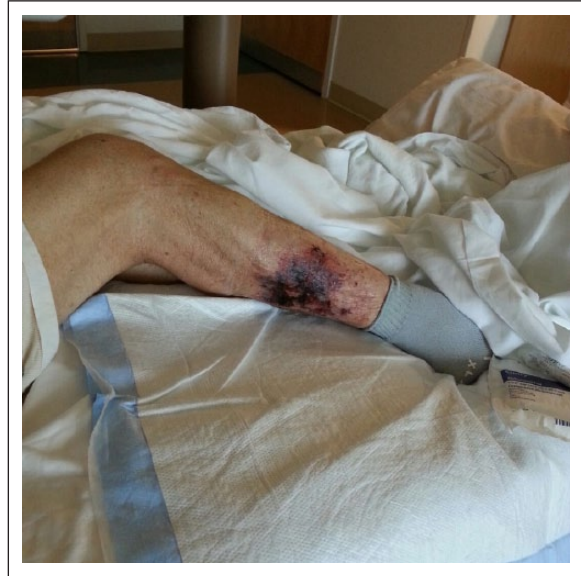

Figure 2. Progress of wound during hospital admission.

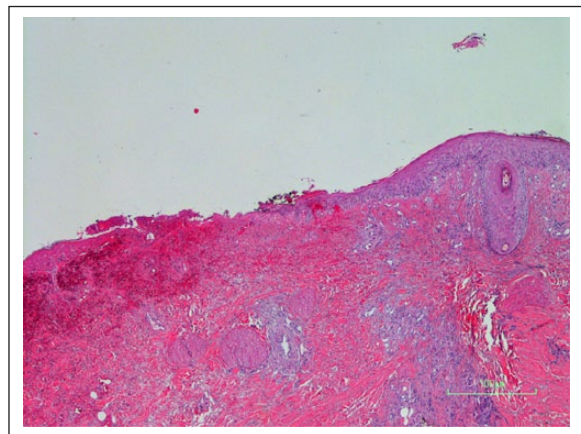


Figure 3. Low power (4 \times) view of partially denuded skin with ulceration and tissue necrosis.

Due to its presentation, this was initially thought to be infective cellulitis or a skin necrosis due to gemcitabine. The patient received vancomycin on admission and then cefazolin. Antibiotic treatment was halted after wound culture results showed no bacterial growth. Tissue biopsy of the lesion revealed areas of ulceration with tissue necrosis and acute inflammation but did not detect an infective or malignant process (Figures 3 and 4).

The pain and swelling of the right knee warranted a joint aspiration and was positive for calcium pyrophosphate crystals consistent with pseudogout. No bacterial and fungal growths were found after culture and staining.

The patient's recent history of DVT on the same leg warranted a Doppler ultrasound, which showed diffuse soft tissue oedema but no evidence of a DVT. Furthermore, the most recent CT scan prior to presentation showed stable

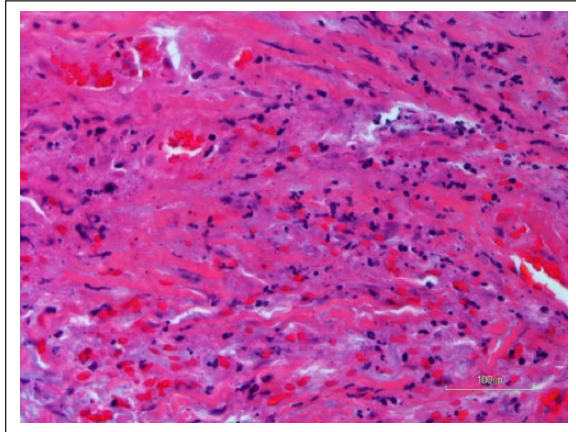


Figure 4. High power (40 \times) view of necrotic dermis with numerous acute inflammatory cells.

postoperative changes and did not suggest residual or recurrent disease, new or acute abnormalities.

He was discharged after 8 days and was further treated at the wound clinic once weekly for 8 weeks. The wound was debrided during the first four visits and collagenase Santyl ointment was applied daily for 6 weeks. Daily dressings were continued without the ointment for the final 2 weeks. The skin necrosis fully resolved after treatment at the wound clinic. The patient was then scheduled for follow-up at the medical oncology clinic every 3 months to monitor disease progression of the pancreatic cancer (Figure 5).

Discussion

Cutaneous reactions associated with gemcitabine have been well-documented since its emergence in cancer treatment. However, there has only been one other documented case of skin necrosis in a patient treated with gemcitabine for pancreatic cancer.⁵ The case report highlighted an 82-year-old female who presented with severe pain, paraesthesia, oedema, and extensive ulcerative necrosis of the lower limb following two cycles of monotherapy gemcitabine. In comparison, our patient developed skin necrosis after completing monotherapy gemcitabine.

As mentioned in the case presentation, the patient was treated for infective cellulitis shortly after the first cycle of gemcitabine treatment. Aside from infective cellulitis, a differential diagnosis would be pseudocellulitis (non-infective cellulitis). Pseudocellulitis has been reported as an adverse reaction of gemcitabine and is frequently misdiagnosed as an infection and inappropriately treated with antibiotics. Reported cases of patients treated with gemcitabine who presented with cutaneous reactions resembling cellulitis include a patient with erythema, pain, and swelling over the anterior chest after being exposed to one cycle of gemcitabine.⁴ This was assumed to be infective cellulitis and was treated with cephalexin. However, the patient's symptoms worsened

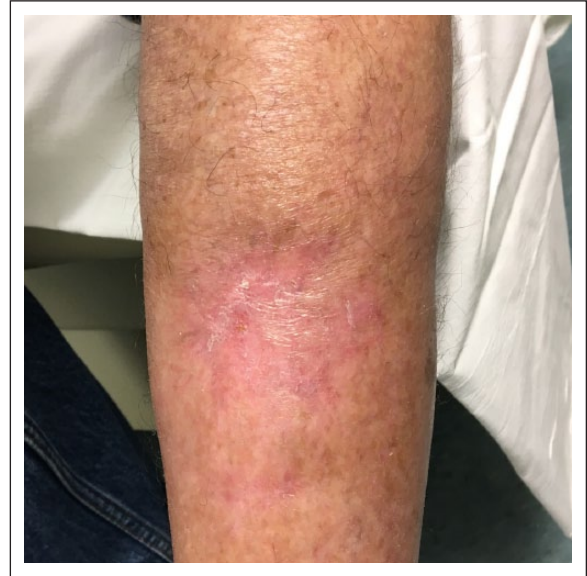

Figure 5. Complete resolution of wound 2 months after discharge from wound clinic.

despite antibiotic treatment. The symptoms were isolated and recurred in an area where the patient had radiotherapy and was therefore more consistent with radiation recall dermatitis rather than infective cellulitis. Our patient has never been exposed to radiotherapy or other chemotherapeutic agents prior to commencing monotherapy gemcitabine. In addition, his symptoms resolved after a course of antibiotics. Although this episode may have been a sign of a more serious cutaneous reaction, we treated the infective cellulitis and the skin necrosis as two separate and unrelated episodes as his presenting symptoms were very different; he was pyrexial and had raised inflammatory markers when diagnosed with infective cellulitis whereas he was afebrile and his leukocytes were within normal range when he presented with the skin lesion 5 months later.

Although our case is only the second reported case of skin necrosis associated with gemcitabine, there are other cases of skin necrosis associated with chemotherapeutic agents. A feared complication of chemotherapy that can lead to tissue necrosis is extravasation of the chemotherapeutic agent. This occurs when a chemotherapeutic agent leaks into the surrounding area of the intravenous injection.⁷ The severity of these reactions depends on the chemotherapeutic agent, dose, and concentration. Symptoms include simple skin irritation, desquamation, or phlebitis at the injection site along with the vein. In severe extravasation, ulceration and tissue necrosis may occur. At the time of writing this case report, we did not find any reports of gemcitabine causing tissue necrosis due to extravasation at the injection site. Furthermore, the location of the skin necrosis in our patient was on the posterior area of the lower leg and not at the injection site.

Another reported case of skin necrosis associated with chemotherapy is with combination therapy of paclitaxel and

fluorometholone, which resulted to full-thickness necrosis at sites distant from the injection site.⁸ However, it is unclear whether the skin necrosis was caused by an individual agent or due to a drug interaction of the combination therapy. Compared with the case mentioned, our patient was only exposed to gemcitabine and was not previously exposed to other chemotherapeutic agents.

Vascular toxicity and endothelial damage have been associated with gemcitabine.⁹ It potentiates an increase in platelet adherence, immune complex deposition, and a hypercoagulable state. Immune-mediated small vessel vasculitis has also been reported after being exposed to gemcitabine (i.e. hypersensitivity vasculitis).¹⁰ In further search of the literature, we found cases of digital necrosis reported as an adverse effect of gemcitabine treatment.^{11–13} The most suggested mechanism is the development of necrotising vasculitis after exposure to gemcitabine. In two of these cases, the authors proposed that the adverse effect was immunologic in origin.^{11,12} Antinuclear antibodies (ANA) titres were elevated, demonstrating a systemic autoimmune process. Although deposition of immune complexes was not examined in these patients, there is experimental evidence that immune complexes that circulate in excess are deposited within blood vessel walls in leukocytoclastic vasculitis, which is a hypersensitivity vasculitis.¹⁴ Upon review, it would have been helpful to have done an autoimmune screen and check for immune complex deposition of the wound to establish whether our patient developed an autoimmune reaction.

In summary, as the patient just completed gemcitabine treatment, which is known to cause cutaneous reaction, we believe that the skin necrosis was an idiosyncratic adverse drug reaction induced by gemcitabine. We also acknowledge that the skin necrosis presented 2 weeks after completion of the treatment (i.e. six cycles) rather than while being on the treatment. To further narrow our diagnosis, we could have investigated whether this was autoimmune in origin (i.e. ANA, p-anca, c-anca). Due to its rarity, there are no existing guidelines in treating this type of adverse reaction. Complete resolution was achieved after debridement and daily wound dressing with collagenase Santyl ointment.

Conclusion

Skin necrosis is a very rare adverse effect of the otherwise well-tolerated gemcitabine. In addition to our case, only one other case has been reported. This idiosyncratic adverse drug reaction may present not only during treatment but also after treatment has been completed. An autoimmune screen or immune complex deposition analysis may be helpful in establishing the presence of an autoimmune reaction. Although there are no guidelines in treating this type of adverse reaction, complete resolution of the wound can be achieved with appropriate wound care.

Declaration of conflicting interests

The author(s) declared no potential conflicts of interest with respect to the research, authorship, and/or publication of this article.

Ethical approval

Our institution does not require ethical approval for reporting individual cases or case series.

Funding

The author(s) received no financial support for the research, authorship, and/or publication of this article.

Informed consent

Verbal informed consent was initially obtained from the patient(s) for their anonymised information to be published in this article. In addition, a written consent was obtained and signed by the patient on 3 November 2016.

ORCID iD

Maria Monica Haydock  <https://orcid.org/0000-0002-6420-6855>

References

1. D'epiro M, Salvi A, Luzi C, et al. Drug cutaneous side effect: focus on skin ulceration. *Clin Ter* 2014; 165(4): e323–e329.
2. Imen A, Amal K, Ines Z, et al. Bullous dermatosis associated with gemcitabine therapy for non-small-cell lung carcinoma. *Respir Med* 2006; 100(8): 1463–1465.
3. Wiznia LE, Subtil A and Choi JN. Subacute cutaneous lupus erythematosus induced by chemotherapy: gemcitabine as a causative agent. *JAMA Dermatol* 2013; 149(9): 1071–1075.
4. Tan DH, Bunce PE, Liles WC, et al. Gemcitabine-related 'pseudocellulitis': report of 2 cases and review of the literature. *Clin Infect Dis* 2007; 45(5): e72–e76.
5. D'epiro S, Salvi M, Mattozzi C, et al. Gemcitabine-induced extensive skin necrosis. *Case Rep Med* 2012; 2012: 831616.
6. Kumar V, Vinay AK and Aster J. *Robbins basic pathology: with STUDENT CONSULT online access, 9e (Robbins pathology)*. 9th ed. Philadelphia, PA: Elsevier Health Sciences, 2012.
7. Schrijvers DL. Extravasation: a dreaded complication of chemotherapy. *Ann Oncol* 2013; 14(Suppl. 3): iii26–iii30.
8. Aboolian A, Tornambe R, Ricci M, et al. Skin necrosis in the presence of paclitaxel and fluorometholone. *Support Care Cancer* 1999; 7(3): 158–159.
9. Dasanu CA. Gemcitabine: vascular toxicity and prothrombotic potential. *Expert Opin Drug Saf* 2008; 7(6): 703–716.
10. Voorburg AM, van Beek FT, Slee PH, et al. Vasculitis due to gemcitabine. *Lung Cancer* 2002; 36(2): 203–205.
11. Banach MJ and Williams GA. Purtscher retinopathy and necrotizing vasculitis with gemcitabine therapy. *Arch Ophthalmol* 2000; 118(5): 726–727.
12. Vénat-Bouvet L, Ly K, Szélag JC, et al. Thrombotic microangiopathy and digital necrosis: two unrecognized toxicities of gemcitabine. *Anticancer Drugs* 2003; 14(10): 829–832.
13. Kuhar CG, Mesti T and Zakotnik B. Digital ischemic events related to gemcitabine: report of two cases and a systematic review. *Radiol Oncol* 2010; 44(4): 257–261.
14. Claudy A. Pathogenesis of leukocytoclastic vasculitis. *Eur J Dermatol* 1998; 8(2): 75–79.