

Failed labral reconstruction of the hip can be successfully revised to another labral reconstruction: improved patient-reported outcomes at a minimum of 2-year follow-up

Brian J. White^{1,2}, R. Presley Swann³, Hannah Spears¹, Anna Shafer¹,
Shannon M. Constantinides^{4,5*}

¹Western Orthopaedics, 1830 Franklin Street, Denver, CO 80218, United States, ²Hip Preservation Institute at HCA Swedish Medical Center, 501 East Hampden Ave, Englewood, CO 80113, United States, ³Colorado Knee & Hip, 799 East Hampden Ave, Englewood, CO 80113, United States, ⁴Rock Harbor Research Institute, Key Largo, FL 33037, United States and ⁵Colorado Center of Orthopaedic Excellence, Colorado Springs, CO 80920, United States

*Corresponding author. Rock Harbor Research Institute, 13 Corrine Place, Key Largo, FL 33037, United States. E-mail: Shannon.constantinides@gmail.com

ABSTRACT

The purpose of this study was to validate the success of revision arthroscopic circumferential allograft labral reconstruction (CLR) in nonarthritic hips, which, in the rare case of failure, had previously undergone labral reconstruction by the same surgeon. Using a minimum of 24-month follow-up, data from 24 hips having undergone revision CLR were analyzed to determine improvements in patient-reported outcomes (PROs). All included cases completed a minimum of 24 months follow-up, with a success rate of 96%. All PROs improved significantly, with exceptionally strong measures of effect. Modified Harris Hip Scores improved by a mean of 26.68 points, with 88% of patients meeting the minimal clinically important difference (MCID) (+6.49, $P \leq .001$, $d = 1.32$). Lower Extremity Functional Scale scores improved by a mean of 21.88 points, with 78% of patients meeting the MCID (+7.79, $P \leq .001$, $d = 1.32$). Pain as rated by the Visual Analog Scale, including at rest, during activities of daily living, and with sports, was significantly improved with strong measures of effect, with >75% of patients having met the MCID. This study validated that a failed labral reconstruction of the hip can be revised safely and effectively to another labral reconstruction of the hip. While labral reconstruction has broadly been shown to result in highly favorable outcomes, this study demonstrated that in the rare case of failure, revision CLR is not only feasible but results in improved pain and functionality.

INTRODUCTION

Arthroscopic allograft circumferential labral reconstruction (CLR) of the hip has been widely validated as a highly successful operation in the presence of an irreparable labrum. Findings from a rapidly expanding body of research have demonstrated that across thousands of patients spanning at least six decades of age, arthroscopic labral reconstruction of the hip reduces pain and improves function [1–7]. By addressing the osseous pathomorphological and pericapsular/capsulolabral conditions that result in femoroacetabular impingement (FAI) and by replacing deficient, diseased, or otherwise irreparable labral tissue in its entirety with an allograft, the femoroacetabular fluid seal can be circumferentially reestablished and healthy biomechanics restored [1, 8–16]. Despite the established success of this procedure, there are patients who fail the operation and require consideration for additional surgery [1, 17–22].

Perhaps due to reported high rates of success and comparatively low rates of failure, there is a relative lack of research

regarding next steps when a labral reconstruction fails. The hypothesis of this therapeutic case series took the position that arthroscopic allograft CLR of the hip is a safe and effective option for hip preservation in patients with pain and loss of function following a previous labral reconstruction that has gone on to failure. The aim of this case series was to demonstrate that revision CLR provides an alternative treatment to patients who would have traditionally been given no other option in the setting of labral reconstruction failure. The purpose of this study was to validate the success of revision arthroscopic circumferential CLR in nonarthritic hips, which, in the rare case of failure, had previously undergone labral reconstruction by the same surgeon.

MATERIALS AND METHODS

Patient selection and surgical indication

This study was conducted with institutional review board approval. It included data from the lead author's prospective hip

registry. Of the 1990 CLRs performed by the lead author during the collection period of 1 January 2016 to 31 December 2020, 24 hips (1.2%) were included as they were deemed to have failed. Failure was defined as persistent pain and dysfunction of the ipsilateral hip in the setting of preserved joint space. Symptomology was determined by the patient report. Recurrent chondrolabral and osseous pathomorphology was determined by the lead author using clinical exams, plain-film radiographs, and magnetic resonance imaging. In these cases and following appropriate conservative management as directed by the lead author, ipsilateral revision surgery was felt to be indicated and was then offered to patients. In cases where borderline acetabular dysplasia was determined to be a contributing factor in the failure, revision CLR with Ganz periacetabular osteotomy (PAO) was indicated and offered to the patients. This study excluded cases with a minimum of <2-year follow-up or cases with progression of osteoarthritic disease and joint space loss of <4 mm.

Data collection and outcome measures

Preoperative data were recorded by the lead author, who was the surgeon in all cases: for both the initial labral reconstruction and the revision CLR. Patient-reported outcomes (PROs) included the Lower Extremity Functional Scale (LEFS), the modified Harris Hip Score (mHHS), and the Visual Analogue Scale (VAS)

at rest, with activities of daily living (ADLs), and with sports. PROs were collected both preoperatively and at the most recent follow-up. Patient satisfaction, which was rated on a scale of 1–10 (where 0 = completely dissatisfied and 10 = extremely satisfied), was recorded at the most recent follow-up.

Surgical technique

Revision CLR and the operation's associated postoperative protocol are approached using the same techniques previously described by the lead author for both primary CLR and CLR done as a revision following a failed labral repair [1, 8, 14, 23–25]. In all cases, CLR was performed using a fresh frozen tensor fascia lata allograft. In cases where borderline hip dysplasia [center edge angle (CEA) measuring 24°–27°] was identified as a potential factor in the initial CLR failure, Ganz PAO was performed in coordination as a second operation by a separate specialist 1 week later.

Postoperative protocol

If microfracture was performed, patients were 20% weight-bearing for 6 weeks. Patients were otherwise 30% weight-bearing for 4 weeks while undergoing intermittent continuous passive motion for 2 weeks. If a PAO was performed, weight-bearing was started at 25% for 2 weeks and was increased by 25% every 2 weeks until progression into full weight-bearing at around Week 6. External rotation of the hip was limited to neutral for 2 weeks. Deep vein thrombosis prophylaxis included the use of sequential compression devices and aspirin of 325 mg daily for 10 days. Heterotopic ossification prophylaxis included naproxen of 500 mg twice daily for 2 weeks. Physical therapy using the lead author's protocol was initiated within 1 week of surgery and continued until patient goals were met.

Table 1. Demographic characteristics.

Characteristics	N
Hips meeting criteria	24
Right	16 (67%)
Left	8 (33%)
Sex	
Male	4 (17%)
Female	20 (83%)
Mean age at surgery (years)	33 (18–53)
Mean follow-up (months)	35 (24–72)
Mean number of revision anchors	11 (8–12)
Mean original anchors	8 (5–11)
Mean revision allograft length (mm)	12 (11–14)
Mean original allograft length (mm)	10 (8.5–14)
Initial CLR was a revision of a prior failed repair (as performed by the lead author or outside surgeon)	8 (33%)
Time to revision surgery (years)	3 (1–6)

Table 2. Associated procedures.

Procedure	N
Capsular plication	22 (92%)
Sutures used	M = 1.1 (1–2)
Femoroplasty	21 (88%)
Acetabular chondroplasty	18 (75%)
Ganz PAO	12 (50%)
Iliopsoas release	2 (8%)
Acetabuloplasty to correct pincer	1 (4%)
Excision of heterotopic ossification	1 (4%)

Note: some patients underwent multiple accompanying procedures.

Table 3. Intraoperative findings.

Chondrolabral/osseous finding	N
Labral characteristics	
Scarred	13 (54%)
Recurrent tear	11 (45%)
Bruised	11 (45%)
Hypertrophic labral tissue	3 (13%)
Inflamed	2 (8%)
Ossified	2 (8%)
Graft did not incorporate	2 (8%)
Otherwise damaged	2 (8%)
Deficient/insufficient labral tissue	1 (4%)
Acetabular characteristics	
Borderline acetabular dysplasia	12 (50%)
Coxa profunda	4 (16%)
Otherwise retroverted	2 (8%)
Retroverted related to HO formation	1 (4%)
Anteverted	1 (4%)
Femoral characteristics	
Reactive osteophyte	11 (45%)
Flattened	6 (25%)
Mild regrowth of cam	3 (12%)

Note: some patients listed multiple reasons.
HO, heterotopic ossification.

Statistical analysis

While this was a retrospective case series, a power analysis using G-Power (<http://www.gpower.hhu.de/>) was preliminarily conducted to ensure an adequate sample size and reduce the risk of statistical error. A sample size of 19 was determined to be needed to obtain a power of $\geq 80\%$, statistical significance, and modest-to-large measures of effect. Because the data were normally distributed, standard deviations (SDs) were reported and paired samples *t*-tests were used to measure changes between the mean pre- and postoperative PRO scores. Patient Acceptable Symptom State (PASS) scores were calculated for the mHHS based on previously published hip arthroscopy data [26, 27]. Minimal clinically important differences (MCIDs) and Cohen's *d* were calculated using distribution-based methods to assess the magnitude of effects [26, 28–37]. Because the study was designed as a therapeutic case series, there were no control or comparison groups; no assessment was made for the prospective or predictive differential effect of changes across time; and a multivariate model was not created to assess for multiple comparisons or to control for covariates or other extraneous variables.

IMB SPSS Statistics, Version 28, was used to perform statistical analysis. A *P*-value of $\leq .05$ was considered statistically significant, and a Cohen's *d* of ≥ 0.8 was considered an effect of large magnitude.

RESULTS

Demographics

Twenty-four hips (16 right, 8 left) including 20 females and four males with a mean age of 33 years (18–53 years) met inclusion criteria. No cases were lost to follow-up. The mean time for revision surgery was 3 years (1–6 years). The mean time to the most recent follow-up was 35 months (24–72 months). One-third of patients (*N* = 8) had undergone an initial arthroscopic labral repair prior to their failed labral reconstruction, making the operation used in this study their third" ipsilateral hip surgery. The remaining two-thirds of patients (*N* = 16) had undergone a primary labral reconstruction prior to the revision included in this study, making the operation used in this study their "second" ipsilateral hip surgery. Table 1 describes patient demographics.

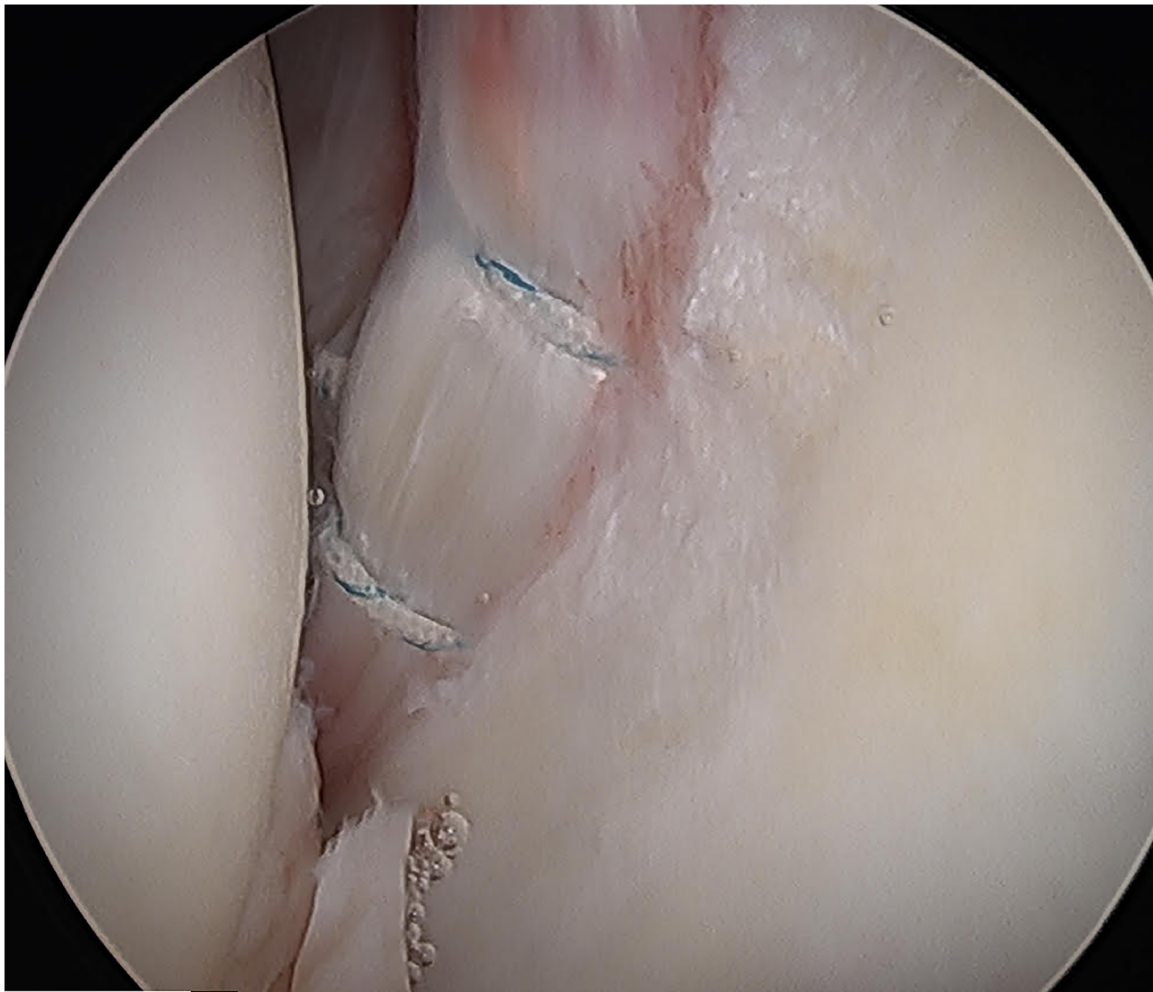


Figure 1. Failed labral graft (antero-inferior graft as viewed from the anterolateral portal) showing inflammatory changes, adhesions, and chondrolabral fibrillation. The patient is in a supine position with the hip on-traction.

Surgical findings

Mean postoperative allograft lengths measured 12 cm (11–14 cm). The mean number of anchors used was 11 (8–12). Postoperative revision CLR is shown in Figs 3 and 4. Associated procedures (Table 2) were performed as indicated by the lead author. These included capsular plication ($N = 22$, 92%), femoroplasty ($N = 21$, 88%), acetabular chondroplasty ($N = 18$, 75%), iliopsoas release ($N = 2$, 8%), and excision of heterotopic ossification ($N = 1$, 4%). Twelve patients (50%) were identified as having borderline acetabular dysplasia (CEA measuring 24° – 27°) and underwent a Ganz PAO of 1 week following their revision CLR by a second surgeon. All hips underwent varying degrees of acetabular excoriation to expose a bleeding surface to which the labral graft could biologically adhere; however, great care was taken to avoid over-resection of the acetabulum, which would result in iatrogenic dysplasia. No cases required tibial or femoral osteotomy.

Characteristics observed in hips that failed the initial CLR (Table 3, Figs 1 and 2) included capsulolabral adhesions ($N = 13$, 54%), recurrent labral tearing ($N = 11$, 45%), labral bruising ($N = 11$, 45%), labral hypertrophy ($N = 3$, 13%), labral inflammation ($N = 2$, 8%), ossification of labral tissue ($N = 2$, 8%), failure of the labral graft to integrate ($N = 2$, 8%), and deficient/insufficient labral tissue ($N = 1$, 4%). Osseous

morphological characteristics noted in hips with initial CLR failure were divided into categories as pertaining to either the femur or acetabulum. In regard to acetabular morphology, this included borderline acetabular dysplasia (CEA measuring 24° – 27° , $N = 12$, 50%), coxa profunda ($N = 4$, 16%), retroversion due to heterotopic ossification formation ($N = 1$, 4%), otherwise noted retroversion ($N = 2$, 8%), and acetabular anteversion ($N = 1$, 4%). In regard to femoral morphology, this included reactive osteophyte formation ($N = 11$, 45%), flattening of the femoral head ($N = 6$, 25%), and mild regrowth of the cam at the femoral head–neck junction ($N = 3$, 12%). Nearly all patients ($N = 21$, 95%) required some degree of recontouring of the femoral head–neck junction to address some degree of residual cam deformity or regrowth.

Patient-reported outcomes

LEFS scores improved by an overall mean of 21.88 points ($P \leq .001$, $d = 1.32$), with 78% of cases meeting the MCID (+7.79 points). MHHS scores improved by an overall mean of 26.68 points ($P \leq .001$, $d = 1.54$), with 88% of cases meeting the MCID (+6.49 points). Over one-half of patients met the PASS for the mHHS based on metrics from previously published data (58%, $N = 14$) [26, 27]. Patients meeting PASS increased to 75% when the threshold was expanded to capture PASS ± 10 ,

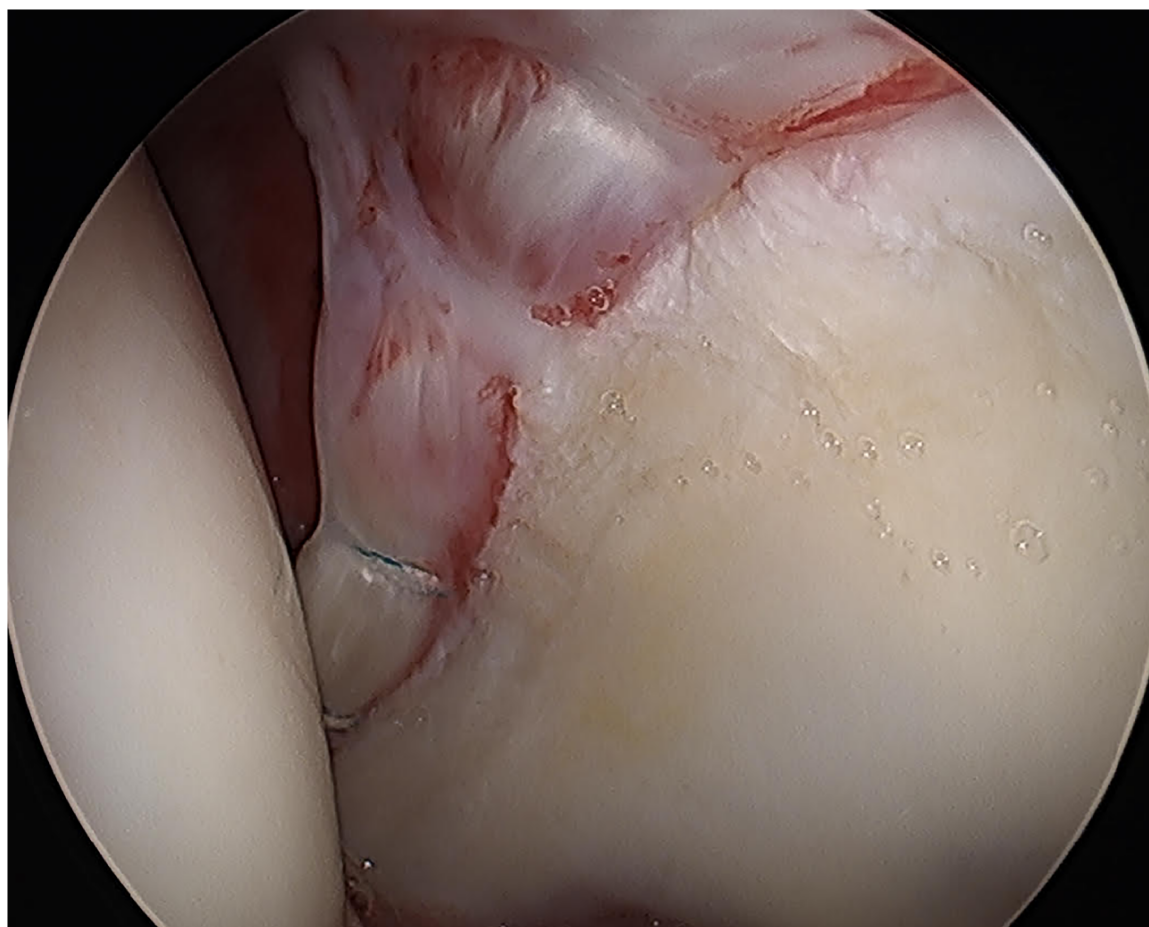


Figure 2. Failed labral graft (antero-superior labral graft as viewed from the anterolateral portal) showing inflammatory changes, adhesions and chondrolabral fibrillation. The patient is in a supine position with the hip on-traction.

which was done to include patients who had met MCID, and were noted to have improved by range of 10–40 points for the mHHS. VAS at rest improved to a postoperative mean of 2.54/10 ($P = .006$, $d = 0.85$). VAS with ADLs improved to a postoperative mean of 3.79/10 ($P \leq .001$, $d = 1.38$). VAS with sports improved to a postoperative mean of 5.22/10 ($P \leq .001$, $d = 1.37$). Nearly one-half of patients (40%) reported a postoperative satisfaction level of 10/10 (completely satisfied) at the most recent follow-up. The mean postoperative satisfaction level was rated 8/10. Table 4 summarizes PRO findings.

Radiographic outcomes

In patients with acetabular over-coverage/pincer-predominant FAI, preoperative CEA was corrected to a postoperative mean

of 32° ($M\Delta = 3.32^\circ$, $P = .114$, $d = 0.56$). In patients with borderline acetabular dysplasia who underwent concomitant PAO, preoperative CEA was corrected to a postoperative mean of 36° ($M\Delta = 11^\circ$, $P \leq .001$, $d = 2.9$). In the PAO group, the mean preoperative Tönnis angle was corrected to a mean of 0.42° ($M\Delta = 8.1$, $P \leq .001$, $d = 3.8$). In patients requiring recontouring of the femoral head–neck junction to address residual cam or regrowth mean alpha angle (AA) was corrected from 46.62° to 43.52° ($N = 21$ (95%), $P = .018$, $d = 0.49$). Radiographic outcomes are summarized in Table 5.

Complications

No postoperative surgical site infections, venous thromboembolism, or other morbidities were noted. All patients underwent

Table 4. Patient-reported outcomes.

	Mean	SD	95% CI	One-tailed <i>P</i>	Cohen's <i>d</i>	Patients meeting the MCID
			Lower/upper			
LEFS						
Preoperative	37.79	15.6				
Postoperative	58.65	21.77				
Change	21.88	20.39	12.27–29.9	$\leq .001$	1.32	78% (+7.79)
mHHS						
Preoperative	49.41	12.99				
Postoperative	76.1	20.7				
Change	26.68	19.44	18.46–34.89	$\leq .001$	1.54	88% (+6.49)
VAS at rest						
Preoperative	4.25	2.01				
Postoperative	2.54	2.19				
Change	1.71	3.07	0.41–3.01	.006	0.8	79% (+1)
VAS with ADLs						
Preoperative	6.33	1.83				
Postoperative	3.79	2.57				
Change	2.54	2.96	1.29–3.79	$\leq .001$	1.52	75% (+.67)
VAS with sports						
Preoperative	8.21	2.11				
Postoperative	5.22	3.09				
Change	2.91	3.33	1.47–4.35	$\leq .001$	1.11	75% (+1.05)
Postoperative satisfaction	8.14	2.27				

Table 5. Radiographic outcomes.

Radiographic metric	Mean	SD	95% CI	One-tailed <i>P</i>	Cohen's <i>d</i>
			Lower/upper		
Preoperative CEA ($N = 24$)	29 (22–44)	6			
Preoperative CEA with Ganz ($N = 12$)	34 (29–44)	3.32			
Postoperative CEA with Ganz	32.56 (30–35)	1.51			
Mean Δ CEA with Ganz	1.44	3.32	(–1.1 to –3.99)	.114	0.56
Preoperative CEA with Ganz ($N = 12$)	24 (22–27)	1.44			
Postoperative CEA with Ganz	36 (27–41)	3.74			
Mean Δ CEA with Ganz	11	3.2	(–13.88 to –9.58)	$\leq .001$	2.9
Preoperative Tönnis angle with Ganz	8.5 (3–12)	2.2			
Postoperative Tönnis angle with Ganz	0.42 (–4 to –3)	1.98			
Mean Δ Tönnis angle with Ganz	8.1	2.31	(6.61–9.55)	$\leq .001$	3.8
Preoperative AA ($N = 21$)	46.62	8.39			
Postoperative AA ($N = 21$)	43.52	1.97			
Mean Δ AA	3.09	6.29	(0.23–5.95)	.018	0.49

Notes: Means are measured in degrees. Tönnis information was only collected on patients having undergone concomitant Ganz PAO at the time of revision arthroscopic allograft CLR.

Table 6. Variables associated with labral reconstruction failure.

Cause	N
Borderline acetabular dysplasia	12 (50%)
Trauma (fall, MVA, etc.)	5 (21%)
Hypermobility	4 (16%)
Postoperative heterotopic ossification	2 (8%)
Postoperative infection	2 (8%)
Persistent iliopsoas pain/popping	2 (8%)
Recurrent pain of an unclear etiology	2 (8%)
Residual pincer/subspine impingement	1 (4%)

Note: some patients listed multiple reasons.
MVA, motor vehicle accident.

both spinal and general anesthesia without incident. Patients were placed on traction intermittently throughout the operation for an approximate cumulative total of 90 min. No lasting cases of neuropraxia were reported.

DISCUSSION

This large therapeutic case series demonstrated that in the rare case of failure, labral reconstruction of the hip can safely and

successfully be revised into another labral reconstruction, resulting in improved pain and functionality. Results of this study add to the exceedingly limited research on next steps in the event that a labral reconstruction of the hip fails. This case series demonstrated that there is a surgical option in hip preservation for patients who historically would have had to live with pain and dysfunction.

The operation was determined to have a 96% survivorship rate at the time of the most recent follow-up. One patient converted to a total hip arthroplasty. PROs were statistically and clinically improved. The average mHHS score improved by a mean of ~27 points, with 88% of patients having met the MCID. The average LEFS score improved by a mean of ~22 points, with 78% of patients having met the MCID. VAS scores at rest, with ADLs, and with sports all improved significantly, and patient satisfaction was rated highly at an average of 8/10. Radiographic measurements indicated correction of underlying osseous pathomorphology.

It is the experience of the lead author that labral reconstruction is less prone to failure than arthroscopic labral repair [13]. As a result, his practice has focused exclusively on arthroscopic CLR since 2012. However, as is the nature of surgery, some cases result in suboptimal outcomes. Table 6 outlines variables that were identified as potentially contributing to failure. In some cases, it was noted that potential causes of failure may have been multifactorial. Variables associated with CLR failure included

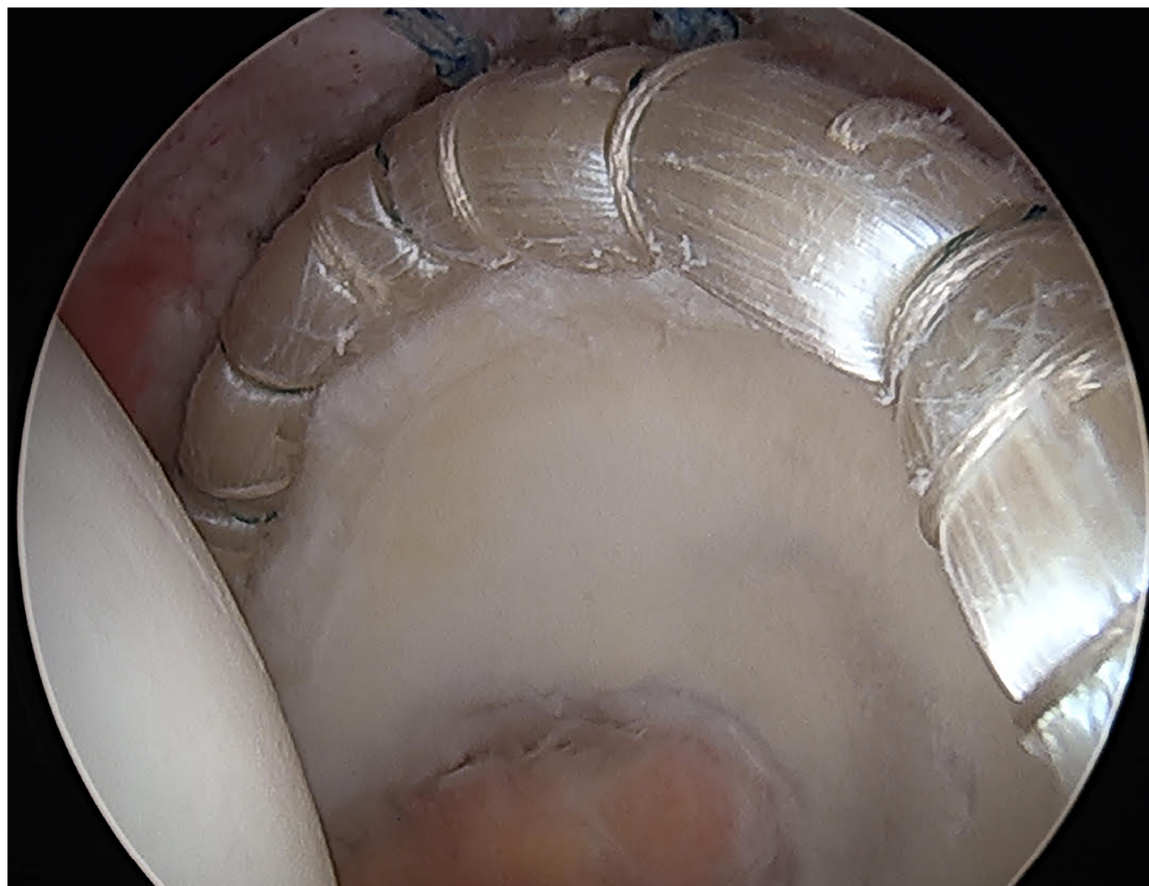


Figure 3. In the same patient in Figures 1 & 2: revision CLR with a new 12.5 cm allograft affixed with 13 anchors. In this figure, the anterosuperior graft is viewed from the anterolateral portal. The patient is in a supine position with the hip on-traction.

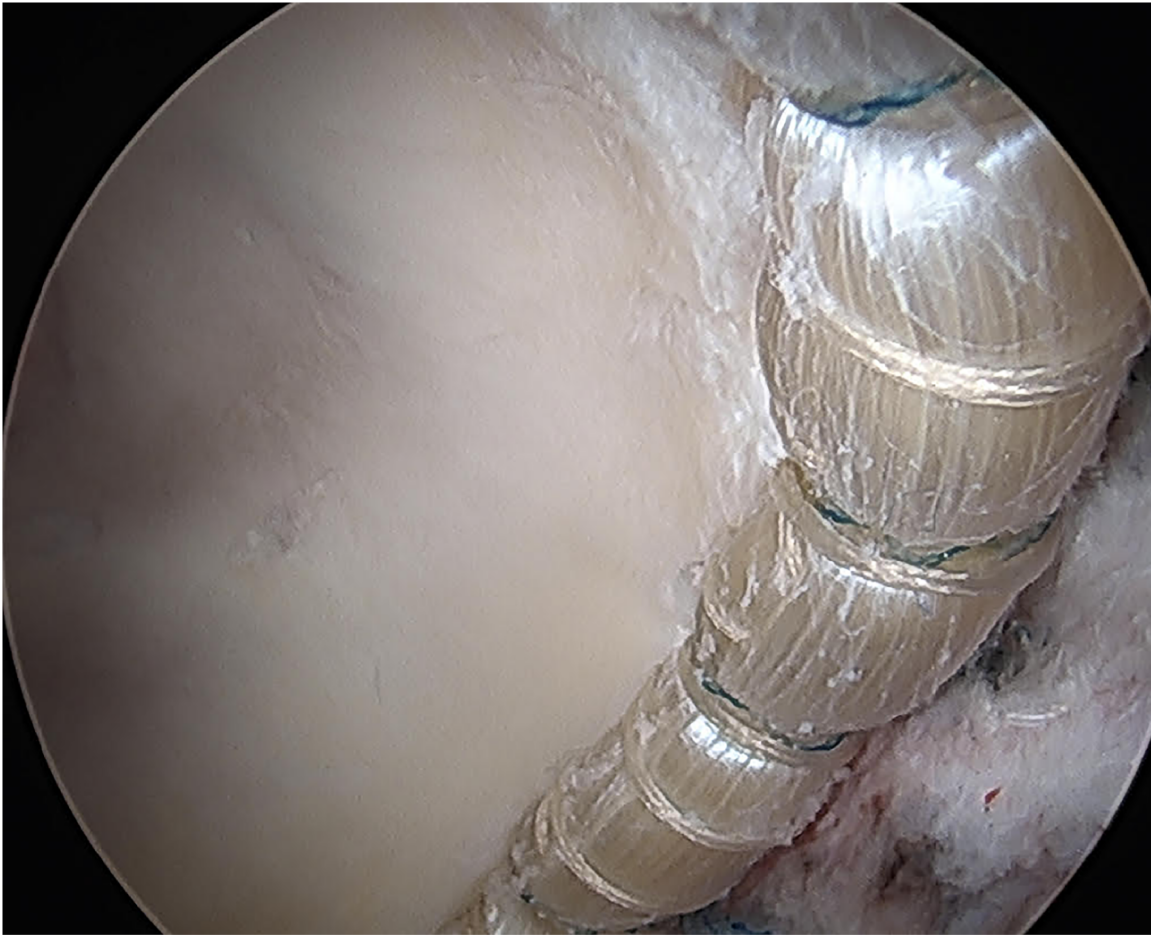


Figure 4. In the same patient in Figures 1, 2, & 3: the posterior aspect of the revised CLR as viewed from the anteromedial portal. The patient is in a supine position with the hip on-traction.

a history of postoperative trauma ($N = 5$, 21%), hypermobility of the joint ($N = 4$, 16%), postoperative heterotopic ossification ($N = 2$, 8%), postoperative infection ($N = 2$, 8%), persistent iliopsoas pain or popping ($N = 2$, 8%), and continued pain of an unclear etiology ($N = 2$, 8%). Residual impingement morphology was felt to contribute to recurrent FAI, including varying degrees of residual cam deformity or regrowth ($N = 21$, 95%), residual pincer-type FAI ($N = 1$, 4%), and borderline acetabular dysplasia ($N = 12$, 50%).

As noted earlier, 50% ($N = 12$) of patients were identified as having borderline hip dysplasia that required treatment at the time of revision CLR with accompanying PAO. The decision to perform a PAO, which is a highly invasive operation associated with increased recovery and potential surgical risk, was not taken lightly by the lead author. These hips were noted to have borderline dysplasia (CEAs measuring 24° – 27°), which, at the time of the initial labral reconstruction, was not felt to be significant enough to justify the PAO. When the initial labral reconstruction failed and revision CLR was performed, the borderline dysplasia was addressed with concomitant PAO as it was felt to be contributory to the failure of the initial surgery. As the revision CLR was found to be feasible, safe, and possible, the PAO could then be added as an associated procedure. The authors acknowledge that an initial PAO could have potentially prevented the need for

a second surgery. It is felt that the combination of the revision CLR and PAO is the reason for the postoperative success, rather than either operation in isolation. The authors also recognize that correction of the acetabular position with PAO alone would have left a damaged or incompetent labral graft in the joint and would not fully restore normal hip mechanics or completely improve pain and function. The two procedures needed to be performed together. It was felt that the ability to revise the labral reconstruction is what allowed the patient to be considered for an additional attempt at hip preservation with the PAO.

Limitations and directions for future research

Due to the nature of the therapeutic case study design, this study lacked the control inherent to experimental research. Therefore, researchers could not control for confounding variables, such as individual history of injury, disease, or comorbid medical history, or “persons-vectors” [31]. Due to the nature of the study design, it was not possible to control for the technological and surgeon-dependent improvements that took place over the data collection period. The cases included in this study were limited to those who had previously undergone labral reconstruction by the lead author, who is a hip arthroscopist with specialization in labral reconstruction. The authors realize that results of this

technically demanding surgery may not be generalizable. Additionally, the authors acknowledge that prior to case selection for this study, patients may have failed and followed up elsewhere. Future research should include longer-term follow-up, cases performed by outside surgeons, the role of and indications for concomitant Ganz PAO, and studying CLR and CLR/PAO combination cohorts individually or with a case-matched design.

In terms of statistical testing, results in this study are similar to those noted in the authors' previous research as well as outside studies evaluating the psychometrics of such PROs as the mHHS [1, 2, 8, 13, 25–27]. This finding establishes a preliminary degree of reliability for the operation. For the purposes of this study, the authors chose to focus on the MCID and Cohen's *d* to assess the magnitude of outcomes, as these statistics represent pre- to postoperative change, whereas a limitation to the PASS is that it is an absolute number and may not reflect patients who had substantial improvement but did not meet a predefined postoperative numeric value.

CONCLUSION

This study validated that a failed labral reconstruction of the hip can be revised safely and effectively to another CLR of the hip. Results of this study demonstrated that across the spectrum of age, capsulolabral characteristics, varying degrees of osseous pathomorphology, and individual patient histories, CLR is safe and feasible, results in improved pain and functionality, and allows for an additional attempt at hip preservation for patients who have fallen short of collective expectations with their initial surgery. Factors such as borderline dysplasia should be addressed in the revision operation to maximize the potential for mechanical improvement and global success. In conclusion, results from this study demonstrated that revision CLR provides an option for patients and surgeons who traditionally would have otherwise had limited treatment alternatives, and would have felt to have been at a dead end of hip preservation.

ACKNOWLEDGEMENTS

None declared.

CONFLICT OF INTEREST

B.J.W. is a development consultant for Smith & Nephew, Allosource, and Biomet; and receives royalties from Zimmer and Biomet. RPS is a consultant for Smith & Nephew and provides fellowship support for Link.

FUNDING

None declared.

DATA AVAILABILITY

Data underlying this article will be shared on reasonable request by the authors.

REFERENCES

- White BJ, Constantinides SM. Allograft labral reconstruction of the hip: expanding evidence supporting greater utilization in hip arthroscopy. *Curr Rev Musculoskelet Med* 2022;**15**:27–37.
- White BJ, Patterson J, Scoles AM *et al.* Hip arthroscopy in patients aged 40 years and older: greater success with labral reconstruction compared with labral repair. *Arthroscopy* 2020;**36**:2137–44.
- Owens JS, Lee MS, Jimenez AE *et al.* Sex-based differences in athletes undergoing primary hip arthroscopy with labral reconstruction: a propensity-matched analysis with minimum 2-year follow-up. *Orthop J Sports Med* 2022;**10**:23259671221100860.
- Jimenez AE, Lee MS, Owens JS *et al.* Revision hip arthroscopy with labral reconstruction for irreparable labral tears in athletes: minimum 2-year outcomes with a benchmark control group. *Am J Sports Med* 2022;**50**:1571–81.
- Scanaliato JP, Chasteen J, Polmear MM *et al.* Primary and revision circumferential labral reconstruction for femoroacetabular impingement in athletes: return to sport and technique. *Arthroscopy* 2020;**36**:2598–610.
- Maldonado DR, Chen SL, Yelton MJ *et al.* Return to sport and athletic function in an active population after primary arthroscopic labral reconstruction of the hip. *Orthop J Sports Med* 2020;**8**:2325967119900767.
- Wolff AB, Hogan GW, Salfiti C *et al.* Circumferential acetabular labral reconstruction provides equivalent improvement to labral repair despite greater initial severe of damage at two-year follow-up. *J Hip Preserv Surg* 2016;**3**:S17–S18.
- White BJ, Spears H, McKaughan Q *et al.* Treatment of severe pincer-type femoroacetabular impingement with arthroscopic significant acetabular rim correction and circumferential labral reconstruction improves patient-reported outcome measures. *Arthroscopy* 2022;**39**:41–50.
- Philippon MJ, Nepple JJ, Campbell KJ *et al.* The hip fluid seal—Part I: the effect of an acetabular labral tear, repair, resection, and reconstruction on hip fluid pressurization. *Knee Surg Sports Traumatol Arthrosc* 2014;**22**:722–29.
- Nepple JJ, Philippon MJ, Campbell KJ *et al.* The hip fluid seal—Part II: the effect of an acetabular labral tear, repair, resection, and reconstruction on hip stability to distraction. *Knee Surg Sports Traumatol Arthrosc* 2014;**22**:730–36.
- Lee S, Wuerz TH, Shewman E *et al.* Labral reconstruction with iliotibial band autografts and semitendinosus allografts improves hip joint contact area and contact pressure: an in vitro analysis. *Am J Sports Med* 2015;**43**:98–104.
- Storaci HW, Utsunomiya H, Kemler BR *et al.* The hip suction seal, Part I: the role of acetabular labral height on hip distractive stability. *Am J Sports Med* 2020;**48**:2726–32.
- White BJ, Patterson J, Herzog MM. Bilateral hip arthroscopy: direct comparison of primary acetabular labral repair and primary acetabular labral reconstruction. *Arthroscopy* 2018;**34**:433–40.
- White BJ, Stapleford AB, Hawkes TK *et al.* Allograft use in arthroscopic labral reconstruction of the hip with front-to-back fixation technique: minimum 2-year follow-up. *Arthroscopy* 2016;**32**:26–32.
- Dwyer MK, Jones HL, Field RE *et al.* Femoroacetabular impingement negates the acetabular labral seal during pivoting maneuvers but not gait. *Clin Orthop Relat Res* 2015;**473**:602–07.
- Dwyer MK, Jones HL, Hogan MG *et al.* The acetabular labrum regulates fluid circulation of the hip joint during functional activities. *Am J Sports Med* 2014;**42**:812–19.
- Rahl MD, LaPorte C, Steidl GK *et al.* Outcomes after arthroscopic hip labral reconstruction: a systematic review and meta-analysis. *Am J Sports Med* 2020;**48**:1748–55.
- Bessa FS, Williams BT, Polce EM *et al.* Indications and outcomes for arthroscopic hip labral reconstruction with autografts: a systematic review. *Front Surg* 2020;**7**:61.
- Maldonado DR, Kyin C, Chen SL *et al.* In search of labral restoration function with hip arthroplasty: outcomes of hip labral reconstruction versus labral repair: a systematic review. *Hip Int* 2021;**31**:704–13.
- Safran N, Rath E, Haviv B *et al.* The efficacy of labral reconstruction: a systematic review. *Orthop J Sports Med* 2021;**9**:2325967120977088.
- Trivedi NN, Sivasundaram L, Su CA *et al.* Indications and outcomes of arthroscopic labral reconstruction of the hip: a systematic review. *Arthroscopy* 2019;**35**:2175–86.

22. Al Mana L, Coughlin RP, Desai V *et al*. The hip labrum reconstruction: indications and outcomes-an updated systematic review. *Curr Rev Musculoskelet Med* 2019;**12**:156–65.
23. White BJ, Herzog MM. Labral reconstruction: when to perform and how. *Front Surg* 2015;**2**:27.
24. White BJ, Herzog MM. Arthroscopic labral reconstruction of the hip using iliotibial band allograft and front-to-back fixation technique. *Arthrosc Tech* 2016;**5**:e89–97.
25. White BJ, Patterson J, Herzog MM. Revision arthroscopic acetabular labral treatment: repair or reconstruct? *Arthroscopy* 2016;**32**:2513–20.
26. Levy DM, Kuhns BD, Chahal J *et al*. Hip arthroscopy outcomes with respect to patient acceptable symptomatic state and minimal clinically important difference. *Arthroscopy* 2016;**32**:1877–86.
27. Chahal J, Van Thiel GS, Mather RC 3rd *et al*. The patient acceptable symptomatic state for the modified Harris Hip Score and Hip Outcome Score among patients undergoing surgical treatment for femoroacetabular impingement. *Am J Sports Med* 2015;**43**:1844–49.
28. Ellis PD. *The Essential Guide to Effect Sizes: Statistical Power, Meta-analysis, and the Interpretation of Research Results*. Cambridge, UK: Cambridge University Press, 2010.
29. Field A. *Discovering Statistics Using IBM SPSS Statistics*. University of Sussex, UK: Sage, 2018.
30. Rai SK, Yazdany J, Fortin PR *et al*. Approaches for estimating minimal clinically important differences in systemic lupus erythematosus. *Arthritis Res Ther* 2015;**17**:143.
31. Newman D, Newman I, Salzman J. Comparing OLS and HLM models and the questions they answer: potential concerns for type VI errors. *Multiple Linear Regression Viewpoints* 2010;**36**:1–8.
32. Mishra B, Sudheer P, Agarwal A *et al*. Minimal clinically important difference (MCID) in patient-reported outcome measures for neurological conditions: review of concept and methods. *Ann Indian Acad Neurol* 2023;**26**:334–43.
33. Sedaghat AR. Understanding the minimal clinically important difference (MCID) of patient-reported outcomes measures. *J Otolaryngol Head Neck Surg* 2019;**161**:551–60.
34. Copay AG, Subach BR, Glassman SD *et al*. Understanding the minimum clinically important difference: a review of concepts and methods. *Spine J* 2007;**7**:541–46.
35. Tashjian RZ, Deloach J, Green A *et al*. Minimal clinically important differences in ASES and simple shoulder test scores after non-operative treatment of rotator cuff disease. *J Bone Joint Surg Am* 2010;**92**:296–303.
36. Tashjian R. Editorial commentary: the alphabet soup of understanding clinical shoulder research: MCID (minimal clinically important difference), PASS (patient acceptable symptomatic state), SCB (substantial clinical benefit), and now... MOI (maximal outcome improvement). *Arthroscopy* 2020;**36**:1811–12.
37. Nwachukwu BU, Fields K, Chang B *et al*. Preoperative outcome scores are predictive of achieving the minimal clinically important difference after arthroscopic treatment of femoroacetabular impingement. *Am J Sports Med* 2017;**45**:612–19.