

# Stock Versus CAD/CAM Customized Zirconia Implant Abutments – Clinical and Patient-Based Outcomes in a Randomized Controlled Clinical Trial

Ulf Schepke, DDS;\* Henny J.A. Meijer, DDS, PhD;<sup>†,‡</sup> Wouter Kerdiijk, PhD;<sup>§</sup>  
Gerry M. Raghoobar, MD, PhD;<sup>‡</sup> Marco Cune, DDS, PhD<sup>†,¶</sup>

---

## ABSTRACT

*Background:* Single-tooth replacement often requires a prefabricated dental implant and a customized crown. The benefits of individualization of the abutment remain unclear.

*Purpose:* This randomized controlled clinical trial aims to study potential benefits of individualization of zirconia implant abutments with respect to preservation of marginal bone level and several clinical and patient-based outcome measures.

*Material and Methods:* Fifty participants with a missing premolar were included and randomly assigned to standard (ZirDesign, DentsplySirona Implants, Mölndal, Sweden) or computer aided design/computer aided manufacturing (CAD/CAM) customized (Atlantis, DentsplySirona Implants, Mölndal, Sweden) zirconia abutment therapy. Peri-implant bone level (primary outcome), Plaque-index, calculus formation, bleeding on probing, gingiva index, probing pocket depth, recession, appearance of soft tissues and patients' contentment were assessed shortly after placement and one year later.

*Results:* No implants were lost and no complications related to the abutments were observed. Statistically significant differences between stock and CAD/CAM customized zirconia abutments could not be demonstrated for any of the operationalized variables.

*Conclusion:* The use of a CAD/CAM customized zirconia abutment in single tooth replacement of a premolar is not associated with an improvement in clinical performance or patients' contentment when compared to the use of a stock zirconia abutment.

**KEY WORDS:** abutments, computer aided design/computer aided manufacturing technology, clinical study, marginal bone loss, patient satisfaction, randomized controlled trial, zirconia

---

---

\*Associate professor, Department of Fixed and Removable Prosthodontics and Biomaterials, Center for Dentistry and Oral Hygiene, University Medical Center Groningen, University of Groningen, Groningen, The Netherlands; <sup>†</sup>Professor, Department of Fixed and Removable Prosthodontics and Biomaterials, Center for Dentistry and Oral Hygiene, University Medical Center Groningen, University of Groningen, Groningen, The Netherlands; <sup>‡</sup>Professor, Department of Oral and Maxillofacial Surgery, University Medical Center Groningen, University of Groningen, Groningen, The Netherlands; <sup>§</sup>Associate professor, Department of Public and Individual Oral Health, Center for Dentistry and Oral Hygiene, University Medical Center Groningen, University of Groningen, Groningen, the Netherlands; <sup>¶</sup>Department of Oral-Maxillofacial Surgery, Prosthodontics and Special Dental Care, St. Antonius Hospital, Nieuwegein, The Netherlands

Corresponding Author: Dr. med. dent. Ulf Schepke, Center for Dentistry and Oral Hygiene, Department of Fixed and Removable Prosthodontics and Biomaterials, UMC Groningen, University of Groningen, A. Deusinglaan 1, 9713 AV Groningen, the Netherlands; e-mail: u.schepke@umcg.nl

© 2016 The Authors. Clinical Implant Dentistry and Related Research Published by Wiley Periodicals, Inc.

This is an open access article under the terms of the Creative Commons Attribution NonCommercial License, which permits use, distribution and reproduction in any medium, provided the original work is properly cited and is not used for commercial purposes.

DOI 10.1111/cid.12440

## INTRODUCTION

The design and stability of the implant-abutment connection as well as the chemical composition and surface properties of the abutment ground material, influence the function of implant-supported restorations, and the adjacent soft tissue health and soft tissue stability. Platform-switched implant-abutment connections maintain better marginal bone levels than matching ones, as is confirmed in several systematic reviews, meta-analyses and clinical trials.<sup>1–5</sup> Zirconia has aesthetic benefits over titanium in situations presenting with thin overlying mucosa, but biological superiority is generally not observed.<sup>6–11</sup> Besides chemical composition, surface topography and surface-free-energy are relevant factors, with surface roughness being the predominant factor with respect to biofilm formation.<sup>12</sup> The ideal abutment surface is smooth enough to inhibit biofilm formation, yet rough enough to allow adhesion of fibroblasts. An optimal surface roughness threshold of R(a) 0.2 micron has been proposed.<sup>13</sup>

Abutment shape could be another influential factor. In general, the stability of labial mucosal margin and fill of the interproximal area are the outcome parameters studied. Stock abutments are cylindrical or divergent at most, which is clearly different from the emergence profile of natural teeth, hence providing compromised support to the proximal and labial peri-implant soft tissues. Rompen and colleagues experimented with a stock, gingivally converging abutment design, which resulted in the formation of extra soft tissues,<sup>14</sup> but his findings could not be confirmed by others.<sup>15–19</sup>

Implant abutments can also be produced by means of Computer Aided Design/Computer Aided Manufacturing (CAD/CAM) technology. Variations are infinite, fitting individual and local circumstances, which offers several advantages. The CAD/CAM process optimally controls the geometry of the abutment including the position of the outline in accordance with the neighboring natural roots and the gingival margin, subsequently reducing the risk on cement remnants deep in the sulcus. The finish of the abutment is controlled, preventing sharp edges and the design can compensate for poor implant angulation. In case of a customized abutment, it is the abutment material that supports and interacts with the soft

tissues and not so much the ceramic crown. This is of biological advantage.<sup>20,21</sup> However, the industrial production process best guarantees standard quality of the product. It facilitates the use of biocompatible materials in the perimucosal area and reduces the risk of corrosive problems from different alloys in casted and milled parts. Finally, it is less time consuming and does not require extra finishing procedures. This raises the question whether there is a difference in performance between stock and individualized abutments.

The aim of the present study is to evaluate whether the use of stock (treatment modality (a) and CAD/CAM customized (treatment modality (b) zirconia abutments results in differences regarding peri-implant bone level alteration (primary objective), clinical performance and fulfilment of patients' expectations.

## MATERIALS AND METHODS

A single-center, randomized controlled clinical trial was designed, for 50 participants, missing a single mandibular or maxillary premolar. Patients were recruited during a 13-month inclusion period (January 2013–February 2014). In- and exclusion criteria are listed in Table 1. Permission from the medical ethics committee of the University Medical Center Groningen, the Netherlands was granted (METc number 2012.388, ABR number NL 42288.042.12) and informed consent was obtained. Primary outcome measure was peri-implant bone level alteration after 1 year of function; clinical relevance was set at >0.25 mm difference and a 0.3 mm standard deviation was estimated.<sup>23</sup> A power calculation was performed using G\*Power<sup>24</sup> (Version 3.1.9.2) and revealed that 24 patients in each group would be needed (80% power, normal distribution, 2 tailed).

### Implant Placement

One-hour pre-operative antibiotic prophylaxis (3 g amoxicillin or, if allergic to penicillin, 600 mg clindamycin, intraorally) was given. Oral disinfection consisted of a 0.2% chlorhexidine mouthwash, twice daily started one day before surgery and ending 10 days later. All surgeries were performed under local anaesthesia.

A full-thickness muco-periosteal flap was raised and the implant site was prepared following the

**TABLE 1 Inclusion and Exclusion Criteria****-Inclusion Criteria**

Missing first or second premolar in the maxilla or mandible  
 Wish to replace the missing premolar with an implant  
 Willing to sign for informed consent  
 Bone height  $\geq 10$  mm beneath the maxillary sinus and  $\geq 10$  mm above the mandibular nerve and a bone width of at least 6 mm

**-Exclusion criteria**

Missing teeth mesial or distal from implantation site  
 Orthodontic treatment at the time of impression taking  
 Severe bruxism  
 Acute periodontitis  
 History of implant loss  
 Documented extreme gagging reflex  
 Poor medical condition (ASA\* score 3 or higher)  
 Previous therapeutic radiation of the head–neck region  
 Chronic pain in orofacial system  
 Younger than 18 years at time of inclusion  
 Reduced mental capacity

\*American Society of Anesthesiologists.

protocol of the manufacturers. The implant was placed (AstraTech OsseoSpeed TX 3.5S in 9, 11, or 13 mm in length and a diameter of 3.5 mm; DentsplySirona Implants, Mölndal, Sweden). Maximum torque used during implant installation was set according to Astra tech Implant System surgical manual and primary implant stability was estimated manually. The corresponding healing abutment was immediately connected onto the implant. The wound was closed with slowly resorbable sutures (Vincryl & Johnson Health Care, Piscataway, NJ, USA).

### Restorative Procedures

Restorative treatment commenced 3 months later. An analogue impression with a polyether material (Impregum, 3M ESPE, Seefeld, Germany) in an open, semi-individual impression tray (Border-Lock, Clan Dental, Maarheeze, the Netherlands) was made by a single, experienced operator (US).

### Fabrication and Provision of the Implant Restoration

A screw-retained implant restoration was provided 3 weeks after impression taking, consisting of a digitally

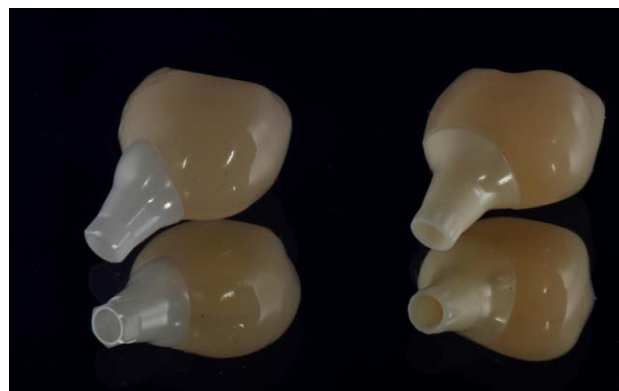designed and milled Resin Nano Ceramic crown (RNC crown, Lava Ultimate, 3M ESPE, Seefeld, Germany), bonded to either a stock (ZirDesign, DentsplySirona Implants Mölndal, Sweden,  $n = 25$ ) or a CAD/CAM customized zirconia abutment (Atlantis, DentsplySirona Implants Mölndal, Sweden,  $n = 25$ ).

The abutment type (Figure 1) was randomly allocated to each of the 50 participants ([www.sealedenvelope.com](http://www.sealedenvelope.com)) and patients were assigned to the treatment modality accordingly by US, who also took care of the enrolment of the patients.

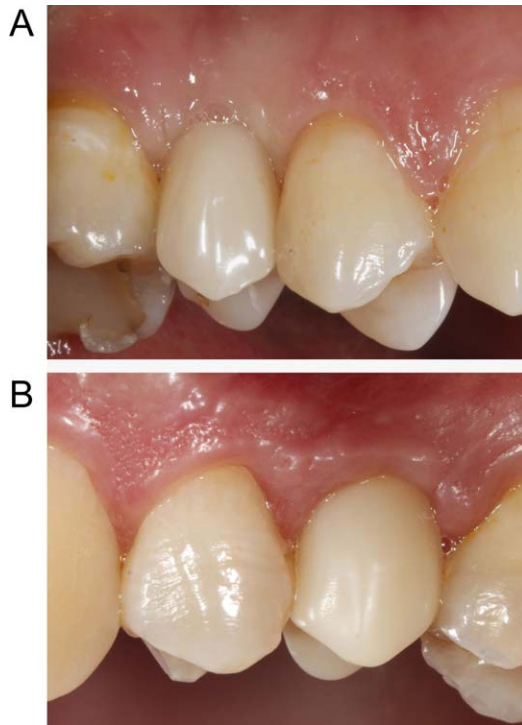
The most appropriate color for the RNC crown was chosen from the available Lava Ultimate shades. The RNC crown was luted extra-orally to the zirconia abutments following the manufacturers' instructions.<sup>25</sup> Blinding of the operator was not possible, due to visual differences between the stock and CAD/CAM customized zirconia abutments. Ground material for both abutment types was yttria-stabilized tetragonal zirconia polycrystal (Y-TZP).

After verification of adequate fit and proximal contact points the abutment fixation screw was tightened, using a wrench at the recommended torque (20 Ncm). The abutment fixation screw was protected by sterile teflon tape and the screw access hole was sealed with a glass ionomer restorative material (Fuji II, GC Europe, Leuven, Belgium). Static and dynamic occlusion were checked meticulously and oral hygiene instruction was given.

All patients with complications were seen as soon as possible. If the abutments remained unaffected, patients were not excluded from the study. During reparation, exact copies of the Crown-Abutment complex were used, so the emerging profile was left unbiased. These were generated from the same CAD file and



**Figure 1** RNC crown bonded to (left) Stock (ZirDesign) and (right) CAD/CAM customized (Atlantis) abutment, both manufactured by DentsplySirona Implants, Mölndal, Sweden.



**Figure 2** (A) Stock zirconia abutment (ZirDesign, Dentsply-Sirona Implants, Sweden) with resin nanoceramic crown (3M ESPE, Germany) at position 15 after 1 year of function. (B) CAD-CAM customized zirconia abutment (Atlantis, Dentsply-Sirona, Sweden) with resin nanoceramic crown (3M ESPE, Germany) at position 25 after 1 year of function.

available for reasons not related to the present study. After 12 months of clinical service, the patients were examined for data acquisition (Figure 2).

### Immediate and Follow Up Clinical Outcome Parameters

After the intake ( $T_0$ ) and implant placement, follow-up appointments were planned at two weeks ( $T_1$ ) and 12 months ( $T_{12}$ ) after delivery of the restoration at which time clinical outcome parameters were assessed around the implant and both neighboring teeth of the implant site using the following parameters:

- Plaque accumulation was measured with the modified plaque index,<sup>26</sup> score range 0–3 on the neighboring teeth and the implant abutment;
- Absence or presence (0/1) of dental calculus was assessed on the neighboring teeth and the implant;
- Probing pocket depth (PPD) was quantified with a plastic periodontal probe. 0.25 Newton of calibrated probing force was applied (Click-probe, KerrHawe, Bioggio, Switzerland) to measure PPD

to the nearest mm from the mucosal margin to the clinical pocket. The neighboring teeth as well as the implant site were measured on three locations (i.e., mesiobuccal, mediobuccal and distobuccal);

- The bleeding tendency of the neighboring teeth and the implant was recorded with the modified sulcus bleeding index,<sup>26</sup> score range 0–3);
- Peri-implant inflammation was assessed with the gingiva-index,<sup>27</sup> score range 0–3).

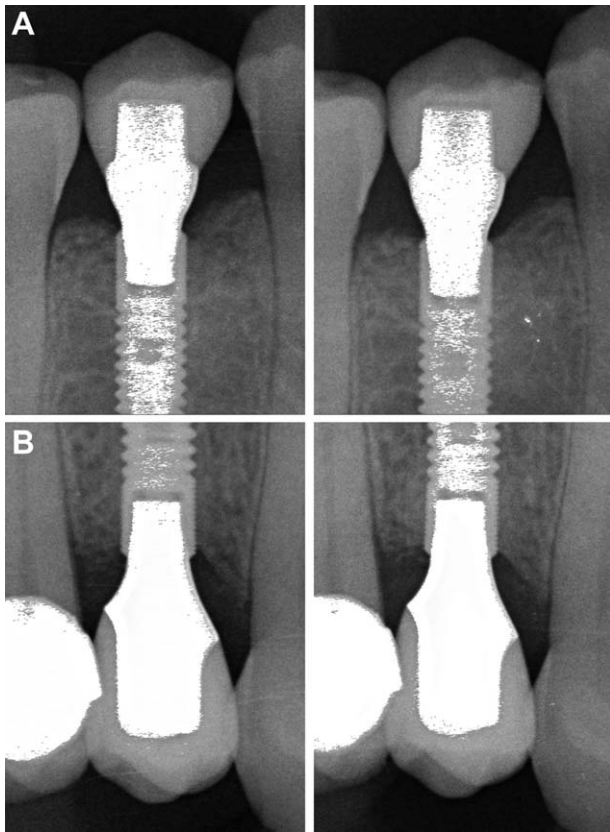
All clinical parameters were assessed at  $T_1$  and  $T_{12}$ .

### Bone Level, Approximal Gingival Margin and Soft Tissue Appearance and Development

Peri-implant bone level was measured on two radiographs ( $T_1$  and  $T_{12}$ ), taken with individually designed x-ray trays to ensure the same projection of objects on the radiograph (Figure 3). At least, two known vertical reference points on the implant had to be visible on each of the radiographs of a set. If this was not the case, but the quality of the radiographs was still sufficient for regular clinical care, no new radiograph was made for the sole purpose of this study, in accordance with the ALARA principle. These patients' radiographs were excluded from the study. Designated software (DicomWorks, Biomedical Engineering, University Medical Center Groningen, the Netherlands) was used to measure the distance from a reference point to the marginal bone, as described in detail by others.<sup>28</sup> Two researchers (US and ES) were simultaneously introduced to the software and analyzed the radiographs independently. To establish interobserver reliability, a two-way mixed average measures intra-class correlation coefficient (ICC) for consistency was calculated. Bone level alterations and recession were determined by subtracting the (pooled) values  $T_1$  from  $T_{12}$  ( $T_{12} - T_1$ ) with a negative value indicating growth.

Alteration of approximal gingival margin on both neighboring teeth was clinically measured to the nearest millimeter from a fixed reference point to the mucosal margin at  $T_1$  and  $T_{12}$ .

The appearance of the soft tissues was determined on randomly presented digital photographs made at  $T_1$  and  $T_{12}$  by assessing the Pink Esthetic Score (PES), as proposed by Fürhauser and colleagues.<sup>29</sup>



**Figure 3** (A) Radiograph of a Stock zirconia abutment (Zir-Design, DentsplySirona Implants, Sweden) with resin nanoceramic crown (3M ESPE, Germany) at baseline (*left*) and after one year of clinical service (*right*) at position 45. (B) Radiograph of a CAD-CAM customized zirconia abutment (Atlantis, DentsplySirona, Sweden) with resin nanoceramic crown (3M ESPE, Germany) at baseline (*left*) and after one year of clinical service (*right*) at position 15.

Seven items were scored: mesial papilla, distal papilla, soft-tissue level, soft tissue contour, alveolar process deficiency, soft-tissue color and texture. All items were assessed on a 2-1-0 score, with 2 being the best and 0 being the poorest score. A sum-score was calculated as an impression of soft tissue appearance and development (range 0–14). Marginal bone level, recession and soft tissue appearance were compared both longitudinally (between  $T_1$  and  $T_{12}$ ) and between groups at both moments in time.

### Patient-Based Outcome Parameters

The participants responded to 12 statements regarding their expected emotional, functional and aesthetic contentment with the restoration ( $T_0$ ) and the perceived contentment at 2 weeks ( $T_1$ ) and 12 months following delivery of the restoration ( $T_{12}$ ). A questionnaire using a visual analogue scale (VAS) adapted

from Guljé and colleagues, ranging from 0 to 100 (very discontent, major concerns to very content, no concerns at all) was used.<sup>28</sup> Expectations at  $T_0$  and the perceived subjective result at  $T_1$  and  $T_{12}$  were compared (Figure 4).

### Statistical Analysis

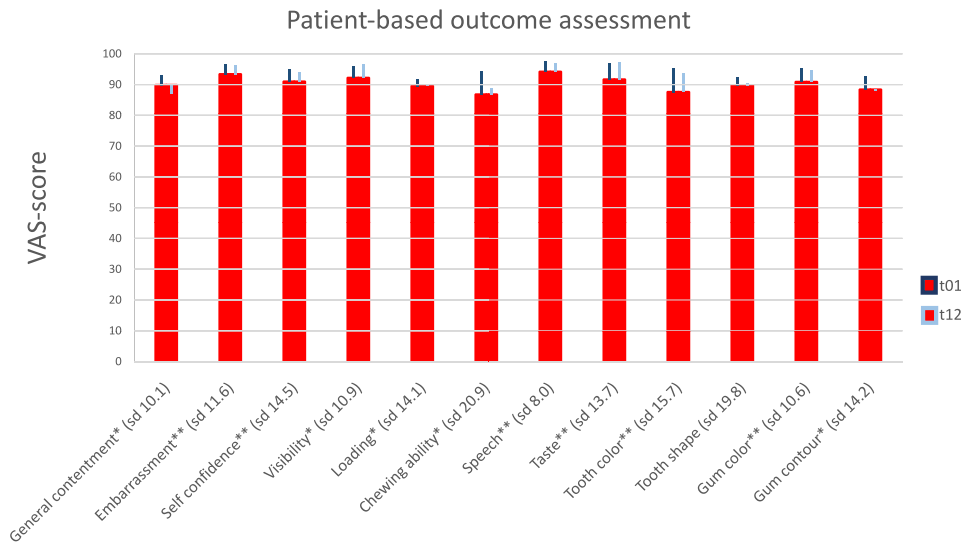
Statistical analysis was performed while blinded with respect to the group a patient was allocated to. Marginal bone level alteration and gingival growth at  $T_{12}$  was compared across abutment types using a Mann-Whitney  $U$  test, because normality was not observed (using a Kolmogorov-Smirnov test). Plaque accumulation, dental calculus, PPD, bleeding tendency and gingiva-index of both abutment types were compared at time point  $T_1$  and  $T_{12}$  with Mann-Whitney  $U$  tests. Alterations over time were assessed with Wilcoxon signed rank test. The change in overall PES score and scores per item were analyzed per group using a Wilcoxon signed rank test. Changes over time in soft tissue appearance were compared across groups using a Mann-Whitney  $U$  test.

Patients' expectations ( $T_0$ ) and the perceived subjective result at  $T_1$  and  $T_{12}$  were compared across groups using Mann-Whitney  $U$  tests. Differences across time were analyzed using Wilcoxon signed rank tests.  $p$ -values  $\leq .05$  were considered statistically significant. All computations were performed using a standard statistical program (SPSS, version 23.0 for Windows, SPSS inc., Chicago, USA).

### RESULTS

From the 50 eligible participants (Table 2), all participants were examined at  $T_1$  and  $T_{12}$ , but 7 patients had to be excluded from the radiographic analysis (primary outcome), because one of their radiographs made at  $T_1$  or  $T_{12}$  were deemed unfit for reliable comparison. One pregnant participant refused to have a radiograph taken at  $T_{12}$  (Figure 5).

No implants were lost and no complications related to the zirconia abutments (fracture or screw loosening) were noted in either group. Mean values for the clinical and subjective outcome parameters are presented in Tables 3 and 4 and Figure 4. Tissues were generally healthy, patients were satisfied with the result on all aspects of evaluation and expectations regarding the outcome of treatment were met or exceeded. No statistically significant differences could



**Figure 4** Mean VAS-scores of several expected ( $t_0$ ) and achieved ( $t_1$  and  $t_{12}$ ) aspects of patient satisfaction for zirconia abutments (Stock and customized CAD/CAM abutments grouped) provided with RNC crowns.  $T_0$  (red bar) is assessed prior to treatment (standard deviation between brackets),  $t_1$  at 2 weeks after placement of the implant crown and  $t_{12}$  after 12 months of function. Values range from 0 (very discontent, major concerns) to 100 (fully content, no concerns at all). Note that positive values at  $t_1$  and  $t_{12}$  compared to  $t_0$  (dark blue and light blue bars) imply that expectations were exceeded. \* Statistically significantly different from  $T_0$  at  $T_1$   $p < .05$ . \*\* Statistically significantly different from  $T_0$  at  $T_1$  and  $T_{12}$   $p < .05$ .

be demonstrated between the two groups, neither related to the implant restoration, nor related to the neighboring teeth.

For the alterations of the radiographically determined marginal bone levels, the measured ICC was 0.910 indicating excellent reliability between the observers. On average, some marginal bone apposition was observed for both groups between  $T_1$  and  $T_{12}$  (Table 3). The difference in bone apposition between the 2 groups (stock: 0.06 mm, 95% CI

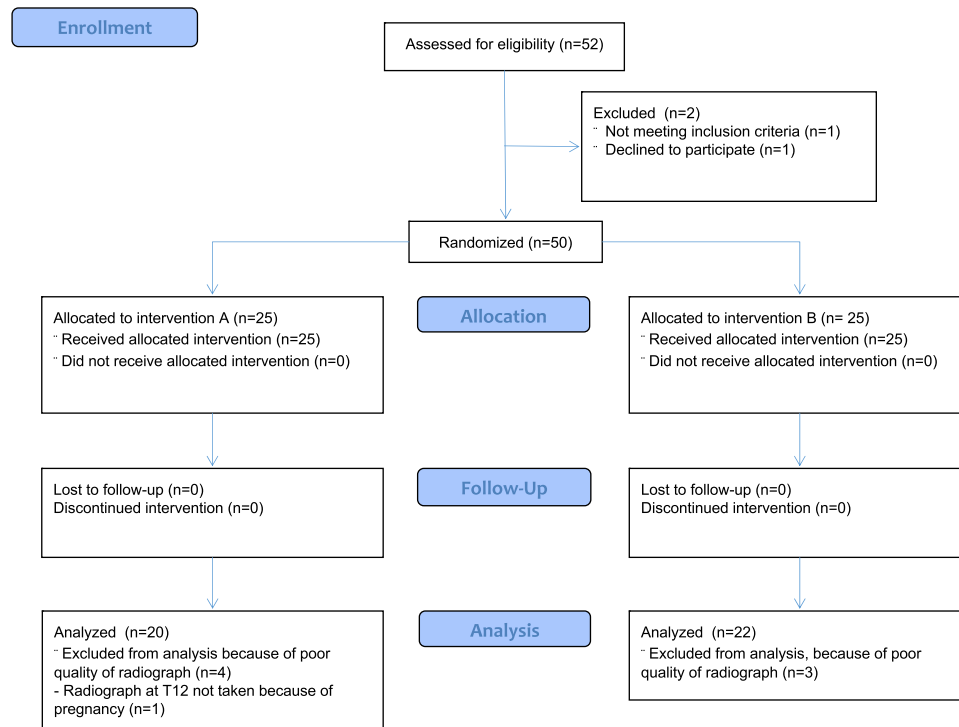
[-0.05 mm; 0.16 mm], standard deviation 0.23mm versus CAD/CAM customized: 0.11 mm, 95% CI [0.02 mm; 0.20 mm]; standard deviation 0.20 mm) was not statistically significant.

Clinical examination revealed a significant ( $T = 24$ ;  $p < .05$ ) coronal growth of approximal gingival margin (0.32 mm; 95% CI [0.06 mm; 0.58mm]; SD 0.88 mm) on the neighboring teeth after 12 months. There was no statistically significant difference between stock (0.24 mm; 95% CI [-0.09 mm; 0.57 mm]; SD 0.77 mm) and CAD/CAM customized abutments (0.40 mm; 95% CI [-0.01 mm; 0.81 mm] SD 0.99 mm, Table 3). Interobserver reliability was good regarding soft tissue margin and soft tissue color (ICC > 0.6) and excellent for all other PES items (ICC > 0.75). In general, the soft tissue appearance had improved after 12 months ( $T = 43$ ,  $p < .001$ ), predominantly because of papilla fill in the mesial and distal proximal areas ( $p < .001$ ), soft tissue contour and texture ( $p < .01$ ; Table 4). There were no significant differences between stock and CAD/CAM customized abutments on individual variables of the PES, as well as for the sum-score at either moment in time.

Differences between groups and over time with regard to plaque accumulation, dental calculus, PPD, bleeding tendency and gingiva-index were generally small and none of them was statistically significant (Table 3).

TABLE 2 Basic Demographic and Clinical Data of the Research Population			
	Stock	Customized	Total
Gender			
Male	6	11	17
Female	19	14	33
Age*			
Mean	48.6	48.1	48,3
Min	18	30	
Max	79	71	
Tooth			
Upper 1st premolar	9	6	15
Upper 2nd premolar	11	15	26
Lower 1st premolar	1	1	2
Lower 2nd premolar	4	3	7

\*At the time of the placement of the restoration.



**Figure 5** Consort flow diagram for primary outcome variable: peri-implant bone level alteration. Treatment consisted of RNC crowns extraorally bonded to (A) stock or (B) CAD/CAM customized zirconia abutments.

Patients were generally content with the achieved result as reflected by high VAS-scores at  $T_1$  and  $T_{12}$  (Figure 4), without a statistically significant difference between the stock and CAD/CAM customized abutments. Expectations were mostly exceeded and general contentment was higher at  $T_1$  than patients had expected ( $T=29$ ;  $p<.01$ ) ( $T_0$ ) but not at  $T_{12}$  ( $T=19$ ;  $p=.9$ ). A similar pattern for chewing ability, confidence in loading the implant and patients' appreciation of the gum contour was found. Patients experienced significantly less embarrassment and problems with taste, speech, gum color

and the visibility of the implant at  $T_1$  ( $p<.01$ ) and  $T_{12}$  ( $p<.05$ ) than they had expected at  $T_0$ . Self-confidence was also boosted more at both  $T_1$  and  $T_{12}$  than patients expected. No differences were found between patients' perceptions and their initial expectations with regard to tooth shape.

## DISCUSSION

Studies comparing stock and CAD/CAM customized abutments are rare. Marginal bone level alteration after one year of clinical service was the primary

**TABLE 3** Clinical Outcome Measures Two Weeks After Delivery of the Restoration ( $T_1$ ) and After 12 Months ( $T_{12}$ ), Standard Deviations Between Brackets

	$T_1$		$T_{12}$	
	Stock	Customized	Stock	Customized
Plaque-index (0–3, median)	0 (0.51)	0 (0.49)	1 (0.57)	1 (0.40)
Calculus-score (0–1, median)	0 (0.00)	0 (0.00)	0 (0.00)	0 (0.00)
Probing pocket depth (in mm, mean)	2.11 (0.60)	2.12 (0.79)	2.32 (0.85)	2.44 (0.78)
Bleeding on probing (0–3, median)	0 (0.41)	0 (0.41)	0 (0.56)	0 (0.58)
Gingiva-index (0–3, median)	0 (0.20)	0 (0.00)	0 (0.41)	0 (0.54)
Gingival margin apposition at the adjacent teeth (in mm, mean)			0.24 (0.77)	0.40 (0.99)
Marginal bone level apposition (in mm, mean)			0.06 (0.23)	0.11 (0.20)

**TABLE 4 Pink Esthetic Score (PES) Based on Photographs Taken Two Weeks After Delivery of the Restoration ( $T_1$ ) and After 12 Months ( $T_{12}$ ), Standard Deviations Between Brackets**

	$T_1$		$T_{12}$	
	Stock	Customized	Stock	Customized
PES (sum-score, 0–14)*	9.2 (1.8)	9.0 (2.5)	10.9 (1.6)	10.6 (2.1)
Papilla mesial*	1.0 (0.6)	1.0 (0.8)	1.6 (0.6)	1.7 (0.5)
Papilla distal*	1.0 (0.7)	1.0 (0.8)	1.3 (0.8)	1.3 (0.7)
Level of the soft tissue margin	1.4 (0.5)	1.5 (0.6)	1.6 (0.5)	1.6 (0.7)
Soft tissue contour**	1.2 (0.4)	1.2 (0.4)	1.5 (0.5)	1.5 (0.6)
Alveolar process deficiency	1.3 (0.5)	1.4 (0.7)	1.3 (0.5)	1.4 (0.6)
Soft tissue color	1.8 (0.4)	1.5 (0.5)	1.8 (0.4)	1.6 (0.5)
Soft tissue texture**	1.5 (0.5)	1.4 (0.5)	1.8 (0.4)	1.5 (0.6)

Statistical significant improvement between  $T_1$  and  $T_{12}$  ( $p < .001$ )\* ( $p < .01$ )\*\*, but not between the groups.

outcome measure of the present study. Some bone apposition was observed (0.06–0.11 mm), whereas according to a recent review, marginal bone resorption ranges on average from 0 to 0.99 mm after one year of function.<sup>5</sup> In this review, two of the included studies show very little marginal bone resorption after one year of service (Hürzeler and colleagues<sup>30</sup> 0.12 mm, SD 0.40 mm,  $n = 14$ ; Prosper and colleagues<sup>31</sup> 0.02 mm, SD 0.11 mm,  $n = 60$ ), so it can be assumed that at least some individuals in those studies showed bone gain instead of bone resorption.

A third study by Guljé and colleagues with the same implant type also found a small amount of bone apposition after one year.<sup>23</sup> Therefore, measuring “bone level alteration” seems to be a more suitable terminology than measuring “bone resorption.”

From in vitro studies it was concluded that the specific stock and CAD/CAM customized abutments used, appeared to have a comparable fit for most of the systems evaluated,<sup>32,33</sup> as well as a comparable fracture strength.<sup>34</sup> Through individual design, retention and resistance of implant crowns is optimized. In a retrospective clinical study loosening of single crowns cemented with zinc oxide eugenol cement was seen more frequently after 2 years when stock abutments were used compared to customized computer-milled specimen.<sup>35</sup> Stronger cement might have prevented cement failure in clinical practice, but also the design of the abutment and the restoration material used seem play a role.<sup>25</sup>

Comparing customized zirconia and titanium abutments with metal cast abutments of an undisclosed alloy on the same implant type as used in the

present study led Borges and colleagues to conclude that papilla fill was enhanced in the customized abutment group after one year of function.<sup>36</sup> However, since the design of a cast-metal abutment allows the dental technician as much freedom of design as a CAD/CAM abutment, the choice of material or the inferior fit of a cast abutment,<sup>37</sup> and not so much the mode of manufacturing may have influenced the result. In a recent multicenter trial, stock and CAD/CAM designed titanium and zirconia abutments were compared with respect to labial recession of the mucosa after 2 years. Titanium CAD/CAM abutments performed better than all other combinations.<sup>38</sup> Since at the time of fabrication of the restoration zirconia was selected as abutment material in case of a labial mucosal thickness within 2 mm and titanium was selected as abutment material for situations with a labial mucosal thickness exceeding 2 mm, there was an obvious risk of selection bias.

Results from the present study with respect to the position of the labial margin provide similar results when looking at the data for zirconia stock and CAD/CAM customized abutments. No relevant differences were seen for this parameter. For patients, the level of the mucosal margin does not appear to be of particular importance with respect to their appreciation of the aesthetic result in the anterior region anyway, in contrast to the papilla fill, which is considered important.<sup>39</sup> In the present study, as also observed by others, papilla fill improved in time.<sup>40</sup> However, again no differences were seen between the two abutment types with regard to papilla fill or any of the other clinical, radiographical or patient-based outcome parameters. Small differences



between the two groups might have remained statistically undetected due to the limited number of patients, but given the small differences observed, it is not likely that these will be relevant to clinical practice.

Factors that have been reported to be of relevant influence on soft tissue development around implants are vertical implant position and bucco-palatal angulation, initial soft tissue thickness and soft tissue grafting procedures, as well as the proximal bone level of the neighboring teeth.<sup>22</sup>

Despite randomization, stock and customized abutments were not evenly distributed among men and women in our study, which is not likely to be of major influence on the results.

In general, patients were pleased with the achieved result. Their expectations were met or even exceeded, especially directly after placement of the restorations. We presume that a certain amount of euphoria might have increased the subjective contentment measurement shortly (two weeks) after the placement of the restoration rather than that the satisfaction decreased after one year of clinical service. A further drop in satisfaction might be possible, but does not appear to be very likely.

The quality of care from the patients' perspective is largely determined and reflected by the ability of the dental team to meet the patients' expectations. It enhances the reputation of the individual physicians involved, the team as a whole and the field in general and can be accomplished with both, customized or stock abutments.

No clinical or satisfaction factors favored one abutment over the other. As a consequence, the choice for a stock or a CAD/CAM customized zirconia implant abutment may just as well be based on secondary factors such as access to software, preference, ease of fabrication or price.

## CONCLUSIONS

The use of a CAD/CAM customized zirconia abutment in standard single tooth replacement of a premolar is not associated with a relevant improvement in outcome measures reflecting clinical performance, peri-implant bone alteration, contentment or the degree to which patients' expectations are met when compared to the use of a stock abutment.

## ACKNOWLEDGMENTS

The authors would like to thank dr. Wim Slot and Charlotte Jensen for performing the surgical intervention and Eva Selier for measuring the marginal bone levels. This study was supported by a grant from DentsplySirona Implants, Mölndal, Sweden and by the authors' institutions. Materials were provided by DentsplySirona Implants and 3M.

## REFERENCES

1. Chrcanovic BR, Albrektsson T, Wennerberg A. Platform switch and dental implants: a meta-analysis. *J Dent* 2015; 43:629–646.
2. Herekar M, Sethi M, Mulani S, Fernandes A, Kulkarni H. Influence of platform switching on periimplant bone loss: a systematic review and meta-analysis. *Implant Dent* 2014; 23:439–450.
3. Strietzel FP, Neumann K, Hertel M. Impact of platform switching on marginal peri-implant bone-level changes. A systematic review and meta-analysis. *Clin Oral Implants Res* 2015; 26:342–358.
4. Telleman G, Raghoobar GM, Vissink A, Meijer HJ. Impact of platform switching on peri-implant bone remodeling around short implants in the posterior region, 1-year results from a split-mouth clinical trial. *Clin Implant Dent Relat Res* 2014; 16:70–80.
5. Annibali S, Bignozzi I, Cristalli MP, Graziani F, La Monaca G, Polimeni A. Peri-implant marginal bone level: a systematic review and meta-analysis of studies comparing platform switching versus conventionally restored implants. *J Clin Periodontol* 2012; 39:1097–1113.
6. Sicilia A, Quirynen M, Fontollet A, et al. Long-term stability of peri-implant tissues after bone or soft tissue augmentation. Effect of zirconia or titanium abutments on peri-implant soft tissues. Summary and consensus statements. The 4th EAO consensus conference 2015. *Clin Oral Implants Res* 2015; 26(Suppl 11):148–152.
7. Linkevicius T, Vaitelis J. The effect of zirconia or titanium as abutment material on soft peri-implant tissues: a systematic review and meta-analysis. *Clin Oral Implants Res* 2015; 26(Suppl 11):139–147.
8. Zembic A, Bosch A, Jung RE, Hammerle CH, Sailer I. Five-year results of a randomized controlled clinical trial comparing zirconia and titanium abutments supporting single-implant crowns in canine and posterior regions. *Clin Oral Implants Res* 2013; 24:384–390.
9. Zembic A, Kim S, Zwahlen M, Kelly JR. Systematic review of the survival rate and incidence of biologic, technical, and esthetic complications of single implant abutments supporting fixed prostheses. *Int J Oral Maxillofac Implants* 2014; 29:99–116.

10. van Brakel R, Noordmans HJ, Frenken J, de Roode R, de Wit GC, Cune MS. The effect of zirconia and titanium implant abutments on light reflection of the supporting soft tissues. *Clin Oral Implants Res* 2011; 22:1172–1178.
11. van Brakel R, Meijer GJ, Verhoeven JW, Jansen J, de Putter C, Cune MS. Soft tissue response to zirconia and titanium implant abutments: an in vivo within-subject comparison. *J Clin Periodontol* 2012; 39:995–1001.
12. Teughels W, Van Assche N, Sliepen I, Quirynen M. Effect of material characteristics and/or surface topography on biofilm development. *Clin Oral Implants Res* 2006; 17 Suppl 2:68–81.
13. Quirynen M, Bollen CM. The influence of surface roughness and surface-free energy on supra- and subgingival plaque formation in man. A review of the literature. *J Clin Periodontol* 1995; 22:1–14.
14. Rompen E, Raepsaet N, Domken O, Touati B, Van Dooren E. Soft tissue stability at the facial aspect of gingivally converging abutments in the esthetic zone: a pilot clinical study. *J Prosthet Dent* 2007; 97:S119–S125.
15. Weinlander M, Lekovic V, Spadijer-Gostovic S, Milicic B, Wegscheider WA, Piehlslinger E. Soft tissue development around abutments with a circular macro-groove in healed sites of partially edentulous posterior maxillae and mandibles: a clinical pilot study. *Clin Oral Implants Res* 2011; 22: 743–752.
16. Patil R, van Brakel R, Iyer K, Huddleston Slater J, de Putter C, Cune M. A comparative study to evaluate the effect of two different abutment designs on soft tissue healing and stability of mucosal margins. *Clin Oral Implants Res* 2013; 24:336–341.
17. Patil RC, den Hartog L, van Heereveld C, Jagdale A, Dilbaghi A, Cune MS. Comparison of two different abutment designs on marginal bone loss and soft tissue development. *Int J Oral Maxillofac Implants* 2014; 29: 675–681.
18. Patil R, den Hartog L, Dilbaghi A, de Jong B, Kerdijk W, Cune MS. Papillary fill response in single-tooth implants using abutments of different geometry. *Clin Oral Implants Res* 2015. doi:10.1111/clr.12594. [Epub ahead of print].
19. Patil R, Gresnigt MM, Mahesh K, Dilbaghi A, Cune MS. Esthetic evaluation of anterior single-tooth implants with different abutment designs—patients' satisfaction compared to dentists' observations. *J Prosthodont* 2016. doi: 10.1111/jopr.12423. [Epub ahead of print].
20. Welander M, Abrahamsson I, Berglundh T. The mucosal barrier at implant abutments of different materials. *Clin Oral Implants Res* 2008; 19:635–641.
21. Abrahamsson I, Berglundh T, Glantz PO, Lindhe J. The mucosal attachment at different abutments. An experimental study in dogs. *J Clin Periodontol* 1998; 25: 721–727.
22. Le B, Nielsen B. Esthetic implant site development. *Oral Maxillofac Surg Clin North Am* 2015; 27:283–311.
23. Gulje F, Abrahamsson I, Chen S, Stanford C, Zadeh H, Palmer R. Implants of 6 mm vs. 11 mm lengths in the posterior maxilla and mandible: a 1-year multicenter randomized controlled trial. *Clin Oral Implants Res* 2013; 24:1325–1331.
24. Faul F, Erdfelder E, Lang AG, Buchner A. G\*Power 3: a flexible statistical power analysis program for the social, behavioral, and biomedical sciences. *Behav Res Methods* 2007; 39:175–191.
25. Schepke U, Meijer HJ, Vermeulen KM, Raghoobar GM, Cune MS. Clinical bonding of resin nano ceramic restorations to zirconia abutments: a case series within a randomized clinical trial. *Clin Implant Dent Relat Res* 2015. doi:10.1111/cid.12382. [Epub ahead of print].
26. Mombelli A, van Oosten MA, Schurch E Jr, Land NP. The microbiota associated with successful or failing osseointegrated titanium implants. *Oral Microbiol Immunol* 1987; 2:145–151.
27. Loe H, Silness J. Periodontal disease in pregnancy. I. Prevalence and severity. *Acta Odontol Scand* 1963; 21:533–551.
28. Gulje FL, Raghoobar GM, Vissink A, Meijer HJ. Single crowns in the resorbed posterior maxilla supported by either 6-mm implants or by 11-mm implants combined with sinus floor elevation surgery: a 1-year randomised controlled trial. *Eur J Oral Implantol* 2014; 7:247–255. Autumn;
29. Furhauer R, Florescu D, Benesch T, Haas R, Mailath G, Watzek G. Evaluation of soft tissue around single-tooth implant crowns: the pink esthetic score. *Clin Oral Implants Res* 2005; 16:639–644.
30. Hurzeler M, Fickl S, Zuhr O, Wachtel HC. Peri-implant bone level around implants with platform-switched abutments: preliminary data from a prospective study. *J Oral Maxillofac Surg* 2007; 65:33–39.
31. Prosper L, Redaelli S, Pasi M, Zarone F, Radaelli G, Gherlone EF. A randomized prospective multicenter trial evaluating the platform-switching technique for the prevention of postrestorative crestal bone loss. *Int J Oral Maxillofac Implants* 2009; 24:299–308.
32. Hamilton A, Judge RB, Palamara JE, Evans C. Evaluation of the fit of CAD/CAM abutments. *Int J Prosthodont* 2013; 26:370–380.
33. Apicella D, Veltri M, Chieffi N, Polimeni A, Giovannetti A, Ferrari M. Implant adaptation of stock abutments versus CAD/CAM abutments: a radiographic and scanning electron microscopy study. *Ann Stomatol (Roma)* 2010; 1:9–13.
34. Gehrke P, Johansson D, Fischer C, Stawarczyk B, Beuer F. In vitro fatigue and fracture resistance of one- and two-

- piece CAD/CAM zirconia implant abutments. *Int J Oral Maxillofac Implants* 2015; 30:546–554.
35. Korsch M, Walther W. Prefabricated versus customized abutments: a retrospective analysis of loosening of cement-retained fixed implant-supported reconstructions. *Int J Prosthodont* 2015; 28:522–526.
  36. Borges T, Lima T, Carvalho A, Dourado C, Carvalho V. The influence of customized abutments and custom metal abutments on the presence of the interproximal papilla at implants inserted in single-unit gaps: a 1-year prospective clinical study. *Clin Oral Implants Res* 2014; 25:1222–1227.
  37. de Franca DG, Morais MH, das Neves FD, Barbosa GA. Influence of CAD/CAM on the fit accuracy of implant-supported zirconia and cobalt-chromium fixed dental prostheses. *J Prosthet Dent* 2015; 113:22–28.
  38. Lops D, Bressan E, Parpaiola A, Sbricoli L, Cecchinato D, Romeo E. Soft tissues stability of cad-cam and stock abutments in anterior regions: 2-year prospective multicentric cohort study. *Clin Oral Implants Res* 2015; 26:1436–1442.
  39. Suphanantachat S, Thovanich K, Nisapakultorn K. The influence of peri-implant mucosal level on the satisfaction with anterior maxillary implants. *Clin Oral Implants Res* 2012; 23:1075–1081.
  40. Schropp L, Isidor F. Papilla dimension and soft tissue level after early vs. delayed placement of single-tooth implants: 10-year results from a randomized controlled clinical trial. *Clin Oral Implants Res* 2015; 26:278–286.