

Available online at www.sciencedirect.com

ScienceDirect

journal homepage: www.elsevier.com/locate/radcr

Case Report

Axial melorheostosis: A rare presentation ☆☆☆

Nikhil Bayya, BS^{a,*}, Anna Fairfax, BS^a, Courtney Dey, MD^a, Shawn Butela, MD^{a,b}, Frank Mihlon, MD^{a,b}^aDepartment of Radiology, Eastern Virginia Medical School, P.O. Box 1980, Norfolk, VA 23501, USA^bHampton Roads Radiology Associates, Norfolk, VA

ARTICLE INFO

Article history:

Received 17 August 2020

Revised 8 September 2020

Accepted 9 September 2020

Keywords:

Melorheostosis

Sclerosing bone dysplasia

Hyperostosis

Cervical radiculopathy

Sclerotic bone lesion

ABSTRACT

Melorheostosis is a rare sclerosing bone dysplasia that most commonly affects the lower extremity long bones in a sclerotomal distribution. Melorheostosis of the spine is a particularly rare manifestation of this disease. In the appendicular skeleton, melorheostosis has a pathognomonic imaging appearance of flowing hyperostosis resembling melted candle wax flowing down the margins of a candlestick. In the spine, it can have a variety of imaging manifestations from unilateral focal sclerotic lesions resembling enostoses, to more bulky and deformative hyperostosis that span and fuse multiple adjacent spinal segments. This combination of nonaggressive radiologic features makes melorheostosis a particularly important diagnosis for radiologists to understand so that they may spare their patients unnecessary biopsy. Here we present the clinical features and computed tomography findings in a 33-year-old male with spinal melorheostosis involving the first and second cervical vertebrae.

© 2020 The Authors. Published by Elsevier Inc. on behalf of University of Washington.

This is an open access article under the CC BY-NC-ND license

[\(http://creativecommons.org/licenses/by-nc-nd/4.0/\)](http://creativecommons.org/licenses/by-nc-nd/4.0/)

Introduction

Melorheostosis, eponymously named Leri disease, is a rare sclerosing bone dysplasia affecting cortical bone and surrounding soft tissues, with estimated prevalence of 1 case per 1 million people [1,2]. It is grouped with other rare skeletal disorders characterized by disruptions along the bone development pathway and may present alone or as an overlapping syndrome with features of other sclerosing bone dysplasias. The etiology of isolated melorheostosis remains

unknown, however when presenting with features of hereditary dysplasias such as osteopoikilosis and Buschke-Ollendorff syndrome, it is thought to be associated with mutations in the *LEMD3* gene. This gene normally encodes osteoblastic regulatory proteins including transcription growth factor beta (TGF-β) and bone morphogenic protein, the loss of which results in skeletal hyperostosis [2,4,6]. Melorheostosis has been classically described radiographically as having a “dripping candlewax” appearance due to its flowing hyperostosis that resembles hardened melted wax that has dripped down the side of a candle [3,4].

☆ Competing interests: None.

☆☆ Finding: None.

* Corresponding author.

E-mail address: bayyan@evms.edu (N. Bayya).<https://doi.org/10.1016/j.radcr.2020.09.028>1930-0433/© 2020 The Authors. Published by Elsevier Inc. on behalf of University of Washington. This is an open access article under the CC BY-NC-ND license (<http://creativecommons.org/licenses/by-nc-nd/4.0/>)

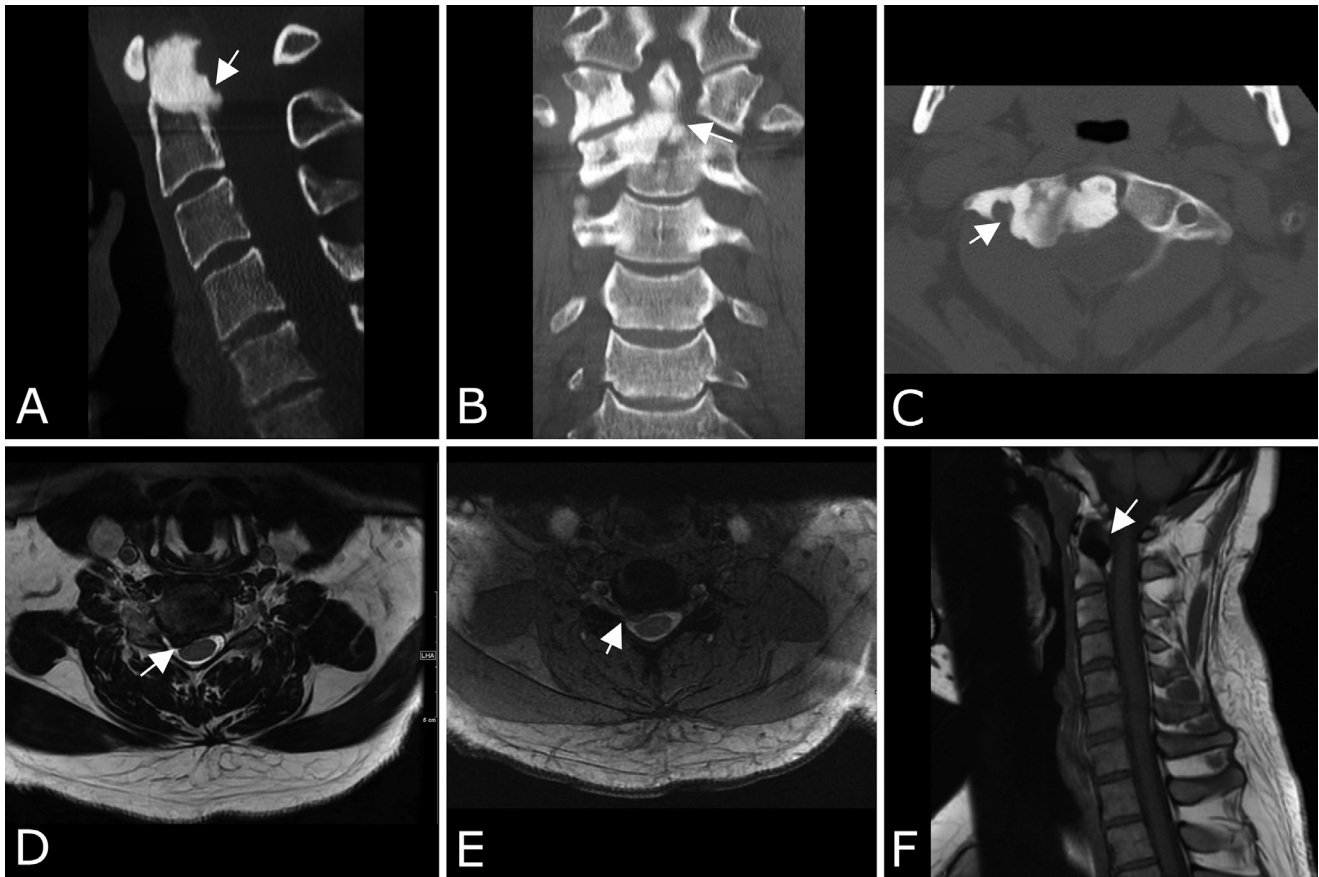


Fig. 1 – Computed tomography of the cervical spine obtained for initial evaluation of progressive neck pain with radiculopathy following a car accident. Sagittal (A), coronal (B), and axial (C) noncontrast CT images through the cervical spine demonstrate sclerotic lesions at C1 and C2 reminiscent of “dripping candle wax,” the characteristic finding in melorheostosis. The lesions are predominantly right-sided, and the sclerotomal unilaterality supports the diagnosis of melorheostosis. Magnetic resonance imaging of the cervical spine was subsequently obtained due to progression cervicalgia and right-sided cervical radiculopathy. Axial T2 SPACE (D) and axial T2-weighted MEDIC (E) images demonstrate a focal disk extrusion eccentric to the right at C5-C6 that impinges upon the right C6 nerve rootlets and indents the right ventral surface of the spinal cord. Sagittal T1-weighted imaging (F) shows the expected T1 hypointense signal of a sclerotic bone lesion in the odontoid process, and further demonstrates the hyperostotic expansion initially shown on CT.

Melorheostosis, which can be monostotic or polyostotic, tends to have a sclerotomal/myotomal distribution that is often unilateral and follows the distribution of a particular segmental spinal sensory nerve. This entity likely begins in early childhood, although patients generally present in young adulthood [1,2]. While many cases are discovered incidentally on imaging, clinical presentations may include pain overlying affected area, radiculopathy due to nerve impingement, skin changes, joint contractures, and limb length discrepancy [2,4,5]. In this case report, we discuss a 33-year-old male with neck pain related to a bulging disc at C5-C6 who had an incidental finding of spinal melorheostosis involving C1-C2 on computed tomography (CT) with pathognomonic imaging features on CT.

Case report

A 33-year-old male presented to the emergency department with 2 months of worsening neck pain and stiffness accompanied by intermittent tingling sensation of the bilateral upper extremities, most notably in the hands. Five months prior to presentation, he was in a motor vehicle accident with resultant “whiplash injury” neck pain. The patient was initially prescribed diclofenac 1% gel and referred to physical therapy, which resulted in only minimal relief of his symptoms. In the emergency department, the physical exam revealed no neurologic deficits. Laboratory values were within normal limits and a noncontrast-enhanced CT of the cervical spine was acquired.

On CT, a patchy sclerosing hyperostosis involving the base of the dens and the right lateral masses of C1 and C2 that resulted in fusion of the odontoid process with the right C1 lateral mass had associated ossific remodeling of the odontoid process reminiscent of “dripping candlewax,” and a diagnosis of spinal melorheostosis was made based upon the characteristic imaging features.

At his outpatient primary care follow-up visit several days later, the patient reported significant progression in his neck pain and right cervical radiculopathy, and immediate orthopedic evaluation was recommended due to concern for cervical instability. MRI of the cervical spine was performed, which showed an eccentric right-sided C5-C6 disk extrusion that impinged upon the right C6 nerve rootlets at the level of the lateral gutter and could account for the patient’s symptoms. As expected, the spinal melorheostosis involving the right side of C1 and C2 was manifest by patchy hypointense T1 and T2 signal, which is a signal pattern characteristic of sclerotic bone lesions.

The patient’s C5-C6 disk bulge was deemed to be the source of the patient’s cervical radiculopathy, and the spinal melorheostosis was an asymptomatic incidental finding. An anterior cervical discectomy with fusion construct was applied at C5-C6 to treat the disk extrusion, and the patient’s cervicgia and radicular symptoms were documented to have resolved at the 3-month postoperative follow-up exam (Fig. 1).

Discussion

Melorheostosis is a rare sclerosing bone disease that often has pathognomonic imaging features such as a sclerosing hyperostosis with “dripping candle wax” morphology as well as often unilateral involvement and lack of aggressive imaging features that would suggest osteoblastic metastatic disease [2–4]. The most common anatomic locations involved are the appendicular long bones, with the lower extremities more commonly affected. Less commonly, melorheostosis affects the small bones of the appendicular skeleton (eg, carpals, tarsals) and only rarely affects the axial skeleton [1,2]. In the spine, characteristic findings on radiography can be used to suggest the diagnosis; however, CT and MRI are useful to assess extent of hyperostosis, soft tissue involvement, associated intersegmental autofusions, and nerve root and spinal cord impingement [3].

As in the appendicular skeleton, the radiologic findings in melorheostosis of the spine can be pathognomonic. In cases where there is no bridging hyperostosis or characteristic sclerotomal involvement, the differential diagnosis includes osteoblastic metastatic disease as well as alternative sclerosing dysplasias such as osteopoikilosis. Features that would be more suggestive of osteoblastic metastatic disease include a random distribution throughout the spinal bone marrow, a

lack of hyperostosis extending beyond the expected margin of the cortex of the affected bone, and a more spherical or ovoid morphology to the lesions as metastatic disease proliferates centripetally from a hematogenous deposit of neoplastic tissue.

In spinal melorheostosis, there can be significant morbidity related to progression of disease, with impingement on adjacent soft tissue structures, including neurovascular bundles [5]. In symptomatic patients, treatment is aimed at symptom control and restoration of range of movement. Nitrogen-containing bisphosphates such as intravenous zoledronic acid, which function by inhibiting osteoclasts and angiogenesis, thus reducing bone turnover, have been utilized to manage pain [2,7]. The surgical options for spinal melorheostosis causing impingement include standard spinal decompression and fusion surgeries, and these can be tailored to include resection of impinging hyperostosis [2].

In summary, spinal melorheostosis is often an incidental finding on imaging performed for other reasons, such as the patient presented in this case report who had an impinging cervical disk extrusion related to a car accident and an incidental finding of spinal melorheostosis involving the axial cervical spine. As such, when a diagnosis of spinal melorheostosis is made on imaging, the presenting symptomatology must be used to distinguish whether the spinal melorheostosis is symptomatic, or whether it is an asymptomatic incidental finding that is tangential to the clinical presentation.

By understanding the pathognomonic radiologic appearance of melorheostosis along with its possible clinical manifestations, radiologists can spare their patients from unnecessary biopsy, and help guide clinicians determine whether the finding is incidental to the clinical presentation that led to the imaging.

REFERENCES

- [1] Freyschmidt J. Melorheostosis: a review of 23 cases. *Eur Radiol* 2001;11(3):474–9.
- [2] Kotwal A, Clarke BL. Melorheostosis: a rare sclerosing bone dysplasia. *Curr Osteoporos Rep* 2017;15(4):335–42.
- [3] Motimaya AM, Meyers SP. Melorheostosis involving the cervical and upper thoracic spine: radiographic, CT, and MR imaging findings. *AJNR Am J Neuroradiol* 2006;27(6):1198–200.
- [4] Wordworth P, Chan M. Melorheostosis and osteopoikilosis: a review of clinical features and pathogenesis. *Calcif Tissue Int* 2019;104(5):530–43.
- [5] Gagliardi GG, Mahan KT. Melorheostosis: a literature review and case report with surgical considerations. *J Foot Ankle Surg* 2010;49(1):80–5.
- [6] Kumar R, Sankhala SS, Bijarnia I. Melorheostosis—case report of rare disease. *J Orthop Case Rep* 2014;4(2):25–7.
- [7] Theriault RL. Zoledronic acid (Zometa) use in bone disease. *Expert Rev Anticancer Ther* 2003;3:157–66.