

OPEN

# Transplantation of a Liver Allograft From a Hepatitis C Virus Seropositive Donor With Previous Sustained Virologic Response to an Uninfected Recipient Suffering Steroid Refractory Acute Graft Rejection With No Evidence of HCV Transmission

Robert A. Mitchell, MD,<sup>1</sup> Trana Hussaini, PharmD,<sup>2</sup> Alan H. Yau, MD,<sup>1</sup> Mel Krajden, MD,<sup>3</sup> Alissa J. Wright, MD,<sup>4</sup> Charles H. Scudamore, MD,<sup>5</sup> Vladimir Marquez Azalgara, MDCM,<sup>1</sup> Siegfried R. Erb, MD,<sup>1</sup> and Eric M. Yoshida, MD<sup>1</sup>

**Background.** The goal of treating chronic hepatitis C virus (HCV) infection is sustained virologic response (SVR). There is concern that despite achieving SVR, replication-competent HCV may be sequestered at low levels within the liver and could theoretically reactivate with immunosuppression. We report transplantation of a HCV-seropositive liver donor, who achieved SVR, into a seronegative patient without HCV reactivation despite profound immunosuppression. **Method.** Retrospective chart review. **Results.** We present a 21-year-old male who was HCV seronegative and received a liver transplant from a donor who had been treated for HCV and achieved SVR. The liver recipient, despite developing severe acute graft rejection and undergoing intense immunosuppression with T cell-depleting antibodies, did not become HCV RNA-positive with a follow up period of 8 months. The recipient was HCV seronegative before transplant, but became HCV seropositive immediately posttransplant. The antibodies were undetectable after 97 days, in keeping with a passive antibody transmission or B lymphocyte transmission with the graft. **Conclusions.** To the best of our knowledge, this is the first reported case of an HCV seropositive liver allograft transplanted into an HCV-negative recipient who subsequently received intense immunosuppression. This case, therefore, is an encouraging and novel step in liver transplantation, and demonstrates that SVR may be closer to a true “cure” of HCV in the donor population and that, even in circumstances of very potent immunosuppression in the recipient, this SVR is sustained.

(*Transplantation Direct* 2018;4: e347; doi: 10.1097/TXD.0000000000000763. Published online 2 February, 2018.)

Sustained virologic response (SVR), defined as hepatitis C virus (HCV) ribonucleic acid (RNA) negativity 12/24 weeks posttherapy,<sup>1</sup> is the goal of treatment and is

regarded as virologic “cure.” This has been rigorously studied, and is generally true, with over 99% of patients maintaining SVR at extended follow-up.<sup>2</sup> Despite excellent outcomes in

Received 8 October 2017. Revision requested 18 November 2017.

Accepted 12 December 2017.

<sup>1</sup> Division of Gastroenterology, University of British Columbia, Vancouver, BC, Canada.

<sup>2</sup> Faculty of Pharmaceutical Sciences, University of British Columbia, Vancouver, BC, Canada.

<sup>3</sup> Department of Pathology and Laboratory Medicine, University of British Columbia, Vancouver, BC, Canada.

<sup>4</sup> Division of Infectious Diseases, University of British Columbia, Vancouver, BC, Canada.

<sup>5</sup> Division of General Surgery, University of British Columbia, Vancouver, BC, Canada.

E.Y. has been an investigator of clinical trials sponsored by Gilead Sciences Inc, Merck Inc, Janssen Inc, AbbVie Inc. He has received honoraria for CME/Ad Board lectures from Gilead Canada Sciences, Merck Canada, AbbVie Canada, Celgene Canada.

M.K. has received research grants and contract funding paid to his institution from Roche, Hologic, Siemens, Boehringer Ingelheim and Merck for unrelated research.

Informed patient consent was obtained for publication of case details.

R.M. is article author and participated in the literature review. H.T. is article editor and participated in the critical revision of the article. A.Y. is article editor and participated in the critical revision of the article. K.M. is article editor and participated in the critical revision of the article. A.W. is article editor and participated in the critical revision of the article. C.S. is article editor and participated in the critical revision of the article. V.M. is article editor and participated in the critical revision of the article. S.E. is article editor and participated in the critical revision of the article. E.Y. is article guarantor and article editor and participated in the critical revision of the article.

Correspondence: Robert Mitchell, MD, Gastroenterology Division, University of British Columbia, 5th Floor, Gordon & Leslie Diamond Health Care Center, 2775 Laurel St., Vancouver, BC, Canada V5Z 1M9. (rmitch86@gmail.ca).

Copyright © 2018 The Author(s). *Transplantation Direct*. Published by Wolters Kluwer Health, Inc. This is an open-access article distributed under the terms of the Creative Commons Attribution-Non Commercial-No Derivatives License 4.0 (CCBY-NC-ND), where it is permissible to download and share the work provided it is properly cited. The work cannot be changed in any way or used commercially without permission from the journal.

ISSN: 2373-8731

DOI: 10.1097/TXD.0000000000000763

the general population, there remains a concern that achieving an SVR may not fully eradicate replication competent virus, with the concern that in special circumstances the virus may reactivate or remain present at low levels within the liver. There are rare reports of patients who achieve SVR, undergo a significant immunosuppressive event and suffer virologic relapse.<sup>3</sup> Some studies have suggested that low levels of HCV RNA remain detectable and replicative in the liver and peripheral white blood cells of patients who achieve SVR.<sup>4</sup> It is conceivable that occult HCV remains present, but dormant in the liver after SVR, and might reactivate with immunosuppression.<sup>5</sup> This phenomenon is well recognized in hepatitis B infected patients who have “resolved” their infection (surface antigen-negative, core antibody-positive [Ab+]) but reactivate after immunosuppression.<sup>6</sup> For hepatitis B, the replicative form of the virus (a covalently closed circular DNA) is typically not cleared with resolved infection and the virus may integrate into the host chromosome. In contrast, HCV is not known to integrate within hepatocyte chromosomes. We report transplantation of a HCV seropositive liver donor, who achieved SVR, into a seronegative patient without HCV reactivation despite intense immunosuppression.

## CASE REPORT

A 21-year-old man with end-stage primary sclerosing cholangitis (PSC) underwent a first orthotopic liver transplantation at age 15 years. He developed progressive liver allograft dysfunction because of recurrent PSC. At age 21 years, he was readmitted to hospital with severe jaundice and hepatorenal syndrome. He underwent a second orthotopic liver transplantation from a deceased donor during the hospitalization. He was HCV antibody-negative, verified 1 day before retransplant.

The deceased liver donor had a history of HCV infection and had been treated with pegylated interferon and ribavirin and achieved SVR 7 years before donation. At the time of transplantation, the donor was HCV Ab+, but HCV RNA PCR was undetectable on 2 samples immediately before organ retrieval. After discussion of the possible risks of HCV reactivation and consent from the transplant recipient, the liver was accepted for transplantation.

After transplant, the patient received a standard immunosuppression regimen which included steroids, mycophenolate mofetil and basiliximab induction with delayed introduction of tacrolimus on postoperative day 7 due to acute kidney injury. The patient was tested for HCV seven days after transplant and was found to now be HCV Ab+ but HCV RNA PCR remained undetectable.

The posttransplant course was complicated by the development of biopsy-proven acute cellular rejection. The patient was treated with pulse steroids starting on posttransplant day 14 (methylprednisolone 600 mg IV for 3 days), followed by Prednisone 20 mg daily. Despite this, he had persistently elevated liver biochemistry. Donor-specific antibody levels were measured and were undetectable. A diagnosis was given of T-cell-mediated steroid-refractory acute graft rejection. Starting on posttransplant day 42, he was treated with a 10-day course of antithymocyte globulin (ATG) at 1.75 mg/kg per day. After this treatment, he had a gradual decline in his liver biochemistry and a repeat biopsy

demonstrated interval improvement in inflammation. After this period of intense immunosuppression, he developed cytomegalovirus reactivation requiring ganciclovir infusion. Of note, on the biopsies performed for acute graft rejection, there was no evidence of cirrhosis or significant fibrosis in the graft.

Given the patient’s HCV Ab+ status on posttransplant day 7 and concerns for virologic relapse within the donor liver during immunosuppression, he had repeat HCV antibody and PCR testing. The titres of anti-HCV Ab over time are noted (Table 1). Despite the interval immunosuppression, he had progressive decay of the HCV Ab over a period of 97 days and HCV RNA was persistently negative (Figure 1). At 9 months posttransplant, he remains HCV-negative both serologically and virologically. He underwent ultrasound screening for hepatocellular carcinoma at 6 months, which was negative; he will continue to undergo ultrasound screening every 6 months.

## DISCUSSION

This report describes liver transplantation from a donor with previously treated HCV who achieved SVR, to an uninfected recipient who subsequently received an intense immunosuppressive regimen including ATG administration for acute graft rejection. Despite a profound level of immunosuppression, as demonstrated by cytomegalovirus reactivation, HCV RNA remained undetectable in the recipient. The recipient was HCV seronegative before transplant, but became HCV seropositive immediately posttransplant. The antibodies were no longer positive after 97 days, in keeping with a passive antibody transmission or B lymphocyte transmission with the graft.<sup>7</sup> The baseline levels of HCV Ab, although above the limit of reactivity, were very low. This could be a result of organ preparation, with saline and preservation solution flushes before transplantation. This is the first documented example of HCV antibody decay postliver organ transplant.

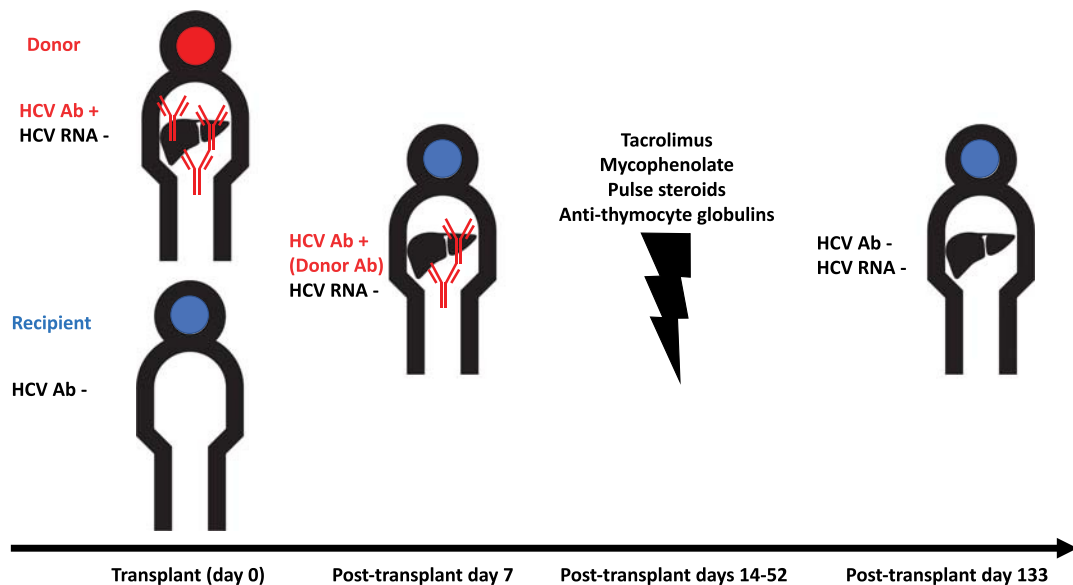
This case demonstrates the durability of SVR from deceased donor livers despite extremely aggressive immunosuppression in the recipient. Other reports exist of patients suffering late viral recurrence after immunosuppression post-SVR. One report from Lin et al. describes a patient who achieved SVR and 2 years later underwent kidney transplant from an HCV-uninfected donor followed by ATG, mycophenolate,

**TABLE 1.**  
Recipient hepatitis C antibody slowly wanes after liver transplantation from a HCV Ab+ donor to an uninfected recipient

Time posttransplant, d	HCV Ab signal (Siemens Centaur Assay)	HCV Ab signal (Abbott Architect Assay)
8	1.90*	2.35 <sup>a</sup>
37	1.90*	3.11 <sup>a</sup>
51	0.77	1.26 <sup>a</sup>
97	0.11	Not tested
133	0.04	Not tested

HCV Ab+ titres were monitored after liver transplantation from a HCV Ab+ donor to a hepatitis C uninfected recipient. In the transplant recipient, the antibody levels were initially mildly elevated and gradually decreased to non-reactive levels. The “reactive” antibody threshold is 1.0 on both assays.

<sup>a</sup> Reactive.



**FIGURE 1.** Liver transplantation from a HCV Ab+ donor to an uninfected recipient followed by immunosuppression. A HCV Ab+ deceased donor achieved SVR with pegylated interferon/ribavirin 7 years before organ transplant to a hepatitis C uninfected individual. The transplant recipient briefly had hepatitis C antibody positivity, followed by an immunosuppressive regimen for acute graft rejection. The recipient became hepatitis C antibody-negative after 4 months, in keeping with a passenger lymphocyte/antibody phenomenon from the donor. The recipient never became hepatitis C RNA-positive.

and tacrolimus with subsequent viral recurrence.<sup>3</sup> Another report exists of a patient with hypogammaglobulinemia who achieved SVR for 8.5 years only to have reemergence of HCV virus after prednisone for asthmatic episodes.<sup>8</sup>

Recent literature has suggested that use of organs from HCV Ab+ donors (with undetectable RNA) to uninfected recipients may be appropriate in the correct setting.<sup>9</sup> A recent study demonstrated the effective use of transplanted kidneys from HCV RNA-positive donors into HCV RNA-negative recipients, with subsequent HCV rescue treatment.<sup>10</sup> Trials are currently underway investigating the use of ex vivo perfusion techniques to reduce HCV RNA levels before lung transplantation from HCV RNA-positive donors to uninfected recipients.<sup>11</sup> Recent guidelines describe the practice of liver transplantation of HCV Ab+, HCV RNA-negative donors to HCV-naïve recipients as generally safe with a low risk of transmission.<sup>12</sup> It is unclear, however, how the use of potent immunosuppression (such as ATG) affects the transmissibility of HCV infection after transplant in this scenario.

To the best of our knowledge, this is the first reported case of an HCV seropositive liver allograft transplanted into a HCV-negative recipient who subsequently received intense immunosuppression for acute graft rejection, although other cases may be unreported. This case, therefore, is an encouraging and novel step in liver transplantation, and demonstrates that SVR may be closer to a true “cure” of HCV in the donor population and that, even in circumstances of very potent immunosuppression in the recipient, this SVR is sustained. Extreme caution must still be used until larger clinical trials have demonstrated the safety of this practice, and the clinical

need for transplant in this situation must always justify the risk of possible donor transmitted infection.

## REFERENCES

1. AASLD/IDSA HCV Guidance Panel. Hepatitis C guidance: AASLD-IDSA recommendations for testing, managing, and treating adults infected with hepatitis C virus. *Hepatology*. 2015;62:932–954.
2. Swain MG, Lai M-Y, Shiffman ML, et al. A sustained virologic response is durable in patients with chronic hepatitis C treated with peginterferon alfa-2a and ribavirin. *Gastroenterology*. 2010;139:1593–1601.
3. Lin A, Thadareddy A, Goldstein MJ, et al. Immune suppression leading to hepatitis C virus re-emergence after sustained virological response. *J Med Virol*. 2008;80:1720–1722.
4. Castillo I, Rodríguez-Irigo E, López-Alcorocho JM, et al. Hepatitis C virus replicates in the liver of patients who have a sustained response to antiviral treatment. *Clin Infect Dis*. 2006;43:1277–1283.
5. Seeff LB. Sustained virologic response: is this equivalent to cure of chronic hepatitis C? *Hepatology*. 2013;57:438–440.
6. Law JK, Ho JK, Hoskins PJ, et al. Fatal reactivation of hepatitis B post-chemotherapy for lymphoma in a hepatitis B surface antigen-negative, hepatitis B core antibody-positive patient: potential implications for future prophylaxis recommendations. *Leuk Lymphoma*. 2005;46:1085–1089.
7. Ramsey G. Red cell antibodies arising from solid organ transplants. *Transfusion*. 1991;31:76–86.
8. Lee WM, Polson JE, Carney DS, et al. Reemergence of hepatitis C virus after 8.5 years in a patient with hypogammaglobulinemia: evidence for an occult viral reservoir. *J Infect Dis*. 2005;192:1088–1092.
9. Kling CE, Perkins JD, Landis CS, et al. Utilization of organs from donors according to hepatitis c antibody and nucleic acid testing status: time for change. *Am J Transplant*. 2017;148:100. doi:10.1111/ajt.14386.
10. Goldberg DS, Abt PL, Blumberg EA, et al. Trial of transplantation of HCV-infected kidneys into uninfected recipients. *N Engl J Med*. 2017;376:2394–2395.
11. Cypel M. Lung Transplant HCV, Pilot Study. ClinicalTrials.gov. <https://clinicaltrials.gov/ct2/show/NCT03112044>. Accessed August 31, 2017.
12. Levitsky J, Formica RN, Bloom RD, et al. The American Society of Transplantation Consensus Conference on the use of hepatitis C viremic donors in solid organ transplantation. *Am J Transplant*. 2017;17:2790–2802.