



Surgical Treatment of Comminuted Midshaft Clavicle Fracture by Minimally Invasive Technique: Description and Preliminary Results*

Tratamento cirúrgico da fratura multifragmentada da diáfise da clavícula pela técnica minimamente invasiva: Descrição e resultados preliminares

Adriano Fernando Mendes Junior¹ Jose da Mota Neto¹ Igor Gerdi Oppe¹
Leandro Furtado de Simoni² Vincenzo Giordano³ Pedro José Labronici⁴

¹Hospital Universitário, Universidade Federal de Juiz de Fora, Juiz de Fora, MG, Brazil

²Hospital Maternidade Therezinha de Jesus, Juiz de Fora, MG, Brazil

³Hospital Municipal Miguel Couto, Rio de Janeiro, RJ, Brazil

⁴Universidade Federal Fluminense, Niterói, RJ, Brazil,

Address for correspondence Adriano Fernando Mendes Junior, Rua Sampaio, 468, apartamento 1402, Juiz de Fora, Minas Gerais, 36010-360, Brazil (e-mail: adrianofmj@yahoo.com.br).

Rev Bras Ortop 2021;56(4):490–496.

Abstract

Objective The present paper aimed to evaluate functional and radiographic outcomes from a group of patients with comminuted midshaft clavicle fracture who were surgically treated using a minimally invasive technique and followed-up for a minimum period of 12 months.

Methods Longitudinal, observational study with 32 consecutive patients (31 males; mean age, 41 years old) with comminuted midshaft clavicle fracture who were surgically treated using the minimally invasive osteosynthesis technique with a 3.5-mm reconstruction plate in the upper position. Patients were clinically and radiologically evaluated for a minimum follow-up period of 12 months.

Results In 30 patients (93.72%), fracture consolidation occurred in an average time of 17 weeks (range, 12 to 24 weeks). The mean follow-up time was 21 months (range, 12 to 45 months). No implant break or pseudoarthrosis were recorded. There was no complaint of paresthesia around the surgical incisions. The surgically-treated shoulder presented lower passive elevation and longer clavicle length ($p < 0.05$) compared with the contralateral shoulder. Functional evaluation revealed an average Disability of Arm, Shoulder and Hand (DASH) score of 1.75, which is considered satisfactory. Age > 60 years old had a negative correlation with DASH score ($p < 0.05$).

Conclusion The minimally invasive osteosynthesis technique was satisfactory for the treatment of comminuted midshaft clavicle fracture, with a high consolidation rate and a low complication rate.

Keywords

- ▶ clavicle
- ▶ fractures, bone
- ▶ treatment outcome
- ▶ minimally invasive surgical procedures

* Study developed at Hospital Universitário da Universidade Federal de Juiz de Fora, Juiz de Fora, MG, Brazil.

received
November 1, 2019
accepted
May 5, 2020
published online
September 24, 2020

DOI <https://doi.org/10.1055/s-0040-1714226>.
ISSN 0102-3616.

© 2020. Sociedade Brasileira de Ortopedia e Traumatologia. All rights reserved.

This is an open access article published by Thieme under the terms of the Creative Commons Attribution-NonDerivative-NonCommercial-License, permitting copying and reproduction so long as the original work is given appropriate credit. Contents may not be used for commercial purposes, or adapted, remixed, transformed or built upon. (<https://creativecommons.org/licenses/by-nc-nd/4.0/>)

Thieme Revinter Publicações Ltda., Rua do Matoso 170, Rio de Janeiro, RJ, CEP 20270-135, Brazil

Resumo

Objetivo Avaliar os resultados funcionais e radiográficos do tratamento cirúrgico realizado em um grupo de pacientes com fratura multifragmentada da diáfise de clavícula, pela técnica minimamente invasiva, em seguimento mínimo de 12 meses.

Métodos Estudo observacional longitudinal de 32 pacientes consecutivos (31 do sexo masculino, idade média 41 anos) com fratura multifragmentada da diáfise da clavícula tratados cirurgicamente pela técnica minimamente invasiva de osteossíntese com placa de reconstrução de 3,5 mm na posição superior, avaliados clínica e radiologicamente, com seguimento mínimo de 1 ano

Resultados Trinta pacientes (93,72%) evoluíram com consolidação da fratura em tempo médio de 17 semanas (entre 12 e 24 semanas). O tempo de seguimento médio foi de 21 meses (variando de 12 a 45 meses). Não houve quebra de implantes ou pseudoartroses. Não houve queixa de parestesia na região das incisões cirúrgicas. O ombro tratado cirurgicamente apresentou menor elevação passiva e maior comprimento da clavícula ($p < 0,05$) em relação ao contralateral. Na avaliação funcional, encontramos um valor médio de Disfunções do Braço, Ombro e Mão (DASH, na sigla em inglês) = 1,75, sendo o mesmo considerado satisfatório. Idade > 60 anos apresentou correlação negativa com escore DASH ($p < 0,05$).

Conclusão A técnica minimamente invasiva de osteossíntese mostrou-se satisfatória para o tratamento da fratura multifragmentada da diáfise da clavícula, com elevada taxa de consolidação e baixo índice de complicações.

Palavras-chave

- ▶ clavícula
- ▶ fraturas ósseas
- ▶ resultado do tratamento
- ▶ procedimentos cirúrgicos minimamente invasivos

Introduction

Clavicle fractures account for 2.6 to 5% of all fractures in adults;¹⁻³ ~ 80 to 85% of these injuries affect the middle third of the bone.^{1,2} Complex or comminuted midshaft clavicle fractures are commonly caused by high-energy accidents, direct trauma or axial compression.^{3,4} Clavicular biomechanics differ from that of long bones and the behavior of clavicle comminuted fractures is poorly studied.⁵ According to the literature, the conservative treatment of these fractures is associated with higher pseudoarthrosis rates.^{2,6,7} Other studies argue that the surgical treatment leads to improved functional outcomes when compared to the nonsurgical treatment.⁶⁻⁹ Most Brazilian orthopedists indicate osteosynthesis for deviated and/or comminuted shaft fractures.¹⁰

The most widely used osteosynthesis method for deviated clavicular shaft fractures is open reduction and internal fixation (ORIF) with plate and screws.^{5,9} However, since comminuted fractures require an extensive access to the fracture site, this approach may be associated with high rates of complications, including hypertrophic, painful scars,⁴ infection,¹¹ pseudoarthrosis,¹² implant failure and refracture after implant removal.¹³ As advantages, the minimally invasive osteosynthesis (MIO) technique with plates preserves the blood supply at the fracture site¹⁴ and can decrease these complications. Minimally invasive osteosynthesis is commonly used in complex long bone fractures in lower limbs,¹⁵ and has proven applicability in diaphyseal fractures of the upper limbs.¹⁶

Some authors have described their MIO techniques and outcomes in clavicle comminuted fractures.^{17,18} The published studies use implant materials that are not easily

accessible to the Brazilian population through the Brazilian Unified Health System (SUS, in the Portuguese acronym). There are no studies in the Brazilian literature regarding the MIO technique with plates to treat such fractures. The present study aims to evaluate clinically and radiographically a group of patients with comminuted midshaft clavicle fracture who were surgically treated using the MIO technique and a 3.5 mm reconstruction plate in the upper position.

Methodology

Longitudinal, observational study, with a retrospective initial survey of patients with comminuted midshaft clavicle fracture who were surgically treated using the MIO technique with plate in the upper position by one of the authors from January 2014 to May 2017 at the university hospital from our institution. The sample size corresponds to the number of patients who were surgically treated in this period and attended the evaluation. The study included patients > 16 years old with comminuted midshaft clavicle fracture type 2B2 according to the Robinson classification⁹ who were surgically treated within 21 days after the trauma and were followed-up for a minimum period of 12 months. Patients with open fractures or associated vascular and nerve injuries, fractures extending to joints, fractures and/or discomfort concomitant with shoulder girdle trauma, concurrent fractures in other parts of the upper limb (arm, forearm, wrist and hand), history of previous clavicular fractures or shoulder girdle trauma, pathological fractures, and metabolic and/or congenital diseases were excluded. The final sample consisted of 32 patients. Patients eligible for the study for

meeting inclusion and exclusion criteria were contacted for an interview, in which the study was explained and the informed consent form (ICF) of the study was presented. Subjects who agreed in participating in the study were prospectively submitted to a clinical evaluation, including the Disability of Arm, Shoulder and Hand (DASH) questionnaire,¹⁹ and radiological tests. Functional evaluation included the DASH questionnaire and a physical examination (passive range of motion of the shoulder, subacromial, rotator cuff and acromioclavicular impingement tests, thoracic scapular dyskinesia and force during active elevation measured with a manual dynamometer [Science Supply Solutions # U40812 [Science Supply Solutions, LLC, Bensenville, Illinois, United States of America], graduation 1 kg/10 N]) performed by an examiner not as involved in the surgical procedures as the main surgeon. At the postoperative period, a digital radiographic evaluation of the clavicles was performed in anteroposterior (AP) and modified craniocaudal views for verification purposes; a posteroanterior (PA) chest radiograph was taken to measure the final length of the clavicle according to the criteria by Smekal et al.²⁰. In addition, medical records were analyzed on outcomes of the surgical procedure, such as consolidation time, delayed consolidation, pseudoarthrosis, infection, implant loosening, synthesis material failure, residual pain and range of motion.

Surgical technique (adapted from Jung et al.¹⁸): patient in the beach chair position; the procedure was aided by radioscopy in frontal and modified craniocaudal views of the clavicle with an approximate inclination of 70° (► **Figure 1**). A fracture reduction maneuver (the Kibler maneuver) was performed; the surgeon put the ipsilateral arm to a posterior, slightly superior position, with lateral rotation of the shoulder, approximating the scapula to the rib cage with lateral, superior rotation and posterior scapular inclination (a position mimicking retraction), leading to the indirect clavicle fracture reduction. Using radioscopy, the clavicular length and shape were determined to choose the implant size (3.5-mm, unlocked reconstruction plate). Next, the medial and lateral ends of the clavicle were palpated to locate the sternal and acromial borders, respectively. A transverse incision 1 cm lateral to the sternal border, with ~ 1.5 cm, was performed on the upper surface, with deep plane

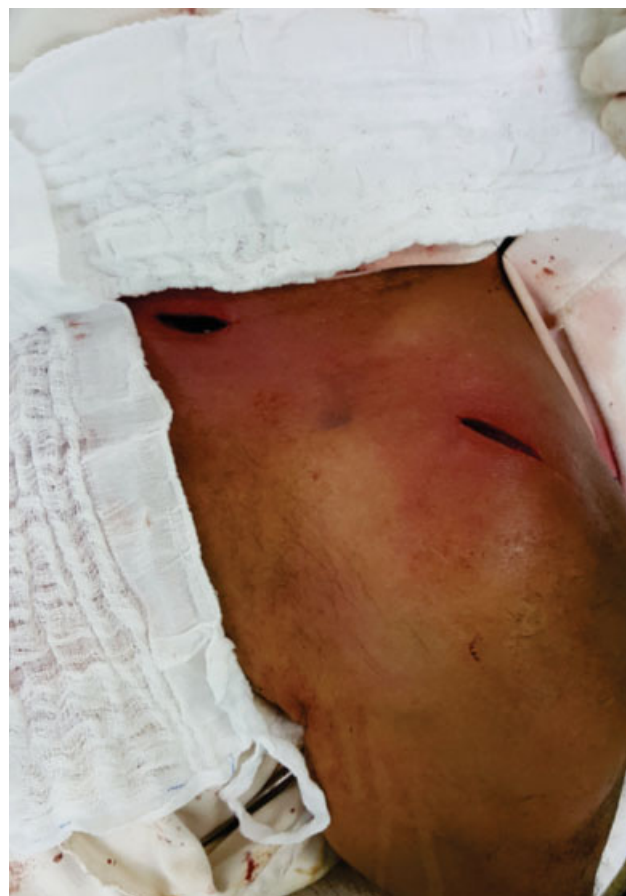

Fig. 2 Medial and lateral incisions.

dissection up to the bone bed (upper clavicle surface). In the lateral region, 1 cm medial from the acromial border, a second incision was made, with the same size, direction and depth, up to the upper clavicle surface. Another bed was prepared at the upper region of the clavicle, from medial to lateral, to pass the implant to an upper position with instruments for blunt dissection (► **Figure 2**). The plate was modeled during surgery (► **Figure 3**), with a medial anterior convexity and a lateral posterior convexity, both at the level of the third most lateral and medial plate holes, following the clavicular shape

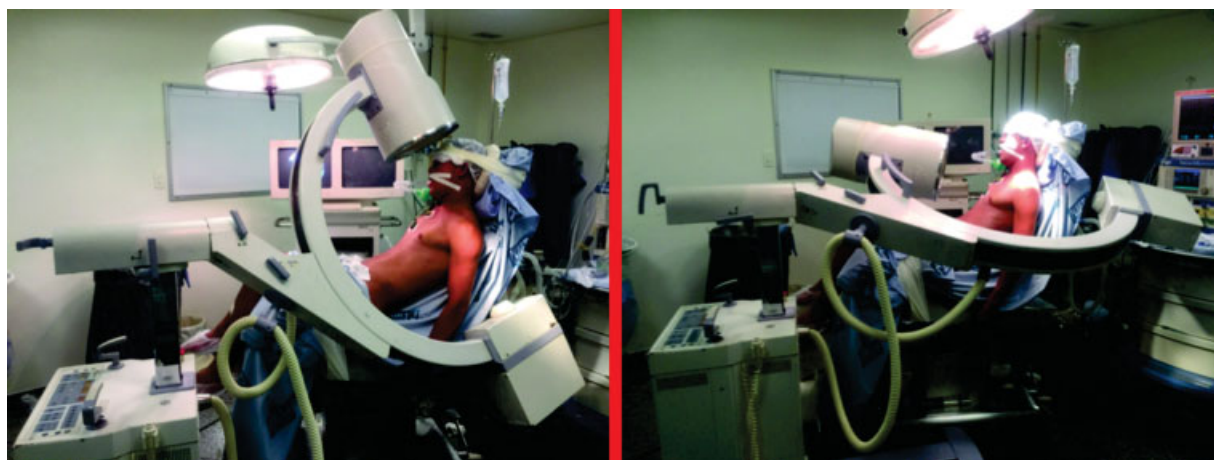


Fig. 1 Radioscopy positioning for superior and anterior views.

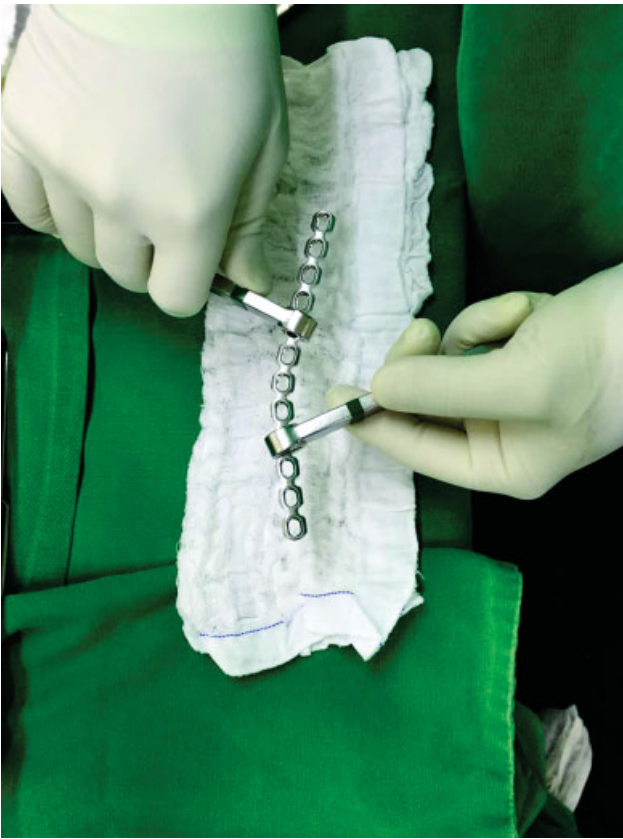

Fig. 3 Plate modeling.

determined at radioscopy. The plate was slipped in the supraclavicular tunnel from medial to lateral, with the scapula kept in a retracted position. Provisional fixation was performed with 2.5-mm Kirchner wires (for length evaluation under radioscopy), and the plate was fixated with 3 bicortical screws on each side, alternately, starting from the medial side. Reduction and final plate and screws positioning were verified (► **Figure 4**). Wounds were irrigated with 0.9% saline solution; deep layers were closed with 3.0 mononylon sutures followed by 2.0 intradermal sutures.

After surgery, the limb was kept in a sling for 6 weeks, and full elbow, wrist and hand movements were oriented. Elevation, abduction $> 30^\circ$ and shoulder rotations were discouraged. After 8 weeks, full active shoulder movements were allowed. Return to activities with load and playing sports were allowed after detecting signs of fracture consolidation on control radiographs.

The patients were followed-up on an outpatient basis, with initial visits in 15 and 30 days and, next, monthly visits until the detection of bone consolidation on control radiographs. Bone union was determined by signs of bone callus on both AP and craniocaudal radiographs, and absence of mobility on diaphyseal palpation.

For statistical analysis, descriptive data was expressed as frequency, mean and standard deviation (SD) tables. The Fisher exact test analyzed associations between categorical variables. Paired t-tests compared the operated and nonoperated sides for continuous numerical variables. Error normality was analyzed by box plot, quantile-quantile graph

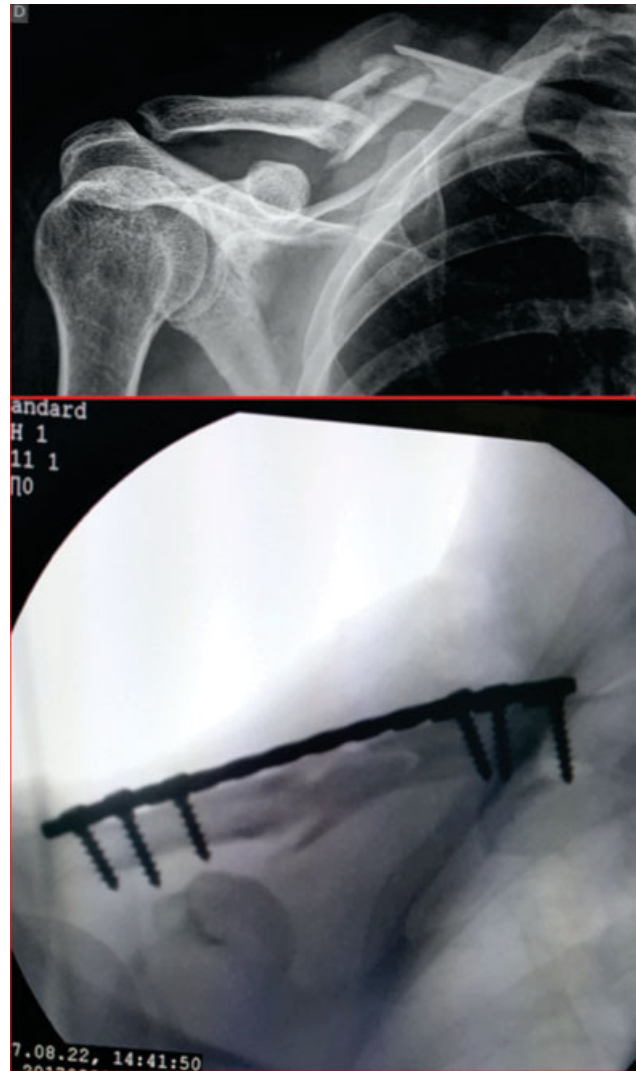

Fig. 4 Before and after fixation with the minimally invasive osteosynthesis (MIO) technique.

and the Shapiro-Wilk test. The analyses were carried out in R* software (R Foundation, Vienna, Austria) considering a significance level of 5%. The present manuscript was written according to the Strengthening the Reporting of Observational Studies in Epidemiology (STROBE) Statement guidelines for observational studies (► **Annex 1**) and was approved by the institutional ethics committee under the number CAE 66877517.5.0000.5133.

Results

The sample consisted of 32 patients, with 31 males and mean age of 41 years old (range, 19 to 61 years old). The median follow-up period was of 21 months (range, 12 to 45 months). The fractures were caused mainly by high-energy trauma (motorcycle and car accidents). The average time until the procedure was 9 days. Demographic data of the patients are presented in ► **Table 1**.

Categorical variables obtained during physical examinations revealed no differences between the operated and nonoperated sides. These variables were not associated to

Table 1 Descriptive analysis of sample characteristics

Variable	Frequency (%)
<i>Gender</i>	
Female	1 (3.1)
Male	31 (96.9)
<i>Trauma type</i>	
Motorcycle accident	14 (43.8)
Fall to the ground	9 (28.1)
Car accident	4 (12.5)
Others	5 (15.6)
<i>Side</i>	
Right	10 (31.3)
Left	22 (68.8)
<i>Dominance</i>	
Right	31 (96.9)
Left	1 (3.1)

continuous numerical variables from the physical examination or functional scores. The operated side had statistically significant ($p < 0.05$) lower mean passive elevation and higher mean clavicle length compared with the nonoperated side (► **Table 2**). There was no statistically significant difference regarding the presence or not of scapular dyskinesia when comparing the operated and nonoperated sides.

At the functional evaluation, the mean DASH score was 1.75, which is considered satisfactory. Using a value of 10 points to analyze the least significant clinical difference (MCID),²¹ scores were subdivided into satisfactory and unsatisfactory. Patients with an early failure of the fixation method were considered as unsatisfactory outcomes for association analyses. Among patients > 50 years old, 33.3% had unsatisfactory DASH scores (≥ 10), whereas only 4.4% of patients < 50 years old had unsatisfactory scores ($p = 0.0572$) (► **Table 3**). Two patients > 60 years old (100.0%) showed unsatisfactory DASH scores, differing significantly from the group < 60 years old ($p < 0.05$), in which 6.7% of the patients had unsatisfactory scores. Among patients with shorter waiting times until surgery (up to 7 days), no one had unsatisfactory DASH scores; on the other hand, among those who waited > 7 days until surgery, 26.7% had unsatisfactory scores ($p < 0.05$).

Table 2 Comparison between operated and nonoperated side variables

Variable	Total Mean (SD)	Side		<i>p-value</i>
		Operated Mean (SD)	Nonoperated Mean (SD)	
Elevation (degrees)	157.67 (7.89)	155.67 (10.73)	159.67 (1.83)	0.0497 ^a
Lateral rotation (degrees)	83.83 (11.77)	83.17 (12.49)	84.50 (11.17)	0.4029
Force (Kgf)	11.43 (2.51)	11.23 (2.96)	11.63 (1.99)	0.3662
Clavicle length (cm)	16.23 (1.23)	16.33 (1.26)	16.13 (1.22)	0.0362 ^a

Abbreviation: SD, standard deviation.

^aPaired t-test ($p < 0.05$).

Table 3 Analysis of the association between studied variables and Disability of Arm, Shoulder and Hand scores

Variable	n (%)	DASH		<i>p-value</i>
		Unsatisfactory	Satisfactory	
		Frequency (%)	Frequency (%)	
<i>Age</i>				
≤ 42 years old (median)	19 (59.4)	1 (5.3)	18 (94.7)	0.2788
> 42 years old	13 (40.6)	3 (23.1)	10 (76.9)	
≤ 50 years old	23 (71.9)	1 (4.4)	22 (95.6)	0.0572
> 50 years old	9 (28.1)	3 (33.3)	6 (66.7)	
≤ 60 years old	30 (93.8)	2 (6.7)	28 (93.3)	0.0121 ^a
> 60 years old	2 (6.2)	2 (100.0)	0 (0.0)	
<i>Gender</i>				
Female	1 (3.1)	0 (0.0)	1 (100.0)	1.0000
Male	31 (96.9)	4 (12.9)	27 (87.1)	
<i>Days until surgery</i>				
≤ 7 days (median)	17 (53.1)	0 (0.0)	17 (100.0)	0.0380 ^a
> 7 days	15 (46.9)	4 (26.7)	11 (73.3)	
<i>Complaints</i>				
No	20 (62.5)	1 (5.0)	19 (95.0)	0.1361
Yes	12 (37.5)	3 (25.0)	9 (75.0)	
<i>Consolidation</i>				
No	2 (6.2)	2 (100.0)	0 (0.0)	0.0121 ^a
Yes	30 (93.8)	2 (6.7)	28 (93.3)	

Abbreviation: DASH, disability of arm, shoulder and hand questionnaire.

^aFisher exact test ($p < 0.05$).

Twelve-hole implants were used in 28 patients, and 5 cases (15.6%) required material removal. Consolidation occurred in 30 patients (93.72%) after an average period of 17 weeks, and no pseudoarthrosis or infection was observed. As complications, there were 2 cases of early failure after osteosynthesis; both patients were 61 years old at the time and presented implant loosening, with no plate fracture: 1 within 1 week after surgery (an alcoholic patient) (► **Figure 5**) and the other

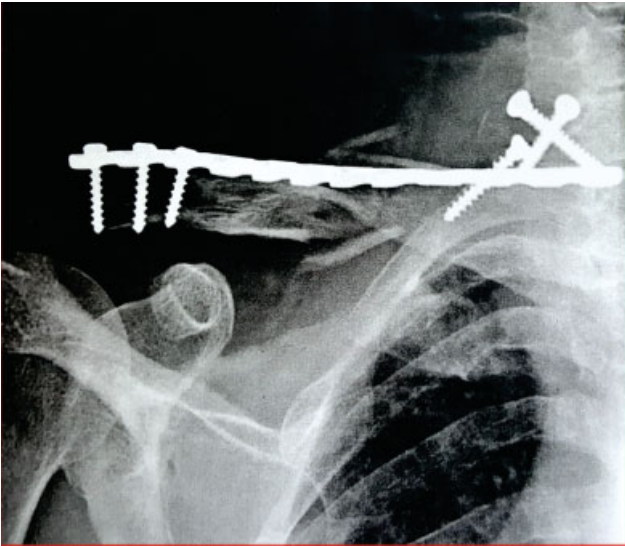


Fig. 5 Detailing of one of the cases with early loosening.

within 8 weeks after surgery (a patient with type 2 diabetes). Both underwent a new surgery for ORIF with plate and screws, but no bone graft, and progressed with fracture consolidation.

The following complications were observed in the study population: pain on exertion (5 patients – 15.6%), plate-related discomfort (6 patients – 18.8%), hypersensitivity (2 patients – 6.2%), and pain at rest (1 patient – 3.1%). Paresthesia around surgical incisions was not reported. The 2 cases of early implant loosening presented unsatisfactory DASH scores (100.0%); in patients with consolidation, however, 93.3% of DASH scores were deemed satisfactory ($p < 0.05$).

Discussion

There was no case of pseudoarthrosis or infection in our sample. We believe that the technique here described spares soft tissues and the fracture focus, contributing to the consolidation rate of 93.72% observed in our sample, similar to that reported by Sohn et al.²² Our patients presented good clinical, functional and radiographic outcomes, which were in line with the literature. Mirzatolooei⁴ observed similar consolidation rates between surgically and clinically treated patients; the former, however, presented lower rates of vicious consolidation and shortening and better DASH scores (mean score, 8.6). This author chose the method of absolute stability and performed fixation with a reconstruction plate in the upper position, obtaining pseudoarthrosis associated with infection.

The rate of early failure was similar to that reported by Wang et al.,²³ who described the same complication, implant loosening, in one of their patients. Our unsatisfactory DASH scores were associated with older age and early fixation failure, and may possibly require an reevaluation of the indication of such technique in this age group; however, due to the observational nature of the study, we cannot say which is the most important factor associated with this complication: bone quality or the use of an unlocked implant.

The MIO technique has the benefit of using smaller incisions, avoiding large exposures that can favor suture dehiscence, infections or pseudoarthrosis.¹³ Incisions performed in the lateral and medial regions of the clavicle do not harm the areas supplied by supraclavicular nerves,²⁴ preventing the development of paresthesia. Other authors corroborate the benefits of the minimally invasive procedure. Jiang et al.²⁵ compared the outcomes from comminuted fractures of the clavicle treated using the mini-open and ORIF surgical techniques. These authors described that patients treated with the mini-open technique presented less dysesthesia, no hypertrophic scars, better ipsilateral shoulder mobility and no pain. You et al.²⁶ reported that the MIO technique resulted in a lower rate of paresthesia at the anterior chest and greater patient satisfaction when compared with the traditional surgical method.

Another important analysis refers to implant removal procedures, which are common in patients undergoing clavicle osteosynthesis. In our sample, 15.60% of the patients required implant removal, consistent with the index reported by Sökücü et al.,⁸ and lower than the 23% rate observed by Asadollahi et al.²⁷

This fracture reduction method is unprecedented and based on retracted scapula positioning, which is described by Kibler et al.,²⁸ ideal for shoulder function. In this technique, the scapula is externally and superiorly rotated, posteriorly inclined and medially translated in relation to the chest. We believe that this maneuver contributes to the alignment of fractured fragments of the clavicle; such alignment was observed in all patients systematically submitted to the maneuver during surgery. We also observed that additional devices, such as Kirchner wires,¹⁷ traction with a screw outside the plate¹⁸ or small approaches to the fracture site were not required to sustain this position.²³ In addition to the scapular retraction maneuver, the unlocked implant in the superior position also helps to reduce fragments, since cortical screws brings deviated inferiorly fragments towards the plate. Implants in the anterior-inferior position or those with superiorly placed locked screws may not be useful to correct these deviations.

We used a 3.5-mm reconstruction plate, as it is an implant easily modeled according to the shape of each clavicle. Some authors^{8,25,26} perform the MIO technique with anatomical or premodeled implants, whereas others^{17,18,22,23} share our philosophy of individualized reconstruction plate modeling for each case but use locked 3.5-mm reconstruction implants. We prefer to use unlocked implants because of their higher availability in Brazil, especially in the SUS. Alzahrani et al.²⁹ evaluated 102 patients after clavicle osteosynthesis with 4 different implants (2.7-mm and 3.5-mm reconstruction plates, premolded plate and 3.5-mm locked plate), and reported that, despite biomechanical studies showing different tensile properties, there was no difference between groups regarding consolidation or complication rate. We emphasize that implant breaks were not observed, consistent with Silva et al.,³⁰ who reported no unlocked reconstruction plate rupture in their study on the surgical treatment of deviated clavicle fractures using these devices or intramedullary nails.³⁰

The positive points of our study are the high reproducibility of the technique, attesting its internal validation, with low

complication rates, no implant breaks, high consolidation rates and satisfactory functional scores determined by an independent examiner. The limitations of the study stem from its observational nature, since our controls are the results of similar studies described by other authors. In addition, we believe that our patients had complex comminuted fractures, but we emphasize that there was no analysis of radiographic images for agreement between evaluators on their simple or complex trait, and this can be considered a weakness of the study. Finally, we believe that this technique must be disseminated in Brazil for external validation and subsequent evaluation in studies with higher levels of evidence and comparison with conventional open reduction procedures.

Conclusion

The MIO technique was satisfactory for the treatment of comminuted midshaft clavicle fracture, with a high consolidation rate and a low complication rate.

Financial Support

There was no financial support from public, commercial, or non-profit sources.

Conflict of Interests

The authors have no conflict of interests to declare.

References

- McKee MD. Fraturas da clavícula. In: Court-Brow CM, Heckman JD, McQueen MM, Ricci WM, Tornetta P 3rd, McKee MD, editores. Fraturas em adultos de Rockwood & Green. 7th ed. Rio de Janeiro: Manole; 2014:1106–1141
- Liu W, Xiao J, Ji F, Xie Y, Hao Y. Intrinsic and extrinsic risk factors for nonunion after nonoperative treatment of midshaft clavicle fractures. *Orthop Traumatol Surg Res* 2015;101(02):197–200
- Nowak J, Mallmin H, Larsson S. The aetiology and epidemiology of clavicular fractures. A prospective study during a two-year period in Uppsala, Sweden. *Injury* 2000;31(05):353–358
- Mirzatoioei F. Comparison between operative and nonoperative treatment methods in the management of comminuted fractures of the clavicle. *Acta Orthop Traumatol Turc* 2011;45(01):34–40
- Rugpolmuang L, Harnroongroj T, Sudjai N, Harnroongroj T. Comminution plays no role in worsening fracture healing of conservatively treated middle third clavicular fractures. *Acta Orthop Traumatol Turc* 2016;50(01):32–36
- Canadian Orthopaedic Trauma Society. Nonoperative treatment compared with plate fixation of displaced midshaft clavicular fractures. A multicenter, randomized clinical trial. *J Bone Joint Surg Am* 2007;89(01):1–10
- McKee RC, Whelan DB, Schemitsch EH, McKee MD. Operative versus nonoperative care of displaced midshaft clavicular fractures: a meta-analysis of randomized clinical trials. *J Bone Joint Surg Am* 2012;94(08):675–684
- Sökücü S, Menges Ö, Cetinkaya E, Parmaksızoğlu A, Kabukçuoğlu Y. Treatment of comminuted mid-diaphyseal clavicle fractures by plate fixation using a bridging technique. *Acta Orthop Traumatol Turc* 2014;48(04):401–405
- Robinson CM, Goudie EB, Murray IR, et al. Open reduction and plate fixation versus nonoperative treatment for displaced midshaft clavicular fractures: a multicenter, randomized, controlled trial. *J Bone Joint Surg Am* 2013;95(17):1576–1584
- Labronici PJ, Santos Filho FCD, Reis TB, Pires RES, Junior AFM, Kojima KE. Are diaphyseal clavicular fractures still treated traditionally in a non-surgical way? *Rev Bras Ortop* 2017;52(04):410–416
- Duncan SFM, Sperling JW, Steinmann S. Infection after clavicle fractures. *Clin Orthop Relat Res* 2005;439(439):74–78
- Der Tavitian J, Davison JNS, Dias JJ. Clavicular fracture non-union surgical outcome and complications. *Injury* 2002;33(02):135–143
- Böstman O, Manninen M, Pihlajamäki H. Complications of plate fixation in fresh displaced midclavicular fractures. *J Trauma* 1997;43(05):778–783
- Apivatthakakul T, Arpornchayanon O, Bavornratanevech S. Minimally invasive plate osteosynthesis (MIPO) of the humeral shaft fracture. Is it possible? A cadaveric study and preliminary report. *Injury* 2005;36(04):530–538
- Heitemeyer U, Kemper F, Hierholzer G, Haines J. Severely comminuted femoral shaft fractures: treatment by bridging-plate osteosynthesis. *Arch Orthop Trauma Surg* 1987;106(05):327–330
- Livani B, Belangero WD. Bridging plate osteosynthesis of humeral shaft fractures. *Injury* 2004;35(06):587–595
- Sohn HS, Kim BY, Shin SJ. A surgical technique for minimally invasive plate osteosynthesis of clavicular midshaft fractures. *J Orthop Trauma* 2013;27(04):e92–e96
- Jung GH, Park CM, Kim JD. Biologic fixation through bridge plating for comminuted shaft fracture of the clavicle: technical aspects and prospective clinical experience with a minimum of 12-month follow-up. *Clin Orthop Surg* 2013;5(04):327–333
- Orfale AG, Araújo PM, Ferraz MB, Natour J. Translation into Brazilian Portuguese, cultural adaptation and evaluation of the reliability of the Disabilities of the Arm, Shoulder and Hand Questionnaire. *Braz J Med Biol Res* 2005;38(02):293–302
- Smekal V, Deml C, Irenberger A, et al. Length determination in midshaft clavicle fractures: validation of measurement. *J Orthop Trauma* 2008;22(07):458–462
- Roy JS, MacDermid JC, Woodhouse LJ. Measuring shoulder function: a systematic review of four questionnaires. *Arthritis Rheum* 2009;61(05):623–632
- Sohn HS, Kim WJ, Shon MS. Comparison between open plating versus minimally invasive plate osteosynthesis for acute displaced clavicular shaft fractures. *Injury* 2015;46(08):1577–1584
- Wang X, Wang Z, Xia S, Fu B. Minimally invasive in the treatment of clavicle middle part fractures with locking reconstruction plate. *Int J Surg* 2014;12(07):654–658
- Nathe T, Tseng S, Yoo B. The anatomy of the supraclavicular nerve during surgical approach to the clavicular shaft. *Clin Orthop Relat Res* 2011;469(03):890–894
- Jiang H, Qu W. Operative treatment of clavicle midshaft fractures using a locking compression plate: comparison between minimally invasive plate osteosynthesis (MIPO) technique and conventional open reduction. *Orthop Traumatol Surg Res* 2012;98(06):666–671
- You JM, Wu YS, Wang Y. Comparison of post-operative numbness and patient satisfaction using minimally invasive plate osteosynthesis or open plating for acute displaced clavicular shaft fractures. *Int J Surg* 2018;56:21–25
- Asadollahi S, Hau RC, Page RS, Richardson M, Edwards ER. Complications associated with operative fixation of acute midshaft clavicle fractures. *Injury* 2016;47(06):1248–1252
- Kibler WB, Sciascia A, Wilkes T. Scapular dyskinesia and its relation to shoulder injury. *J Am Acad Orthop Surg* 2012;20(06):364–372
- Alzahrani MM, Cota A, Alkhalafi K, et al. Are clinical outcomes affected by type of plate used for management of mid-shaft clavicle fractures? *J Orthop Traumatol* 2018;19(01):8
- Silva FBA, Kojima KE, Silva JS, Mattar R Junior. Comparação entre o uso de placas e o de hastes flexíveis para a osteossíntese de fraturas do terço médio da clavícula: resultados preliminares. *Rev Bras Ortop* 2011;46(01):34–39