



Rosai-Dorfman disease and superinfection due to *Salmonella enterica* and *Mycobacterium avium* complex in a patient living with HIV

Alejandro Olmedo-Reneaum*, Aaron Molina-Jaimes, Eliezer Conde-Vazquez, Stefania Montero-Vazquez

Mexico

ARTICLE INFO

Article history:

Received 7 October 2019
Received in revised form 2 January 2020
Accepted 3 January 2020

Keywords:

Rosai-Dorfman disease
Superinfection
Salmonella
MAC
HIV

ABSTRACT

Rosai-Dorfman disease (RDD) a rare, non-malignant disease of histiocytic proliferation usually presents as a painless lymphadenopathy. It has been associated with autoimmune diseases, viral infections, and malignancies. Management is the treatment of underlying disease. Here we present the case of a patient with HIV infection who presented with massive splenomegaly and lymphadenopathy.

© 2020 The Author(s). Published by Elsevier Ltd. This is an open access article under the CC BY-NC-ND license (<http://creativecommons.org/licenses/by-nc-nd/4.0/>).

Introduction

Rosai-Dorfman disease (RDD) is a non-malignant disease of histiocytic proliferation. RDD is a rare, self-limiting disorder that usually affects children, adolescents, and young men; however, it can occur in adults and the elderly. Its main clinical manifestation is a painless cervical lymphadenopathy, though other lymph nodes can be involved. Involvement in extranodal sites, such as the skin, brain, pericardium, scrotum, bone, eyes, upper respiratory tract, breast, heart, and thyroid have also been described [1–4]. Infection by human herpesvirus 6 and Epstein Barr virus [5] has been suggested as a possible etiology of this disease. It has also been associated with infection by the human immunodeficiency virus [6]. Immunopathology of RDD could be linked to viral infections that can create an immunologic environment that will result in the activation of the histiocyte–macrophage system. Here we present the case of a patient with chronic HIV infection in virological control, who had progressive splenomegaly, and multiple lymphadenopathies.

Case report

A 31-year-old, policeman, MSM, without any other previous relevant history, had a wasting syndrome of approximately 6

months of evolution. He was diagnosed with HIV infection in November 2017, his baseline viral load was 136,922 copies/mL (5.1log) and his CD4 cell count was 29 cells / mm³ (1 %). Two months later, he started antiretroviral treatment (ART) with dolutegravir/emtricitabine/tenofovir disoproxil and also received prophylaxis with trimethoprim/sulfamethoxazole 160/800 mg qd and fluconazole 100 mg po qd. Three months after starting ART, his viral load was undetectable and the CD4 count was 46 (2 %). His vital signs and somatometry were as follows: BP 105/70 mmHg, HR 105 bpm, 23 RR, Temp 36.8 °C, 96 % oxygen saturation, weight 71.2 kg and size 1.73 m, BMI 23.8. He was re-evaluated at 4 months with weight loss, nocturnal diaphoresis, and anorexia. On physical examination, hepatomegaly was found 5 cm below the costal margin and grade IV splenomegaly (beyond the navel line and reaching the left iliac fossa). The patient was admitted to our hospital for diagnosis workup.

Peripheral blood cultures were performed, all without growth. Bone marrow aspiration and biopsy reported the following: cellularity 80 %, myeloid-erythroid series with a 3: 1 ratio, myeloid with adequate maturation, erythroid with normal characteristics, fibrosis was not identified. Ziehl Neelsen, PAS, Gram, Grocott and Wright stains did not show microorganisms. Bone marrow culture was negative for bacteria, fungi and mycobacteria.

Abdominal tomography showed massive splenomegaly, hepatomegaly and multiple retroperitoneal and inguinal lymphadenopathy (Fig. 1). A right inguinal lymph node biopsy was performed. The cultures and inguinal lymph node tissue stains

* Corresponding author.

E-mail address: a_olmedo38@hotmail.com (A. Olmedo-Reneaum).

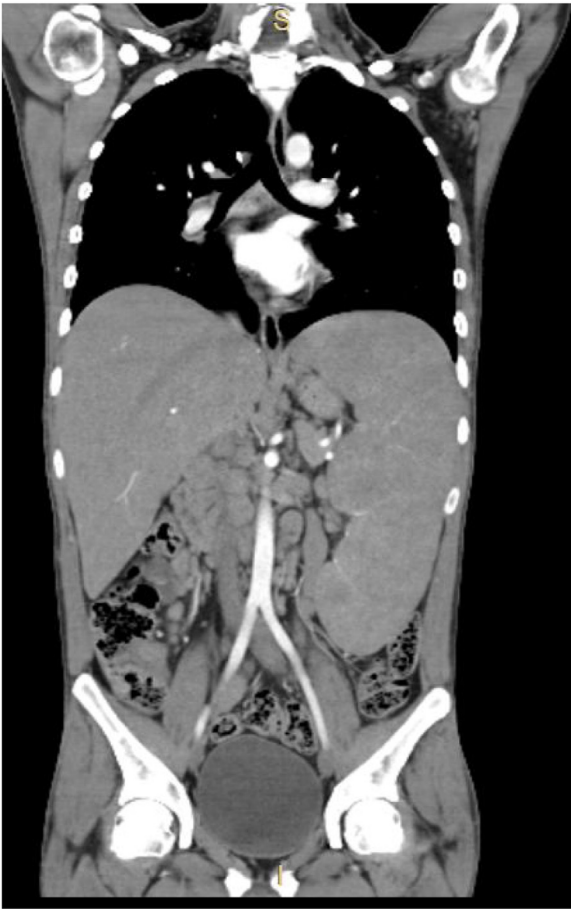

Fig. 1. Coronal section of contrast CT scan with IV contrast, showing massive splenomegaly and multiple enlarged retroperitoneal nodes.

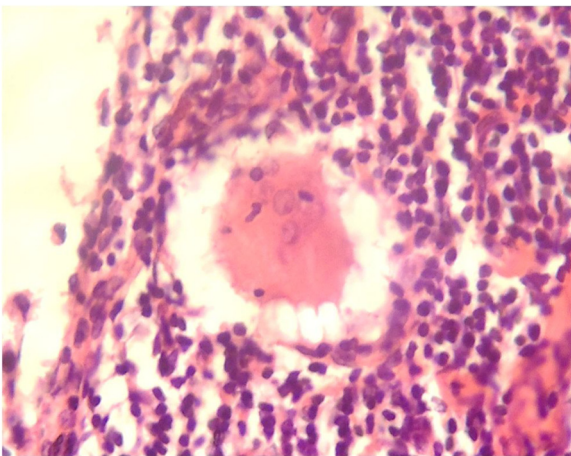


Fig. 2. Inguinal lymph node H&E stain showing multinucleated histiocytes with emperipolesis.

were negative for bacteria, mycobacteria and fungi. Histopathology showed sinusoidal histiocytosis and emperipolesis, the diagnosis of Rosai-Dorfman disease was made (Fig. 2).

Treatment was started with prednisone at a dose of 1 mg/kg/day. One month after he showed clinical and biochemical improvement. He gained 4 kg of weight. Fever, diaphoresis, and splenic pain had

stopped. He was lost to follow up for three months when he presented with splenic pain, persistent fever, weight loss, nocturnal diaphoresis, and dysentery. The onset of abdominal symptoms was associated with the intake of raw food on a street establishment in Tijuana. Because of this symptomatology, he went to the emergency department of our hospital. He presented with anemia, abdominal pain predominantly in the left hemiabdomen, and massive splenomegaly, the spleen was stony and painful. No dermatological lesions nor cervical, axillary or inguinal lymphadenopathy was found. Abdominal tomography showed massive splenomegaly, as well as multiple zones of splenic hypodensities suggestive of splenic infarcts and probable abscesses.

Bone marrow aspirate and culture were performed, it showed presence of Gram-negative bacilli with bipolar staining and subsequently grew on Salmonella-Shigella agar forming black colonies, and was identified as *Salmonella enterica* resistant to ampicillin only (Fig. 3a). Ziehl Neelsen's staining of bone marrow culture showed acid-fast bacilli (Fig. 3b). Gene Xpert for *Mycobacterium tuberculosis* was negative. Treatment was started with ceftriaxone, isoniazid, pyrazinamide, ethambutol, rifampin and clarithromycin. The dose of dolutegravir was doubled to 50 mg every 12 h. The HIV viral load at this time was <40copies/mL. Diagnostic-therapeutic splenectomy was performed. The spleen weighed 4.2 kg, measured 32 × 20 × 17 cm, with a white nodular surface, showing an anterior subcapsular abscess. No nodes were identified in the hilum. The histological analysis showed a splenic abscess, a generalized granulomatous process with multiple Gram positive bacilli with segmental staining and acid-alcohol resistant, which were later identified as *Mycobacterium avium* complex (Fig. 4a and b). Despite antimicrobial treatment, the patient developed multiple organ failure and died two weeks after performing the surgical procedure.

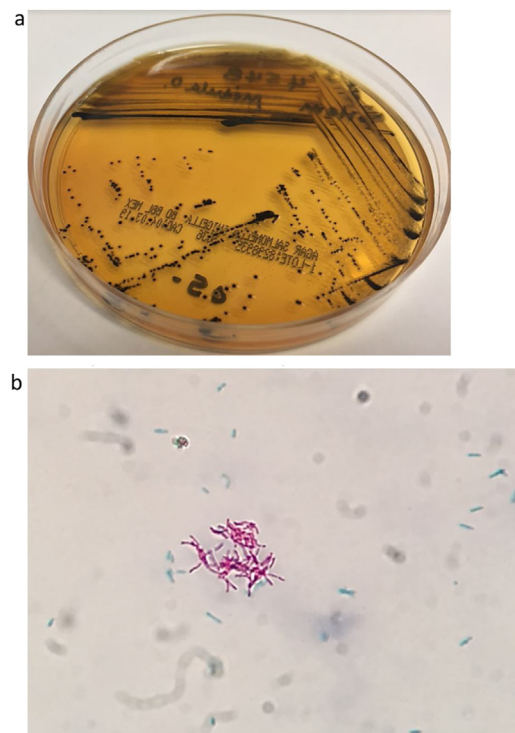


Fig. 3. a) Salmonella-Shigella agar, showing black colonies, identified as *Salmonella enterica*. b) Ziehl Neelsen stain of bone marrow mycolytic culture. Acid-fast resistant bacilli (pink color) and blue bacilli (*Salmonella enterica*). (For interpretation of the references to colour in this figure legend, the reader is referred to the web version of this article).

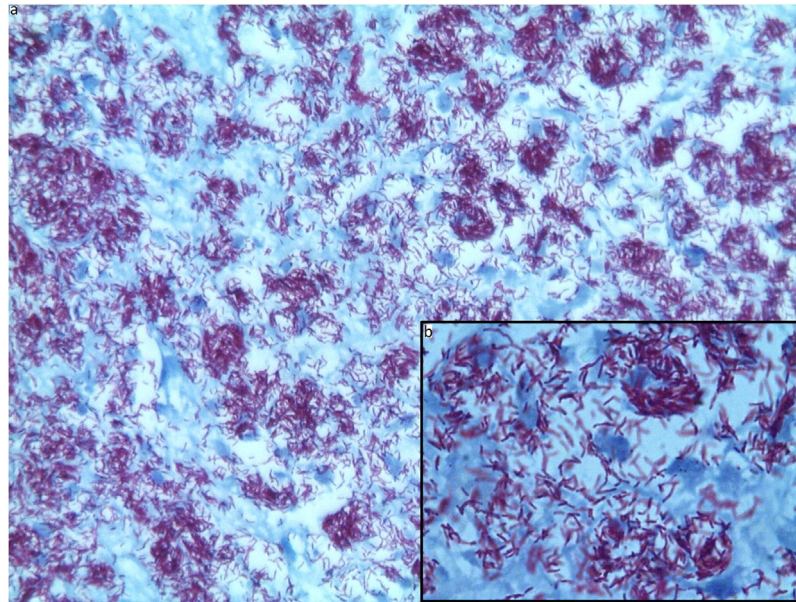


Fig. 4. a–b. Ziehl-Neelsen's stain of histopathology of spleen.40x-100x.

Table 1
Rosai-Dorfman disease in patients LWH cases reported in the literature.

Case	Age/sex	Lesion localization	Serology and/or molecular test	CD4 count/HIV viral load	Histopathology findings	Treatment/Outcome	ref
2	-/-	Skin, nasal nodules	—	204/NR	—	—	[5]
1	31/F	Cervical, submandibular, and axillary lymph nodes	EBV, HHV6, HSV 1 and 2, CMV: Neg	423/NR	Large histiocytes, emperipolesis, SP100+/CD68-/Alpha-1-antichymotrypsin+	Excision/on follow-up	[6]
3	28/F	Skin: erythematous papules on face	HHV6+, EBV IgG +	NR/NR	Emperipolesis Sp100+ CD 68, CD1a-	Topical steroids/improvement	[7]
4	56/F	Maxillary, malar	EBV + CMV+ HBV+	350/10,000	Pale histiocytosis, emperipolesis, SP100+ CD68+	Subtotal maxillectomy	[8]
5	Child/F	Skin, liver, spleen, kidneys	CV CMV+	490/750,000	Foamy histiocytes, Sp100+, CD68+	Metilprednisolone/death	[9]
6	40/M	Cervical lymph node, parotid	—	—	Emperipolesis	Chemotherapy/improvement/lost on follow-up	[10]
7	49/M	Eye, retroperitoneum, axillary lymph node	HSV - VZV - CMV -	361/25	Emperipolesis SP100+	Topical and oral corticosteroids/improvement	[11]
9	19/M	Cervical lymph nodes	HBV- STS-	610/150,000	Emperipolesis Sp100+ CD68+	Lost on follow-up	[12]
10	31/M	Cervical, retroperitoneal, and inguinal lymph nodes, and spleen.	HBV -, CMV -, VZV -	29/ <40	Emperipolesis Sp 100+ CD68+	Prednisone/death due to superinfection	—

Discussion

The etiology of RDD is not fully understood but is thought to be related to immune dysregulation. It has been associated with viral infections, usually herpes viruses, autoimmune disease and haematological malignancies [7]. If an underlying cause is established, then this will guide treatment. However, in the absence of an underlying cause, treatment is not well established. Treatment is required if there is compromise of vital organs due to compression by lymph nodes or other organs, like in this case, where the patient had massive splenomegaly and mechanical respiratory insufficiency. Unfortunately, our patient lost follow-up and developed a fatal dual infection with Salmonella and Mycobacterium avium complex that, despite the treatment, caused his death. To our best knowledge, this is the tenth case of RDD in a patient LWH reported in medical literature (Table 1).

Funding

None.

Consent

Written informed consent was obtained from the patient for publication of this case report and accompanying images. A copy of the written consent is available for review by the Editor-in-Chief of this journal on request.

Author contribution

-Aarón Molina-Jaimes, study design, data collection
-Alejandro Olmedo-Reneaum, data analysis, writing, and corresponding author
-Eliezer Conde-Vazquez, contributor
+Stefania Montero-Vazquez, contributor

CRediT authorship contribution statement

Alejandro Olmedo-Reneaum: Writing - original draft. **Aaron Molina-Jaimes:** Investigation, Writing - original draft. **Eliezer Conde-Vazquez:** Resources. **Stefania Montero-Vazquez:** Investigation.

Declaration of Competing Interest

None.

References

- [1] Lüdemann W, Banan R, Samii A, Koutzoglou M, Di Rocco C. Cerebral rosai-dorfman disease. *Childs Nerv Syst* 2015;31:529–32.
- [2] Lao IW, Dong Y, Wang J. Rosai-Dorfman disease of the pericardium: a case report and review of literature. *Int J Clin Exp Pathol* 2014;7:3408–12.
- [3] Cole AJ, Chen C, Lorsbach RB, Honnebler BM, Gardner JM, Shalin SC. Extranodal Rosai-Dorfman disease in the scrotum of a 13-month male: a unique anatomic presentation. *Diagn Cytopathol* 2015;43:40–4.
- [4] Orvets ND, Mayerson JL, Wakely [60_TD\$DIFF][61_TD\$DIFF]r. PE. Extranodal Rosai-Dorfman disease as solitary lesion of the tibia in a 56-year-old woman. *Am J Orthop (Belle Mead NJ)* 2013;42:420–2.
- [5] Perez A, Rodriguez M, Febrer I, Aliaga A. Sinus histiocytosis confined to the skin. Case report and review of the literature. *Am J Dermatopathol* 1995;17:384–8.
- [6] Delacretaz F, Meuge-Moraw C, Anwar D, Borisch B, Chave JP. Sinus histiocytosis with massive lymphadenopathy (Rosai Dorfman disease) in an HIV positive patient. *Virchows Arch A Pathol Anat Histopathol* 1991;419:251–4.
- [7] Perry BP, Gregg CM, Myers S, Lilly S, Mann KP, Prieto V. Rosai-Dorfman disease (extranodal sinus histiocytosis) in a patient with HIV. *Ear Nose Throat J* 1998;77:855–8.
- [8] Pitamber HV, Grayson W. Five cases of cutaneous Rosai-Dorfman disease. *Clin Exp Dermatol* 2019;28:17–21.
- [9] Dickson-Gonzalez SM, Jimenez L, Barbella RA, Mota-Gamboa JD, Rodriguez-Morales AJ, Vals J, et al. Maxillofacial Rosai-Dorfman disease in a newly diagnosed HIV-infected patient. *Int J Infect Dis* 2008;12:219–21.
- [10] Nastouli E, Carroll E, Malone M, Riordan A, Lyall H. Fatal histiocytic proliferative disorders in paediatric HIV infection with cytomegalovirus end-organ disease. *Br J Haematol* 2009;146:580–2.
- [11] Khuraijam SD, Myrthong BG, Khuraijam S, Tamphasana RK, Sharma DC. Rosai-Dorfman disease in a HIV-positive patient. *JACM* 2012;13:336–7.
- [12] Monroe AK, Burkholder BM, Butler NJ, Duffield AS. Sclerouveitis associated with Rosai-Dorfman disease in an HIV-infected patient. *Ocul Immunol Inflamm* 2014;22:236–8.