


## ORIGINAL ARTICLE

# Acne scar treatment using high-energy fractional nanosecond Q-switched 1064 nm laser

Nasrin Mani MD<sup>1</sup> | Anže Zorman<sup>2</sup> <sup>1</sup>La Jolla Cosmetic Laser Clinic, La Jolla, CA, USA<sup>2</sup>Medilase Ljubljana Slovenia, Ljubljana, Slovenia**Correspondence**

Anže Zorman, Medilase, Ljubljana, Slovenia, Tbilisijaska ulica 59 Ljubljana 1000, Slovenia.

Email: zormanze@gmail.com

**Funding information**

None

**Abstract**

**Aims:** The objective of this study was to evaluate the effectiveness and safety of high-energy ablative fractional nanosecond Q-switched 1064 nm laser therapy for acne scars.

**Material and methods:** Forty-six patients aged from 16 to 69 years and of Fitzpatrick skin type from 2 to 4 were included in this retrospective study. Multiple passes were delivered with a fractional 1064-nm handpiece at high energy. Results were evaluated using blinded analysis of patient before and after photographs and also by evaluating patient satisfaction.

**Results:** Most patients (75%) were improved or very improved according to blinded evaluation. Patient satisfaction was high. No hypo/hyperpigmentation, scarring, or any other side effects were reported by any of the patients.

**Conclusions:** The study demonstrated good clinical outcomes in facial acne scar management with a high patient satisfaction rate and no adverse side effects.

**KEYWORDS**

acne scars, fractional, laser, Q-switched 1064 nm

## 1 | INTRODUCTION

Acne vulgaris is one of the most common skin diseases; it will affect one out of two people in their lifetimes and about 80% of people aged between 11 and 30 years.<sup>1-3</sup> Acne scarring, a common complication, develops to some degree in the majority of acne sufferers.<sup>4</sup> Scars are divided into three general categories: ice-pick scars, rolling scars, and boxcar scars<sup>5</sup> and are a result of excessive inflammation, acne severity, physical manipulation of the skin, and a delay in seeking adequate treatment.<sup>3</sup> It affects people both physically and emotionally worldwide, regardless of sex, age, and ethnicity.<sup>2,6</sup> There is also a negative societal perception of acne scars.<sup>7</sup> Unfortunately, many cases of acne remain untreated or are treated sub-optimally, and patients that later develop acne

scarring often need acne scarring treatment. None of the currently available treatments achieve a complete resolution of scars, and thus, prevention of scarring by early and aggressive acne treatment is the best option.<sup>8</sup> There are many different treatment modalities for acne scarring, such as chemical peeling, retinoids, dermabrasion, microneedling, subcision, surgical excision, dermal fillers, platelet-rich plasma (PRP), and different energy-based devices. Evidently, a combination of various treatment modalities gives better results than monotherapy.<sup>8,9</sup> Energy-based devices, such as intense pulsed light (IPL), radiofrequency, and lasers, have gained popularity as part of the scar treatment arsenal in recent years. The ablative 2940 nm Er:YAG and 10 600 nm CO<sub>2</sub> lasers have been used in treating various types of scars. However, due to adverse effects such as edema, erythema, dyspigmentation,

This is an open access article under the terms of the Creative Commons Attribution-NonCommercial License, which permits use, distribution and reproduction in any medium, provided the original work is properly cited and is not used for commercial purposes.

© 2021 The Authors. *Journal of Cosmetic Dermatology* published by Wiley Periodicals LLC.

and significant downtime, a search for a better alternative continues.<sup>10–14</sup> One of the options to reduce the downtime and risk for side effects is to use a non-ablative wavelength and fractional delivery. In recent years, new studies have shown that the fractional Q-switched (nanosecond and picosecond) laser can be highly effective in the treatment of acne scars and other indications with minimal side effects. However, most of these studies have used lower, non-ablative fluences.<sup>15–20</sup> The aim of our study was to assess the efficacy and safety of Nd:YAG laser treatments using a higher, ablative fluence that in our experience gives better results with fewer sessions when compared to lower, non-ablative fluence treatments.

## 2 | METHODS

### 2.1 | Patients

Forty-six subjects (9 males and 37 females) that had been treated for acne scars at La Jolla Cosmetic Laser Clinic (California, USA) between February 2018 and October 2020 using the treatment protocol described below were included in this retrospective study. The age of the participants ranged from 16 to 69 years (average 34.8 years) with Fitzpatrick skin types from 2 to 4. Inclusion criteria were as follows: (1) age  $\geq 16$  years, (2) presence of acne scarring, (3) no severe underlying diseases, and (4) willingness to follow-up and comply with the study protocol. Exclusion criteria included untreated and active/ongoing acne vulgaris or those patients who had infection present in the area of the treatment despite anti-acne treatment, immunocompromised status, history of skin cancer, recurrent herpes viral infection, oral intake of vitamin A derivatives in the past 3 months, photosensitizing drug use, history of chemical peeling 1 month prior to the study, facial laser treatment in the past 3 months, history of keloids, photosensitivity, pregnancy or breastfeeding status. Written consent was received from the participants or their surrogates before undergoing treatment. The study was conducted according to the Helsinki declaration.

### 2.2 | Treatment protocol

Patients received anti-viral prophylaxis (Acyclovir 800 mg PO twice daily) for 3 days starting on the day of the treatment in order to prevent possible herpetic outburst. No other pre-treatment was used. The treatment was delivered with the nanosecond 1064-nm Nd:YAG laser (StarWalker MaQX, Fotona) with a fractional 1,064-nm handpiece (FS20A) at an energy level of 30–75 mJ/pixel and MaQX-10 mode. Multiple passes (2–6) over the treated area have been performed according to the severity of scarring and the patient's immediate response. Protective eyewear was used by all personnel and the patient during all treatments. Use

of topical PRP application over the treated area immediately after the procedure to speed up and improve the healing process was encouraged. Patients were recommended to use topical antibiotic (Clindamycin) for 5 days and continue with Acyclovir. They were also instructed not to undergo any other anti-scarring procedure until the final follow-up visit, as well as to avoid sun exposure and apply sunscreen. Patients received multiple treatments until satisfactory results were achieved. The interval between the treatments was not predetermined and was chosen according to the patient's availability and wishes, but it was not shorter than required for complete healing of the treated area (approximately 10 days).

All patients were encouraged to give consent for standardized photographs to be obtained before the initial treatment and after satisfactory results were achieved. Lighting conditions and patient positioning were identical every time. Three non-involved assessors who were unaware of the treatment methods were first asked to determine the correct sequence of before/after photographs. If they failed to determine the right sequence, a score of 5 (worsened patient) was applied. Secondly, the pre-treatment and post-treatment(s) photographs were compared for the improvement of scarring. A global assessment improvement scale (GAIS) was used, where 1= exceptional improvement, 2= very good improvement, 3= improvement, 4= no change, and 5= worsening. The patients were also asked to rate their satisfaction on a 0–3 scale, where 0= not at all satisfied, 1= somewhat satisfied, 2= satisfied, and 3= very satisfied. Student's *t*-test was used to compare length of recovery (erythema and re-epithelization) between the group where PRP was used and the group without the use of topical PRP after the treatment. A chi-square test of independence was performed to examine the relation between PRP use and self-reported patient satisfaction.

## 3 | RESULTS

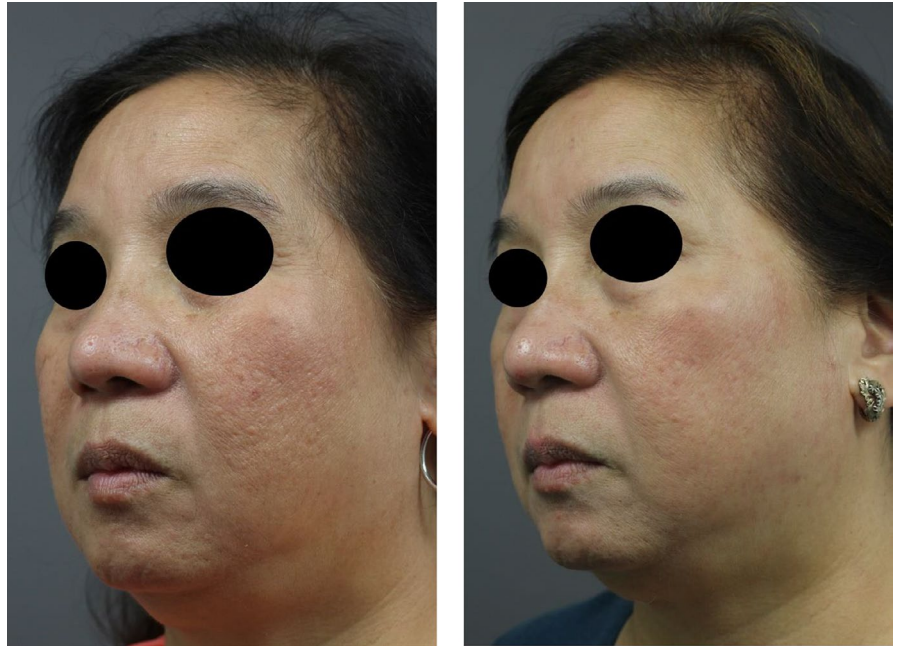Overall, a total of 46 patients were included in our final analysis (37 females and 9 males). The patients' ages ranged from 16 to 69 years (mean  $35 \pm 12$  years). Most of the patients were Hispanic or Asian and would fit into Fitzpatrick type II to IV classifications. Twenty-one patients out of 46 decided for the application of topical PRP.

The mean number of sessions was  $1.7 \pm 0.9$  (range 1–4); see Table 1. The treatment interval was not predetermined and therefore ranged from 22 days to a year with an average  $92 \pm 89$  days. All patients recovered very quickly, re-epithelization took  $2.3 \pm 0.8$  for those patients where PRP was used and  $2.4 \pm 0.9$  days when no PRP

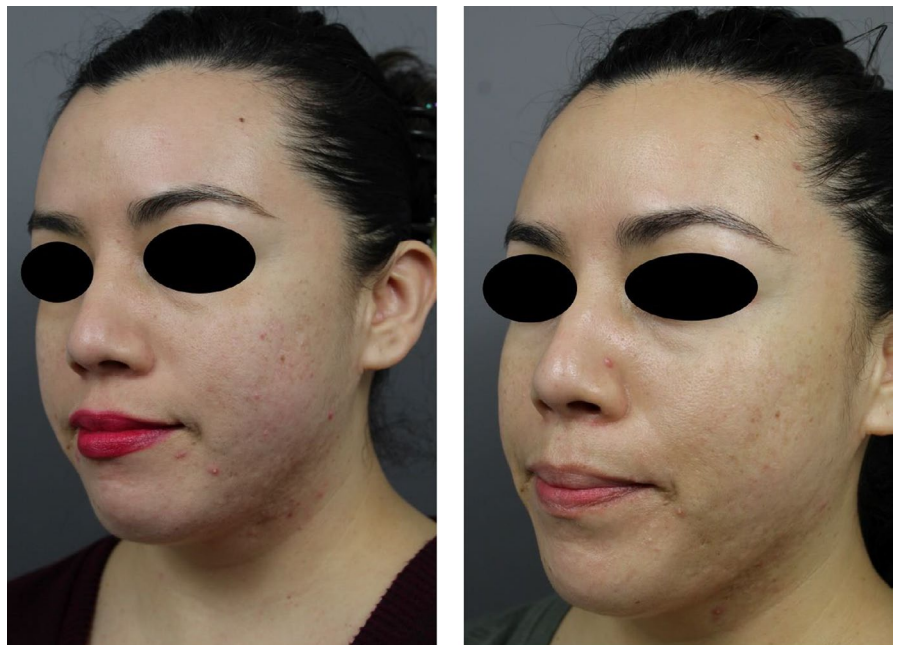TABLE 1 Number of treatments needed

# of treatments	1	2	3	4
# of patients	23	14	7	2

**FIGURE 1** Patient #1: before and 2 weeks after the second procedure



**FIGURE 2** Patient #2: before and 4 months after a single procedure



was used. The redness faded on the 9th day on average ( $9.2 \pm 2.5$  with PRP and  $9.3 \pm 2.8$  without PRP). No hypo/hyperpigmentation, scarring, or any other side effects were reported by any of the patients.

Twelve pairs of high quality before/after photos were available in our database (Figures 1, 2, and 3). The photographs were taken 1–6 months after the final procedure (average: 3.2 months). A correct blinded before/after recognition was achieved by all 3 blinded assessors in 75% of cases; in the remaining 25% of cases, 2 out of the 3 assessors recognized the correct sequence. Most patients (75%) were improved or very improved according to blinded evaluation

(see Table 2). Only 20 patients were available for the satisfaction survey. Self-rated satisfaction ranged from 0 to 3 with a mean  $2.1 \pm 0.64$  (see Table 3). A chi-square test of independence showed that there was no significant association between PRP use and self-reported patient satisfaction,  $X^2(1, N = 20) = 0.09, p = 0.96$ .

#### 4 | DISCUSSION

This is the first study, to our knowledge, to report on the efficacy of the high-fluence 1064 nm-nanosecond laser and diffractive lens



**FIGURE 3** Ablation holes over a tattooed area as seen through dermatoscopy (dermatoscopic photograph from a patient not related to this study, Courtesy of Fotona)

**TABLE 2** Scar improvement graded by 3 blinded assessors (GAIS)

Blinded evaluation	N = 12	
1-Exceptional improvement	0	0%
2-Very good improvement	3	25%
3-Improvement	6	50%
4-No change	3	25%
5-Worsening	0	0%

**TABLE 3** Patient satisfaction

Patient satisfaction	N = 20	
3-Very satisfied	5	25%
2-Satisfied	12	60%
1-Somewhat satisfied	3	15%
0-Not satisfied	0	0%

array technology in the management of facial acne scarring. The high energies per pixel used in this method enable ablation of the treated skin islets using a nanosecond Q-switched Nd:YAG laser, representing a novel approach to acne scar treatment that combines the benefits of surface ablation and deep tissue penetration, both contributing a role in the scar revision process. We have shown that this method produces significant clinical improvement of acne scars and results in high patient satisfaction.

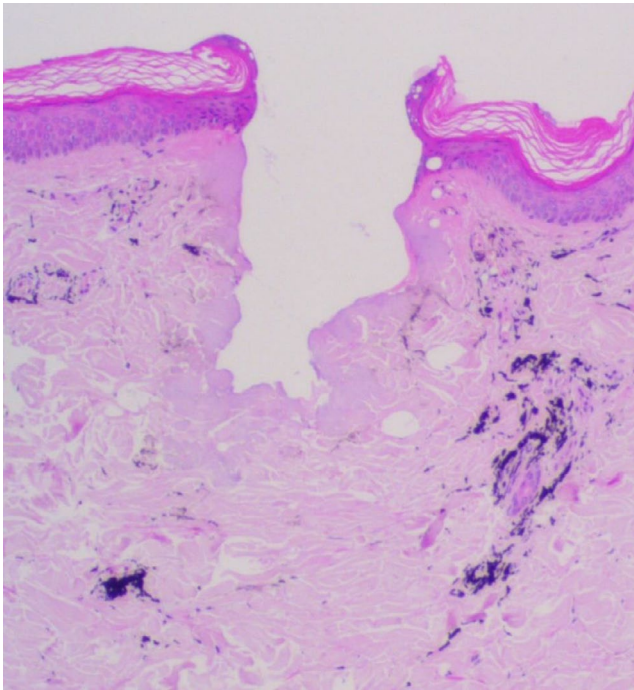
Akerman et al.<sup>18</sup> have reported an overall moderate improvement in scar appearance and a statistically significant decrease in scar severity in post-surgical scars using a similar approach

with the nanosecond 1064 nm wavelength in a fractional delivery mode, but with lower energies per pixel. Histological changes (multicellular and wavy epidermis, dense collagen fibers, and collagen regeneration in the dermis) were also observed in a study by Urdiales-Galvez et al.<sup>21</sup> where a fractional approach for the improvement of acne scars was used also with picosecond lasers (around 10 times shorter pulses) of the same wavelength, showing good results. Manuskiatti et al.<sup>22</sup> treated 26 patients with atrophic acne scars and showed improvement in scar volume and smoothing of the skin. Koren et al.<sup>23</sup> reported an average 50%–75% improvement in 16 patients with hyperpigmented scars, whereas Choi achieved 25%–49% improvement in 24 patients with hypertrophic scars.<sup>24</sup> Similar improvement (25%–50%) was also reported by Brauer who included 17 patients in the study.<sup>20</sup> A small study with 4 patients reported ECCA score improvement of 57.9% in using fractional picosecond 1064 nm with atrophic acne scars.<sup>16</sup>

Our study on acne scars included a relatively high number of patients ( $n = 46$ ) in comparison with all others using a similar approach in treating acne scarring. Clinical efficacy was evaluated by three blinded assessors that were able to determine the correct before/after sequence in almost all of the cases showing that improvement was substantial and obvious. Even though we applied a score of 5 (worsened patient) in the cases of an incorrect evaluation of before/after sequence, 75% of patient fell into the improved or very improved category. Photographs for blinded assessment were taken at the last follow-up, which was 1–6 months (average 3.2 months) after the final treatment. Downtime was minimal; patients experienced transient erythema, mild edema and some crusting over the next couple of days post-treatment. Re-epithelization on average happened on the second/third day and erythema resolved by day 9 in comparison with standard ablative treatments, where erythema can last a few weeks with Er:YAG and even up to half a year with CO<sub>2</sub> resurfacing.<sup>13,25,26</sup> Our previous personal experience when ablative laser treatments are performed was that the use of PRP after the treatment will shorten the recovery time and improve the outcome. This has also been confirmed by different studies.<sup>27–29</sup> However, we have not been able to show statistically significant difference with the use of PRP in this study since redness disappeared and re-epithelization occurred in the same amount of time in both groups. The procedure proved to be patient friendly since 85% of the patients were satisfied or very satisfied with the treatment and treatment outcome. Minimal preparation was required, with the face cleansed to remove any makeup or excess sebum before initiating treatment. Patients were not asked about a pain score specifically, but we can assume it was minimal since none of the patients required any pre-treatment anesthesia or cooling for analgesia during the treatment sessions, which are usually needed for standard ablative fractional treatments. The majority of our patients were of a darker skin type (namely Hispanic or Asian) who are more likely to develop adverse side effects (e.g.,



hyperpigmentation).<sup>26,30</sup> However, no adverse side effects were reported, so we can conclude that fractional Q-switched 1064 nm treatment as proposed in this study is safe for all skin types. This improvement in the safety profile and reduction in downtime is achieved by the use of fractionalization of the laser beam. A specialized diffractive lens array was used to alter the distribution

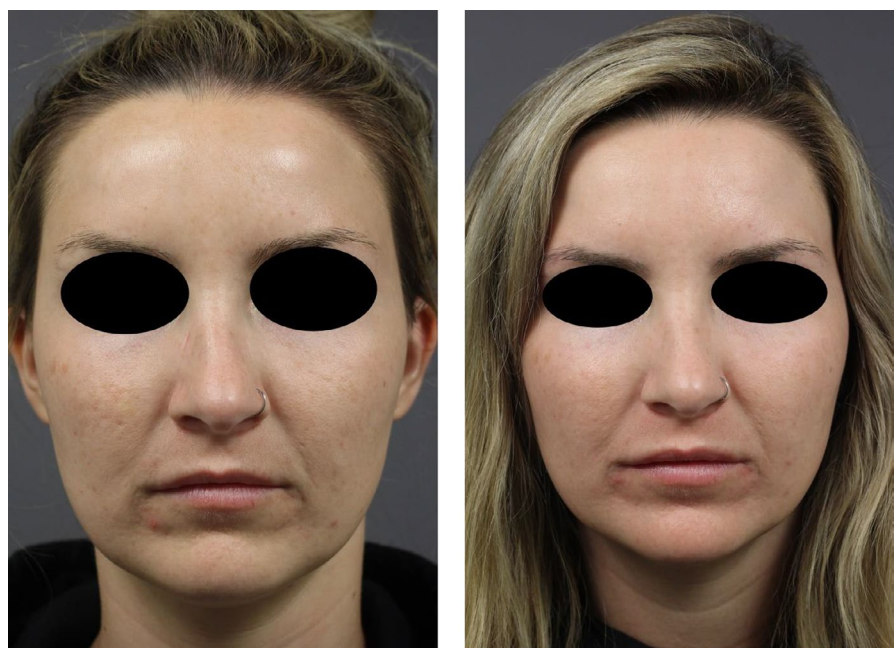

**FIGURE 4** Cross section of an ablation hole in a tattooed area (histology slide from a patient not related to this study, Courtesy of Fotona)

of energy delivered to the skin. Standard, that is full-beam handpieces deliver the energy in a uniform fashion. In contrast, the handpiece and laser used in our study deliver high energy to 81 ( $9 \times 9$ ) pixels in a  $9 \times 9$  mm matrix. Practically, all of the energy is delivered directly to the 81 pixels (each around 100  $\mu$ m in diameter). This produces discrete areas of damage (microthermal treatment zones) and spares the surrounding tissue.<sup>31,32</sup> When a high energy per pixel is used, these microthermal treatment zones actually become points of ablation (see Figures 4 and 5). By using the FS20A handpiece, approximately 3% of the cutaneous surface area per laser shot is ablated, therefore multiple passes were performed to achieve around 15%–20% coverage, a density considered optimal for ablative fractional treatments. The strengths of this study are a high number of patients, and the use of subjective and objective for evaluation of the results. The limitations are that only not all participants gave consent for photography and only a part of them answered the post-treatment satisfaction questionnaire.

## 5 | CONCLUSION

It is important to find new and better, more tolerable ways with shorter downtime to treat acne scars because of the high prevalence of this problem in the general population. To our knowledge, this is the first reported study that demonstrates good clinical outcomes in facial acne scar management with the fractional nanosecond 1064 nm laser. Additional studies with even larger sample sizes, additional methods for objective outcome evaluation, histologic analyses, or split case studies are needed to confirm our findings and potentially improve the technique itself.



**FIGURE 5** Patient #3: before and 1 months after a single procedure

**CONFLICTS OF INTEREST**

N. Mani and A. Zorman have no conflict of interest.

**AUTHOR'S CONTRIBUTION**

N.M. carried out the laser treatments. A.Z. wrote the manuscript with support from N.M. Both authors conceived the original idea.

**ETHICAL APPROVAL**

It is a retrospective study, Ethics Review Board approval was not sought.

**CONSENT TO PARTICIPATE**

Informed consent was obtained from all individual participants included in the study.

**DATA AVAILABILITY STATEMENT**

Data sharing is not applicable to this article as no new data were created or analyzed in this study

**ORCID**

Anže Zorman  <https://orcid.org/0000-0003-3777-6497>

**REFERENCES**

- Goulden V, Stables GI, Cunliffe WJ. Prevalence of facial acne in adults. *J Am Acad Dermatol*. 1999;41(4):577-580.
- Greydanus DE, Azmeh R, Cabral MD, Dickson CA, Patel DR. Acne in the first three decades of life: an update of a disorder with profound implications for all decades of life. *Dis Mon*. 2021;67(4):101103.
- Connolly D, Vu HL, Mariwalla K, Saedi N. Acne scarring-pathogenesis, evaluation, and treatment options. *J Clin Aesthet Dermatol*. 2017;10(9):12-23.
- Layton AM, Henderson CA, Cunliffe WJ. A clinical evaluation of acne scarring and its incidence. *Clin Exp Dermatol*. 1994;19(4):303-308.
- Jacob CI, Dover JS, Kaminer MS. Acne scarring: a classification system and review of treatment options. *J Am Acad Dermatol*. 2001;45(1):109-117.
- Fried R, Wechsler A. Psychological problems in the acne patient. *Dermatol Ther*. 2006;19:237-240.
- Dréno B, Tan J, Kang S, et al. How people with facial acne scars are perceived in society: an online survey. *Dermatol Ther (Heidelb)*. 2016;6(2):207-218.
- Tuchayi SM, Makrantonaki E, Ganceviciene R, Dessinioti C, Feldman SR, Zouboulis CC. Acne vulgaris. *Nat Rev Dis Prim*. 2015;1:15029.
- Bhargava S, Cunha PR, Lee J, Kroumpouzou G. Acne scarring management: systematic review and evaluation of the evidence. *Am J Clin Dermatol*. 2018;19(4):459-477.
- Buhalog B, Moustafa F, Arkin L, et al. Ablative fractional laser treatment of hypertrophic burn and traumatic scars: a systematic review of the literature. *Arch Dermatol Res*. 2020;313(5):301-317.
- Verma N, Yumeen S, Raggio BS. *Ablative Laser Resurfacing*. : StatPearls Publishing; 2020.
- Zhang D-D, Zhao W-Y, Fang Q-Q, et al. The efficacy of fractional CO(2) laser in acne scar treatment: a meta-analysis. *Dermatol Ther*. 2020;34:e14539.
- Sadick NS, Cardona A. Laser treatment for facial acne scars: a review. *J Cosmet Laser Ther*. 2018;20(7-8):424-435.
- Cenk H, Sarac G. Effectiveness and safety of 2940-nm multifractional Er: YAG laser on acne scars. *Dermatol Ther*. 2020;33:e14270.
- Agarwal M, Velaskar S. Laser skin rejuvenation with fractional 1064 Q-switched Nd:YAG In 252 patients: an Indian experience. *J Cosmet Dermatol*. 2020;19(2):382-387.
- Choi ME, Paik SH, Lee WJ, et al. Treatment of acne scars with a fractional 1064-nm Nd:YAG picosecond laser and histopathologic findings. *Dermatol Ther*. 2020;33(3):e13297.
- Santos PA. Laser-induced optical breakdown - acne scars treatment. *LA&HA - J Laser Heal Acad*. 2018;2018:CB11.
- Akerman L, Solomon-Cohen E, Rozenblat M, Hodak E, Lapidot M, Levi A. 1064-nm Q-switched fractional Nd:YAG laser is safe and effective for the treatment of post-surgical facial scars. *Lasers Med Sci*. 2021;36(4):871-874.
- Chayavichitsilp P, Limtong P, Triyankulsri K, Pratumchart N. Comparison of fractional neodymium-doped yttrium aluminum garnet (Nd:YAG) 1064-nm picosecond laser and fractional 1550-nm erbium fiber laser in facial acne scar treatment. *Lasers Med Sci*. 2020;35(3):695-700.
- Brauer JA, Kazlouskaya V, Alabdulrazzaq H, et al. Use of a picosecond pulse duration laser with specialized optic for treatment of facial acne scarring. *JAMA Dermatol*. 2015;151(3):278-284.
- Urdiales-Gálvez F, Trelles MA, Martín-Sánchez S, Maiz-Jiménez M. Histopathological changes after experimental skin resurfacing using an improved fractional high-power 1064-nm Q-Switched Nd:YAG laser. *J Drugs Dermatol*. 2019;18(12):1261-1266.
- Manuskiatti W, Punyaratabandhu P, Tantrapornpong P, Yan C, Cembrano KAG. Objective and long-term evaluation of the efficacy and safety of a 1064-nm picosecond laser with fractionated micro-lens array for the treatment of atrophic acne scar in Asians. *Lasers Surg Med*. 2021;53(7):899-905.
- Koren A, Niv R, Cohen S, Artzi O. A 1064-nm neodymium-doped yttrium aluminum garnet picosecond laser for the treatment of hyperpigmented scars. *Dermatol Surg*. 2019;45(5):725-729.
- Choi YJ, Kim JY, Nam JH, Lee GY, Kim WS. Clinical outcome of 1064-nm picosecond neodymium-doped yttrium aluminum garnet laser for the treatment of hypertrophic scars. *J Cosmet Laser Ther*. 2019;21(2):91-98.
- Newman JB, Lord JL, Ash K, McDaniel DH. Variable pulse erbium:YAG laser skin resurfacing of perioral rhytides and side-by-side comparison with carbon dioxide laser. *Lasers Surg Med*. 2000;26(2):208-214.
- Alster TS, Lupton JR. Erbium:YAG cutaneous laser resurfacing. *Dermatol Clin*. 2001;19(3):453-466.
- Shin M-K, Lee J-H, Lee S-J, Kim N-I. Platelet-rich plasma combined with fractional laser therapy for skin rejuvenation. *Dermatol Surg*. 2012;38(4):623-630.
- Hui Q, Chang P, Guo B, Zhang Y, Tao K. The clinical efficacy of autologous platelet-rich plasma combined with ultra-pulsed fractional CO2 laser therapy for facial rejuvenation. *Rejuvenation Res*. 2017;20(1):25-31.
- Min S, Yoon JY, Park SY, Moon J, Kwon HH, Suh DH. Combination of platelet rich plasma in fractional carbon dioxide laser treatment increased clinical efficacy of for acne scar by enhancement of collagen production and modulation of laser-induced inflammation. *Lasers Surg Med*. 2018;50(4):302-310.
- Metelitsa AI, Alster TS. Fractionated laser skin resurfacing treatment complications: a review. *Dermatologic Surg*. 2010;36(3):299-306.
- Tannous Z. Fractional resurfacing. *Clin Dermatol*. 2007;25(5):480-486.
- Pozner JN, DiBernardo BE. Laser resurfacing full field and fractional. *Clin Plast Surg*. 2016;43(3):515-525.

**How to cite this article:** Mani N, Zorman A. Acne scar treatment using high-energy fractional nanosecond Q-switched 1064 nm laser. *J Cosmet Dermatol*. 2021;20:3907-3912. <https://doi.org/10.1111/jocd.14534>