

## Case Report

# Secretory Endometrial Adenocarcinoma: A Rare Sequelae in a Postmenopausal Woman Following Tamoxifen Therapy for Breast Cancer

Sonam Sharma

Department of Pathology,  
Kalpana Chawla Government  
Medical College, Karnal,  
Haryana, India

Submitted: 22-Jul-2019

Revised: 28-Feb-2020

Accepted: 05-May-2020

Published: 29-Sep-2020

### ABSTRACT

The double-edged sword effect of tamoxifen therapy on the female reproductive system including the breast is quite well established. However, it is still poorly understood at the molecular level which significantly affects the management of such patients receiving it in terms of therapeutics and prognosis. An experience of an extremely rare case of secretory endometrial adenocarcinoma developing due to the adverse effect of tamoxifen used for the treatment of breast cancer in a 60-year-old woman is being described herewith so as to create awareness among the dealing clinicians about the occurrence of rare histological types of endometrial cancer after long-term tamoxifen therapy. The approach to such a case, pathogenesis, differential diagnosis, and a brief literature review is also presented.

**KEYWORDS:** Breast cancer, endometrium, secretory adenocarcinoma, tamoxifen

## INTRODUCTION

Endometrial adenocarcinoma of secretory type is an uncommon variant of well-differentiated endometrioid adenocarcinoma and accounts for only 1%–2% of all endometrial carcinomas.<sup>[1]</sup> It is histologically a reminiscent of normal early secretory endometrium (17–22 days) and is frequently seen as a focus within the other endometrioid carcinomas rather than in pure form. It occurs predominantly in postmenopausal women and often presents with abnormal vaginal bleeding. Many known risk factors similar to those of other endometrial cancers and polyps such as obesity, hypertension, diabetes mellitus, exogenous estrogen as well as progestin administration, and nulliparity are associated with it.<sup>[2]</sup> However, tamoxifen therapy has been rarely implicated in its pathogenesis. Nevertheless, this tumor is generally low grade and has a good prognosis.<sup>[3]</sup> Herein is described an extremely uncommon case of secretory adenocarcinoma of the endometrium which developed in a 60-year-old woman due to the long-term intake of tamoxifen as a treatment for her breast cancer.

## CASE REPORT

A 60-year-old woman, G4 L4, presented to the gynecological outpatient department with the chief

complaint of bleeding per vaginum for the past 2 months. She had four full-term normal vaginal deliveries and had attained menopause 12 years back. Her medical history revealed that she had undergone right-sided mastectomy for breast cancer 8 years back, for which she had further received six cycles of chemotherapy and had been taking oral 10 mg tamoxifen twice daily since then. She was also diagnosed with hypertension 6 months back and was on oral telmisartan 40 mg/day. However, she denied any history of estrogen replacement therapy after menopause. Her family history of any cancer (breast/uterine/colon/ovarian) or of any other major illnesses was non-contributory. On general physical examination, she had an average built and was anemic. Per abdomen examination revealed mild tenderness in the lower abdomen with no evidence of ascites or any organomegaly. The external pelvis and per speculum examination was unremarkable. Bimanual pelvic examination revealed an open external os and a firm, mobile cervix. The uterus was anteverted, irregular, soft,

**Address for correspondence:** Dr. Sonam Sharma,

Department of Pathology, Kalpana Chawla Government Medical  
College, Karnal, Haryana, India.  
E-mail: drsonamsharma@gmail.com

This is an open access journal, and articles are distributed under the terms of the Creative Commons Attribution-NonCommercial-ShareAlike 4.0 License, which allows others to remix, tweak, and build upon the work non-commercially, as long as appropriate credit is given and the new creations are licensed under the identical terms.

For reprints contact: WKHLRPMedknow\_reprints@wolterskluwer.com

**How to cite this article:** Sharma S. Secretory endometrial adenocarcinoma: A rare sequelae in a postmenopausal woman following tamoxifen therapy for breast cancer. J Mid-life Health 2020;11:171-4.

### Access this article online

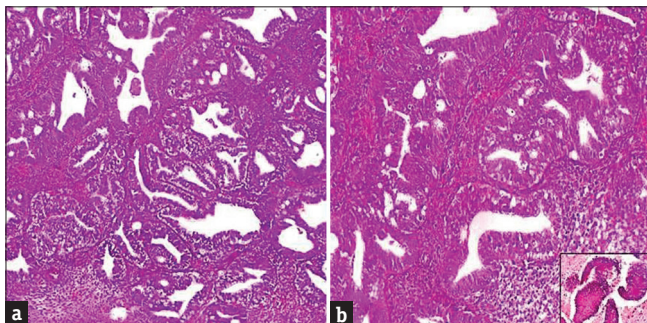
#### Quick Response Code:



Website: [www.jmidlifehealth.org](http://www.jmidlifehealth.org)

DOI: 10.4103/jmh.JMH\_104\_19

and enlarged with free bilateral fornices. No adnexal masses could be palpated. On per rectal examination, the rectal mucosa was free. All other systemic examinations were within the normal limits. Her routine hematological investigations revealed microcytic hypochromic blood picture. Urine and blood cultures were negative. Kidney and liver function tests were normal. Serum antibodies to the human immunodeficiency virus, hepatitis B surface antigen, and syphilis were negative. X-ray chest was normal. Transvaginal sonography (TVS) showed heterogeneous irregular endometrium of 22.2 mm thickness. Papanicolaou smear was performed which was negative for dysplasia or any malignancy. Fractional curettage specimen consisting of multiple fragments of soft, gray-brown material together measuring 2 cm × 1 cm × 1 cm in size was histopathologically examined. Microscopic sections showed a well-differentiated adenocarcinoma with dominant papillary and glandular patterns, consisting of tall columnar epithelial cells showing mild-to-moderate pleomorphism and having small, vesicular, and uniform nuclei with fine nuclear chromatin. The cytoplasm of these cells was clear and exhibited a severe degree of supranuclear and subnuclear vacuolization. The mitotic rate was 2–3/high-power field, and most of the mitosis was atypical. Areas of the stromal invasion were also evident [Figure 1]. A diastase sensitive Periodic Acid-Schiff (PAS) stain showed positivity with the presence of eosinophilic fine granular material in the vacuolated cells, and the stains for mucin were negative [Figure 1b-Inset]. On immunohistochemistry (IHC), tumor cells were positive for estrogen receptor (ER), progesterone receptor (PR), p53 and exhibited a high Ki-67 proliferation index of 60% [Figure 2]. Based on these histomorphological and immunohistochemical findings, a diagnosis of secretory adenocarcinoma of the endometrium was made. The patient underwent total hysterectomy with bilateral salpingo-oophorectomy.

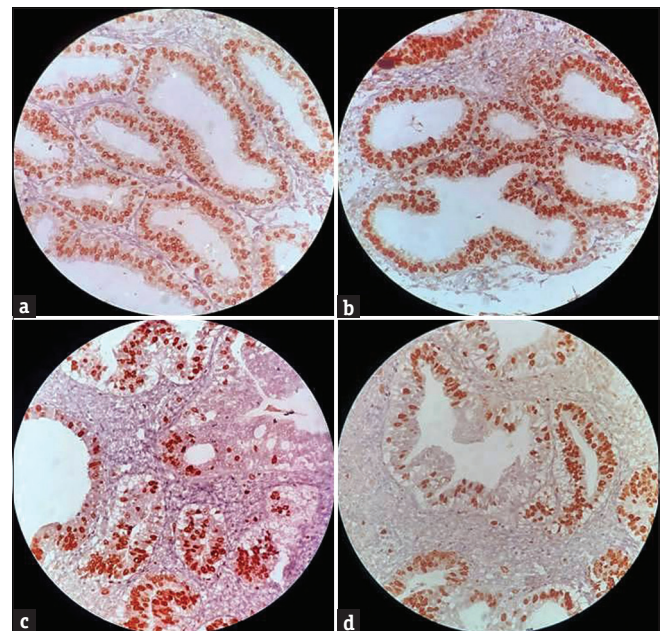


**Figure 1:** (a) Secretory endometrial adenocarcinoma (H and E, ×100). (b) Glandular crowding, epithelial stratification, atypical mitosis, and prominent intracytoplasmic subnuclear vacuolization (H and E, ×400). (Inset: Periodic Acid-Schiff-positive vacuoles [Periodic Acid-Schiff stain, ×100])

Grossly, the resected specimen consisted of a globoid uterus with the cervix and bilateral adnexae. The uterus along with the cervix measured 7 cm × 6 cm × 5 cm in size. On cut section, the uterus showed no polypoidal lesions of the endometrium or any apparent invasion of the myometrium. There was a generalized thickening of the endometrium and the myometrium measured 3 cm in thickness. The cervix, bilateral tubes, and ovaries were unremarkable. Microscopic sections from the uterus revealed a tumor of 0.4 cm in size at its greatest dimensions which had approximately 3 mm downward invasion into the myometrium. The morphology of the tumor as well as IHC and PAS stain positivity was identical to that of the curettage specimen examined earlier. A final diagnosis of secretory adenocarcinoma of the endometrium (Grade 1 and Stage 1A) was rendered. The postoperative period of the patient was uneventful. She is under regular monthly follow-up and has no fresh complaints.

## DISCUSSION

Tamoxifen, a non-steroidal triphenylethyl compound, belongs to a class of drugs that are known as selective ER modulators. It has both the estrogenic and antiestrogenic effects depending on the difference in the ER expression of the target tissue, differential ER conformation on ligand binding as well as varied expression, and binding of coregulator proteins to the ER.<sup>[4]</sup> Due to its estrogen antagonistic properties, it



**Figure 2:** Photomicrographs showing immunohistochemical profile of the tumor cells. (a) Nuclear positivity for estrogen receptor (IHC; ×200). (b) Positive progesterone receptor expression (IHC, ×200). (c) Strong nuclear staining for p53 (IHC, ×200). (d) Ki-67 brisk positivity (IHC, ×200)

has emerged as the first antineoplastic agent that has been extensively used for ER-positive breast cancers. It has not only significantly reduced the recurrences from the early stages of breast cancer but also has decreased the chances of contralateral breast cancer development.<sup>[5]</sup> Nevertheless, it also has a strong estrogenic agonistic effect on the vaginal epithelium, the uterine myometrium, and the endometrium of the postmenopausal women as well as the liver and the bones, which cannot be underestimated as this action of tamoxifen can potentially be detrimental as it may increase the risk of adenomyosis, adenomyomatous polyps, leiomyoma, cervical polyps, ovarian cysts, benign cystic hyperplasia of the endometrial stroma, endometrial polyps, and endometrial cancers.<sup>[2,6,7]</sup>

Tamoxifen-associated endometrial carcinogenesis has been observed in approximately 3.05/1000 women per year.<sup>[8]</sup> The risk of endometrial cancer increases two- to three-fold after a tamoxifen exposure of up to 5 years, and a median tamoxifen cumulative dose of 29 g has been suggested as a threshold for its development. However, the presence of other known risk factors of endometrial cancer such as obesity, previous estrogen use, and hypertension has also been documented to increase the chances of endometrial carcinoma in woman taking tamoxifen.<sup>[9]</sup> The mechanisms involved in such tumorigenesis are still not well understood. Nevertheless, various molecular genetic alterations involving the cellular oncogenes such as mutations in Phosphatase and tensin homolog (PTEN), *K-ras*, and the presence of microsatellite instability have been implicated to play a crucial role in its pathogenesis.<sup>[5,10]</sup> However, these mutations are segregated on the basis of histological subtypes rather than tamoxifen exposure, indicating that tamoxifen may only act as a tumor initiator through estrogen agonistic activity on the endometrium.<sup>[11]</sup>

Secretory adenocarcinoma of the endometrium is a very rare subtype of well-differentiated endometrioid adenocarcinoma, which has been seldom associated with tamoxifen therapy. According to the pertinent world literature, till now, only two previous case reports have highlighted this rare association.<sup>[10,12]</sup> In the current case, the use of tamoxifen since last 8 years in addition to hypertension might have triggered the initiation of this tumor. Another important finding was that this rare tumor was ER, PR, and p53 positive, which was unlike the case reported by Wu CJ *et al.*<sup>[10]</sup> Researchers have documented that tamoxifen can cause an increase in PR as well as sex hormone-binding globulin and a significant decrease in ER which can, in turn, enhance the progestational changes of this tumor.<sup>[13]</sup> Therefore, the mechanisms by which tamoxifen promotes endometrial

carcinogenesis are still controversial and need exploration as it can also act independent of its action as an estrogen agonist. Nevertheless, although the existing data on tamoxifen-associated secretory endometrial carcinoma is limited, this tumor has an excellent prognosis irrespective of the tamoxifen therapy status of the patient so far. However, it needs to be differentiated histologically from other endometrial pathologies such as clear cell carcinoma, atypical hyperplasia with secretory change, endometrioid adenocarcinoma with squamous differentiation, lipid-rich endometrioid carcinoma, low-grade mucinous carcinoma, metastatic renal cell carcinoma, Arias–Stella reaction, and clear cell change of pregnancy.<sup>[13]</sup>

## CONCLUSION

This case is a relevant valuable addition to the spectrum of tamoxifen-associated endometrial carcinomas and also underscores that the prolonged utilization of tamoxifen after breast cancer should be reconsidered in all the premenopausal and postmenopausal users. It is necessary to evaluate the pathological changes on the female genital tract, especially endometrium, both before and during the period of administration of this drug. In such circumstances, vaginal and endometrial cytology, TVS, fractional curettage, and frequent gynecological follow-up can aid in preventing its deleterious effects. However, more insight is required in understanding the genesis behind the endometrial carcinomas associated with tamoxifen therapy, both for the early diagnosis of the disease and also for developing better alternative treatment methods so as to improve the survival rate of such patients in near future.

## Declaration of patient consent

The authors certify that they have obtained all appropriate patient consent forms. In the form the patient(s) has/have given his/her/their consent for his/her/their images and other clinical information to be reported in the journal. The patients understand that their names and initials will not be published and due efforts will be made to conceal their identity, but anonymity cannot be guaranteed.

## Financial support and sponsorship

Nil.

## Conflicts of interest

There are no conflicts of interest.

## REFERENCES

1. Fukunaga M. Secretory adenocarcinoma of the endometrium. *Jikeikai Med J* 2002;49:51-4.
2. Sharma S. Giant endometrial polyp: An enigma in a postmenopausal woman. *J Midlife Health* 2018;9:212-5.

3. Pandey P, Mittal S, Goel A, Dixit A, Kapur K, Mahajan NC. Secretory carcinoma of the endometrium: An unusual pattern. *Basic Appl Pathol* 2011;4:21-4.
4. Lee WL, Cheng MH, Chao HT, Wang PH. The role of selective estrogen receptor modulators on breast cancer: From tamoxifen to raloxifene. *Taiwan J Obstet Gynecol* 2008;47:24-31.
5. Varras M, Zachos G, Spandidos D. Endometrial carcinoma in a breast cancer patient treated with tamoxifen: Activation of K-ras proto-oncogene. *Oncol Rep* 1997;4:1045-6.
6. Cohen I. Endometrial pathologies associated with postmenopausal tamoxifen treatment. *Gynecol Oncol* 2004;94:256-66.
7. Nasu K, Takai N, Nishida M, Narahara H. Tumorigenic effects of tamoxifen on the female genital tract. *Clin Med Pathol* 2008;1:17-34.
8. Jordan VC, Gapstur S, Morrow M. Selective estrogen receptor modulation and reduction in risk of breast cancer, osteoporosis, and coronary heart disease. *J Natl Cancer Inst* 2001;93:1449-57.
9. Bernstein L, Deapen D, Cerhan JR, Schwartz SM, Liff J, McGann-Maloney E, *et al.* Tamoxifen therapy for breast cancer and endometrial cancer risk. *J Natl Cancer Inst* 1999;91:1654-62.
10. Wu CJ, Peng YJ, Yu MH, Chen CH. Secretory endometrial adenocarcinoma in a tamoxifen user with breast cancer after menopause. *Taiwan J Obstet Gynecol* 2007;46:88-90.
11. Prasad M, Wang H, Douglas W, Barakat RR, Ellenson LH. Molecular genetic characterization of tamoxifen-associated endometrial cancer. *Gynecol Oncol* 2005;96:25-31.
12. Folk JJ, Mazur MT, Eddy GL, Musa AG. Secretory endometrial adenocarcinoma in a patient on tamoxifen for breast cancer: A report of a case. *Gynecol Oncol* 1995;58:133-5.
13. Nola M, Jukić S, Ilić-Forko J, Babić D, Uzarević B, Petrovecki M, *et al.* Effects of tamoxifen on steroid hormone receptors and hormone concentration and the results of DNA analysis by flow cytometry in endometrial carcinoma. *Gynecol Oncol* 1999;72:331-6.