

Rabbit Model of Intra-Arterial Chemotherapy Toxicity Demonstrates Retinopathy and Vasculopathy Related to Drug and Dose, Not Procedure or Approach

Anthony B. Daniels,¹⁻³ Michael T. Froehler,⁴ Amy H. Nunnally,¹ Janene M. Pierce,¹ Ivan Bozic,⁵ Cameron A. Stone,¹ Pranav R. Santapuram,¹ Yuankai K. Tao,^{1,5} Kelli L. Boyd,^{3,6} Lauren E. Himmel,^{3,6} Sheau-chiann Chen,⁷ Liping Du,⁷ Debra L. Friedman,^{3,8} and Ann Richmond^{3,9,10}

¹Department of Ophthalmology and Visual Sciences, Vanderbilt University Medical Center, Nashville, Tennessee, United States

²Department of Radiation Oncology, Vanderbilt University Medical Center, Nashville, Tennessee, United States

³Vanderbilt-Ingram Cancer Center, Vanderbilt University Medical Center, Nashville, Tennessee, United States

⁴Cerebrovascular Program, Vanderbilt University Medical Center, Nashville, Tennessee, United States

⁵Department of Biomedical Engineering, Vanderbilt University, Nashville, Tennessee, United States

⁶Department of Pathology, Microbiology and Immunology, Vanderbilt University Medical Center, Nashville, Tennessee, United States

⁷Center for Quantitative Sciences, Vanderbilt University Medical Center, Nashville, Tennessee, United States

⁸Department of Pediatrics, Vanderbilt University Medical Center, Nashville, Tennessee, United States

⁹Tennessee Valley Healthcare System, Department of Veterans Affairs, Nashville, Tennessee, United States

¹⁰Department of Pharmacology, Vanderbilt University, Nashville, Tennessee, United States

Correspondence: Anthony B. Daniels, Vanderbilt Eye Institute, Vanderbilt University Medical Center, 2311 Pierce Avenue, Nashville, TN 37232, USA;

anthony.b.daniels@vumc.org,
anthony.b.daniels@gmail.com.

Submitted: July 24, 2018

Accepted: December 4, 2018

Citation: Daniels AB, Froehler MT, Nunnally AH, et al. Rabbit model of intra-arterial chemotherapy toxicity demonstrates retinopathy and vasculopathy related to drug and dose, not procedure or approach. *Invest Ophthalmol Vis Sci.* 2019;60:954-964. <https://doi.org/10.1167/iovs.18-25346>

PURPOSE. To use our intra-arterial chemotherapy (IAC) rabbit model to assess the impact of IAC procedure, drug, dose, and choice of technique on ocular structure and function, to study the nature and etiology of IAC toxicity, and to compare to observations in patients.

METHODS. Rabbits received IAC melphalan (0.4-0.8 mg/kg), carboplatin (25-50 mg), or saline, either by direct ophthalmic artery cannulation, or with a technique emulating nonocclusion. Ocular structure/function were assessed with examination, electroretinography (ERG), fundus photography, fluorescein angiography, optical coherence tomography (OCT), and OCT angiography, prior to and 5 to 6 weeks after IAC. Blood counts were obtained weekly. We reviewed our last 50 IAC treatments in patients for evidence of ocular or systemic complications.

RESULTS. No toxicity was seen in the saline control group. With standard (0.4 mg/kg) melphalan, no vascular/microvascular abnormalities were seen with either technique. However, severe microvascular pruning and arteriolar occlusions were seen occasionally at 0.8 mg/kg doses. ERG reductions were dose-dependent. Histology showed melphalan dose-dependent degeneration in all retinal layers, restricted geographically to areas of greatest vascular density. Carboplatin caused massive edema of ocular/periocular structures. IAC patients experienced occasional periocular swelling/rash, and only rarely experienced retinopathy or vascular events/hemorrhage in eyes treated multiple times with triple (melphalan/carboplatin/topotecan) therapy. Transient neutropenia occurred after 46% of IAC procedures, generally after triple therapy.

CONCLUSIONS. IAC toxicity appears to be related to the specific drug being used and is dose-dependent, rather than related to the IAC procedure itself or the specific technique selected. These rabbit findings are corroborated by our clinical findings in patients.

Keywords: retinoblastoma, intra-arterial chemotherapy, animal models, toxicity

Intra-arterial chemotherapy (IAC) is increasingly being used for both the primary management of intraocular retinoblastoma as well as for salvage therapy.¹ We and others have previously shown that intravenous (IV) chemotherapy has poor globe salvage success rates for more advanced disease.^{2,3} We and others have also shown that IAC achieves very high rates of globe salvage, even for eyes with advanced disease (85%-91% for international classification of retinoblastoma [ICRB] group D disease,^{2,4} and 48% for ICRB group E disease).⁴ This is even true for advanced eyes that have failed other prior conservative

therapies such as IV chemotherapy, as 72% of these eyes can be saved with IAC.²

While IAC has the benefit of avoiding many of the systemic adverse consequences associated with IV chemotherapy, IAC is not without its own consequences. In particular, we and others have shown that ocular adverse events are quite common with the current melphalan-based chemotherapy regimens.^{2,5} While the majority of these are mild, transient, and self-limited, some can be vision threatening. In addition, we have shown that rates of severe (grade 3 or 4) neutropenia, though much lower than with IV chemotherapy, are still not insignificant.^{2,5,6}

Several studies have sought to expand our understanding of the causes and mechanisms of IAC-related ocular toxicity.⁷⁻¹⁰ However, at least in humans, the ability to explore these etiologies has been limited to interpretation of observation of chance unintended adverse events, as it would be highly unethical to attempt to intentionally cause toxicity experimentally in patients. Thus, several critical questions in the field remain unanswered:

1. Does the IAC procedure itself cause damage to the vasculature, and thereby ultimately impact retinal function, in a way that is independent of any drug-related toxicity?
2. Is the particular technique chosen by the interventionist predictive of adverse ocular consequences, and specifically, does catheter occlusion of the artery result in cessation of flow and higher toxicity to the vascular endothelium?
3. What are the characteristics of IAC-associated toxicity, and which subset of retinal cells is most affected?
4. Of the commonly used IAC drugs, is melphalan the primary (or sole) cause of drug-related toxicity?
5. Is melphalan-associated toxicity only seen when very high doses reach the eye due to either anomalous vascular flow patterns or higher doses being used for recalcitrant disease, or can even “routine” infusions of melphalan (in which normal levels of drug reach the eye) cause damage to the retina and retinal vasculature?

Clearly, many of these studies cannot be performed in patients, and so several of these answers have only been imputed indirectly from clinical observations.

We recently described the first small animal model of IAC, as well as a rabbit xenograft model of retinoblastoma.⁷ We were able to demonstrate that we could perform IAC effectively even in the small vasculature of rabbits, without acute vascular occlusions or other procedure-related complications. However, we did not initially explore the chronic or late consequences to an eye of the IAC procedure, nor did we explore systemic toxicities. Using our rabbit model of IAC, we can now provide some answers to the question of the causes and mechanisms of ocular toxicity seen with IAC, and corroborate these preclinical findings in patients receiving the same chemotherapeutic agents via IAC.

METHODS

Rabbit IAC Technique

All procedures were performed under the auspices of the Vanderbilt Institutional Animal Care and Use Committee and adhered to the ARVO Statement for the Use of Animals in Ophthalmic and Vision Research. New Zealand white rabbits (3.0–3.2 kg, $n = 23$) were used for all studies. Rabbit endovascular catheterization and IAC delivery were performed as we have described previously.⁷ Briefly, after induction of anesthesia, femoral arterial access was obtained by surgical exposure of the femoral artery, and arteriotomy using a 4-French micropuncture system. The rabbit was heparinized and a 1.5-French Marathon microcatheter was advanced over a Mirage microwire (Medtronic Neurovascular, Minneapolis, MN, USA). Rabbits have two ophthalmic arteries (OAs) per eye—an internal and an external—and we have shown that one is usually highly dominant for a given eye. Therefore, under fluoroscopic guidance, the dominant arterial blood supply to the eye was assessed, the microcatheter was navigated to the dominant OA for that particular rabbit, and OA selection confirmed angiographically.

Once OA selection was completed, melphalan was prepared according to the manufacturer’s specifications and filtered through a 0.22- μ m filter prior to use. For the majority of experiments, the catheter positioned in the OA was typically occlusive and did not permit blood flow around the catheter. Melphalan (0.4–0.8 mg/kg), or saline for control experiments, was infused in a pulsatile fashion over 5 minutes, followed by a saline flush. All melphalan infusions were performed within 1 hour following reconstitution of the melphalan. For the carboplatin studies, 50 mg of carboplatin (a dose commonly used in patients >1 year old¹¹) or 25 mg (dose reduced to account for the rabbit eye being approximately half the size of the human eye) was infused. For the assessment of a continuous flow technique, the OA was again occluded by the catheter, but a continuous flow of saline was maintained through the microcatheter and pulsatile infusion of melphalan was performed into the continuous stream of saline. At the end of the procedure, the sheath was removed and the artery ligated above and below the arteriotomy site to ensure hemostasis, followed by closure of the fascia, muscle, and skin.

Three to six rabbits were used in each subgroup (melphalan 1.2 mg by standard technique, melphalan 1.2 mg by continuous flow technique, melphalan 2.4 mg by standard technique, carboplatin 25 mg by standard technique, carboplatin 50 mg by standard technique, or saline control by standard technique).

Assessment of Retinal Toxicity

A few days prior to the planned IAC procedure, baseline testing of retinal and retinal vascular structure and retinal function was performed. This consisted of electroretinography (ERG), clinical ophthalmic examination, fundus photography, fluorescein angiography (FA), optical coherence tomography (OCT), and OCT angiography. Following pupillary dilation, rabbits were dark adapted for at least 1 hour and then anesthesia induced with ketaset and xylazine. ERG (OcuScience, Henderson, NV, USA) was performed according to the modified International Standard for Clinical Electrophysiology of Vision protocol for rabbits.¹² Fundus photography was performed using a handheld camera (PictorPlus; Volk Optical, Mentor, OH, USA). OCT and OCT angiography were performed using a custom-built engine and ophthalmic scanner.¹³ FA was then performed using the FA module of the handheld camera system. Five to six weeks following the IAC treatment, the exact same testing procedures were performed prior to euthanasia, and both eyes were submitted for histopathology.

For assessment of retinal function by ERG, toxicity was defined for each rabbit for each test and each parameter (for example, rabbit #1 scotopic 100 mcd a-wave amplitude, or rabbit #2 photopic 3000 mcd b-wave implicit time). Toxicity was defined prospectively and was deemed significant for a given dose in a rabbit group if there was a 25% reduction in average ERG amplitude or a 25% prolongation of average implicit time for a given parameter when comparing the posttreatment values with the pretreatment values, and the difference was statistically significant. For assessment of toxicity in individual rabbits, toxicity was defined as a 25% reduction in ERG amplitude or a 25% prolongation of implicit time for a given parameter when comparing the posttreatment values with the pretreatment values for that rabbit.

Histopathologic Assessment of Eyes and Periocular Structures

Following euthanasia, the globes were fixed in Davidson’s solution for 48 hours, transferred to ethanol, then embedded in paraffin and sectioned. Following staining with hematoxylin

and eosin (H&E), the sections were examined by an experienced veterinary pathologist (KLB, LEH). For the rabbits treated with IAC carboplatin, massive periocular swelling necessitated euthanasia earlier than the 5- to 6-week time point. In order to study the entire orbit in these rabbits with periocular swelling, both orbits were harvested in toto using a rotating saw, keeping the orbital bones intact within the specimen. The bones were decalcified in Immunocal (StatLab, McKinney, TX, USA) and then the specimens were fixed in 10% neutral buffered formalin and sectioned as wholemounts, prior to H&E staining and examination by the veterinary pathologists.

Assessment of Systemic Toxicity

Complete blood counts were obtained from peripheral venipuncture at baseline as well as weekly following the IAC treatments until the time of euthanasia 5 to 6 weeks later. All measurements were conducted on the ForCyte hematology analyzer (Oxford Science, Oxford, CT). White blood cell, absolute neutrophil, hemoglobin, and platelet counts were each tracked over time.

Assessment of Ocular and Systemic Toxicity in Patients Treated With IAC

Under the auspices of the Vanderbilt Institutional Review Board, and in accordance with the tenets of the Declaration of Helsinki, we reviewed our last 50 intra-arterial chemotherapy eye treatments for retinoblastoma for patients for whom there was at least 18 months of follow-up. Informed consent was obtained from patients for all procedures performed. Eye group, whether IAC was used as primary treatment or as salvage after intravenous chemotherapy failure, technique used, whether the catheter tip was occlusive or not, eye outcome (globe salvaged or not), and length of follow-up were all recorded. We specifically documented if the medical record indicated that any of the following adverse events were either seen on examination or if the parents called with complaints consistent with these adverse events: periocular/eyelid swelling or erythema/rash, conjunctival chemosis or inflammation, evidence of myositis. When known, timing of the particular complication was recorded. We also retrospectively reviewed the images that were obtained (RetCam; Clarity Medical Systems, Inc., Pleasanton, CA, USA) at the time of the subsequent examination under anesthesia to assess for any evidence of retinal or retinal vascular toxicity, or residual periocular reactions or swelling. It is our standard practice to perform FA on patients following IAC, and especially if there is any hint of toxicity, and all of these FA images were reviewed for all patients included in this study as well. In addition, it is our practice to obtain complete blood counts (CBCs) on patients 7 to 10 days following IAC treatments. These were reviewed whenever available in the medical record for evidence of cytopenias and graded according to the National Cancer Institute's Common Toxicity Criteria for Adverse Events version 5 (CTCAE5) standards. Since occasionally both eyes were treated sequentially during the same anesthesia event ("tandem therapy"),¹⁴ the 50 eye treatments corresponded to 43 separate IAC treatments (on a patient level) with a theoretical maximum of 43 (not 50) CBCs to review. For patients who travel long distances for treatment with us, CBCs are ordered by their pediatricians at home, and occasionally these results (presumably if normal) are not forwarded to us. While we order CBC with differential to calculate absolute neutrophil count, occasionally the patients' pediatricians may have ordered a CBC without differential.

Statistical Analyses of Rabbit ERG Data

To evaluate the toxicity and compare the effect of treatment at different dosages, a linear mixed-effects model was fit for each parameter and each test on the measurement time point (pre- or post-), treatment group identity, and their interactions. The post- and pretreatment difference for each treatment group was estimated from the model. The toxicity for a treatment is defined as above. The differences in the pre- and posttreatment change (difference of differences) between different treatment groups were also estimated. Bonferroni adjusted *P* values were reported to account for multiple comparisons between groups. All tests were two-sided with *P* values less than 0.05 considered as statistically significant. The analyses were performed using R version 3.3.2 including packages "nlme."

RESULTS

Effect of IAC Procedure Itself on Ocular or Retinal Vascular Toxicity

To assess whether the IAC procedure itself was causing damage to the vessels and ultimately to the retina, we performed control experiments in which saline was infused. Despite the fact that the microcatheter was always occlusive within the OA and prevented normal blood flow, no evidence of retinal or retinal vascular toxicity was observed following saline infusion (Fig. 1). Specifically, ERG amplitudes were not reduced and implicit times were not prolonged (Fig. 2), no vascular occlusions were seen on subsequent FA, and no microvascular loss was observed by OCT angiography subsequent to treatment as compared to either the pretreatment FA or OCT angiograms or as compared to the contralateral untreated eyes (Fig. 1).

Dose Relation of Ocular Toxicity of Intra-Arterial Melphalan

We assessed the effect of melphalan given via IAC on retinal and retinal vascular structure and function. IAC melphalan was infused at either the usual weight-based dose given in children (0.4 mg/kg) or else with double the usual weight-based dose (0.8 mg/kg). In our clinical practice, we generally dose intra-arterial melphalan according to patient weight because doses above 0.4 mg/kg are associated with much higher rates of neutropenia.⁶ Minimal toxicity was observed with the usual 0.4 mg/kg dose. In all of the rabbits in this group, retinal structure was normal on the OCT B scan images, no retinal vascular occlusions were observed by FA, and the microvasculature was normal as assessed by OCT angiography (Fig. 1). Only one single parameter (scotopic 10,000 mcd a-wave amplitude) was observed to have worsened by a statistically and clinically significant amount subsequent to the 0.4 mg/kg melphalan IAC treatment, as compared to the pretreatment ERG measures (30% reduction in amplitude, *P* = 0.00012; Fig. 2).

In the double dose (0.8 mg/kg group), there was greater evidence of retinal functional loss following IAC as measured by ERG. Worsening of ERG parameters was observed on average across rabbits in this group. The scotopic 3000 mcd a-wave amplitude, scotopic 10,000 mcd a-wave amplitude, scotopic 10,000 mcd b-wave amplitude, photopic 3000 mcd b-wave amplitude, and 30-Hz flicker b-wave amplitude tests all showed worsening (Fig. 2). In addition, the degree of worsening of each was significantly greater than that which was observed in the 0.4 mg/kg melphalan-treated group. In the 0.8 mg/kg group, each affected parameter worsened between 49% to 72% compared to pretreatment measures, whereas the

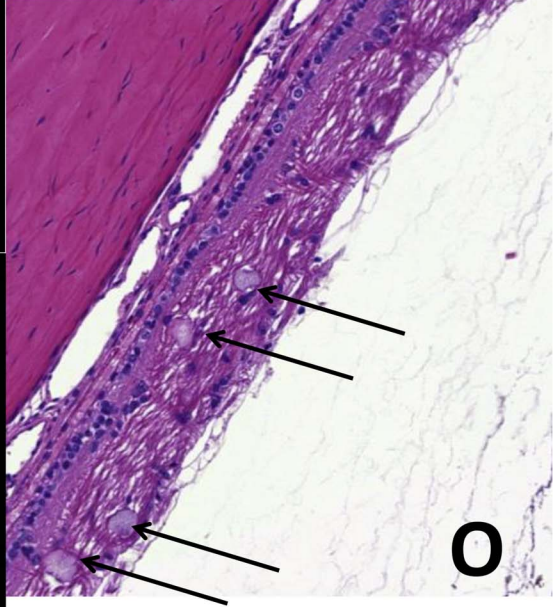
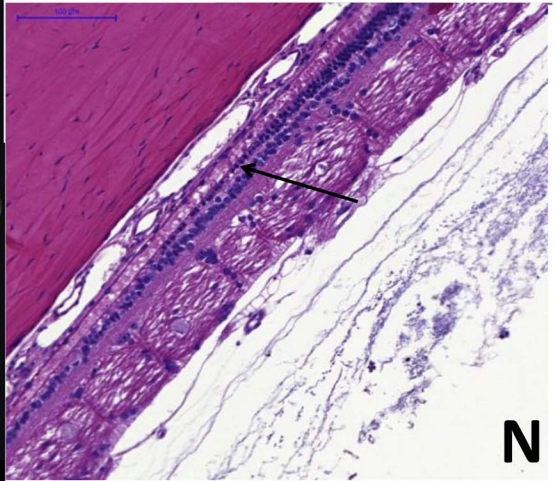
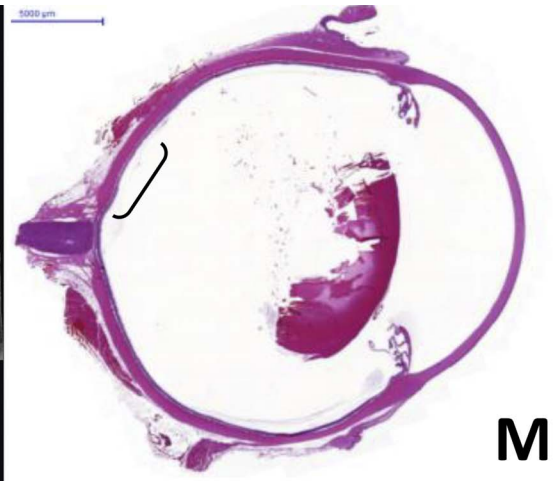
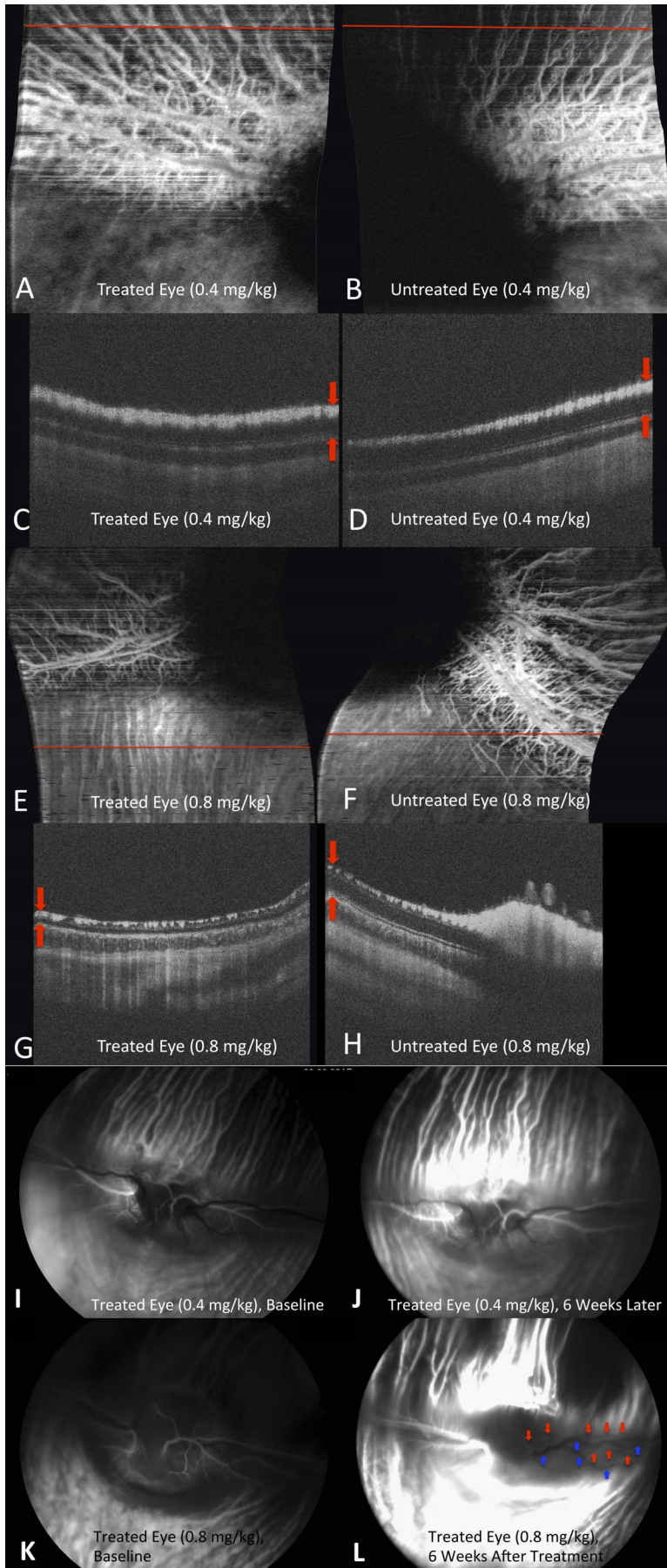


FIGURE 1. Melphalan toxicity occurs at higher doses and is characterized by vascular damage to both large retinal vessels and retinal microvasculature, with degeneration of inner and outer retinal layers. (A–D) Retina 6 weeks following intra-arterial treatment with 0.4 mg/kg melphalan (usual dose). None of the rabbits treated with this dose demonstrated evidence of retinal toxicity on imaging or histopathology. (A, B) OCT angiography shows normal microvasculature in both the treated (A) and contralateral untreated (B) eyes. (C, D) OCT B scan shows normal retinal appearance in both the treated eye (C) and the untreated contralateral eye (D). *Red arrows* show the retinal thickness on the OCT B scans in C and D. The OCT B scans in C and D were taken at the location of the *red lines* seen in panels A and B. (E–H) Retina 6 weeks following intra-arterial treatment with 0.8 mg/kg melphalan (double the usual dose). Occasionally, animals in this group showed evidence of retinal toxicity. (E) OCT angiography shows severe vascular pruning and loss of microvasculature in the treated eye. (F) The normal microvasculature is retained in the contralateral untreated eye. (G, H) OCT B scan shows diffuse retinal thinning in the treated eye (G), but not in the contralateral untreated eye (H). *Red arrows* show the retinal thickness on the OCT B scans in G and H. The OCT B scans in G and H were taken at the location of the *red lines* seen in panels E and F. (I–L) Fluorescein angiography before (I, K) and 6 weeks after (J, L) intra-arterial melphalan with either the usual (0.4 mg/kg) dose (I, J) or with double the usual dose (0.8 mg/kg; K, L). All fluorescein angiography images shown here were obtained during the arterial phase. Occasionally, rabbits in the 0.8 mg/kg melphalan group demonstrated evidence of retinal vascular occlusions following treatment (L), but this was never seen in any of the rabbits treated with 0.4 mg/kg of melphalan. *Red arrows* show the course of the non-filling arterioles, and *blue arrows* denote the course of the venules. (M–O) Dose-dependent toxicity was seen in eyes harvested 6 weeks following intra-arterial infusion of melphalan. H&E stain. (M) Retina was noted to be abnormal in areas relatively close to the optic nerve, where the retinal vasculature is most dense in the rabbit eye. The bracket denotes the affected area. (N, O) Magnified views of the area denoted with the bracket in panel M. (N) The *arrow* points out the transition from normal photoreceptors to degenerated ones. (O) Similarly, degenerating cell bodies are seen within the ganglion cell layer (*arrows*).

single parameter that worsened in the 0.4 mg/kg group only showed a 30% reduction in amplitude (Fig. 2). When assessing toxicity in individual rabbits, all four rabbits in the 0.8 mg/kg double dose group showed a worsening of 25% in at least one ERG parameter on at least one test, and this occurred in a median of 8.5 (range: 3–10) different parameters per rabbit.

In addition to the functional loss in the double dose group, one out of the four rabbits demonstrated retinal arterial damage, with no flow seen in that major retinal artery 5 to 6 weeks following the IAC treatment (Fig. 1J). In addition, there was profound pruning and loss of the retinal microvasculature in another (different rabbit's) treated eye, which was not seen in the rabbit's contralateral (untreated) eye (Fig. 1E).

Histopathology of eyes treated with either 0.4 mg/kg or 0.8 mg/kg of intra-arterial melphalan corroborated the dose-dependent retinal toxicity that had been noted on functional retinal ERG testing. Patchy areas of retinal thinning, photoreceptor damage, and degeneration of retinal ganglion cells were seen, generally within a delimited area of retina posteriorly near the optic nerve (Figs. 1K–M). These areas were more extensive and diffuse in the 0.8 mg/kg (double dose) group, compared to the 0.4 mg/kg (usual dose) group.

Comparison of Standard Occlusive Technique to Continuous Flow Technique

It has been argued that much of the toxicity that has been reported following IAC can be attributed to use of an occlusive surgical technique, specifically if the OA is completely occluded by the catheter.¹⁵ This situation could potentially result in ischemia related to retinal hypoperfusion, or thrombosis of the stagnant blood within the OA and resultant thromboembolism. In addition, the lack of flow could lead to stagnant pooling of the infused drug within the OA, leading to very high concentrations within the vessel and resultant toxicity to vascular endothelial cells. To assess the effect of choice of occlusive or nonocclusive surgical technique on ocular toxicity, we performed endovascular infusions of 1.2 mg of melphalan (0.4 mg/kg) using two different techniques. In the first technique, which is our standard technique in rabbits, the microcatheter was advanced into the ophthalmic artery, allowing the vessel to be occluded, and then melphalan was infused in a pulsatile fashion followed by a final saline flush. In the second technique, the catheter was advanced into the ophthalmic artery, allowing the vessel to be occluded (occlusion cannot be avoided in this model system due to the small size of the ophthalmic artery lumen in rabbits, which approximates the diameter of the smallest microcatheters). To prevent stagnation of blood and chemotherapy within the OA,

we allowed saline to flow continuously through the microcatheter, and small interspersed pulses of melphalan were infused into this continuous saline flow, which were immediately taken downstream by the saline flow. There was no difference in ERG parameters between rabbits in the two different technique groups, and no vascular occlusions or microvascular loss were observed in rabbits in either group. The same degree of retinal degeneration was seen on histopathology, regardless of technique.

Ocular Toxicity of Intra-Arterial Carboplatin in the Rabbit Model

We assessed the toxicity of carboplatin in rabbits using a dose of 50 mg, which is a common dose used clinically to treat infants >1 year old¹¹ (and which is the carboplatin dose we use for all of our patients), or else the rabbits were treated with 25 mg carboplatin, which represents a 50% dose reduction to account for the fact that the rabbit eye is approximately half the size of the human eye. Following IAC with carboplatin at either the standard human dose of 50 mg, or at the rabbit eye size-adjusted dose of 25 mg, massive ocular swelling developed in all treated rabbits (Fig. 3). Following infusion of 50 mg carboplatin, swelling developed within a few hours of the treatment, necessitating euthanasia. Following infusion of 25 mg carboplatin, the same swelling developed, but was more gradual and developed and worsened over the 1 to 5 days following treatment. Ultimately, these rabbits likewise all had to be euthanized once the swelling developed. The entire orbits were harvested for histopathology to allow us to study not just the globe itself, but also the massively swollen periocular structures. Histopathology demonstrated choroidal edema and congestion with vessel dilation on H&E staining. In addition, there was edema of the episclera and bulbar conjunctiva. The extraocular muscles were likewise affected, with inter- and intramuscular edema, foci of early hyaline degeneration, and heterophilic infiltrates (Fig. 3).

Ocular Toxicity of IAC in Patients

Of the patient eyes treated with IAC, 18% were ICRB group B, 18% were group C, and 64% were group D. At our institution, we generally enucleate all group E eyes primarily, so no group E eyes are represented in this IAC treatment cohort. IAC was performed as primary therapy for 55% of eyes, and as salvage following failure of intravenous chemoreduction for 45%. We used a direct technique, with catheter tip advanced to near the ostium of the ophthalmic artery via the internal carotid artery, 40% of the time. Alternative techniques were used the remainder of the time, including an external carotid approach

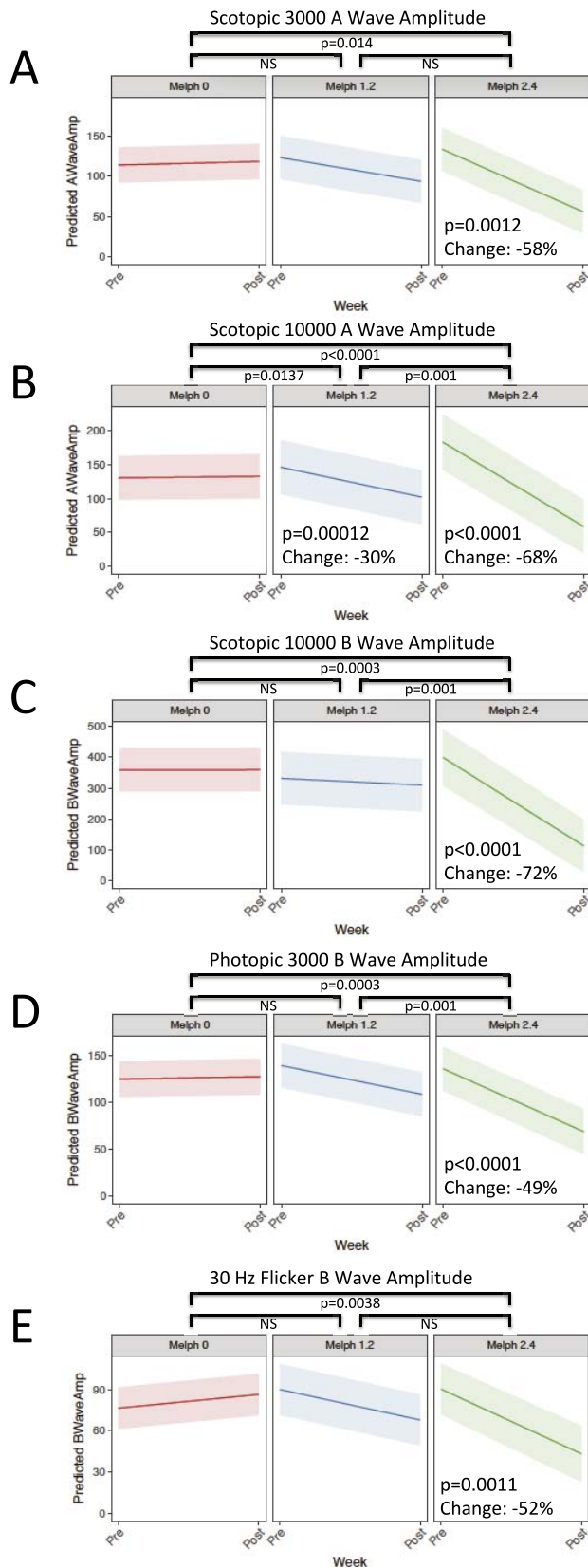


FIGURE 2. Melphalan toxicity causes retinal functional damage that is dose-dependent. Electroretinography was performed before, and again 6 weeks after, intra-arterial treatment with either melphalan 0.4 mg/kg or 0.8 mg/kg, or with saline. Retinal responses to scotopic 1000 mcd flashes, scotopic 3000 mcd flashes, scotopic 10,000 mcd flashes, photopic 3000 mcd flashes, and 30-Hz flicker flashes were recorded.

in 14%, use of the Japanese internal carotid balloon technique¹⁶ in 30%, and use of the bifemoral “Cincinnati” technique (with a balloon inserted into a collateral to achieve a more favorable flow pattern through the ophthalmic artery¹⁷) 12% of the time. Interestingly, due to changes in flow patterns over the duration of individual patients’ treatment courses, the same technique was not necessarily used for every IAC treatment of a given patient. Importantly, the catheter tip was nonocclusive in all but two treatments. Those two treatments where the tip was occlusive occurred in a patient who received a total of four rounds of IAC to one eye. Interestingly, while he had developed subretinal hemorrhage in a previous nonocclusive treatment, he did not develop any complications following either of his two IAC treatments where the catheter tip was felt to be occluding the ophthalmic artery.

A total of 12/50 (24%) eye treatments resulted in some evidence of local toxicity. Most were mild and almost all were transient. Periorcular edema or eyelid swelling or erythema occurred following 10/50 (20%) of treatments, always within the first few days after treatment. These episodes of swelling, many of which were mild, almost always occurred after triple therapy with melphalan, carboplatin, and topotecan, with only one episode occurring in a child (>1 year old) who received 50 mg carboplatin and 2 mg topotecan without melphalan (Fig. 3F). The frequently-described rash in the distribution of the supratrochlear artery was seen after 3/50 (6%) treatments, always within the first few days after treatment. Retinopathy was seen in a single patient who received multiple rounds of triple therapy with maximal routine doses of each agent, following failure of intravenous chemoreduction. Focal subretinal hemorrhage was seen after two treatments (two different patients) with triple therapy, both of which resolved spontaneously. Proptosis or evidence of extraocular muscle myositis occurred after two treatments (two different patients) with triple therapy, both of which resolved spontaneously. It is our standard practice to perform FA on patients following IAC, and especially if there is any hint of toxicity. No evidence of vascular occlusion, or iris or retinal neovascularization, was seen in any patients. Importantly, over a mean follow-up of 34 months (range: 18–50 months), we found no pattern of complications related to disease classification, primary versus secondary use of IAC, or the specific technique employed. This was consistent with our experimental findings in our rabbit model that showed no difference with toxicity or complications between eyes treated with an occlusive technique or those eyes treated with continuous flow of saline to simulate nonocclusion.

A-wave and b-wave amplitudes, and a- and b-wave implicit times were recorded (except for with the 30-Hz flicker, where there is only a b-wave). Shaded areas on the graphs represent 95% confidence intervals. Among all of the parameters studied, toxicity (see Methods section for toxicity criteria) was only observed for the scotopic 10,000 mcd a-wave amplitude in the 0.4 mg/kg treated group (**B**, middle panel). Toxicity was observed in the 0.8 mg/kg treated group for the (**A**) scotopic 3000 mcd a-wave amplitude, (**B**) scotopic 10,000 mcd a-wave amplitude, (**C**) scotopic 10,000 mcd b-wave amplitude, (**D**) photopic 3000 mcd b-wave amplitude, and (**E**) the 30-Hz flicker b-wave amplitude (rightmost panels). None of the other parameters showed evidence of toxicity for any treatment group. For those particular tests where toxicity was seen, percent change and *P* values for estimates of trend are shown along with the particular graph. *P* values of the difference between groups are shown within brackets at the top of each graph. NS = not significant.

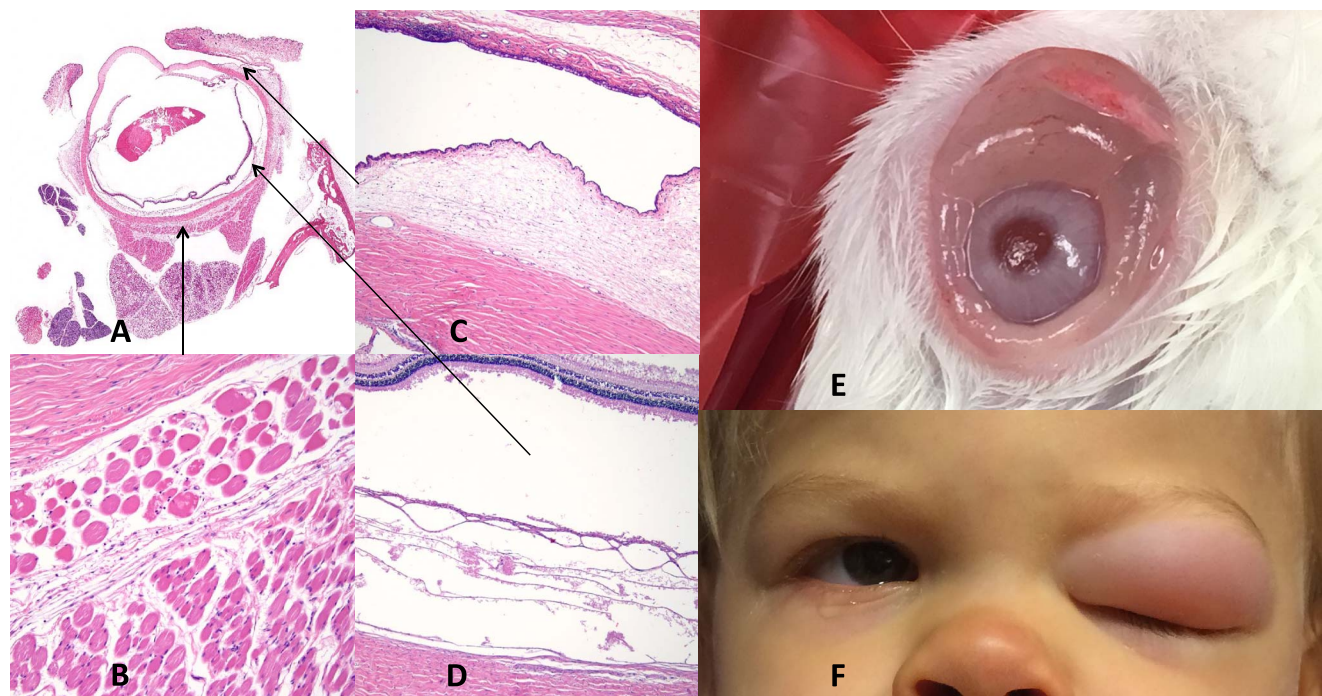


FIGURE 3. Carboplatin toxicity is characterized by massive congestion and edema of intraocular and extraocular tissues. (A–E) Toxicity was seen in all rabbits treated with intra-arterial carboplatin. (A) Histopathology of the orbit of a rabbit treated with 50 mg intra-arterial carboplatin (H&E). (B–D) Magnified view of part A in the areas denoted by the *arrows*. (B) Inter- and intramuscular edema, foci of early hyaline degeneration, and heterophilic infiltrates. (C) Edema of the episclera and bulbar conjunctiva. (D) Choroidal vessel dilation, congestion, and edema (retinal detachment is artifactual). (E) Clinical appearance of a rabbit eye that was treated with intra-arterial carboplatin. (F) Clinical appearance of a patient with bilateral retinoblastoma (right eye ICRB group C, left eye ICRB group D) with periocular swelling following intra-arterial treatment of the left eye with 50 mg carboplatin and 2 mg topotecan. The right eye had received intra-arterial melphalan (4.5 mg at 0.4 mg/kg) at the same time and did not develop swelling. This periocular swelling of the left eye was transient and resolved with systemic steroids. With intra-arterial chemotherapy treatment, all of this child's six tumors regressed, both of this child's eyes were saved, and vision improved in both eyes, now with 4 years of follow-up.

Systemic Toxicity of Intra-Arterial Melphalan in Rabbits

CBCs were obtained weekly in rabbits treated with intra-arterial melphalan with either 1.2 mg (0.4 mg/kg) or 2.4 mg (0.8 mg/kg, double the usual dose given in patients), or with intra-arterial saline as a control. When comparing treatment groups, there was no significant reduction in neutrophil, hemoglobin, or platelet counts compared to baseline (Fig. 4). We next looked at individual rabbits, to determine if there may have been some individuals who developed a cytopenia,¹⁸ even if the group as a whole did not. However, no sustained cytopenias were observed in any animals, even at double the usual treatment dose.

Systemic Toxicity of IAC in Patients

CBCs were available for review after 33/43 procedures, with differentials available for 26/33 CBCs. No episodes of grade 3 or 4 anemia or thrombocytopenia occurred, and no patients required blood or platelet transfusions. Grade 3 or 4 neutropenia was seen following 12 of the treatments. Since differentials were only available for review following a total of 26 IAC treatments (local pediatricians often ordered CBC without differential), this represents 46% of evaluable treatments. One patient, with a neutrophil count of 950, developed a brief fever, but did not require granulocyte-colony stimulating factor (G-CSF) and no evidence of infection was found. Low neutrophil count never delayed or prevented subsequent IAC treatments, and IAC doses never had to be adjusted as a result

of transient neutropenia. All tumors were successfully treated, and no eyes required enucleation or salvage external beam radiotherapy. All patients are alive and well with no cases of metastatic disease.

DISCUSSION

Making use of our recently-developed rabbit model of IAC,⁷ we have explored the toxicities associated with the IAC procedure and with the most commonly used IAC drugs. We found no procedure-related toxicity, even when using an occlusive technique, and no difference when a nonocclusive technique was emulated (by continuous saline flow during the melphalan treatment). When we explored drug-related toxicity using an extensive battery of tests, occlusions of major retinal arteries as well as pruning and loss of retinal microvasculature were seen occasionally only with supratherapeutic doses of melphalan (twice the usual weight-based dose used in patients), but not with usual (0.4 mg/kg) doses. In our clinical practice we generally dose intra-arterial melphalan according to patient weight because doses above 0.4 mg/kg are associated with much higher rates of neutropenia.⁶ However, mild dose-related functional and structural toxicity to the retina itself was seen even with 0.4 mg/kg melphalan, and much greater functional loss was seen with higher doses. Carboplatin caused massive edema of intraocular and extraocular structures, akin to the edema seen in some patients.^{2,5} This edema was seen even when the dose was reduced by 50% from 50 mg (which is a standard dose used to treat infants >1 year old,¹¹ and is the

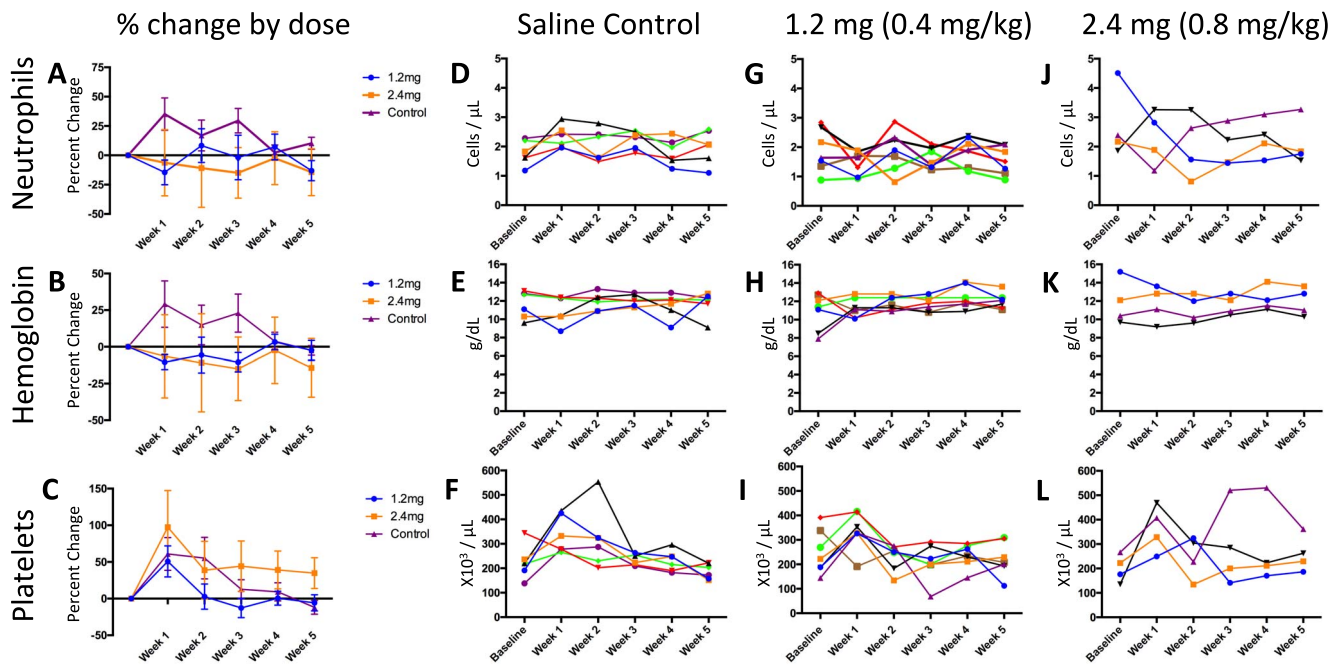


FIGURE 4. Blood counts following intra-arterial melphalan treatments at various doses. CBCs were obtained at baseline prior to intra-arterial treatment with either melphalan 0.4 mg/kg or 0.8 mg/kg, or with saline, and then were obtained weekly. (A–C) Percent change within each treatment group for (A) neutrophil count, (B) hemoglobin, and (C) platelet count. *Error bars* represent standard deviations. (D–L) Tracings of individual rabbits. Rabbits were treated with (D–F) intra-arterial saline, (G–I) with 1.2 mg (0.4 mg/kg) of intra-arterial melphalan, or (J–L) with 2.4 mg (0.8 mg/kg) of intra-arterial melphalan. (D, G, J) Neutrophil counts. (E, H, K) Hemoglobin. (F, I, L) Platelet counts. A sustained decrease in neutrophil count was only seen with a single rabbit in the 2.4 mg (0.8 mg/kg) melphalan group (J, *blue line*), but did not drop below 1.

dose we use to treat all our retinoblastoma patients) to 25 mg, to account for the fact that the rabbit eye is approximately half the size of the human eye.

Some authors have suggested that at least some of the toxicity associated with IAC might be related to the procedure itself, either due to iatrogenic embolus formation from clots, from iatrogenically introduced foreign material, from iatrogenic occlusion of vascular flow, or from iatrogenic damage to the vessels themselves.^{19,20} To explore the possibility that the procedure itself caused downstream damage to the retina or vasculature independent of the drug being infused, we performed the procedure infusing saline, as a control. We did not find any evidence of vascular occlusions or microvascular loss and no worsening of ERG parameters indicating retinal functional toxicity in this group. Similarly, histopathology showed no damage to retinal structures, consistent with our *in vivo* findings on OCT.

Intraoperative ophthalmoscopic and fluorescein angiographic anomalies have been found in patients following IAC treatment^{21,22}; however, it is difficult to attribute this to the procedure rather than the drug that was infused. Similar FA anomalies have been seen in a nonhuman primate model of IAC,²³ and direct evidence of embolus formation was reported in this primate model.⁸ However, in order to allow for larger animals to be used in those primate experiments, older animals were used.^{8,23,24} As with humans, older nonhuman primates are more likely to have carotid atherosclerosis, which could be dislodged by endovascular microcatheter intervention.²⁵ From the interventional literature, we know that in the 21st century, stroke occurs in <0.5% of patients undergoing carotid angiography.²⁶ However, these are similarly older patients, with more atherosclerosis (particularly higher among those patients who may find themselves requiring an interventional procedure due to vascular pathology). In contrast, we saw no emboli in our young rabbits receiving endovascular cannula-

tion without chemotherapy infusion (our rabbits were 3 months old), and no strokes occurred. Importantly, human babies who might find themselves undergoing IAC for retinoblastoma are unlikely to have the atherosclerosis seen in older patients or older nonhuman primates. Relatedly, the nonhuman primate model did not employ systemic heparin anticoagulation,^{8,24} whereas we did in our rabbit model (to mimic precisely what we do with our patients) and this may partially contribute to the absence of iatrogenic embolus formation in our saline control animals.

Several authors have likewise suggested that some of the adverse consequences seen with IAC can be attributed to iatrogenic vascular damage from inexperience, technique selection, or poor technique. This contention is supported by the fact that several authors have published their initial complications when first beginning their institutions' IAC programs,^{27–30} while IAC complications in larger series over longer periods of time tend to show lower complication rates.² Even within a given treating institution, ocular complications are known to decrease with increasing experience.³¹ Our long experience (both with IAC in patients as well as in rabbits) might therefore have contributed to our lack of technique-related complications in the saline-treated control animal. In fact, we can perform up to four full IAC procedures back-to-back (four separate animals) within an hour of reconstituting the melphalan in our rabbit model system.

However, there remains the question of whether the specific technique that is employed relates to adverse consequences. Specifically, whether direct OA cannulation vs. placing the catheter tip near (but not within) the ostium of the OA affects vascular flow and local endothelial drug toxicity. It has been suggested by some that direct cannulation leads to an accumulation of drug at very high concentrations immediately downstream of the catheter tip, leading to excessively high local concentrations for the vascular endothelium. Others

advocate this cannulation technique, and it has conversely been argued that there is sufficient collateral circulation within the orbit around the point of OA occlusion. To explore these possibilities directly, we performed intra-OA melphalan infusions using two different techniques to approximate the direct cannulation (“occlusion”) technique, or the nonocclusive technique with continued flow through the catheter (the “flow” technique). We did employ pulsatile infusions to improve fluidics in both cases, as we do with our patients. We found no difference in toxicity with either technique.

We would caution that, while these results are certainly suggestive that careful direct cannulation and occlusion of the OA does not result in downstream retinal or vascular damage, interspecies differences between rabbits and humans need to be considered, and therefore we cannot definitively exclude this possibility in humans. For example, rabbits have two OAs on each side, an external ophthalmic artery arising from the external carotid artery, and an internal ophthalmic artery arising from the internal carotid artery. Thus, one may wonder, even in the case where the dominant ophthalmic artery is “occluded,” if the second minor ophthalmic artery functions like a “collateral”, allowing blood to continuously reach the retina downstream of the catheter occlusion site. However, we have previously shown that for a given eye, the entire retina is supplied by either the external ophthalmic artery or else by the internal ophthalmic artery exclusively.⁷ Only in a minority of eyes (9%) does the eye actually receive blood supply from both OAs simultaneously. Even in these cases, half of the retina is exclusively supplied by the external ophthalmic artery and the other half of the eye’s retina is supplied exclusively by the internal ophthalmic artery.⁷ Thus, even in these rare eyes with “dual” circulation, there is no ability of the minor ophthalmic artery to “protect” the retina from an upstream occlusive event within the dominant ophthalmic artery. In this way, despite the presence of two OAs in the rabbit, we feel that our experiments related to occlusive or nonocclusive technique do recapitulate the situation found in humans relatively well.

We found evidence of retinal functional toxicity, as manifested by worsening of ERG parameters, in a dose-dependent fashion following intra-arterial melphalan infusion. Similar findings of melphalan dose-dependent reductions in ERG parameters have been seen in patients.³² Within treatment groups, statistically significant worsening of ERGs was observed for more parameters at higher melphalan doses. Similarly, the degree of worsening, as measured by percent change relative to baseline, was greater at higher doses among those parameters that demonstrated significant worsening. When looking at individual rabbits, the number of ERG parameters that showed clinically-meaningful worsening was greater at higher doses, compared to those rabbits that received standard melphalan doses, or compared to saline-treated controls. However, it should be emphasized that some individual rabbits did experience worsening of some ERG parameters even in the standard dose (0.4 mg/kg) group. This is in concert with published cases of melphalan-induced toxicities such as choroidopathy that have occurred in patients receiving intra-arterial melphalan at standard doses, as well. In contrast to these published results in humans, we did not see similar cases of choroidopathy in our rabbits, although the absence of choroidal infarctions in our rabbits was in line with the absence of choroidal infarctions seen among our own patients. There is also recent clinical work that corroborates the contention that cases of severe visual loss associated with IAC are likely attributable to doses of melphalan that are too high for a given size child, rather than being due to complications associated with the catheterization itself.³³

ERG parameters that worsened were not exclusive to a single retinal cell type. Scotopic, photopic, and flicker

responses were all affected at higher doses. Similarly, reductions in both the a-wave (indicating outer retinal pathology) and b-wave (including middle and inner retinal layers) were seen. Consistent with these findings, histopathology of affected eyes demonstrated dose-dependent degeneration both of outer retinal photoreceptors as well as inner retinal ganglion cell bodies. These histopathologic findings were seen within a delimited area near to the optic nerve, with the extent of involvement dependent on the dose of melphalan given. Interestingly, the rabbit retina has the greatest concentration of retinal vessels near the optic nerve head, and so it is plausible that these juxtapapillary sections of retina received the highest doses of chemotherapy.

In contrast to the retinal and retinal vascular toxicity seen with melphalan, toxicity associated with carboplatin manifested as edema and swelling of intraocular and extraocular structures, including the choroid, episclera and conjunctiva, and extraocular muscles. In our patients, we occasionally saw similar findings, with eyelid edema, conjunctival chemosis, and rarely myositis and proptosis. This swelling was dramatic in the rabbits, as is the case in some patients. However, in the patient cohort, the majority of eyes with periocular swelling had received triple therapy with melphalan, carboplatin, and topotecan (as was the case in previous publications),² and so it is difficult to parse out the relative contribution of each drug. Interestingly, one patient with profound periocular swelling received only carboplatin and topotecan, but not melphalan (Fig. 3F), suggesting that melphalan may not be the sole driver of the clinically observed swelling. Periocular swelling following IAC treatment with 50 mg carboplatin has been described previously.¹⁵ The remainder of the eyes that developed swelling had received triple therapy.

One patient, who had previously failed intravenous chemoreduction in both eyes, developed retinopathy following treatment with melphalan, carboplatin, and topotecan. This initially manifested as a salt-and-pepper retinopathy over the nasal retina, but included parts of the retina temporal to the optic nerve head and included much of the macula as well. Tiny subretinal hemorrhages were also observed near the fovea. This is in contrast to the typical segmental clinical appearance that has been reported in other patients with occlusive choroidal vasculopathy following IAC. This patient had an anomalous vascular variation, with the ocular blood supply arising off of a branch of the external carotid artery. While it is tempting to blame the vascular anatomy, this same external carotid artery approach had been used for this eye for two previous treatments, yet the retinopathy did not manifest until the third treatment using the same approach. It was first noted on the subsequent examination under anesthesia 1 month following this third injection, and worsened following the subsequent (fourth) IAC treatment with the “Cincinnati” bifemoral balloon technique. This eye was quite recalcitrant, had failed prior intravenous chemoreduction, and the tumors had not regressed despite two cycles of IAC with 0.4 mg/kg melphalan, 50 mg carboplatin, and 2 mg topotecan. Thus, in an effort to increase the efficacy of treatment without having to increase the melphalan dose for this very young child, we increased the topotecan dose beyond our usual limit of 2 mg,¹¹ on the assumption that topotecan would be less toxic than a higher melphalan dose. We suspect that the retinopathy seen was largely due to the suprathreshold dose of topotecan used, and so we returned to the usual 2 mg topotecan dose for the subsequent round of IAC, and tumor control was achieved. While the purpose of this paper is not to explore the toxicity of intra-arterial topotecan specifically, the presence of a complication seen only following the treatment with a higher-than-usual topotecan dose supports our overall hypothesis that the

type of toxicity that is seen depends on the specific drug and dose that is used.

The primary dose-limiting toxicity with melphalan, and the reason that the typical upper limit is 0.4 mg/kg, is cytopenias.⁶ Within rabbit treatment groups, reductions in average blood counts were always less than 25%, and this was true for absolute neutrophil count, hemoglobin, and platelets. In our rabbit model, this was true even when 0.8 mg/kg melphalan (double dose) was given. We next looked at blood counts in each individual rabbit, and we considered absolute values for these counts rather than relative reduction, to determine if any rabbits reached the level of a true cytopenia.¹⁸ In general, no patterns of sustained neutropenia, anemia, or thrombocytopenia were seen following intra-arterial melphalan infusion. Occasional rabbits had neutrophil counts that dropped below 1000 transiently, and one rabbit had a platelet count that dropped below 100,000, but all subsequently recovered. One rabbit in the double dose group had a relative reduction in neutrophil count that persisted out to the end of the study, but never reached the level of true neutropenia. Similarly, in patients, there were no cases of chemotherapy induced anemia or thrombocytopenia. However, transient grade 3 or 4 neutropenia was not uncommon, consistent with previous findings,^{2,6} despite the fact that no patient received greater than 0.4 mg/kg. It should be noted that all patients who developed grade 3/4 neutropenia had received triple therapy with melphalan, carboplatin, and topotecan, except for a single patient who had received only carboplatin and topotecan, suggesting that myelosuppressive synergy may be playing a role. Blood counts recovered spontaneously in all patients without the need for blood or platelet transfusions or for granulocyte colony-stimulating factor, consistent with our findings in rabbits.

CONCLUSIONS

Our findings in our rabbit model support the following answers to our initial questions regarding the etiology and nature of toxicity associated with IAC:

1. In experienced hands, the IAC procedure itself does not appear to cause vascular occlusions or vascular damage independent of drug-related toxicity. No evidence of retinal toxicity or vascular compromise was seen in rabbits treated with intra-arterial saline.
2. The particular surgical technique chosen, including whether cannulation with occlusion is employed or not, does not seem to affect adverse events. No vascular complications were seen at standard drug doses with either the standard occlusive technique or the continuous flow technique in our rabbit model.
3. IAC toxicity with melphalan is dose-dependent and appears to affect the entire retina, without obvious predilection for a particular cell type. However, we found evidence that more highly vascularized areas of the retina developed greater damage, and that retinal vascular damage was seen with higher melphalan doses.
4. Melphalan and carboplatin appear to cause very different types of ocular toxicity, with carboplatin causing vasogenic edema with swelling of intraocular and extraocular structures similar to that seen in patients who receive triple IAC therapy.
5. Melphalan-associated retinal toxicity can occur even at "normal" doses, although toxicity is greater with higher doses. In our model, only rabbits that received higher than normal weight-adjusted doses developed vascular toxicity.

Acknowledgments

Supported by a Career Starter Grant from the Knights Templar Eye Foundation (ABD), the Vanderbilt Faculty Research Scholars program (ABD), a Career Development Award from the Research to Prevent Blindness Foundation (ABD), the National Eye Institute grant NIH/NEI 5K08EY027464-02 (ABD); an unrestricted departmental grant from Research to Prevent Blindness to the Vanderbilt Department of Ophthalmology and Visual Sciences; a Department of Veterans Affairs Senior Research Career Scientist Award (AR); the Vanderbilt Ingram Cancer Center Support Grant (CA68485) for core facilities; P41 GM103391-06 and by the National Center for Research Resources; Grant UL1RR024975-01, now at the National Center for Advancing Translational Sciences (2 UL1 TR000445-06). The authors alone are responsible for the content and writing of the paper.

Disclosure: **A.B. Daniels**, Alcon Research Institute (F), Spectrum Pharmaceuticals, Inc. (F), P; **M.T. Froehler**, Balt USA (C), Control Medical (C), Medtronic (F, C), Microvention (F), NeurVana (C), Penumbra (F), Stryker (F, C), Viz.ai (C); **A.H. Nunnally**, None; **J.M. Pierce**, None; **I. Bozic**, None; **C.A. Stone**, None; **P.R. Santapuram**, None; **Y.K. Tao**, Leica Microsystems (R), P; **K.L. Boyd**, None; **L.E. Himmel**, None; **S. Chen**, None; **L. Du**, None; **D.L. Friedman**, P; **A. Richmond**, None

References

1. Abramson DH, Shields CL, Munier FL, Chantada GL. Treatment of retinoblastoma in 2015: agreement and disagreement. *JAMA Ophthalmol*. 2015;133:1341-1347.
2. Abramson DH, Daniels AB, Marr BP, et al. Intra-arterial chemotherapy (ophthalmic artery chemosurgery) for group D retinoblastoma. *PLoS One*. 2016;11:e0146582.
3. Shields CL, Mashayekhi A, Au AK, et al. The international classification of retinoblastoma predicts chemoreduction success. *Ophthalmology*. 2006;113:2276-2280.
4. Shields CL, Jorge R, Say EA, et al. Unilateral retinoblastoma managed with intravenous chemotherapy versus intra-arterial chemotherapy. Outcomes based on the international classification of retinoblastoma. *Asia Pac J Ophthalmol (Phila)*. 2016;5:97-103.
5. Yuan S, Friedman DL, Daniels AB. Alternative chemotherapeutic agents for the treatment of retinoblastoma using the intra-arterial and intravitreal routes: a path forward toward drug discovery. *Int Ophthalmol Clin*. 2017;57:129-141.
6. Dunkel IJ, Shi W, Salvaggio K, et al. Risk factors for severe neutropenia following intra-arterial chemotherapy for intraocular retinoblastoma. *PLoS One*. 2014;9:e108692.
7. Daniels AB, Froehler MT, Pierce JM, et al. Pharmacokinetics, tissue localization, toxicity, and treatment efficacy in the first small animal (rabbit) model of intra-arterial chemotherapy for retinoblastoma. *Invest Ophthalmol Vis Sci*. 2018;59:446-454.
8. Tse BC, Steinle JJ, Johnson D, Haik BG, Wilson MW. Superselective intraophthalmic artery chemotherapy in a nonhuman primate model: histopathologic findings. *JAMA Ophthalmol*. 2013;131:903-911.
9. Susskind D, Hagemann U, Schrader M, Januschowski K, Schnichels S, Aisenbrey S. Toxic effects of melphalan, topotecan and carboplatin on retinal pigment epithelial cells. *Acta Ophthalmol*. 2016;94:471-478.
10. Steinle JJ, Zhang Q, Thompson V, et al. Intra-ophthalmic artery chemotherapy triggers vascular toxicity through endothelial cell inflammation and leukostasis. *Invest Ophthalmol Vis Sci*. 2012;53:2439-2445.
11. Fischer C, Petriccione M, Vitolano S, Guarini E, Davis ME, Dunkel IJ. The effect of ophthalmic artery chemosurgery on immune function in retinoblastoma patients: a single institution retrospective analysis. *J Pediatr Hematol Oncol*. 2017;39:555-559.

12. Gyorloff K, Andreasson S, Ehinger B. Standardized full-field electroretinography in rabbits. *Doc Ophthalmol*. 2004;109:163-168.
13. Bozic I, Li XY, Tao YK. Quantitative biometry of zebrafish retinal vasculature using optical coherence tomographic angiography. *Biomed Opt Express*. 2018;9:1244-1255.
14. Abramson DH, Marr BP, Francis JH, et al. Simultaneous bilateral ophthalmic artery chemosurgery for bilateral retinoblastoma (tandem therapy). *PLoS One*. 2016;11:e0156806.
15. Gobin YP, Dunkel IJ, Marr BP, Brodie SE, Abramson DH. Intra-arterial chemotherapy for the management of retinoblastoma: four-year experience. *Arch Ophthalmol*. 2011;129:732-737.
16. Klufas MA, Gobin YP, Marr B, Brodie SE, Dunkel IJ, Abramson DH. Intra-arterial chemotherapy as a treatment for intraocular retinoblastoma: alternatives to direct ophthalmic artery catheterization. *AJNR Am J Neuroradiol*. 2012;33:1608-1614.
17. Abruzzo TA, Geller JI, Kimbrough DA, et al. Adjunctive techniques for optimization of ocular hemodynamics in children undergoing ophthalmic artery infusion chemotherapy. *J Neurointerv Surg*. 2015;7:770-776.
18. Manning PJ, Ringler DH, Newcomer CE. *The Biology of the Laboratory Rabbit*. 2nd ed. San Diego, CA: Academic Press; 1994.
19. Eagle RC Jr, Shields CL, Bianciotto C, Jabbour P, Shields JA. Histopathologic observations after intra-arterial chemotherapy for retinoblastoma. *Arch Ophthalmol*. 2011;129:1416-1421.
20. Wilson MW, Haik BG, Dyer MA. Superselective intraophthalmic artery chemotherapy: what we do not know. *Arch Ophthalmol*. 2011;129:1490-1491.
21. Fallaha N, Dubois J, Carret AS, Callejo SA, Hamel P, Superstein R. Real-time ophthalmoscopic findings of intraophthalmic artery chemotherapy in retinoblastoma. *Arch Ophthalmol*. 2012;130:1075-1077.
22. Bianciotto C, Shields CL, Iturralde JC, Sarici A, Jabbour P, Shields JA. Fluorescein angiographic findings after intra-arterial chemotherapy for retinoblastoma. *Ophthalmology*. 2012;119:843-849.
23. Wilson MW, Jackson JS, Phillips BX, et al. Real-time ophthalmoscopic findings of superselective intraophthalmic artery chemotherapy in a nonhuman primate model. *Arch Ophthalmol*. 2011;129:1458-1465.
24. Ditta LC, Choudhri AF, Tse BC, et al. Validating a nonhuman primate model of super-selective intraophthalmic artery chemotherapy: comparing ophthalmic artery diameters. *Invest Ophthalmol Vis Sci*. 2012;53:7791-7794.
25. Fifi JT, Meyers PM, Lavine SD, et al. Complications of modern diagnostic cerebral angiography in an academic medical center. *J Vasc Interv Radiol*. 2009;20:442-447.
26. Al-Ameri H, Thomas ML, Yoon A, et al. Complication rate of diagnostic carotid angiography performed by interventional cardiologists. *Catheter Cardiovasc Interv*. 2009;73:661-665.
27. Tsimpida M, Thompson DA, Liasis A, et al. Visual outcomes following intraophthalmic artery melphalan for patients with refractory retinoblastoma and age appropriate vision. *Br J Ophthalmol*. 2013;97:1464-1470.
28. Tuncer S, Sencer S, Kebudi R, Tanyildiz B, Cebeci Z, Aydin K. Superselective intra-arterial chemotherapy in the primary management of advanced intra-ocular retinoblastoma: first 4-year experience from a single institution in Turkey. *Acta Ophthalmol*. 2016;94:e644-e651.
29. Ghassemi F, Ghanaati H, Karkhaneh R, Boujabadi L, Tabatabaie SZ, Rajabi MT. Outcome of retinoblastoma following limited sessions of intra-arterial chemotherapy in iran. *Iran J Radiol*. 2014;11:e16958.
30. Rishi P, Sharma T, Koundanya V, et al. Intra-arterial chemotherapy for retinoblastoma: First Indian report. *Indian J Ophthalmol*. 2015;63:331-334.
31. Dalvin LA, Ancona-Lezama D, Lucio-Alvarez JA, Masoomian B, Jabbour P, Shields CL. Ophthalmic vascular events after primary unilateral intra-arterial chemotherapy for retinoblastoma in early and recent eras. *Ophthalmology*. 2018;125:1803-1811.
32. Francis JH, Abramson DH, Gobin YP, et al. Electroretinogram monitoring of dose-dependent toxicity after ophthalmic artery chemosurgery in retinoblastoma eyes: six year review. *PLoS One*. 2014;9:e84247.
33. Reddy MA, Naeem Z, Duncan C, et al. Reduction of severe visual loss and complications following intra-arterial chemotherapy (IAC) for refractory retinoblastoma. *Br J Ophthalmol*. 2017;101:1704-1708.