

# Changes in choriocapillaris and retinal morphology after laser photocoagulation by OCT angiography

## A case report

Takeshi Iwase, MD\*, Yoshitaka Ueno, MD, Eimei Ra, MD, Yasuki Ito, MD, Hiroko Terasaki, MD

### Abstract

**Rationale:** Earlier studies have shown that laser photocoagulation treatments are associated with good long-term visual acuity in most patients with severe nonproliferative diabetic retinopathy (S-NPDR). Histopathologic studies of autopsied eyes have demonstrated defects in the choriocapillaris beneath the retinal laser lesions secondary to photocoagulation for S-NPDR. These lesions have been observed to expand centrifugally over time especially in the posterior pole, and the atrophy of the retinal pigment epithelium (RPE) can be significantly enlarged. There are, however, limited studies detailing the in vivo changes that occur in the RPE and choriocapillaris following laser photocoagulation.

**Patient concerns:** A 46-year-old woman presented with visual disturbances in both eyes.

**Diagnoses:** Fundus examinations showed many retinal hemorrhages and soft exudates in the four quadrants due to S-NPDR.

**Interventions:** Laser photocoagulations with a 532-nm wavelength argon laser with power of 170 to 230 mW and spot size of 200  $\mu\text{m}$  were performed to treat the S-NPDR. The changes in the choriocapillaris and retinal vasculature were followed by optical coherence tomography (OCT) angiography.

**Outcomes:** The choriocapillaris beneath the laser spots was disrupted from 1 hour following the photocoagulation but it was restored at week 2. The choriocapillaris appeared almost normal at some laser spots, but they were still some spots that were altered at 1 year. The outer retina and RPE were disrupted beneath the laser spots at 1 year. On the contrary, there were no visible retinal vascular changes in the superficial and deep plexuses of retinal vasculature determined by OCT angiography with manual and automated segmentation.

**Lessons:** The choriocapillaris in human eyes can recover after laser photocoagulation although the outer retina and RPE remain disrupted and do not recover.

**Abbreviations:** DM = diabetes mellitus, OCT = optical coherence tomography, RPE = retinal pigment epithelium, S-NPDR = severe nonproliferative diabetic retinopathy.

**Keywords:** choriocapillaris, disruption, laser photocoagulation, optical coherence tomography angiography, restoration

## 1. Introduction

Diabetic retinopathy is the most important ocular complication in patients with diabetes mellitus (DM). Studies have demonstrated that laser photocoagulation treatments are associated with good long-term visual acuity in most patients with severe nonproliferative diabetic retinopathy (S-NPDR).<sup>[1]</sup> Histopatho-

logic studies of autopsied eyes have shown defects in the choriocapillaris beneath the laser lesions due to the photocoagulation for the diabetic retinopathy.<sup>[2]</sup> These lesions have been observed to expand *centrifugally* with time especially in the posterior pole, and the atrophy of the retinal pigment epithelium (RPE) can be significantly enlarged.<sup>[3,4]</sup>

Optical coherence tomography (OCT) angiography enables noninvasive, depth-resolved images of the retinal and choroidal vasculature. The discomfort of the patients is minimal, and OCTA can be performed repeatedly at short intervals. New OCTA findings have been reported in a variety of fundus abnormalities, and they have provided more detailed information on the retinal capillary networks.<sup>[5]</sup> However, there have been only a few studies detailing the in vivo changes that occur in the RPE and choriocapillaris following laser photocoagulation.

Thus, the purpose of this study was to evaluate the changes in the RPE and choriocapillaris determined by OCTA after laser photocoagulation.

## 2. Case presentation

A 46-year-old woman was referred to our hospital due to S-NPDR (Fig. 1A). We performed laser photocoagulations with a

Editor: N/A.

The authors have no funding and conflicts of interest to disclose.

Department of Ophthalmology, Nagoya University Graduate School of Medicine, Nagoya, Japan.

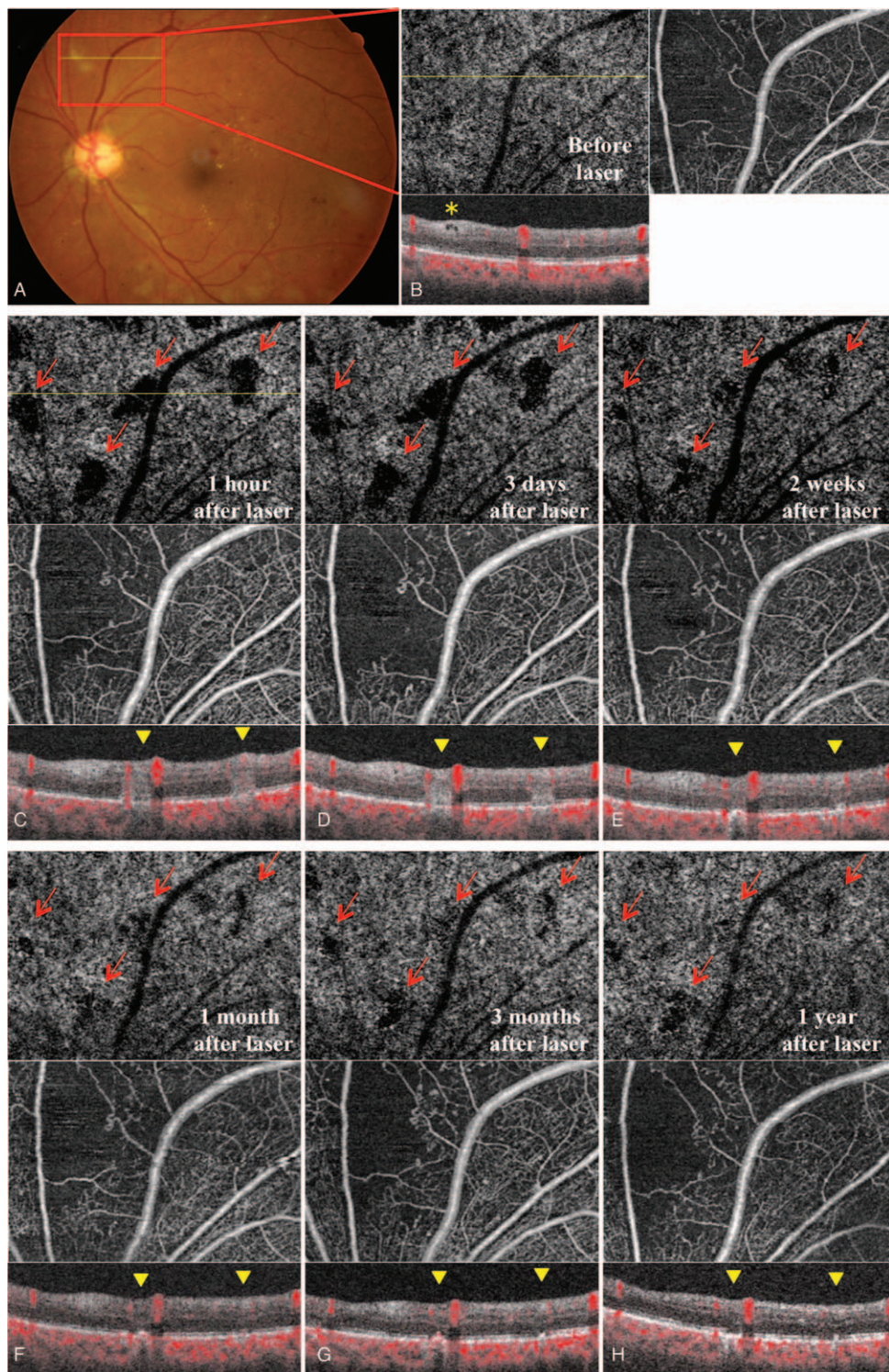
\* Correspondence: Takeshi Iwase, Department of Ophthalmology, Nagoya University Graduate School of Medicine, 65 Tsurumai-cho, Showa-ku, Nagoya 466-8560, Japan (e-mail: tsuyoshilwase@aol.com).

Copyright © 2018 the Author(s). Published by Wolters Kluwer Health, Inc. This is an open access article distributed under the terms of the Creative Commons Attribution-Non Commercial-No Derivatives License 4.0 (CCBY-NC-ND), where it is permissible to download and share the work provided it is properly cited. The work cannot be changed in any way or used commercially without permission from the journal.

Medicine (2018) 97:46(e13278)

Received: 5 July 2018 / Accepted: 23 October 2018

<http://dx.doi.org/10.1097/MD.0000000000013278>



**Figure 1.** Fundus photographs and optical coherence tomography (OCT) angiography images. (A) Fundus photograph showing many retinal hemorrhages and soft exudates in the 4 quadrants of the eye. (B) OCT angiography image segmented at the level of the choriocapillaris and the superficial of plexus of the retinal vasculature before laser treatment. OCT B scan was taken at the level of yellow arrow at sites corresponding to the soft exudate. OCT B scan shows edema in the inner retina (yellow asterisk). (C) The choriocapillaris is disrupted as shown by the black empty region in the OCT angiography image 1 hour after the laser photocoagulation. OCT B scan shows the photocoagulation burn as a white region in the intraretinal layer and blood flow signal is not observed at the level of choriocapillaris layer beneath the retinal laser lesions (yellow arrowhead). (D) Three days after the laser treatment, the findings in the OCT angiography and OCT B scan images were not significantly different from that at 1 hour after the laser treatment. (E) Two weeks after the laser treatment, the disruptions of the choriocapillaris corresponding to the sites of the laser spots that were seen as black areas have become smaller and the structure of choriocapillaris is restored in all of the laser spots (red arrows). OCT B scan shows that blood flow signal is observed beneath the retinal laser lesions. (F) The disruption of the choriocapillaris has become smaller, and the structure of the choriocapillaris can be seen more clearly in all of the laser spots at 1 month after the laser treatment (red arrows). OCT B scan shows that the laser lesion has shrunk in a transverse direction and the outer nuclear layer is also shrunk and the inner nuclear layer has widened. (G) The disruption of choriocapillaris is more restored in some laser spots 3 month after laser photocoagulation (red arrows). (H) OCT angiography taken 1 year after the laser treatment. The choriocapillaris has become almost normal appearing in some laser spots.

532-nm wavelength argon laser with power of 170 to 230 mW and spot size of 200  $\mu\text{m}$  on the left eye and followed the changes in the choriocapillaris and the retinal vasculature by OCT angiography (Zeiss Cirrus 5000 HD-OCT; Zeiss Meditec Inc, Jena, Germany) before (Fig. 1B) and after the laser photocoagulation.

This study was conducted at the Nagoya University Hospital and the procedures used were approved by the Ethics Committee of the Nagoya University Hospital. The procedures conformed to the tenets of the Declaration of Helsinki, and an informed written consent was obtained for the treatments and publication of this case report and accompanying images after an explanation of the procedures to be used and the possible complications.

The choriocapillaris was disrupted as shown by the black empty region in the OCTA image 1 hour after the laser photocoagulation (Fig. 1C). There were no visible retinal vascular changes in the superficial plexus of the retinal vasculature throughout the postlaser period. However, 2 weeks after the laser treatment, the disruption of the choriocapillaris corresponding to the sites of the laser spots that were seen as black areas had become smaller. The structure of the choriocapillaris was restored in all of the laser spots which were observed as black areas at 1 and 3 days after the laser photocoagulation (Fig. 1D, E). OCT B scan showed that the laser burn in the intraretinal layer was not evident, and blood flow signals were observed beneath the retinal laser lesions. The degree of disruption of the choriocapillaris was smaller, and the structure of the choriocapillaris could be seen more clearly at all of the laser spots with increasing time (Fig. 1F, G). In addition, OCT B scan images showed that the laser lesions had shrunk in a transverse direction and the outer nuclear layer was also shrunk and the inner nuclear layer had widened. At 1 year, the choriocapillaris was almost normal appearing at some laser spots but was still altered in other laser lesions (Fig. 1H). However, the outer retina and RPE remained disrupted at the lasered spots 1 year after the laser photocoagulation.

### 3. Discussion

The choriocapillaris is a thin, dense, monolayer<sup>[6]</sup> that consists of fenestrated capillaries that are organized in a unique segmental, lobular pattern. Some histopathologic studies of laser scars in humans show a disruption of the choriocapillaris and a lack of recovery.<sup>[2,7]</sup> Recent studies of laser lesions by OCT angiography have shown that the choriocapillaris is altered in regions treated with laser burns.<sup>[5]</sup> There are, however, only a limited number of studies detailing the *in vivo* changes that occur in the choriocapillaris before and after laser photocoagulation.

The structural changes in the retina and choroid induced by laser photocoagulation depend on the laser parameters such as the wavelength, power, exposure time, and spot size. Accordingly, the difference in the degree of restoration among the laser spots might be due to differences in the power used for the photocoagulation. Higaki et al reported that the expansion rates of the laser lesion in short-pulse laser were significantly lower than those after conventional laser.<sup>[8]</sup> Our results showed a restoration of the choriocapillaris at 2 weeks, and the recovery continued with time and was almost normal appearing at 1 year in some lasered spots with our laser settings using OCTA. On the contrary, the outer retina and RPE were also disrupted in the lasered spots 1 year after the laser photocoagulation.

Perry et al reported a recovery of the capillary integrity in feline eyes following laser photocoagulation which appeared to result

from thrombolysis and proliferation of endothelial cells of the choriocapillaris. In time, the entire vascular integrity was restored without recanalization, and the choriocapillaris appeared almost normal in the laser photocoagulated areas after 30 days.<sup>[9]</sup>

Our study has several limitations. First, this was a retrospective case report. Second, it has been reported that choroidal thickness<sup>[10]</sup> and blood flow<sup>[11]</sup> are decreased after laser photocoagulation even in the not laser lesion in the macular area. However, current commercially available OCT angiography cannot detect the choroidal structure and blood flow under choriocapillaris such as in Sattler layer and Haller layer that play a role in the main choroidal blood flow. Further prospective studies with larger sample sizes and assessments of deep choroidal layer are required.

In conclusion, our results showed a restoration of the choriocapillaris from 2 weeks after laser photocoagulation and a recovery with time in some lasered spots using OCT angiography. These results indicate a possibility that the choriocapillaris can recover in human eyes although the outer retina and RPE are disrupted and not regenerated after the laser treatment.

### Author contributions

**Conceptualization:** Takeshi Iwase.

**Data curation:** Takeshi Iwase, Eimei Ra, Yoshitaka Ueno.

**Methodology:** Takeshi Iwase, Yoshitaka Ueno.

**Validation:** Takeshi Iwase, Eimei Ra, Yasuki Ito, Hiroko Terasaki, Yoshitaka Ueno.

**Visualization:** Takeshi Iwase, Eimei Ra, Hiroko Terasaki, Yasuki Ito.

**Writing – original draft:** Takeshi Iwase.

### References

- [1] Chew EY, Ferris FL3rd, Csaky KG, et al. The long-term effects of laser photocoagulation treatment in patients with diabetic retinopathy: the early treatment diabetic retinopathy follow-up study. *Ophthalmology* 2003;110:1683–9.
- [2] Wilson DJ, Green WR. Argon laser panretinal photocoagulation for diabetic retinopathy. Scanning electron microscopy of human choroidal vascular casts. *Arch Ophthalmol* 1987;105:239–42.
- [3] Schatz H, Madeira D, McDonald HR, et al. Progressive enlargement of laser scars following grid laser photocoagulation for diffuse diabetic macular edema. *Arch Ophthalmol* 1991;109:1549–51.
- [4] Morgan CM, Schatz H. Atrophic creep of the retinal pigment epithelium after focal macular photocoagulation. *Ophthalmology* 1989;96:96–103.
- [5] Cole ED, Novais EA, Louzada RN, et al. Visualization of changes in the choriocapillaris, choroidal vessels, and retinal morphology after focal laser photocoagulation using OCT angiography. *Invest Ophthalmol Vis Sci* 2016;57:OCT356–61.
- [6] de Carlo TE, Romano A, Waheed NK, et al. A review of optical coherence tomography angiography (OCTA). *Int J Retina Vitreous* 2015;1:5.
- [7] Stitt AW, Gardiner TA, Archer DB. Retinal and choroidal responses to panretinal photocoagulation: an ultrastructural perspective. *Graefes Arch Clin Exp Ophthalmol* 1995;233:699–705.
- [8] Higaki M, Nozaki M, Yoshida M, et al. Less expansion of short-pulse laser scars in panretinal photocoagulation for diabetic retinopathy. *J Ophthalmol* 2018;2018:9371895.
- [9] Perry DD, Reddick RL, Risco JM. Choroidal microvascular repair after argon laser photocoagulation. Ultrastructural observations. *Invest Ophthalmol Vis Sci* 1984;25:1019–26.
- [10] Zhang Z, Meng X, Wu Z, et al. Changes in choroidal thickness after panretinal photocoagulation for diabetic retinopathy: a 12-week longitudinal study. *Invest Ophthalmol Vis Sci* 2015;56:2631–8.
- [11] Mikoshiba Y, Iwase T, Ueno Y, et al. A randomized clinical trial evaluating choroidal blood flow and morphology after conventional and pattern scan laser panretinal photocoagulation. *Sci Rep* 2018;8:14128.