


# Radiofrequency catheter ablation of premature ventricular contractions from the mitral annulus in patients without structural heart disease

Yoshibumi Antoku MD<sup>1,2</sup> | Masao Takemoto MD, PhD<sup>1,2</sup>  | Atsushi Tanaka MD, PhD<sup>3,2</sup> |  
Takahiro Mito MD, PhD<sup>5,2</sup> | Akihiro Masumoto MD, PhD<sup>4</sup> | Takafumi Ueno MD, PhD<sup>4</sup> |  
Takuya Tsuchihashi MD, PhD<sup>1</sup>

<sup>1</sup> Cardiovascular Center, Steel Memorial Yawata Hospital, Kitakyusyu, Japan

<sup>2</sup> Cardiology, Munakata Suikokai General Hospital, Fukutsu, Japan

<sup>3</sup> Saiseikai Fukuoka General Hospital, Fukuoka, Japan

<sup>4</sup> Cardiology, Fukuoka Kinen Hospital, Fukuoka, Japan

<sup>5</sup> Cardiology, Hakujuji Hospital, Fukuoka, Japan

## Correspondence

Masao Takemoto, MD, PhD, Cardiovascular Center, Steel Memorial Yawata Hospital, 1-1-1 Haruno-machi, Yahatahigashi-ku, Kitakyushu 805-8508, Japan.

Email: [matakemo@kc4.so-net.ne.jp](mailto:matakemo@kc4.so-net.ne.jp)

Authors Antoku, Tanaka, and Mito contributed equally to this paper.

## Abstract

**Introduction:** We previously reported the clinical benefits of radiofrequency catheter ablation (RFCA) of premature ventricular contractions (PVCs) from the right ventricular outflow tract or near the His-bundle, which can often deteriorate the clinical status. PVCs from the mitral valve (MA-PVCs) also often deteriorate the patients' clinical status. This study aimed to evaluate the effect of ablating MA-PVCs with RFCA from a trans-interatrial septal approach on the clinical status in symptomatic patients with frequent MA-PVCs without structural heart disease.

**Methods:** The frequency of PVCs per the total heart beats by 24-hours Holter monitoring and New York Heart Association (NYHA) functional class in 22 patients with MA-PVCs were evaluated before and 6 months after RFCA.

**Results:** Procedural success was achieved in 20 (91%) of 22 patients. Of the 22 patients, in 15 (68%) and 1 (5%) patient, a successful RFCA on the left ventricular side of the MA using the trans-interatrial septal approach and trans-coronary sinus approach was achieved. Interestingly, in four (18%) patients, a successful RFCA on the left atrial (LA) side of the MA using a trans-interatrial septal approach was achieved. Ablating MA-PVCs readily improved the NYHA functional class compared to that before. A  $\geq 0.62$  peak deflection index and  $\leq 30$  years old may be one of the important predictors of successfully ablated MA-PVCs from the LA side of the MA.

**Conclusions:** RFCA produces clinical benefits in patients with MA-PVCs. Further, it may be necessary to initially consider a trans-interatrial septal approach to ablate these PVCs.

## KEYWORDS

catheter ablation, clinical characteristics, clinical status, mitral annulus, premature ventricular contraction, trans-interatrial septal approach

## 1 | INTRODUCTION

Isolated premature ventricular contractions (PVCs) are the most common arrhythmias observed in daily clinical practice even in patients without structural heart disease.<sup>1</sup> Many patients with frequent PVCs not only often experience disabling symptoms, and sometimes, need long-term antiarrhythmic medication, but also they can cause left ventricular (LV) dysfunction and increase the incidence of heart failure and mortality.<sup>2</sup> In recent years, radiofrequency catheter ablation (RFCA) has proven to be a safe and successful therapy for arrhythmias including PVCs.<sup>1,3</sup> Moreover, we previously and recently reported the clinical benefit of RFCA of PVCs from the right ventricular outflow tract (RVOT-PVCs),<sup>1</sup> which are one of the most common types of PVCs, and from near the His-bundle,<sup>3</sup> which are a comparably uncommon type of PVC. In particular, eliminating frequent RVOT-PVCs by RFCA could steadily improve the clinical status.<sup>4</sup> Although PVCs from near the mitral annulus (MA) (MA-PVCs) are also comparably uncommon, they also often cause a deterioration of the patients' clinical status. Thus, the purpose of this study was to evaluate the effect of ablating MA-PVCs with RFCA from a trans-interatrial septal approach on the clinical status of symptomatic patients with frequent MA-PVCs without structural heart disease.

## 2 | MATERIAL AND METHODS

### 2.1 | Study population and laboratory analysis

This study was approved by the institutional review committee and ethics review board of our hospitals. From 2014 to 2019, 22 consecutive intolerably symptomatic patients with drug (including beta-blockers, calcium-channel blockers, and class I agents of the Vaughan Williams classification) refractory MA-PVCs visited our hospitals to undergo RFCA. All patients had their history recorded, and underwent a physical examination, laboratory analysis, 12-lead electrocardiography (12-ECG), 24-hours Holter monitoring, and echocardiography, on admission or within at least 1 month before admission. All the echocardiography values were recorded during sinus rhythm, but not during PVC beats, nor post-PVC beats. The New York Heart Association (NYHA) functional class using a specific activity scale was evaluated on admission and 6-months after the RFCA. All patients also underwent exercise stress testing, cardiac catheterization with coronary angiography, and / or <sup>201</sup>-thallium scintigraphy. Those examinations yielded no evidence of clinically overt structural heart disease, including coronary artery disease, valvular heart disease, congenital heart disease, LV hypertrophy, or right ventricular abnormalities in all patients.

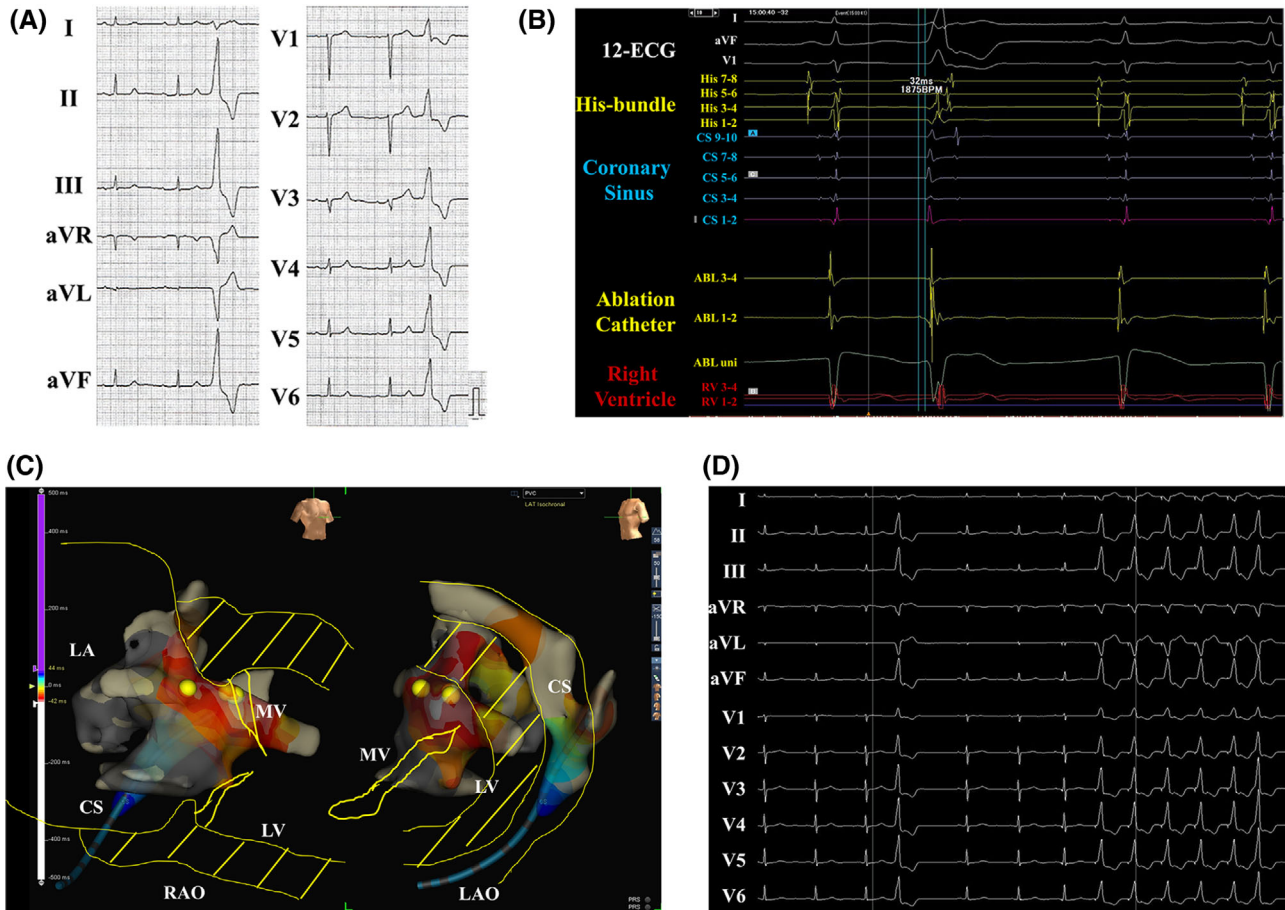
### 2.2 | Definition of MA-PVC

MA-PVCs were defined as having a characteristic electrocardiographic appearance of a right bundle branch block morphology in V1 and positive concordant R waves in the precordial leads including V1-6 (Figure 1A). Ventricular tachycardia (VT) was defined with standard electrocardiographic criteria including at least three consecutive

PVCs at a rate of >120 beats per minute. Patients with VT and atrial tachyarrhythmias including atrial fibrillation, atrial flutter, atrial tachycardia, and paroxysmal supra-VT were excluded from this study because they may deteriorate the NYHA functional status. The patients who received hemodialysis during this study were also excluded from this study.

### 2.3 | Mapping and catheter ablation procedure

All procedures were performed after written informed consent was obtained. Anti-arrhythmic drugs were withdrawn in all patients at least five half-lives before the procedure. The antihypertensive and antihypercholesterolemic agents and/or others were continued in patients with hypertension and dyslipidemia before and after the RFCA. The antidiabetic agents in patients with diabetes mellitus were continued before and after the RFCA but not on the procedural day. The QRS duration and peak deflection index (PDI)<sup>5</sup> were measured before the RFCA. RFCA was performed under local anesthesia. After a 50 unit per kilogram administration of heparin was administered, 4- or 5-mm-tip electrode catheters (St. Jude Medical, St. Paul, MN, USA) were introduced percutaneously into the right ventricle and coronary sinus, respectively. A 100 unit per kilogram administration of heparin was administered following the trans-interatrial septal puncture guided by the intracardiac echocardiography (ViewFlex Xtra ICE catheter, Abbott, Plymouth, MN, USA) that was the most helpful tool to visualize the exact location of the tip of the ablation catheter with regard to the MA. Then, the heparinized saline was additionally infused to maintain the activated clotting time at 300 to 350 seconds. After left atrio- and ventriculography (Figure 2A), electroanatomical mapping during the PVCs was performed in the coronary sinus and around the MA, left atrium (LA), and LV near the MA in detail utilizing a 3D mapping system (EnSite NavX / Velocity™ Cardiac Mapping System, St. Jude Medical, St. Paul, MN) by a circular mapping catheter (Inquiry™ AFocusII™ Double Loop Catheter, St. Jude Medical) or high-density mapping catheter (Advisor™ HD Grid catheter, Abbott) during culprit PVCs. If the culprit PVC was not found during the procedure, an isoproterenol administration and/or programmed electrical stimulation with a digital stimulator (Cardiac Stimulator, Nihon Kohden Co., Tokyo, Japan) was performed to induce the culprit PVC. Then, an open irrigated 3.5-mm-tip ablation catheter (FlexAbility™, St. Jude Medical) through a steerable introducer (Agilis™ NxT, Abbott) was positioned at the MA. An optimal pace map was defined as a match of all 12 surface leads by comparing the R/S ratio and subtle notching in the QRS complex during pacing. An identical match was necessary in at least 11 of 12 leads. Further, based on the findings of the electroanatomical mapping and an optimal pace map, radiofrequency energy was delivered at the site of the unipolar potentials from the ablation catheter demonstrating a QS pattern and bipolar potentials from the tip of the ablation catheter preceding the QRS in the 12-ECG by at least 20-30 milliseconds during the PVC with a preset temperature of 43 to 50°C and power limit of 30-35 W. Further, when the radiofrequency energy was delivered from the coronary sinus, in order to avoid any complications, (a) heparinized saline was additionally infused to maintain the



**FIGURE 1** The 12-lead electrocardiograms in the patients with premature ventricular contractions from the mitral annulus (MA) (A). The EnSite™ 3D-mapping images of the earliest activation sites during the culprit PVCs (BE), intracardiac electrocardiograms (CF), and 12 ECGs during the pace map (DG) at the successful ablation sites on the ventricular side of the MA (BCD) or left atrium side of the MA (EFG) with the trans-interatrial septal approach

activated clotting time at more than 300 seconds; (b) before the RFCA, left coronary angiography was performed to confirm that the ablation site was far enough away from the coronary arteries, (c) a maximum power setting of 20 W for the radiofrequency energy was chosen, and (d) careful attention to and observation of the patient was paid during the radiofrequency energy delivery as we previously reported.<sup>6</sup> The radiofrequency energy application was terminated when an abnormal impedance rise ( $>30 \Omega$ ) was observed. A successful ablation was defined as no recurrence and non-inducibility of the culprit PVC with and without an isoproterenol administration and/or programmed electrical stimulation for at least 30 minutes after the ablation. Procedural success was defined as no recurrence of the culprit PVC within 24 hours after the procedure under electrocardiographic monitoring. If the recurrence of the culprit PVC was observed, a repeat RFCA was considered.

## 2.4 | Statistical analysis

The numerical results are expressed in the text as the mean  $\pm$  standard deviation. Paired data were compared by a Fisher's exact test and Student's t-test or Wilcoxon signed-rank test. The sensitivity and specificity of the PDI and age at the time the successful ablation was

performed at a site on the LA side of the MA were evaluated by a receiver-operating characteristic (ROC) curve analysis. All analyses were performed with SAS version 9.2 software (SAS Institute, Cary, NC). A  $P$  of  $<.05$  was considered to indicate statistical significance.

## 3 | RESULTS

### 3.1 | Clinical characteristics of the patients with MA-PVCs on admission

The baseline characteristics of all 22 patients (14 males and 8 females with a mean age of  $61 \pm 19$  years, body mass index [BMI] of  $25.3 \pm 4.9 \text{ kg/m}^2$ , and serum creatinine of  $0.95 \pm 0.78 \text{ mg/dl}$ ) are shown in Tables 1 and 2. The prevalence of an inferior axis of the PVC, coexistence of hypertension, dyslipidemia, diabetes mellitus, and ex- or current smoking was 95%, 50%, 27%, 18%, and 45%, respectively. All patients had MA-PVCs-associated symptoms including palpitations (95%), general fatigue (45%), chest discomfort/pain (32%), and fainting (14%). Although the LV ejection fraction (EF) (LVEF) by echocardiogram was preserved at  $66 \pm 11\%$ , the NYHA functional class using a specific activity scale mildly deteriorated to  $2.00 \pm 0.62$ . Sixteen out of 22

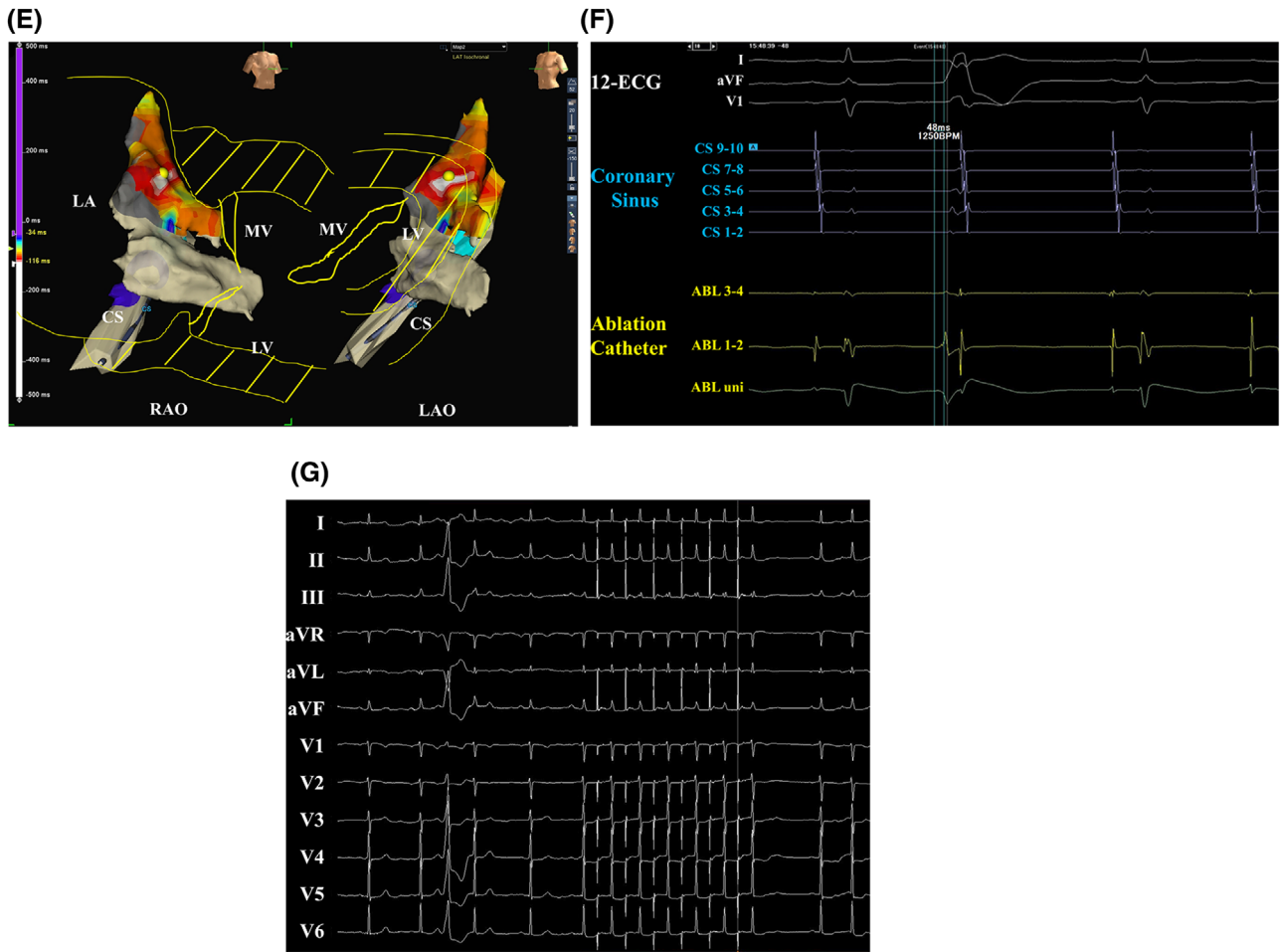
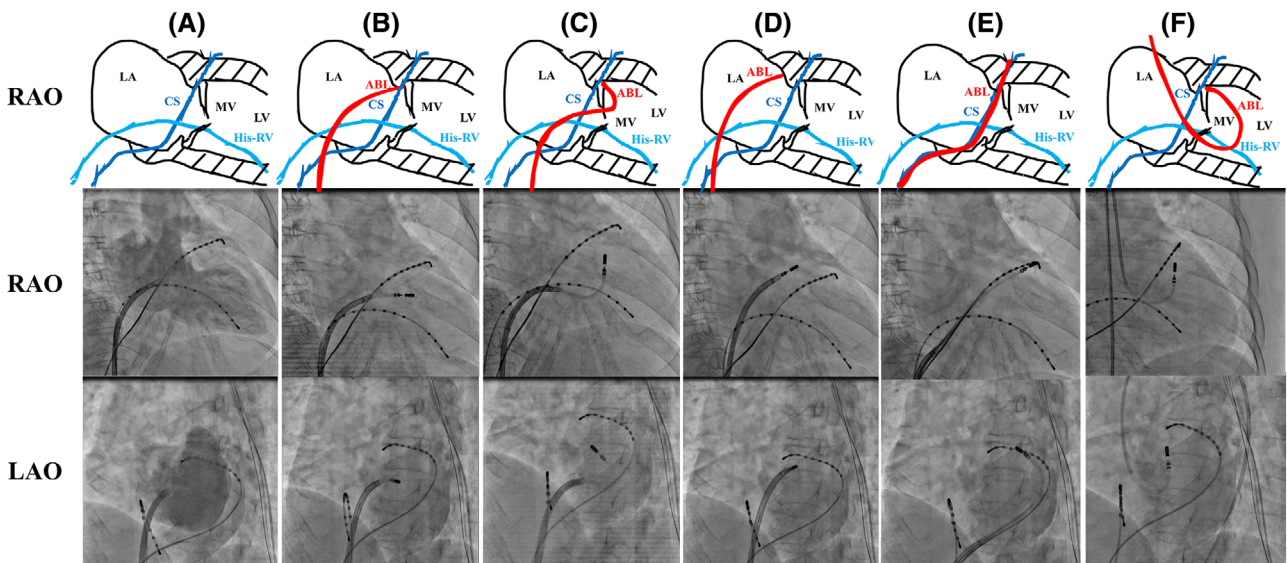


FIGURE 1 Continued



**FIGURE 2** The left atrio- and ventriculography (A) and the approach sites of the radiofrequency catheter ablation on the ventricular side of the mitral annulus (MA) from the supramitral valve (B), inframitral valve (C), and left atrial side of the MA (D) from the trans-interatrial septal approach, from the trans-coronary sinus approach (E), and from the trans-aortic approach (F). The LA, LV, MV, ABL, CS, and His-RV indicate the left atrium, left ventricle, mitral valve, ablation catheter, coronary sinus, and His-bundle and right ventricle, respectively. The upper and middle and lower panels were the right (RAO) and left anterior oblique (LAO) view of the LA and LV, respectively. The red, blue, and water blue bar indicate the ablation catheter and the electrodes placed on the CS and His-RV, respectively

**TABLE 1** Clinical characteristics in patients with PVCs from the mitral annulus on admission

	All (n = 22)	Successful (n = 20)	LA-G (n = 4)	P value; LV versus LA	CS-G (n = 1)	Unsuccessful (n = 2)
Male	14 (64%)	9 (60%)	2 (50%)	.737	1 (100%)	2 (100%)
Age (years)	61 ± 19	68 ± 12	36 ± 21	.001	43	68
Body mass index (kg/m <sup>2</sup> )	25.3 ± 4.9	25.1 ± 4.6	24.3 ± 1.5	.730	38.4	22.7
Serum creatinine (mg/dL)	0.95 ± 0.78	1.06 ± 0.94	0.68 ± 0.12	.441	0.79	0.80
<b>Electrocardiography; Axis of PVC</b>						
Inferior axis	21 (95%)	14 (93%)	4 (100%)	.948	1 (100%)	2 (100%)
Superior axis	1 (5%)	1 (7%)	0 (0%)	.948	0 (0%)	0 (0%)
<b>Co-existence</b>						
Hypertension	11 (50%)	8 (53%)	1 (25%)	.341	1 (100%)	1 (50%)
Dyslipidemia	6 (27%)	4 (27%)	1 (25%)	.950	0 (0%)	1 (50%)
Diabetes mellitus	4 (18%)	3 (20%)	0 (0%)	.357	1 (100%)	0 (0%)
Ex or current smoking	10 (45%)	7 (47%)	1 (25%)	.464	1 (100%)	1 (50%)
<b>Symptoms</b>						
Palpitations	21 (95%)	14 (93%)	4 (100%)	.620	1 (100%)	2 (100%)
General fatigue	10 (45%)	7 (47%)	1 (25%)	.464	1 (100%)	1 (50%)
Chest discomfort/pain	7 (32%)	6 (40%)	0 (0%)	.141	0 (0%)	1 (50%)
Fainting	3 (14%)	2 (13%)	0 (0%)	.468	0 (0%)	1 (50%)
<b>Medications</b>						
Beta blockers	12 (55%)	8 (53%)	2 (50%)	.912	1 (100%)	1 (50%)
Calcium channel blockers	4 (18%)	1 (7%)	2 (50%)	.036	0 (0%)	1 (50%)
class I agents	5 (23%)	3 (20%)	1 (25%)	.839	0 (0%)	1 (50%)
No medication	6 (27%)	4 (27%)	1 (25%)	.950	0 (0%)	1 (50%)

Abbreviations: CS-G, group with an approach from the coronary sinus; LA-G, group with an approach from left atrial side of the mitral annulus; LV-G, group with an approach from the left ventricular side of the mitral annulus; PVC, premature ventricular contraction.

patients took medications including beta-blockers (55%), calcium channel blockers (18%), and/or class I agents of the Vaughan Williams classification (23%). No patients were on amiodarone, sotalol, or bepridil. Although those agents were not sufficiently effective in eliminating the PVC-associated symptoms before the RFCA, all of the patients with a successful procedure reported the absence of any PVC-associated symptoms and could discontinue the antiarrhythmic agents after the RFCA.

### 3.2 | Analysis of the 24-hours Holter monitoring, NYHA functional status, and echocardiogram

Table 2 summarizes the analysis of the 24-hour Holter monitoring, NYHA functional status, and echocardiogram. The frequency of the PVCs (%PVC) was calculated as: [number of PVC / number of total heart beats per 24 hours] × 100. The mean %PVC of the 22 patients in this study was 20.1 ± 8.6%. In both 20 and 2 patients who achieved successful and unsuccessful procedures, respectively, the number of total heart beats did not statistically differ before and after the RFCA. In 20 patients in whom procedural success was achieved, the RFCA significantly reduced the number of total PVCs and %PVCs with no evidence

of a recurrence of the culprit PVC. There was no statistical difference in the frequency of premature atrial contractions before and after the RFCA between the three groups (data not shown). The NYHA functional status significantly improved in 20 patients who achieved procedural success, but not in two patients who did not achieve procedural success. There were no statistical differences in the LVEF and LV thickness of the interventricular septum and posterior wall on echocardiogram between that before and after RFCA.

### 3.3 | Electrophysiological findings and approach sites with a successful RFCA

Table 3 summarizes the results of the electrophysiological findings and successful ablation sites. An RFCA procedure for MA-PVCs was performed in 22 patients. Procedural success was achieved in 20 (91%) of 22 patients. No patients suffered from any procedure-related complications. During the follow-up, recurrence of the culprit MA-PVCs was observed in one patient (5%) whose successful ablation site was the ventricular side of the MA from the inframitral valve. This patient underwent a repeat RFCA with a successful result. The mean QRS

**TABLE 2** Twenty four hours Holter monitoring, NYHA functional class, and serum BNP concentration, in patients with PVCs from the mitral annulus before and after RFCA

	All (n = 22)	Successful (n = 20)		P value; LV versus LA	CS-G (n = 1)	Unsuccessful (n = 2)
		LV-G (n = 15)	LA-G (n = 4)			
<b>Before RFCA</b>						
<b>24-hours Holter monitoring</b>						
Total heart beats (beats per day)	107 654 ± 12 600	110 958 ± 12 650	97 888 ± 4546	.062	113 317	99 572
Total PVC (beats per day)	22 002 ± 10 806	23 628 ± 11 172	15 472 ± 3328	.175	39 661	14 040
%PVC (%)	20.1 ± 8.6	21.0 ± 8.9	15.9 ± 3.7	.282	35.0	13.9
<b>Functional status</b>						
NYHA functional class	2.00 ± 0.62	1.93 ± 0.59	2.00 ± 0.82	.855	3.00	2.00
<b>Echocardiogram</b>						
LVEF (%)	66 ± 11	67 ± 12	72 ± 2	.384	65	50
Inter-ventricular septum (mm)	9.2 ± 1.0	9.4 ± 1.0	8.8 ± 0.5	.259	10	8.5
Posterior wall (mm)	9.1 ± 0.9	9.2 ± 0.7	8.5 ± 1.0	.115	10	8.5
<b>After RFCA</b>						
<b>24-hours Holter monitoring</b>						
Total heart beats (beats per day)	105 628 ± 10 608	108 382 ± 10 891	99 020 ± 8828	.133	109 096	96 459
Total PVC (beats per day)	1300 ± 4053*	99 ± 126*	63 ± 55*	.592	93	13 394
%PVC (%)	1.3 ± 4.2*	0.09 ± 0.11*	0.06 ± 0.06*	.676	0.09	13.9
<b>Functional status</b>						
NYHA functional class	1.09 ± 0.29*	1.00 ± 0.00*	1.00 ± 0.00*	.855	1.00	2.00
<b>Echocardiogram</b>						
LVEF (%)	68 ± 8	69 ± 7	73 ± 3	.384	63	55
Interventricular septum (mm)	9.2 ± 1.0	9.2 ± 0.7	9.0 ± 0.0	.539	10	8.5
Posterior wall (mm)	9.1 ± 0.9	9.4 ± 0.5	8.8 ± 0.5	.259	10	8.5

Abbreviations: CS-G, group with an approach from the coronary sinus; LA-G, group with an approach from the left atrial side of the mitral annulus; LVEF, left ventricular ejection fraction; LV-G, group with an approach from the left ventricular side of the mitral annulus; NYHA, New York Heart Association; PVC, premature ventricular contraction; RFCA, radiofrequency catheter ablation.

\*P < .05 versus before RFCA.

duration and PDI of the PVCs in all 22 patients were  $144 \pm 28$  ms and  $0.60 \pm 0.07$ , respectively. The frequency of the use of a circular mapping catheter (Inquiry™ AFocusII™ Double Loop Catheter, St. Jude Medical) and high-density mapping catheter (Advisor™ HD Grid catheter, Abbott) was 23% and 77%, respectively. The approach sites of the MA-PVCs for the RFCA are demonstrated in Figures 2B-F. Of the 22 patients, in 13 (59%), 2 (9%), and 1 (5%) patient, a successful RFCA on the ventricular side of the MA from the supramitral valve (Figure 2B) and inframitral valve (Figure 2C) using the trans-interatrial septal approach and trans-coronary sinus approach (Figure 2E) was achieved. Interestingly, in 4 (18%) patients, a successful RFCA on the LA side of the MA using a trans-interatrial septal approach was achieved (Figure 2D). A successful RFCA of the MA-PVCs could be achieved in 20 patients with these steps. The notable point was that, of the 20 patients with a successful RFCA, in 19 (95%) patients, a successful RFCA using a trans-interatrial septal approach could be achieved. However, in the remaining two patients, successful results could not be achieved even though additional RFCA using the trans-aortic approach was performed (Figure 2F).

Figures 1B-G demonstrate the EnSite™ 3D-mapping images of the earliest activation sites during the culprit PVCs (Figures 1B and 1E), intra-cardiac electrocardiograms (Figures 1C and 1F), and 12-ECGs of the pace map (Figures 1D and 1G) at the successful ablation sites. The EnSite™ 3D-mapping images demonstrated that the earliest activation sites during the culprit PVCs were confirmed in the white area on the LV (Figure 1B) and LA (Figure 1E) side of the MA. The yellow tags were the successful ablation sites. The findings from the unipolar potentials recorded by the ablation catheter demonstrated a QS pattern, bipolar potentials were recorded by the tip of the ablation catheter that preceded the QRS on the 12-ECG by 32 ms (Figure 1C) during the culprit PVC, and a suboptimal pace map during pace mapping at 9.9 V (Figure 1D) was obtained by the ablation catheter placed at the successful ablation site on the ventricular side of the MA using a supramitral valve approach (Figure 3B). In 14 out of 15 patients (93%) who were successfully ablated from the LV side of the MA, the atrial potentials were not confirmed by the tip of the ablation catheter. On the other hand, the findings from the unipolar potentials recorded by the ablation catheter demonstrated a QS pattern and bipolar potentials

**TABLE 3** Comparison of the electrophysiological findings, successful ablation site, successful rate, complications, and recurrence rate in patients with PVCs from the mitral annulus

	Successful (n = 20)			P value; LV versus LA	CS-G (n = 1)	Unsuccessful (n = 2)
	All (n = 22)	LV-G (n = 15)	LA-G (n = 4)			
<b>Electrophysiological findings of PVCs</b>						
QRS duration (ms)	144 ± 28	140 ± 29	150 ± 20	.564	166	155
Peak deflection index	0.60 ± 0.07	0.58 ± 0.06	0.67 ± 0.05	.016	0.53	0.63
<b>Mapping catheter for the PVCs</b>						
Circular mapping catheter	5 (23%)	4 (27%)	0 (0%)	.270	1 (100%)	0 (0%)
High-density mapping catheter	17 (77%)	11 (73%)	4 (100%)	.270	0 (0%)	2 (100%)
<b>Successful ablation site</b>						
<b>Trans-interatrial septal approach</b>						
Ventricular side of MA from supramitral valve	13 (59%)	13 (87%)	-	-	-	-
Ventricular side of MA from inframitral valve	2 (9%)	2 (13%)	-	-	-	-
Left atrial side of MA	4 (18%)	-	4 (100%)	-	-	-
<b>Trans-coronary sinus approach</b>	1 (5%)	-	-	-	1 (100%)	-
<b>Trans-aortic approach</b>	0 (0%)	-	-	-	-	-
Successful rate	20 (91%)	-	-	-	-	-
Recurrence rate for the first session	1 (5%)	1 (7%)	0 (0%)	.620	0 (0%)	-
Recurrence rate for the second session	0 (0%)	0 (0%)	-	-	-	-
Complications	0 (0%)	0 (0%)	0 (0%)	1.000	0 (0%)	-

Abbreviations: CS-G, group with an approach from the coronary sinus; LA-G, group with an approach from the left atrial side of the mitral annulus; LV-G, group with an approach from the left ventricular side of the mitral annulus; MA, mitral annulus; PVC, premature ventricular contraction.

recorded by the tip of the ablation catheter that preceded the QRS on the 12-ECG by 48 ms (Figure 1F) during the culprit PVC obtained by the ablation catheter placed at the successful ablation site on the LA side of the MA (Figure 1E). Of course, in all four patients, the atrial potentials were confirmed by the tip of the ablation catheter, and pace mapping at varying outputs from 1.0 to 9.9 V on the LA side of the MA (Figure 1E) captured the LA but not the LV (Figure 1G). After radiofrequency energy was delivered at those points, the PVCs were steadily terminated. Figure 3 summarizes the earliest activation sites of the MA-PVCs that were successful (red, blue, green, and purple circles; n = 20) or unsuccessful (black circle; n = 2) RFCA sites in the left anterior oblique view of the MA. They were crowded in the direction from 0:00 to 3:00 in the left anterior oblique view of the MA. The red, blue, green, and purple circles indicate successful ablation sites on the ventricular side of the MA from the supramitral valve (Figure 2B), inframitral valve (Figure 2C), and LA side of the MA (Figure 2D) from the trans-interatrial septal approach and trans-coronary sinus approach (Figure 2E), respectively.

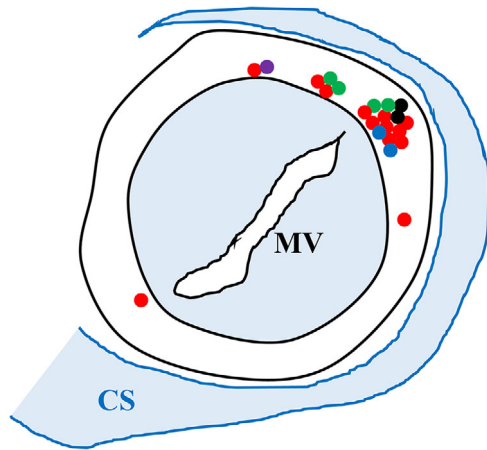
### 3.4 | Comparison of successful ablation sites between the LV side and LA side of the MA

There were 15 and 4 patients whose successful ablation sites were on the LV side (LV group) and LA side (LA group) of the MA, respectively. Tables 1–3 summarize the clinical characteristics (Table 1), results of the analysis of the 24-hours Holter monitoring, clinical status, echocar-

diograms (Table 2), and electrophysiological findings (Table 3) of the two groups. The BMI and serum creatinine levels, prevalence of a male gender, inferior axis of the PVCs, coexistence of hypertension, dyslipidemia, and diabetes mellitus; ex- or current smoking; symptoms including palpitations, general fatigue, chest discomfort/pain, and fainting; and the results of the analysis of the 24-hours Holter monitoring, clinical status, echocardiogram results, and QRS duration of the PVCs did not statistically differ between the two groups. However, the mean age ( $36 \pm 21$  versus  $68 \pm 12$  years;  $P = .001$ ) and PDI ( $0.67 \pm 0.05$  versus  $0.58 \pm 0.06$ ;  $P = .016$ ) in the LA group were significantly younger and larger than that in the LV group. The ROC curve analysis of the PDI and age at the time of the successful ablation at a site on the LA side of the MA in patients with MA-PVCs is shown in Figure 4. Their specificity and sensitivity were 0.800 and 1.000 at a PDI of 0.62 and 1.000 and 0.750 for an age of 30 years old, respectively. The areas under the curve (AUC) were 0.908 and 0.925, respectively. Thus, a PDI  $\geq 0.62$  and age  $\leq 30$  years old may be one of the important predictors of a successful ablation of MA-PVCs from the LA side of the MA.

### 3.5 | Outcome of patients with an unsuccessful RFCA

In 2 of the 22 patients, unfortunately, the procedure was unsuccessful during this study. One patient received a repeat RFCA with an unsuccessful result. The other did not want to receive a repeat RFCA. Thus, medical therapies were continued in those two patients. The



**FIGURE 3** The earliest activation sites of the premature ventricular contractions from the MA with a successful (red, blue, green, and purple circles;  $n = 20$ ) or unsuccessful (black circle;  $n = 2$ ) radiofrequency catheter ablation in the LAO view of the MA. The red, blue, green, and purple circles indicate successful ablation sites on the ventricular side of the MA from the supramitral valve (Figure 2B), inframitral valve (Figure 2C), and LA side of the MA (Figure 2D) from the trans-interatrial septal approach and trans-coronary sinus approach (Figure 2E), respectively

factors including the %PVC, NYHA functional class, and LVEF obtained by echocardiography, in the two patients with an unsuccessful RFCA, still deteriorated further during the follow-up (Table 2).

## 4 | DISCUSSION

### 4.1 | Clinical and electrophysiological characteristics in patients with MA-PVCs

It has been reported that a PDI  $> 0.6$  indicates that the origin of the PVC exists deep within the ventricle or at an epicardial site.<sup>5</sup> The PDI in the LA group was significantly larger than that in the LV group ( $0.67 \pm 0.05$  versus  $0.58 \pm 0.06$ ;  $P = .016$ ) (Table 3). The ROC curve analysis of the PDI of a successful ablation site on the LA side of the MA in patients with MA-PVCs demonstrated that the specificity and sensitivity were 0.800 and 1.000 at a PDI of 0.62 (Figure 4A). Thus, the origins of MA-PVCs in the LA group may possibly be located deep within the MA, and it was hard to ablate it from the LV side of the MA. As shown in Figures 1E and 2D, if the origins of the MA-PVCs exist near the LA side of the MA, those MA-PVCs were able to be ablated from the LA side of the MA even though they existed deep within the MA or on the epicardial side of the LV. The mean age in the LA group was significantly younger than that in the LV group ( $36 \pm 21$  versus  $68 \pm 12$  years;  $P = .001$ ) (Table 1). There were no statistical differences in the LV wall thickness (Table 2). Unfortunately, the reason(s) why the younger patients ( $\leq 30$  years old) were successfully ablated on the LA side of the MA was not completely elucidated in this study. Thus, when ablating MA-PVCs in those patients with a younger age ( $\leq 30$  years old) (Figure 4B) and larger

PDI ( $\geq 0.62$ ) (Figure 4A), it may be necessary to consider ablating from the LA side of the MA.

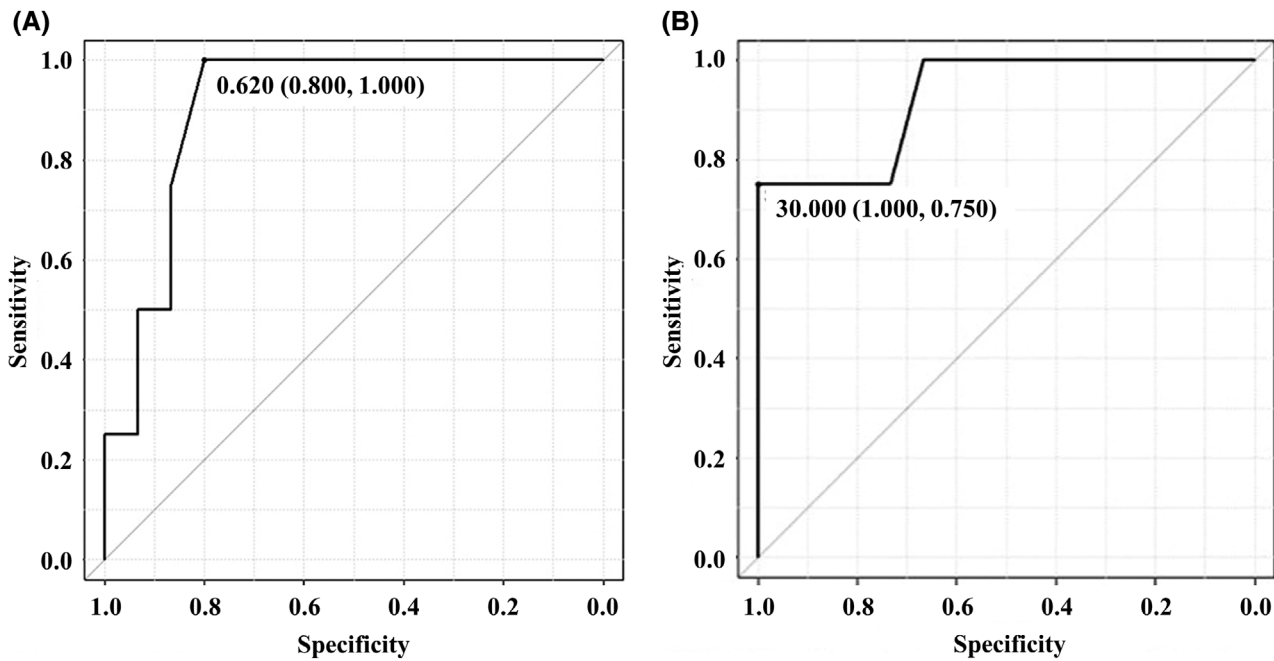
### 4.2 | Clinical benefits of RFCA of MA-PVCs

The NYHA functional status significantly improved in 20 patients in whom procedural success without any adverse effects was achieved (Table 2), and RFCA is known to be safe and effective for the treatment of arrhythmias as compared to medical therapy.<sup>1,3</sup> Thus, RFCA may be considered as the first choice of therapy in intolerable symptomatic patients with frequent MA-PVCs.

### 4.3 | RFCA of MA-PVCs

A recent report demonstrated that in 18 of 21 patients (86%), a successful ablation could be achieved in those with MA-PVCs/VT.<sup>7</sup> Procedural success in this study was achieved in 20 (91%) of the 22 patients, which was slightly higher than that of the previous report.<sup>7</sup> To achieve a high procedural successful rate, we tried and paid attention to the three points described below. (a) First, to gain strong support and contact force of the ablation catheter, the trans-interatrial septal approach was initially performed and a steerable introducer (Agilis™ NxT, Abbott) was routinely used. Actually, of those 20 patients with a successful procedure, in 19 (95%), a successful RFCA of the MA-PVCs could be achieved with a trans-interatrial septal approach on the ventricular side of the MA from the supramitral valve (59%) (Figure 2B) and inframitral valve (9%) (Figure 2C) and on the LA side of the MA (18%) (Figure 2D) (Table 3). Interestingly, in four patients (18%), a successful RFCA was achieved on the LA side of the MA using the trans-interatrial septal approach (Figure 2D). Thus, operators should try to ablate MA-PVCs on the LA side of the MA (Figure 2D), when those PVCs cannot be ablated on the ventricular side of the MA (Figures 2B and 2C). It may be hard for the ablation catheter to reach the LA using the trans-aortic approach (Figure 2E). Moreover, in the remaining two patients (9%) with an unsuccessful procedure, successful results could not be achieved even though a trans-aortic approach was additionally performed<sup>8</sup> (Figure 2F). The trans-aortic approach was not considered to be able to gain stronger support and contact force than the trans-interatrial septal approach. Further, the remaining one patient (5%) underwent a successful procedure that could be achieved from a coronary sinus approach<sup>6,8</sup> (Figure 2E). It may be a gentle treatment for patients to ablate MA-PVCs with only a right-sided (venous) approach without an aortic puncture. Thus, a right-sided approach including a trans-interatrial septal and coronary sinus approach may be considered first, when MA-PVCs need to be ablated. (b) Second, to detect more precise earliest activation sites of culprit MA-PVCs, electroanatomical mapping was performed in detail using a circular mapping catheter (Inquiry™ AFocusII™ Double Loop Catheter, St. Jude Medical) or high-density mapping catheter (Advisor™ HD Grid catheter, Abbott) on the both the LV and LA side of the MA (Table 3). Especially, the high-density mapping catheter is the only directional high-density mapping catheter that cannot only identify the local electrical signals but also more importantly can capture





**FIGURE 4** The ROC curve analysis of the peak deflection index (PDI) (A) and age (B) at the time the successful ablation was performed at a site on the left atrial (LA) side of the mitral annulus (MA) in patients with premature ventricular contractions from the MA. Their specificity and sensitivity were 0.800 and 1.000 at a PDI of 0.62 and 1.000 and 0.750 for 30 years old, respectively. The area under the curve (AUC) was 0.908 and 0.925, respectively

the direction of the wave front propagation.<sup>9</sup> On the other hand, the operators should take extreme care to avoid ensnaring the catheter in the mitral apparatus when using a circular mapping catheter near the mitral valve. Thus, the high-density mapping catheters may be much more useful and safer than the circular mapping catheters. In this study, we used high-density mapping catheters instead of circular mapping catheters since the high-density mapping catheters were commercially available in Japan. (c) Third, to obtain a stable lesion creation, an open irrigated 3.5-mm-tip ablation catheter (FlexAbility™, St. Jude Medical) was routinely used. However, unfortunately, in two patients (5%), successful results could not be achieved even though RFCA using an open irrigated ablation catheter from the various approach sites described in Figures 2B-F was performed. The recent advancements in the new technologies, including contact force catheters,<sup>10</sup> which can facilitated a more stable lesion creation, were not used in this study, and they might have improved and helped during the RFCA procedure in those unsuccessful patients.

#### 4.4 | Distribution of the earliest activation sites of the MA-PVCs

The earliest activation sites of the MA-PVCs were crowded in the direction from 0:00 to 3:00 in the left anterior oblique view of the MA (Figure 3) where the left atrial appendage was attached. Although there has been a case report supporting a possible association between ventricular arrhythmias and the LA appendage,<sup>11</sup> the detailed mechanism(s) of MA-PVCs still remains unidentified.

#### 4.5 | Treatment of patients with an unsuccessful RFCA

In 2 out of the 22 patients, the procedure was unsuccessful during this study. All of the parameters including the %PVC, NYHA functional class, and LVEF obtained by echocardiography, in the two patients with an unsuccessful RFCA, still deteriorated further during the follow-up (Table 2). Thus, intensive treatment of heart failure including the administration of renin-angiotensin system inhibitors and diuretics was started after the unsuccessful RFCA, resulting in a comparative improvement in the patient symptoms. The class I agents were discontinued because of the adverse effects of the long-term antiarrhythmic medications associated with those agents such as an increased mortality, probably due to their proarrhythmic effects, even though the occurrence of the PVCs was markedly suppressed.<sup>12</sup>

#### 4.6 | Limitations of the study

Although our study was a multicenter trial, it was limited by a retrospective design and relatively small number of patients because MA-PVCs are comparatively rare arrhythmias. The patients in this study were also limited by having a high frequency of %PVCs (mean %PVC =  $20.1 \pm 8.6\%$ ) and disabling symptoms. Thus, the effect of the RFCA of the MA-PVCs in patients with a low frequency of %PVCs and/or asymptomatic patients was unfortunately unknown in this study. Moreover, our study could not clarify the long-term clinical benefit of RFCA of MA-PVCs. Thus, whether our results can safely be

extrapolated to the inclusion of a larger number of patients, whether the use of contact force catheters, and whether a longer follow-up period in these patients is needed should be determined in further studies.

## 5 | CONCLUSIONS

RFCA could steadily improve the clinical status in patients with MA-PVCs. Initially performing a trans-interatrial septal approach and using a steerable introducer to gain a stronger support and contact force of the ablation catheter, performing detailed electroanatomical mapping using by a circular mapping catheter or high-density mapping catheter to detect more precise earliest activation sites of the target MA-PVCs, and using open irrigated ablation catheters to obtain a stable lesion creation, may be important procedures to achieve a high success rate of the RFCA of MA-PVCs. Interestingly, a successful RFCA was achieved for the MA-PVCs from not only the LV side of the MA (Figures 2B and 2C) or coronary sinus (Figure 2E) but also from the LA side of the MA (Figure 2D) whose characteristics were a younger age ( $\leq 30$  years old) and larger PDI ( $\geq 0.62$ ). Thus, it may be necessary to understand the cardiac anatomy and try to ablate those PVCs from various approach sites, especially using a trans-interatrial septal approach initially may be helpful. Because these PVCs are often drug refractory, RFCA may be considered as the first choice of therapy in those patients.

## ACKNOWLEDGMENTS

We thank Mrs. Kensuke Kawasaki, Tomomi Hatae, Ryo Okada, Tsutomu Yoshinaga, Shu Takata, Kazutaka Yamaguchi, and Takejiro Masumoto for their technical assistance with the electrophysiological study in the cardiac catheterization laboratory, and Mr. John Martin for his linguistic assistance with this paper.

## AUTHOR CONTRIBUTIONS

All doctors were in charge of the patients in this study. Drs. Y. Antoku and M. Takemoto wrote this manuscript. Drs. Y. Antoku, M. Takemoto, A. Tanaka, A. Masumoto, and T. Mito performed the radiofrequency catheter ablation of the patients in this study. Dr. T. Moto performed the data analysis.

## FUNDING SOURCES

None.

## CONFLICT OF INTEREST

The authors report no relationships that could be construed as a conflict of interest.

## ORCID

Masao Takemoto MD, PhD  <https://orcid.org/0000-0002-6047-9653>

## REFERENCES

1. Takemoto M, Yoshimura H, Ohba Y, et al. Radiofrequency catheter ablation of premature ventricular complexes from right ventricular outflow tract improves left ventricular dilation and clinical status in patients without structural heart disease. *J Am Coll Cardiol*. 2005;45:1259-1265.
2. Dukes JW, Dewland TA, Vittinghoff E, et al. Ventricular ectopy as a predictor of heart failure and death. *J Am Coll Cardiol*. 2015;66:101-109.
3. Tanaka A, Takemoto M, Masumoto A, et al. Radiofrequency catheter ablation of premature ventricular contractions from near the his-bundle. *J Arrhythm*. 2019;35:252-261.
4. Vasan RS, Larson MG, Benjamin EJ, Evans JC, Levy D. Left ventricular dilatation and the risk of congestive heart failure in people without myocardial infarction. *N Engl J Med*. 1997;336:1350-1355.
5. Hachiya H, Hirao K, Sasaki T, et al. Novel ecg predictor of difficult cases of outflow tract ventricular tachycardia: peak deflection index on an inferior lead. *Circ J*. 2010;74:256-261.
6. Mito T, Takemoto M, Kang H, et al. A case of premature ventricular complexes/ventricular tachycardia from the left ventricular outflow tract successfully ablated from the distal great cardiac vein. *J Cardiol Cases*. 2017;16:85-88.
7. Yue-Chun L, Cheng Z, Jun H, Jun-Hua C, Jing-Lin Z, Jia-Feng L. Catheter ablation of idiopathic premature ventricular contractions and ventricular tachycardias originating from the vicinity of endocardial and epicardial mitral annulus. *PLoS One*. 2013;8:e80777.
8. Lian-Pin W, Yue-Chun L, Jing-Lin Z, et al. Catheter ablation of idiopathic premature ventricular contractions and ventricular tachycardias originating from right ventricular septum. *PLoS one*. 2013;8:e67038.
9. Tan VH, Lyu MZ, Tan PC, Wong LC, Yeo C, Wong KCK. Utility of directional high-density mapping catheter (advisor(tm) hd grid) in complex scar-related atrial tachycardia. *J Arrhythm*. 2020;36:180-183.
10. Ariyaratna N, Kumar S, Thomas SP, Stevenson WG, Michaud GF. Role of contact force sensing in catheter ablation of cardiac arrhythmias: evolution or history repeating itself? *JACC Clin Electrophysiol*. 2018;4:707-723.
11. Yakubov A, Salayev O, Hamrayev R, Sultankhonov S. A case of successful ablation of ventricular tachycardia focus in the left ventricular summit through the left atrial appendage: a case report. *Eur Heart J Case Rep*. 2018;2:yy110.
12. Akhtar M, Breithardt G, Camm AJ, et al. Cast and beyond. Implications of the cardiac arrhythmia suppression trial. Task force of the working group on arrhythmias of the European society of cardiology. *Circulation*. 1990;81:1123-1127.

**How to cite this article:** Antoku Y, Takemoto M, Tanaka A, et al. Radiofrequency catheter ablation of premature ventricular contractions from the mitral annulus in patients without structural heart disease. *Pacing Clin Electrophysiol*. 2020;43:1258–1267. <https://doi.org/10.1111/pace.14063>