

This is an Open Access article licensed under the terms of the Creative Commons Attribution-NonCommercial-NoDerivs 3.0 License (www.karger.com/OA-license), applicable to the online version of the article only. Distribution for non-commercial purposes only.

Complicated Cholelithiasis: An Unusual Combination of Acute Pancreatitis and Bouveret Syndrome

Ioannis Baloyiannis^a Dimitrios Symeonidis^a
Georgios Koukoulis^a Eleni Zachari^a Spyros Potamianos^b
George Tzovaras^a

Departments of ^aGeneral Surgery and ^bGastroenterology, University Hospital of Larissa, Larissa, Greece

Key Words

Complicated cholelithiasis · Acute pancreatitis · Bouveret syndrome · Duodenal obstruction · Gallstone ileus

Abstract

Bouveret syndrome is a rare form of gallstone ileus. The purpose of the present study was to present the unusual case of a female patient with complicated cholelithiasis manifested as a combination of acute pancreatitis and concomitant Bouveret syndrome. A 61-year-old female patient was admitted to the emergency department complaining of mid-epigastric and right upper quadrant abdominal pain radiating band-like in the thoracic region of the back as well as repeated episodes of vomiting over the last 24 h. The initial correct diagnosis of pancreatitis was subsequently combined with the diagnosis of Bouveret syndrome as a computed tomography scan revealed the presence of a gallstone within the duodenum causing luminal obstruction. After failure of endoscopic gallstone removal, a surgical approach was undertaken where gallstone removal was followed by cholecystectomy and restoration of the anatomy by eliminating the fistula. The concomitant pancreatitis complicated the postoperative period and prolonged the length of hospital stay. However, the patient was discharge on the 45th postoperative day. Attempts for endoscopic removal of the impacted stone should be the initial therapeutic step. Surgery should be reserved for cases refractory to endoscopic intervention and when definite treatment is the actual challenge.

Introduction

Gallstone ileus represents a rare complication of cholelithiasis. It usually occurs in elderly female patients and symptomatic biliary disease is usually elicited from the patient's history. Multiple episodes of acute cholecystitis can finally result in the formation of a bilio-digestive fistula [1]. The variant of gallstone ileus associated with gastric outlet obstruction due to the impaction of a large gallstone in the duodenum defines Bouveret syndrome. A cholecystoduodenal fistula represents the necessary prerequisite condition. Mortality rates ranging from 12 to 30% have been reported in the literature [2]. Recently, the advancements in diagnostic imaging, the utilization of sophisticated endoscopic techniques as well as the introduction of the laparoscopic surgical approach set the stage for the optimization of this dismal prognosis.

On the other hand, the causative correlation between cholelithiasis and acute pancreatitis appears solid [3]. Epidemiological data render acute pancreatitis as a relatively common complication of cholelithiasis [3]. However, the co-existence of the two conditions, i.e. pancreatitis and gallstone-induced gastric outlet obstruction, creates a challenging combination for both diagnosis and timely treatment. The purpose of this study was to present the unusual case of a female patient with acute pancreatitis and concomitant gallstone-induced gastric outlet obstruction, i.e. Bouveret syndrome.

Case Report

A 61-year-old female patient was admitted to the emergency department complaining of mid-epigastric and right upper quadrant abdominal pain radiating band-like in the thoracic region of the back as well as repeated episodes of vomiting over the last 24 h. An episode of biliary colic had been successfully treated conservatively on an outpatient basis 7 days before. Hypertension, hyperuricemia and chronic obstructive pulmonary disease under the proper medication summarized the patient's past medical history.

Physical examination revealed right upper quadrant abdominal tenderness and a positive Murphy's sign. The patient had a body temperature of 37.8°C. Laboratory tests showed a white blood cell count of 13,500/μl and markedly elevated serum and urine amylase levels of 2,544 and 3,352 U/l, respectively. Liver function tests as well as serum bilirubin levels were within normal range. An ultrasound scan of the gallbladder revealed the presence of a large single gallstone and a common bile duct diameter of up to 9 mm.

The patient was admitted to the department's clinic with a relatively certain diagnosis of mild acute pancreatitis as no signs of organ dysfunction were noted. Due to copious bilious vomiting, a nasogastric tube was inserted while the administration of proton pump inhibitors and broad-spectrum antibiotics was simultaneously initiated. However, despite aggressive supportive management the patient's symptoms failed to ameliorate during the first 24 h of observation. In addition, the markedly high bilious nasogastric tube output (>2,000 ml/24 h) dictated further diagnostic investigation.

An emergency abdominal computed tomography (CT) scan with intravenous contrast medium was carried out and confirmed the presence of edematous pancreatitis accompanied with peri-pancreatic fluid collections. Surprisingly, a gallstone obstructing the lumen of the duodenum as well as air within the gallbladder and the biliary tree were observed (fig. 1). With a nearly certain diagnosis of Bouveret syndrome a gastroduodenoscopy for both diagnosis confirmation and therapeutic purposes was decided. Endoscopy revealed the presence of a cholecystoduodenal fistula as well as a gallstone approximately 3 cm in diameter obstructing the lumen of the third portion of the duodenum. However, endoscopic removal of the gallstone was unsuccessful.

Under these circumstances, an emergency operation was decided. Laparotomy under general anesthesia via a right subcostal Kocher incision was performed. The gallbladder was found firmly adherent to the duodenal wall and blunt dissection revealed the two openings of the fistula between the third portion of the duodenum and the gallbladder corpus. A formal cholecystectomy was then performed. A duodenotomy that elongated the opening in the duodenal wall aided the removal of the gallstone (fig. 2). The entire gastrointestinal tract was then palpated in order to exclude the possible presence of additional stones. The resultant defect in the duodenal wall was closed with one layer of interrupted 2-0 monofilament absorbable sutures reinforced with the application of a surgical adhesive material. Finally, a pyloric exclusion and a gastrojejunostomy were added. One silicon drain was placed adjacent to the duodenum.

Postoperative recovery was episodic, with aggravation of the existing chronic obstructive pulmonary disease requiring aggressive postoperative pulmonary toilet. Additional imaging workup one month after the procedure due to pain recurrence revealed the presence of a 4 cm pancreatic pseudocyst. However, conservative treatment proved adequate for the management of this complication. The patient was discharged from the hospital on the 45th postoperative day.

Discussion

Bouveret syndrome is defined as gastric outlet obstruction caused by a relatively large gallstone. Given that the 'normal' route – cystic duct, common bile duct, ampulla of Vater – is of insufficient range in order to allow the migration of large gallstones into the duodenum, the presence of a cholecystoduodenal fistula is the prerequisite that provides the gallstone access to the gastrointestinal tract. Generally, gallstone ileus occurs in approximately 15% of patients after the formation of a bilio-digestive fistula, with the duodenum involved only in 2–3% of cases [2, 4]. Rigler's triad, i.e. bowel obstruction, air in the biliary tree and an ectopic gallstone, is the hallmark for imaging diagnosis [5]. CT scan is currently considered as the imaging modality of choice in order to identify the indirect signs of Rigler's triad and to confirm the diagnosis [6]. The role of ultrasonography and magnetic resonance cholangiopancreatography still remains secondary and adjuvant to CT [6].

The nonspecific clinical symptoms triad of abdominal pain, nausea and vomiting characterizes Bouveret syndrome [1]. Patient age, comorbidities as well as the size of the gallstone determine the prognosis [1]. Early accurate diagnosis and an appropriately chosen therapeutic strategy can reduce the reported high morbidity and mortality rates [2]. Besides endoscopy that is currently considered as the first-line treatment, laparoscopic or laparoscopic-assisted procedures have been successfully employed, offering alternative treatment options [2]. However, open surgery is still the mainstream of definitive treatment, by resolving the obstruction, removing the gallbladder and finally restoring the anatomic defects, i.e. fistula.

In this study, we present an interesting case of complicated cholelithiasis in a female patient manifesting with an unusual clinical combination. A diagnosis of pancreatitis based on the presence of characteristic band-like abdominal pain as well as on the elevation of plasma levels of pancreatic enzymes was initially correctly established. Nausea and vomiting, present in up to 90% of patients with pancreatitis, further advocated the diagnosis [3]. The relatively certain diagnosis of pancreatitis in the setting of the emergency department rendered an early abdominal CT scan unnecessary. However, the unpredictable clinical course of the patient with a copious amount of vomiting as noted from the nasogastric tube output dictated a detailed

imaging evaluation. Interestingly, the CT scan performed confirmed the concurrent presence of two pathologies with relatively similar clinical presentations, i.e. acute pancreatitis and Bouveret syndrome.

Initial endoscopic treatment failed; the size of the stone and the distorted anatomy due to the presence of inflammation were the main arguments. Under these circumstances, a surgical approach was decided where gallstone removal was followed by cholecystectomy and restoration of the normal anatomy by eliminating the fistula. However, controversies do exist especially in cases of lower gallstone-induced intestinal obstructions. The need for cholecystectomy and repair of the cholecystoduodenal fistula in one surgical procedure has been questioned [7, 8]. The one-stage procedure has been associated with higher mortality and morbidity rates compared with simple enterolithotomy alone [7, 8]. However, low-risk patients should be offered the one-stage definite procedure given that the appropriate surgical expertise is available [9].

In conclusion, Bouveret syndrome is a rare form of gallstone ileus. Attempts for endoscopic removal of the impacted stone should be the initial approach. Surgery, either open or laparoscopic, should be reserved for cases refractory to the endoscopic approach and when definite treatment is the actual challenge.

Disclosure Statement

The authors have no conflicts of interest to disclose.

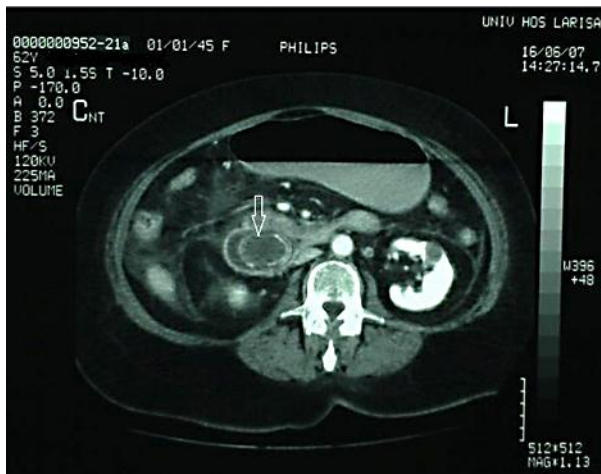


Fig. 1. CT scan with intravenous contrast medium showing edematous pancreatitis of the head and body of the organ with fluid collections and extension of the inflammatory process to the regional fat and to adjacent extrapancreatic spaces; an ectopic gallstone (arrow) and air bubbles within the gallbladder, as well as a small amount of air in the intrahepatic bile ducts especially of the left hepatic lobe, are seen.



Fig. 2. The gallstone (arrows) causing the obstruction.

References

- 1 Frattaroli FM, Reggio D, Gaudalaxara A, Illomei G, Lomanto D, Pappalardo G: Bouveret's syndrome: case report and review of the literature. *Hepatogastroenterology* 1997;44:1019–1022.
- 2 Malvaux P, Degolla R, De Saint-Hubert M, Farchakh E, Hauters P: Laparoscopic treatment of a gastric outlet obstruction caused by a gallstone (Bouveret's syndrome). *Surg Endosc* 2002;16:1108–1109.
- 3 Tonsi AF, Bacchion M, Crippa S, Malleo G, Bassi C: Acute pancreatitis at the beginning of the 21st century: the state of the art. *World J Gastroenterol* 2009;15:2945–2959.
- 4 Langhorst J, Schumacher B, Deselaers T, Neuhaus H: Successful endoscopic therapy of a gastric outlet obstruction due to gallstone with intracorporeal laser lithotripsy: a case of Bouveret's syndrome. *Gastrointest Endosc* 2000;51:209–213.

- 5 Pickhardt PJ, Bhalla S, Balfe DM: Acquired gastrointestinal fistulas: classification, etiologies, and imaging evaluation. *Radiology* 2002;224:9–23.
- 6 Brennan GB, Rosenberg RD, Arora S: Bouveret syndrome. *Radiographics* 2004;24:1171–1175.
- 7 Pavlidis TE, Atmatzidis KS, Papaziogas BT, Papaziogas TB: Management of gallstone ileus. *J Hepatobiliary Pancreat Surg* 2003;10:299–302.
- 8 Rodriguez-Sanjuan JC, Casado F, Fernandez MJ, Morales DJ, Naranjo A: Cholecystectomy and fistula closure versus enterolithotomy alone in gallstone ileus. *Br J Surg* 1997;84:634–637.
- 9 Ravikumar R, Williams JG: The operative management of gallstone ileus. *Ann R Coll Surg Engl* 2010;92:279–281.