



Functional Outcome of Lateral Extraarticular Tenodesis (LET) Procedure in Addition to Anterior Cruciate Ligament Reconstruction: A Metaanalysis*

*Resultado funcional do procedimento de tenodese extra-articular lateral (TEL) como complemento à reconstrução do ligamento cruzado anterior: Uma metanálise**

I Gusti Ngurah Wien Aryana¹ I Wayan Subawa¹ I Wayan Suryanto Dusak¹
Cokorda Gde Oka Dharmayuda¹ Hans Kristian Nugraha¹ Maria Florencia Deslivia¹

¹Department of Orthopedics and Traumatology, Faculty of Medicine Udayana University, Sanglah General Hospital, Bali, Indonesia

Address for correspondence I Gusti Ngurah Wien Aryana, MD, RSUP Sanglah, Orthopaedi dan Traumatologi, Jl. Diponegoro, Dauh Puri Klod, Kec. Denpasar Bar., Kota Denpasar, Bali, Denpasar, Bali 80113, Indonesia (e-mail: wienaryana@unud.ac.id).

Rev Bras Ortop 2022;57(1):33–40.

Abstract

Objectives The aim of the present study is to systematically review and analyze the functional outcome of lateral extraarticular tenodesis (LET) procedure in addition to anterior cruciate ligament reconstruction (ACLR) in studies with a high level of evidence.

Methods We performed a literature search for clinical studies comparing the LET method as an augmentation to ACL reconstruction with ACL reconstruction alone. The primary outcomes were the International Knee Documentation Committee (IKDC) score, the Lysholm score, and graft failures. Continuous variables were reported as means and 95% confidence intervals (CIs).

Results Six clinical studies with 1,049 patients were included in the metaanalysis. The follow-up period was, in average, 24 months (range, 6–63 months). The addition of the LET procedure to ACLR results in better functional outcome based on the IKDC score ($p < 0.05$). Graft failure was found to be lower in the ACLR plus LET group (16 of 342 patients) compared with the ACLR-only group (46 of 341 patients) ($p < 0.05$).

Conclusion There is high-level evidence that LET procedure in addition to ACLR is preferable in terms of functional outcome and graft failure.

Keywords

- ▶ anterior cruciate ligament reconstruction
- ▶ anterior cruciate ligament injuries
- ▶ joint instability
- ▶ tenodesis

* Work developed at Orthopaedics and Traumatology Department, Faculty of Medicine Udayana University, Sanglah General Hospital, Bali, Indonesia.

received
February 19, 2021
accepted
June 15, 2021
published online
January 21, 2022

DOI <https://doi.org/10.1055/s-0041-1736514>.
ISSN 0102-3616.

© 2022. Sociedade Brasileira de Ortopedia e Traumatologia. All rights reserved.

This is an open access article published by Thieme under the terms of the Creative Commons Attribution-NonDerivative-NonCommercial-License, permitting copying and reproduction so long as the original work is given appropriate credit. Contents may not be used for commercial purposes, or adapted, remixed, transformed or built upon. (<https://creativecommons.org/licenses/by-nc-nd/4.0/>)

Thieme Revinter Publicações Ltda., Rua do Matoso 170, Rio de Janeiro, RJ, CEP 20270-135, Brazil

Resumo

Objetivos O objetivo deste estudo é revisar e analisar sistematicamente o desfecho funcional do procedimento de tenodese extra-articular lateral (TEL) em complemento à reconstrução do ligamento cruzado anterior (RLCA) em de estudos com alto nível de evidências.

Métodos Realizamos a pesquisa bibliográfica para estudos clínicos comparando o método TEL como complemento à RLCA com a RLCA isolada. Os resultados principais foram a pontuação no Comitê Internacional de Documentação de Joelho (IKDC, na sigla em inglês), pontuação de Lysholm, e falhas no enxerto. Variáveis contínuas foram relatadas, como médias e intervalos de confiança (ICs) de 95%.

Palavras-chave

- ▶ reconstrução do ligamento cruzado anterior
- ▶ lesões do ligamento cruzado anterior
- ▶ instabilidade articular
- ▶ tenodese

Resultados Seis estudos clínicos com 1,049 pacientes foram incluídos na metanálise. O período de seguimento foi de, em média, 24 meses (intervalo de 6–63 meses). A adição do procedimento TEL à reconstrução do LCA resultou em melhor resultado funcional com base no escore IKDC ($p < 0,05$). A falha do enxerto foi menor no grupo RLCA mais TEL (16 dos 342 pacientes) em comparação com o grupo apenas RLCA (46 dos 341 pacientes) ($p < 0,05$).

Conclusão Há evidências de alto nível de que o procedimento TEL como complemento à RLCA é preferível em termos de resultado funcional e falha do enxerto.

Introduction

Traditional, single-bundle anterior cruciate ligament reconstruction (ACLR) techniques have been demonstrated to provide good subjective results; however, multiple studies have shown that many patients continue to have complications related to the procedure. Failure of ACLR might be caused by anterolateral rotational instability due to inadequacy of the intra-articular graft to recreate a normal knee kinematics.¹ One of the proposed solutions is to use lateral-based soft-tissue reconstructive techniques in addition to ACLR. The present metaanalysis will discuss lateral extra-articular tenodesis (LET) as an augmentation technique for ACLR.

Lateral extraarticular tenodesis is not a new concept. It was originally used to treat the ACL-deficient knee in the absence of intraarticular reconstruction techniques. The goal is to place a lateral soft-tissue restraint a distance from the central pivot of the knee, thereby improving the mechanical advantage to control rotation when treating the ACL-deficient knee.² Along with the widespread use of intra-articular reconstruction, in particular the introduction of arthroscopic techniques, LET became less known, especially since there was no proven additional advantage with its application.³

The paradigm changed when a significant focus was placed upon the anterolateral complex (ALC). On the lateral side of the knee, there are soft-tissue structures whose function is to prevent anterolateral rotatory laxity. The ALC includes the superficial and deep iliotibial band (ITB), the capsuloosseous layer of the ITB, and a thickening of the lateral capsule referred to as the anterolateral ligament (ALL).⁴ Anterolateral ligament was diversely described by many authors as either the mid-third capsular ligament, the capsuloosseous layer of the ITB, or a combination of both.⁵ Cadaveric studies have shown that in conjunction with ACLR, LET is an excellent surgical technique to control anterolateral

rotatory laxity of the knee due to injury or deficiency of the ALC.⁶ There were also previous systematic reviews and metaanalyses that reported good mid-term results even with a limited number of patients.^{7–10}

The purpose of this study is to gather evidence of the latest randomized controlled trials (RCTs) on LET regarding its functional outcome and complications as an augmentation of the ACLR procedure.

Materials and Methods

This systematic review and metaanalysis was performed in accordance with the preferred reporting items for systematic reviews and metaanalyses (PRISMA) guideline.

Search Strategy and Selection Criteria

We performed a literature search using the PubMed/MEDLINE and Google Scholar databases. There was no limitation regarding publication date. Language was limited to English. Search terms included, but were not limited to: *lateral extraarticular ligament, tenodesis, anterolateral ligament reconstruction, and anterior cruciate ligament reconstruction*.

All types of clinical trials published as full article were included in the present study. The articles were selected based on inclusion and exclusion criteria according to the population, intervention, comparison, outcome (PICO) model as depicted in ▶ **Table 1**.

Data Extraction

The articles were screened by a research team, with each article screened independently by two team members (HN and MFD). Disagreements between reviewers regarding whether to include or exclude a study were resolved by consensus and, if necessary, consultation with a third reviewer.

Table 1 Inclusion and exclusion criteria based on the PICO model

	Inclusion criteria	Exclusion criteria
Population	Patients aged ≥ 18 years or older with primary ACL rupture and planned to undergo ACL reconstruction with arthroscopy.	<ul style="list-style-type: none"> • Animal studies. • Revision cases of ACL reconstruction. • Concomitant PCL or meniscus reconstruction. • Underlying congenital condition or neoplasm.
Intervention	ACL reconstruction with lateral extraarticular tenodesis.	<ul style="list-style-type: none"> • ACLR with (ALL) reconstruction. • Pharmacologic treatment. • Nutrition treatment. • Physical therapy or rehabilitation which stands alone.
Control	ACL reconstruction alone.	
Outcome	<p>Primary outcome measures Clinical outcomes including the IKDC score, VAS for pain, and SF-36 for quality of life are the primary outcomes. Mean difference will be reported with 95% confidence intervals.</p> <p>Secondary outcome measures Additional outcomes of interest include complications. Dichotomous outcomes will be measured using risk ratios with 95% confidence intervals.</p>	<ul style="list-style-type: none"> • Study is ongoing, and no results have been reported • Outcome measures not reported in completion

Abbreviations: ACL, anterior cruciate ligament; ACLR, anterior cruciate ligament reconstruction; ALL, anterolateral ligament; IKDC, International Knee Documentation Committee; PCL, posterior cruciate ligament; VAS, visual analogue scale.

Data were collected from each article by two independent reviewers, with disagreements resolved through consensus and, if required, consultation with a third reviewer. Data were recorded in a form developed a priori.

Abstracted variables included patient age, gender, sample size, mean follow-up, ALL augmentation technique, ALL augmentation graft, ACLR technique, ACLR graft, IKDC score, Lysholm score, and complications (e.g., graft failure).

Quality Assessment

The included clinical trials were assessed in terms of quality by two independent reviewers based on the 13 items of the 2015 Updated Method Guideline for Systematic Reviews in the Cochrane Back and Neck Group.¹¹ The following domains were assessed for each included study: randomization (selection bias), allocation concealment (selection bias), blinding of participants and personnel (performance bias), blinding of outcome assessment (detection bias), drop-out rate (attrition bias), all participants analyzed in proper group (attrition bias), selective reporting bias (reporting bias), similar baseline regarding the most important prognostic indicators (selection bias), cointerventions (performance bias), acceptable compliance in all groups (performance bias), other sources of bias (e.g., industry sponsorship). Disagreements during quality assessment were resolved through discussion and consensus and, if necessary, consultation with a third reviewer.

Data Synthesis

The mean differences in the IKDC score, Lysholm score, and graft failures were the primary outcomes investigated.

Continuous variables were reported as means and 95% confidence intervals (CIs). Dichotomous outcomes will be measured using risk ratios with 95% confidence intervals. Heterogeneity was determined by estimating the proportion of between-study inconsistencies due to actual differences, rather than differences due to random error or chance, using the I statistic, with values of 25%, 50%, and 75% indicating low, moderate, and high degrees of heterogeneity, respectively. The statistical analysis was performed using RevMan version 5.4 (Nordic Cochrane Centre, Copenhagen, Denmark). A p -value < 0.05 was considered significant.

Results

Literature Search and Study Characteristics

The preliminary electronic search of all databases resulted in 1,364 records, which were screened for duplicates, publication period, study methodology (only RCTs were included), and language. The remaining articles were subsequently studied by two independent investigators based on the full text extracted using a form developed a priori. This selection text yielded six final articles to be included in the metaanalysis, with the flow of selection process depicted in ► **Fig. 1**. All articles had high quality of evidence except one which had moderate quality¹² (► **Table 2**).

Baseline Characteristics

A total of 1,049 patients were investigated in this study. The complete list of baseline characteristics can be seen in ► **Table 3**. From six studies, four used the Lemaire¹³ technique for the LET, while two studies used the techniques described by MacIntosh¹⁴ and Christel, respectively.¹⁵ The ITB was utilized for the tenodesis in four studies, and the

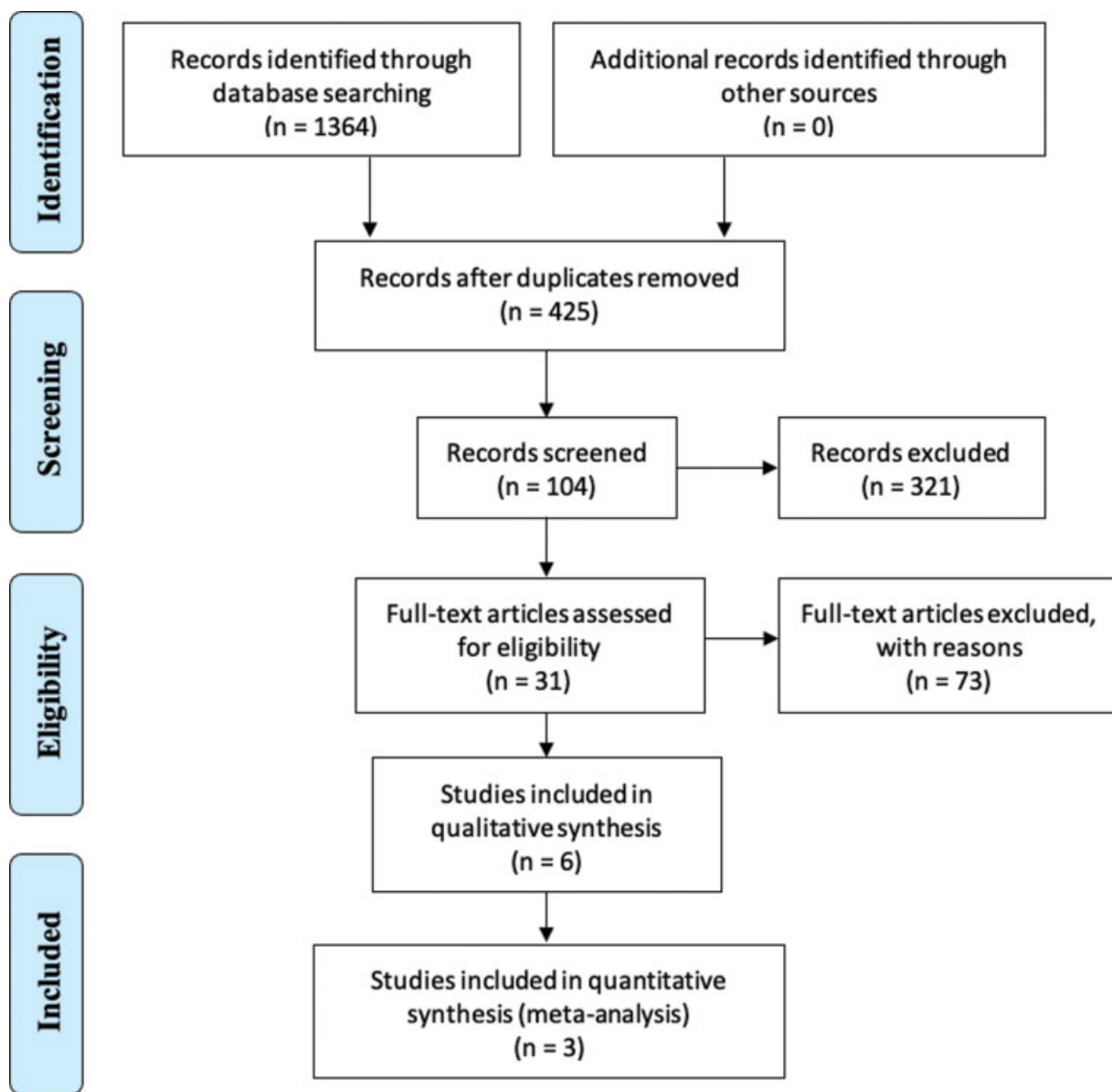


Fig. 1 Flow chart showing article selection.

gracilis graft was used in two studies. The ACL reconstruction technique was varied in all studies, with three studies using ACL graft from the hamstring tendon (gracilis and semitendinosus), and three using bone patellar tendon bone graft. The follow-up period was similar in most studies, that is, in average 24 months (range, 6–63 months), while 2 studies had long-term follow-up, that is, a follow-up period longer than 10 years.

Functional Outcome

There are a wide variety of clinical parameters that can be used to assess the outcome of procedures in the knee. The complete list of functional outcomes of LET in ACLR can be seen in ► **Table 4**. The most widely used is the IKDC score, with 3 studies using this parameter^{1,16,17} favoring ACLR along with LET procedure and 1 study resulting in insignificant difference between the 2 procedures.¹⁸ The addition of the LET procedure to ACLR resulted in significant difference

of functional outcome based on the IKDC score ($p < 0.05$). The mean difference was -0.71 (95% CI, -0.84 – -0.58). (► **Figs. 2** and **3**) Two studies confirmed better Lysholm score with addition of the LET procedure.^{12,19}

Complication

Of all the complications reported in each study, the most often reported is graft failure.^{16,19} Graft failure was found to be lower in the ACLR plus LET group (16 of 342 patients) compared with the ACLR-only group (46 of 341 patients) ($p < 0.05$). The risk ratio was 2.63 (95% CI, 1.53–4.52).

Discussion

This metaanalysis investigated the recent high-quality evidence of LET procedure in addition to ACLR. Despite the current enormous interest in this procedure, there is not enough quantitative evidence about how the addition of LET

Table 2 Quality assessment of randomized control trial methodology¹¹

No	Author (year)	Adequate randomization ^b	Concealed allocation	Patient blinded	Care provider blinded	Assessor blinded	Drop-out rate acceptable	Analyzed according to group	Free of selective outcome reporting	Similar at baseline	Cointerventions avoided	Compliance acceptable	Timing of outcome similar	No other sources of potential bias	Quality assessment
1	Dejour et al. (2013)	No	Unsure	No	No	No	Yes	Yes	Yes	Yes	Yes	No	Yes	Yes	Moderate
2	Trichine et al. (2014)	Yes	Unsure	Yes	No	Yes	Yes	Yes	Yes	Yes	Yes	Yes	Yes	Yes	High
3	Ferretti et al. (2016)	Yes	Unsure	No	No	No	Yes	Yes	Yes	Yes	Yes	Yes	Yes	Yes	High
4	Getgood et al. (2019)	Yes	Yes	No	No	No	No	Yes	Yes	Unsure	Yes	Yes	Yes	Yes	High
5	Castoldi et al. (2020)	Yes	Unsure	No	No	No	No	Yes	Yes	Unsure	Unsure	Yes	Yes	Yes	High
6	Getgood et al. (2020)	Yes	Unsure	No	No	No	No	Yes	Yes	Yes	Yes	Yes	Yes	Yes	High

Table 3 Baseline characteristics of final articles included in the systematic review

Study (year)	ALL augmentation technique	ALL augmentation graft	ACLR technique	ACLR graft	Age		Gender		Sample size		Mean follow-up	
					ACLR alone	ACLR + LET	ACLR alone	ACLR + LET	ACLR alone	ACLR + LET		
Dejour et al. (2013)	Modified Lemaire	Gracilis	Single Bundle	Bone patellar tendon bone graft	27.5 years (range: 14-42 years)	21.4 years (range: 14-34 years)	Male: 17 (68%)	Male: 20 (80%)	25	25	25.4 (range 18-30 months)	ACLR + LET 25.6 (range 14-33 months)
Trichine et al. (2014)	Kenneth Jones plasty	Iliotibial band	Single-incision arthroscopic technique (Kenneth Jones)	Patellar tendon	27.7 ± 4.75 years	28.6 ± 4.69 years	Comparable statistically		60	60	24.5 months (range 6-63 months)	23.4 months (range 6-45 months)
Ferretti et al. (2016)	MacIntosh modified by Cocker-Arnold	Iliotibial band	Single Bundle	Semitendinosus and gracilis	27.3 (range: 18-50 years)	25.7 (range: 18-46 years)	Male 51 (71%)	Male 56 (82%)	72	68	10 years 5 months (range 121-128 months)	24 months
Getgood et al. (2019)	Modified Lemaire	Iliotibial band	Triple bundle	Semitendinosus and gracilis	18.7 ± 3.2 years	19.0 ± 3.1 years	Male 79 (45.9%)	Male 75 (44.4%)	180	176	24 months	24 months
Castoldi et al. (2020)	Lemaire extra-articular tenodesis	Gracilis	NA	Bone patellar tendon bone graft	26 years (range: 15-40 years)	15-40 years	Male 43 (70%)	Male 47 (78%)	61	60	19.4 years (range, 19-20.2 years)	24 months
Getgood et al. (2020)	Modified Lemaire	Iliotibial band	Various	Semitendinosus and/or gracilis.	18.9 years (range: 14-25 years)	14-25 years	Male 151 (48%)	Male 151 (49%)	312	306	24 months	24 months

Abbreviations: ACLR, anterior cruciate ligament reconstruction; ALL, anterolateral ligament; LET, lateral extraarticular tenodesis.

Table 4 Functional outcome of lateral extraarticular tenodesis in anterior cruciate ligament reconstruction from recent randomized control trials

Study (year)	IKDC		Lysholm		Graft failure (%)	
	ACL alone	ACL + LET	ACL alone	ACL + LET	ACL alone	ACL + LET
Dejour et al. (2013)	90.1	86	NA	NA	NA	NA
Trichineet al. (2014)	92.1	88.2	NA	NA	NA	NA
Ferretti et al. (2016)	93.77 (SD 6.63)	96.19 (SD 3.3)	95.46 (SD 5.68)	96.24 (SD 3.5)	NA	NA
Getgood et al. (2019)	NA	NA	NA	NA	11.67%	13.07%
Castoldi et al. (2020)	81.1 (range, 42.5–100)	82.4 (range, 55.2–100)	86.6 (42–100)	90.3 (67–100)	47.54%	21.67%

Abbreviations: ACLR, anterior cruciate ligament reconstruction; IKDC, International Knee Documentation Committee; LET, lateral extraarticular tenodesis; SD, standard deviation.

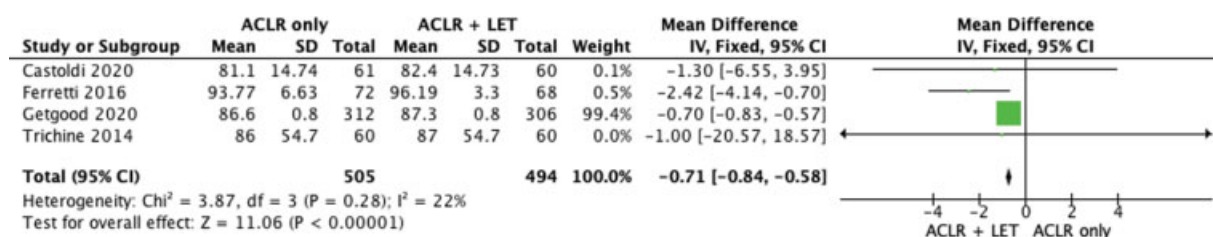


Fig. 2 Forrest plot showing that addition of lateral extraarticular tenodesis procedure to anterior cruciate ligament reconstruction results in significant difference of functional outcome based on the International Knee Documentation Committee score.

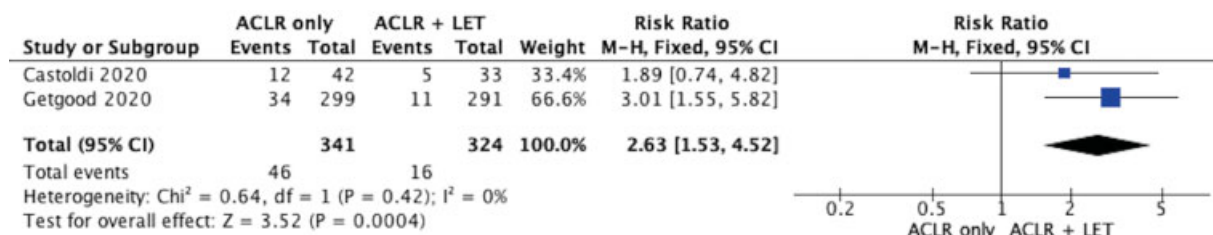


Fig. 3 Forrest plot showing lower graft failure in anterior cruciate ligament reconstruction plus lateral extraarticular tenodesis group.

might affect the functional outcome. Therefore, this procedure is not common, and it is mainly indicated for revision and grade III pivot shift.²⁰ Previous systematic reviews reported good mid-term result even with a limited number of patients.⁷⁻¹⁰ The current study is the first to present quantitative analysis of recent studies which concluded that LET procedure in addition to ACLR yielded a satisfactory functional outcome.

Failure to reconstruct anterolateral structure, especially ALL, was considered to be one of the factors producing unsatisfactory result in anatomical ACLR.²¹ Anterolateral ligament was diversely described by many authors as a component of ALC, which was thought to be either the mid-third capsular ligament, the capsuloosseous layer of the ITB, or a combination of both. It has a significant role in rotatory instability, along with the ITB.⁵ The quantitative analysis of previous clinical trials showed that graft failure is lower in combined ACLR and LET procedure. The addi-

tional procedure is beneficial in reducing complication probably due to its effect in reducing residual rotational laxity.

The anterolateral augmentation procedure improves rotatory instability significantly and eliminates pivot shift in high-risk patients.^{22,23} It can be performed with two techniques: LET procedure and modern ALL reconstruction. The main difference between the two methods is that ALL reconstruction allows more anatomical reconstruction than LET.²⁴ Another difference is that in the LET procedure, the proximal fixation point is near the femoral epicondyle, and the distal fixation point is around the Gerdy tubercle, while in ALL, it is integrated with the fibular collateral ligament (FCL).⁴

A previous metaanalysis found that even when patients reported generally satisfactory outcome measures, combined LET procedure and ACL reconstruction provided worse anterior stability.⁸ On the other hand, one metaanalysis

provided good mid-term follow-up results with low rates of residual rotatory laxity, re-ruptures, or complications. In terms of functional outcome, there was a trend that the IKDC subjective outcome was more similar between the two groups in primary reconstruction procedure than the one in revision procedure.⁷ However, the studies included in both metaanalysis were all retrospective studies dating back to 1986⁸ and 2006.⁷

The present study focused on recent literature, with the latest clinical trial dating back to 2013¹² since the technique of arthroscopy and surgeon's familiarity with the technique has progressed well in recent years. Even though there are several clinical trials comparing ACLR procedure alone with ACLR combined with LET, these studies found no significant difference between the two groups in terms of pain and functional outcome, using tools such as the limb symmetry index (LSI).²⁵⁻²⁷ These studies used different techniques and graft, making it difficult to derive a conclusion.

In recent years, more uniform techniques were utilized in LET procedure in addition to ACLR with a more standardized method to assess the functional outcome, thus making the methodology more rigorous. Most studies included in our analysis used the IKDC scoring system as the functional outcome. Even though Getgood et al.¹⁶ reported a greater amount of pain in the first 3 months after surgery and a delay to quadriceps strength recovery and reduction in the lower extremity functional scale (LEFS), these differences were small and transient.

Another interesting topic is how LET procedure provides additional benefit, especially in delayed ACLR procedures (after 12 months of injury).¹⁰ The additional benefit was shown in terms of pivot shift test, which was not described regarding its grading and might influence the statistical analysis. To provide better recommendation for delayed ACLR procedures, future studies should consider utilizing functional outcome, that is, using the IKDC score as outcome measurement. It is patient-oriented and should be more considered in future studies.

There are several limitations of the present study that should be mentioned. First, the data available in the studies are limited. For example, the mean and standard deviation was not always provided in the studies; thus, a quantitative analysis could not be performed. Secondly, only four out of six studies were RCTs, while two of them were retrospective studies.^{12,17} Therefore some data presented in the systematic review is not of high quality. Third, all studies included were published in English, which might lead to publication bias. Fourth, we only investigated functional outcome and complications since those two were the most associated factors with the development of the ACLR technique. Finally, the variability in the follow-up period might have also influenced our data analysis.

Conclusion

There is high-level evidence that LET procedure in addition to ACLR is preferable to ACLR alone in terms of functional outcome and rate of graft failure.

Financial Disclosure

There was no financial support.

Conflict of Interests

The authors have no conflict of interests to declare.

References

- 1 Getgood AMJ, Bryant DM, Litchfield R, et al. STABILITY Study Group. Lateral Extra-articular Tenodesis Reduces Failure of Hamstring Tendon Autograft Anterior Cruciate Ligament Reconstruction: 2-Year Outcomes From the STABILITY Study Randomized Clinical Trial. *Am J Sports Med* 2020;48(02):285–297
- 2 Schindler OS. Surgery for anterior cruciate ligament deficiency: a historical perspective. *Knee Surg Sports Traumatol Arthrosc* 2012;20(01):5–47
- 3 Draganich LF, Reider B, Ling M, Samuelson M. An in vitro study of an intraarticular and extraarticular reconstruction in the anterior cruciate ligament deficient knee. *Am J Sports Med* 1990;18(03):262–266
- 4 Caterine S, Litchfield R, Johnson M, Chronik B, Getgood A. A cadaveric study of the anterolateral ligament: re-introducing the lateral capsular ligament. *Knee Surg Sports Traumatol Arthrosc* 2015;23(11):3186–3195
- 5 Musahl V, Herbst E, Burnham JM, Fu FH. The Anterolateral Complex and Anterolateral Ligament of the Knee. *J Am Acad Orthop Surg* 2018;26(08):261–267
- 6 Patel RM, Brophy RH. Anterolateral Ligament of the Knee: Anatomy, Function, Imaging, and Treatment. *Am J Sports Med* 2018;46(01):217–223
- 7 Grassi A, Zicaro JP, Costa-Paz M, et al. ESSKA Arthroscopy Committee. Good mid-term outcomes and low rates of residual rotatory laxity, complications and failures after revision anterior cruciate ligament reconstruction (ACL) and lateral extra-articular tenodesis (LET). *Knee Surg Sports Traumatol Arthrosc* 2020;28(02):418–431
- 8 Ra HJ, Kim JH, Lee DH. Comparative clinical outcomes of anterolateral ligament reconstruction versus lateral extra-articular tenodesis in combination with anterior cruciate ligament reconstruction: systematic review and meta-analysis. *Arch Orthop Trauma Surg* 2020;140(07):923–931
- 9 Hewison CE, Tran MN, Kaniki N, Remtulla A, Bryant D, Getgood AM. Lateral Extra-articular Tenodesis Reduces Rotational Laxity When Combined With Anterior Cruciate Ligament Reconstruction: A Systematic Review of the Literature. *Arthroscopy* 2015;31(10):2022–2034
- 10 Devitt BM, Bell SW, Ardern CL, et al. The Role of Lateral Extra-articular Tenodesis in Primary Anterior Cruciate Ligament Reconstruction: A Systematic Review With Meta-analysis and Best-Evidence Synthesis. *Orthop J Sports Med* 2017;5(10):2325967117731767
- 11 Furlan AD, Malmivaara A, Chou R, et al. Editorial Board of the Cochrane Back, Neck Group. 2015 updated method guideline for systematic reviews in the Cochrane Back and Neck Group. *Spine* 2015;40(21):1660–1673
- 12 Dejour D, Vanconcelos W, Bonin N, Saggin PRF. Comparative study between mono-bundle bone-patellar tendon-bone, double-bundle hamstring and mono-bundle bone-patellar tendon-bone combined with a modified Lemaire extra-articular procedure in anterior cruciate ligament reconstruction. *Int Orthop* 2013;37(02):193–199
- 13 Lemaire M. Rupture ancienne du ligament croisé antérieur du genou. *J Chir (Paris)* 1967;93:311–320
- 14 Macintosh D, Darby T. Lateral Substitution Reconstruction. *J Bone Joint Surg* 1976;58:142
- 15 Christel P, Djian P. Plastie extra-articulaire antéro-latérale du genou utilisant une ténodèse courte au fascia lata. [Anterior-

- lateral extra-articular tenodesis of the knee using a short strip of fascia lata]. *Rev Chir Orthop Repar Appar Mot* 2002;88(05): 508–513
- 16 Getgood A, Hewison C, Bryant D, et al. Stability Study Group. No Difference in Functional Outcomes When Lateral Extra-Articular Tenodesis Is Added to Anterior Cruciate Ligament Reconstruction in Young Active Patients: The Stability Study. *Arthroscopy* 2020; 36(06):1690–1701
 - 17 Ferretti A, Monaco E, Ponzo A, et al. Combined Intra-articular and Extra-articular Reconstruction in Anterior Cruciate Ligament-Deficient Knee: 25 Years Later. *Arthroscopy* 2016;32(10): 2039–2047
 - 18 Trichine F, Alsaati M, Chouteau J, Moyen B, Bouzitouna M, Maza R. Patellar tendon autograft reconstruction of the anterior cruciate ligament with and without lateral plasty in advanced-stage chronic laxity. A clinical, prospective, randomized, single-blind study using passive dynamic X-rays. *Knee* 2014;21(01):58–65
 - 19 Castoldi M, Magnussen RA, Gunst S, et al. A Randomized Controlled Trial of Bone-Patellar Tendon-Bone Anterior Cruciate Ligament Reconstruction With and Without Lateral Extra-articular Tenodesis: 19-Year Clinical and Radiological Follow-up. *Am J Sports Med* 2020;48(07):1665–1672
 - 20 Tramer JS, Fidai MS, Kadri O, et al. Anterolateral Ligament Reconstruction Practice Patterns Across the United States. *Orthop J Sports Med* 2018;6(12):2325967118811063
 - 21 Ferretti A, Conteduca F, Monaco E, De Carli A, D'Arrigo C. Revision anterior cruciate ligament reconstruction with doubled semitendinosus and gracilis tendons and lateral extra-articular reconstruction. *J Bone Joint Surg Am* 2006;88(11):2373–2379
 - 22 Spencer L, Burkhart TA, Tran MN, et al. Biomechanical analysis of simulated clinical testing and reconstruction of the anterolateral ligament of the knee. *Am J Sports Med* 2015;43(09):2189–2197
 - 23 Ueki H, Katagiri H, Otabe K, et al. Contribution of Additional Anterolateral Structure Augmentation to Controlling Pivot Shift in Anterior Cruciate Ligament Reconstruction. *Am J Sports Med* 2019;47(09):2093–2101
 - 24 Slette EL, Mikula JD, Schon JM, et al. Biomechanical Results of Lateral Extra-articular Tenodesis Procedures of the Knee: A Systematic Review. *Arthroscopy* 2016;32(12):2592–2611
 - 25 Noyes FR, Barber SD. The effect of an extra-articular procedure on allograft reconstructions for chronic ruptures of the anterior cruciate ligament. *J Bone Joint Surg Am* 1991;73(06):882–892
 - 26 Roth JH, Kennedy JC, Lockstadt H, McCallum CL, Cunnig LA. Intra-articular reconstruction of the anterior cruciate ligament with and without extra-articular supplementation by transfer of the biceps femoris tendon. *J Bone Joint Surg Am* 1987;69(02):275–278
 - 27 Oni OO, Crowder E. A comparison of isokinetics and muscle strength ratios following intra-articular and extra-articular reconstructions of the anterior cruciate ligament. *Injury* 1996; 27(03):195–197