

Available online at [www.sciencedirect.com](http://www.sciencedirect.com)

ScienceDirect

journal homepage: <http://Elsevier.com/locate/radcr>

## Cardiac

# Pulmonary venous varix associated with mitral regurgitation mimicking a mediastinal mass: A case report and review of the literature

Dana AlNuaimi MD<sup>a,\*</sup>, Reem AlKetbi MD<sup>a</sup>, Usama AlBastaki MD<sup>a</sup>,  
Claude Pierre-Jerome MD, PhD<sup>b</sup>, Ebrahim Ahmad Ebrahim MD<sup>a</sup>

<sup>a</sup> Rashid Hospital, Dubai Health Authority, Oud Metha Street, PO Box 4545, Dubai, United Arab Emirates

<sup>b</sup> Ackershus University Hospital, Sykehusveien, 75, 1470, Lorenskog, Norway

### ARTICLE INFO

#### Article history:

Received 12 December 2017

Accepted 26 December 2017

Available online 8 February 2018

#### Keywords:

Pulmonary venous varix

Mitral valve insufficiency

Cerebral infarction

Splenic infarction

Computed tomography

### ABSTRACT

Pulmonary vein varix is an unusual cause of a mediastinal mass on a chest radiograph. It may be found as an isolated malformation or as a sequela of pulmonary venous hypertension. We encountered a case presenting with left hemiparesis and a past medical history of rheumatic heart disease. The chest radiograph revealed a well-defined mediastinal mass that turned out to be a hugely dilated pulmonary vein on contrast enhanced computed tomography of the chest. The computed tomography of the brain and upper abdomen revealed bilateral cerebral infarction and splenic infarction. In the literature, one-third of the reported cases of pulmonary vein varix are acquired secondary to mitral valve disease.

© 2018 the Authors. Published by Elsevier Inc. under copyright license from the University of Washington. This is an open access article under the CC BY-NC-ND license (<http://creativecommons.org/licenses/by-nc-nd/4.0/>).

## Introduction

Pulmonary venous varices may be congenital or acquired [1]. A major cause of acquired cases is mitral valve insufficiency leading to pulmonary venous hypertension, as in our case. On plain radiograph, it may mimic a mediastinal or perihilar mass. Multidetector computed tomography (CT) scan is crucial in determining its exact nature as it is noninvasive and provides important information on the accurate size and location [2]. Nevertheless, conventional angiography is still considered the

gold standard for definitive diagnosis [1,3]. Management of the causative factor has a positive influence on the reduction of the varix size, thereby providing relief [3,4].

## Case report

A 38-year-old man presented to the emergency department with slurring of speech, facial drooping, and weakness of his left arm. On clinical anamnesis, he stated having

Competing Interests: The authors have declared that no competing interests exist.

\* Corresponding author.

E-mail address: [dr.danas@hotmail.com](mailto:dr.danas@hotmail.com) (D. AlNuaimi).

<https://doi.org/10.1016/j.radcr.2017.12.009>

1930-0433/© 2018 the Authors. Published by Elsevier Inc. under copyright license from the University of Washington. This is an open access article under the CC BY-NC-ND license (<http://creativecommons.org/licenses/by-nc-nd/4.0/>).

persistent headache and fever 3 days prior. He also confirmed an existing rheumatic heart disease since childhood; but he was not followed up by a cardiologist up to the time of admission.

On physical examination, the patient was vitally stable. A pansystolic murmur was heard on auscultation over the mitral region radiating to axilla with a displaced apex beat to the sixth left intercostal space. He had left hemiparesis as well as left facial weakness. The electrocardiogram (ECG) showed a bigeminal rhythm.

An urgent brain CT scan without intravenous contrast displayed multiple scattered supra- and infra-tentorial cerebral infarctions with an element of small hemorrhage in the left frontal lobe. Hypodense edema and effacement of the cortical sulci were seen in the right frontoparietal region (Fig. 1). Following contrast administration, no parenchymal enhancement was detected.

The chest radiograph showed cardiomegaly with a well-defined large right paramediastinal mass, which was not silhouetting the right cardiac border (Fig. 2). For further evaluation, a multidetector CT chest examination was performed with intravenous contrast. The CT images revealed a massively dilated right lower pulmonary vein at the confluence with the left atrium, along with left atrial and left ventricular

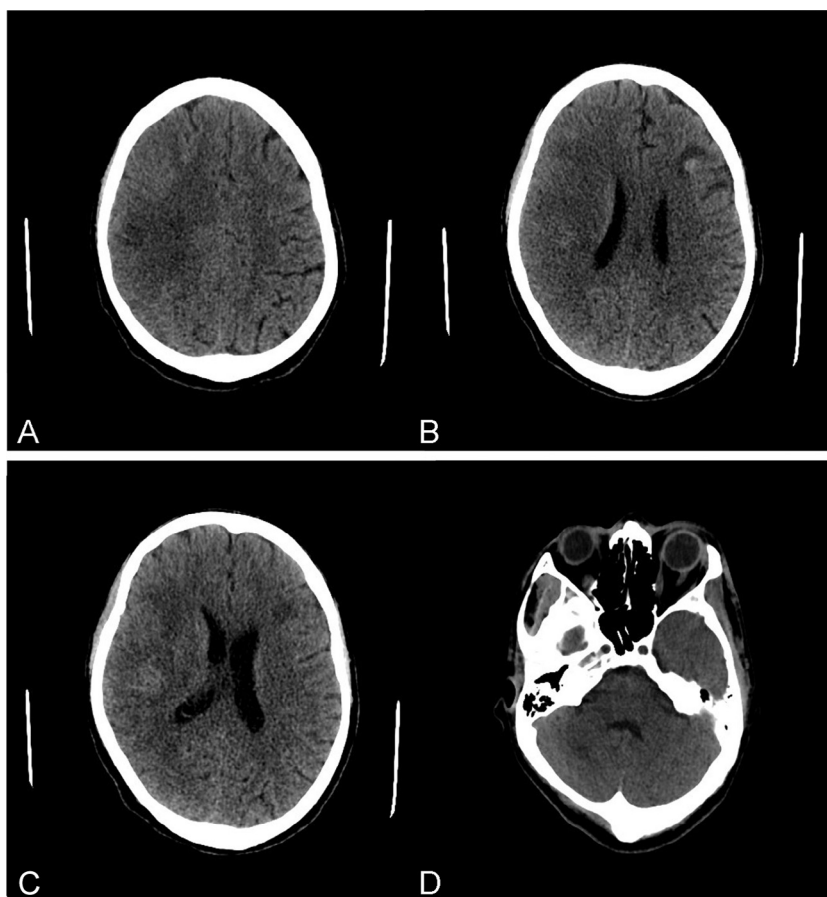
dilatation. The rest of the pulmonary veins were mildly dilated as well. Additional CT images of the upper abdomen showed low attenuation areas in the spleen consistent with splenic infarction (Fig. 3).

Both transthoracic and transesophageal echocardiographic imaging demonstrated severe mitral regurgitation with small vegetations on the anteromedial leaflet. Marked dilatation of the left atrium and left ventricle was also detected.

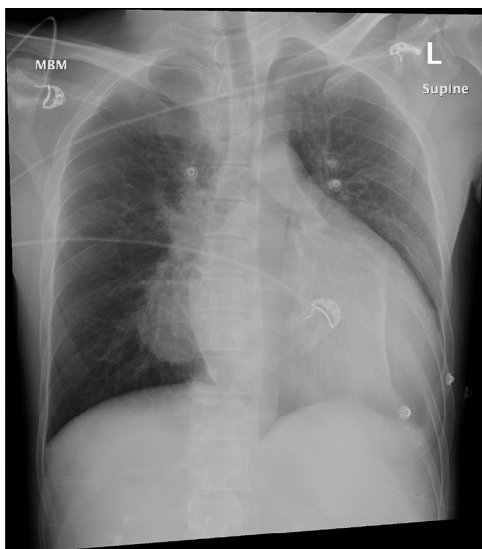
The blood cultures demonstrated the presence of *Streptococcus gordonii*. The final diagnosis was set as infective endocarditis with thromboembolic stroke on a background of rheumatic heart disease with severe mitral valve regurgitation inducing pulmonary vein varix (PVV) and cardiomegaly. The patient improved after a course of antibiotics and multiple sessions of physiotherapy. Further surgical management with mitral valve replacement was considered.

## Discussion

PVV is defined as a focal pathologic aneurysmal dilatation of the pulmonary vein [1]. It can be congenital or acquired. It may be seen in asymptomatic patients [5,6]. It has no gender



**Fig. 1** – Plain brain CT axial slices: (A) Presence of ill-defined hypodensities in the gray-white matter junction in the right frontoparietal area. (B and C) Note the edema and effacement of the cortical sulci. There is a small ill-defined hypodense area seen in left frontal lobe at the gray-white matter junction containing small hemorrhagic component. (D) Display of a right cerebellar ill-defined hypodensity.



**Fig. 2 – Mobile chest radiograph, AP view: Presence of a well-defined homogenous right paramediastinal mass not silhouetting the right cardiac border, confirming its location posterior to the heart. The mass has no internal calcification or air-fluid level. No adjacent bone erosion is seen. There is cardiomegaly with blunting of left costophrenic angle. AP, anteroposterior.**

predominance and can occur at any age [1]. Its incidence is unknown and has been reported infrequently [7].

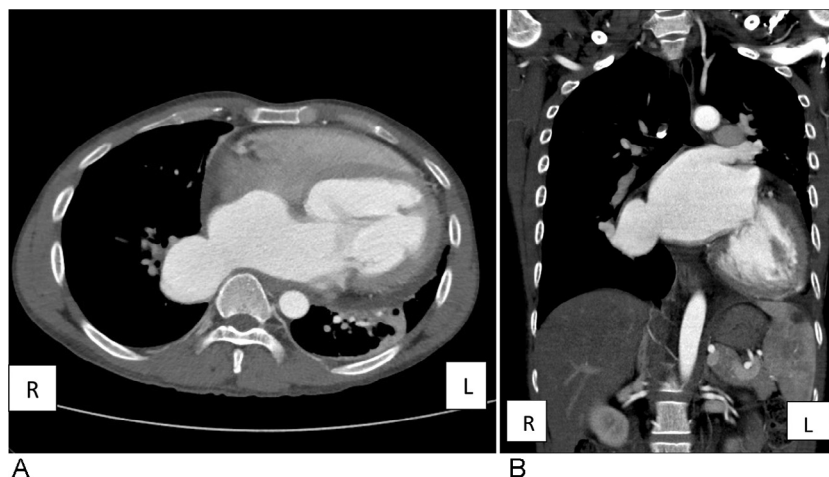
PVV is classified into 3 morphologic types: sacular (localized and ovular form), tortuous (extensive), and confluent (localized at the confluence of the pulmonary veins) [8]. The sacular type is seen most commonly in the left upper lobe, whereas the tortuous and confluent types are most commonly seen in the right lower lobe [9]. The sacular type is localized, and is seen most commonly in congenital cases. It is proposed that congenital pulmonary varicosities may be due to

alterations in the development of the primitive splanchnic plexus [10]. The patients are thought to have congenital weakness of the vein walls [4,11]. However, histologic examination of the vein suggested no intrinsic wall defects [5]. Other congenital cardiovascular malformations can be found in association with PVV, such as a patent ductus, double outlet ventricles, coarctation of the aorta, pulmonary vein stenosis, and ventricular septal defects. They are also associated with Klippel-Trenaunay-Weber syndrome [10].

The confluent type of PVV is the most common type. It usually occurs at the confluences of the pulmonary veins adjacent to the left atrium [8] and is commonly associated with mitral valve disease secondary to pulmonary venous hypertension [8,9,12]. This may explain the rapid development of a varix with mitral valve prosthetic malfunction [12]. It has been noticed that after mitral valve replacement surgery, there is significant interval regression of the size of pulmonary varicosities [1,8]. However, around one-third of the reported cases show no relation with pulmonary venous pressure [3]. On the other hand, an increase in size seems to be directly related to an increased atrial pressure only [3,8]. No correlation has been established between the severity of the pulmonary venous hypertension and the development of a pulmonary venous varix [12].

In the literature, the sacular type has not been reported in association with mitral valve disease [8,9]. Other factors may predispose to the formation of PVV. They include post-inflammatory changes [6,9] and end-stage liver disease [4,13]. Some studies [3,8] show that PVV occurs most commonly in the right lower lobe (60%), followed by the left upper lobe (12%). The theory behind this is that the normal anatomic mitral valve plane is located supero-posteriorly and to the right; thus, the flow jet across an incompetent mitral valve is directed toward the right side [9,12,14]. The size of the PVV on fluoroscopy may fluctuate and correlate with the intrathoracic pressure [9]. It increases with Müller maneuver and decreases with Valsalva maneuver [12].

On chest radiography, the PVV may mimic a mediastinal or perihilar mass, such as in our case. Other differentials of



**Fig. 3 – (A) CT chest with contrast in axial and coronal planes show a marked dilatation of the left atrium, left ventricle, and the right lower pulmonary vein in a confluent manner. (B) The same findings in addition to a cortical wedge-shaped splenic hypodensity consistent with splenic infarction. CT, computed tomography.**

mediastinal masses include mediastinal lymphadenopathy either infectious or lymphoproliferative, bronchogenic carcinoma, foregut duplication cysts, cor triatriatum, and left atrial aneurysm or diverticuli [15,16]. Thus, it is important to emphasize the benign nature of varices before any procedure or biopsy [5,11]. They may also appear as a rounded parenchymal lesion resembling a solitary pulmonary nodule if an end-on image is taken [15,17].

Echocardiography can detect varices close to the heart [11]. Transthoracic and transesophageal echocardiography also have the advantage of detecting mitral valve disease and the anatomic characteristics of the varix without the effects of surrounding body fat or lung tissue. Also, color Doppler aids in visualization of the jet flow across the valves [16]. The diagnosis can be made by multidetector CT imaging with 3D and maximum intensity projection reconstruction [2], which can also provide good visualization of the whole pulmonary vascular tree [5].

Magnetic resonance imaging plays a new emerging role and can differentiate whether the lesion is an atrial aneurysm or a PVV, as a varix will not be covered with pericardial fat [16]. Conventional angiography is still considered the gold standard for the diagnosis of PVV [3]. However, it is reserved for inconclusive studies only when a CT scan cannot provide a clear diagnosis [11].

Batram and Strickland set a criteria for conventional angiography diagnosis which includes (1) normal arterial phase, (2) filling of varix in venous phase, (3) direct drainage to the left atrium, (4) delayed emptying, and (5) localization to proximal portion of the pulmonary vein [18].

Complications of PVV include hemoptysis due to rupture, or bronchial compression resulting in middle lobe syndrome, esophageal compression inducing dysphagia, and cerebral infarction due to thromboembolic sequelae [4,8,19]. In most of the cases, the treatment of an asymptomatic PVV is unnecessary. However, monitoring is crucial. The increase in size increases the risk of complication and the necessity to undergo surgical intervention [7,19]. Symptomatic patients with pulmonary venous hypertension due to mitral valve disease must undergo mitral valve replacement surgery, especially if the varix has progressively increased in size [6].

## REFERENCES

- [1] Kumazow H, Komori M, Ochiai R, Egashira R, Nakazono T, Kudo S. Pulmonary varix mimicking arteriovenous malformation. *Clin Imaging* 2008;32:61–4.
- [2] Porres D, Morenza O, Pallisa E, Rogue A, Andreu J, Martines M. Learning from the pulmonary veins. *Radiographics* 2013;33:999–1022.
- [3] Andrikakos P, Gallis P, Christopoulos A, Flabouriaris S, Mylona M, Dimopoulos PA. An asymptomatic pulmonary hilar mass: a case report. *Acta Radiol* 2004;45(5):516–18.
- [4] Haddad J, Badran A, Pavao R, De Padua A, Lago I, Marin Neto J. Pulmonary varix: a case report. *Rev Port Cardiol* 2016;35(7–8):443.
- [5] Vanherreweghe E, Rigauts H, Bogaerts Y, Meeus L. Pulmonary vein varix: diagnosis with multislice helical CT. *Eur Radiol* 2000;10:1315–17.
- [6] Kelser G, Adkins P, Shefferman M. Pulmonary varix regression after mitral valve replacement. *Am J Cardiol* 1976;37:928–32.
- [7] Emmert A, Jebran A, Schmidt K, Hinterthaler M, Bohnenberger H, Bahr M, et al. Aneurysm of the pulmonary vein: an unusual cause of stroke. *Ann Thorac Surg* 2014;98(5):1841–3.
- [8] Berecova Z, Neuschi V, Boruta P, Masura J, Ghersin E. A pulmonary vein varix—diagnosis with ECG gated MDCT, MRI and invasive pulmonary angiography. *J Radiol Case Rep* 2012;6(12):9–16.
- [9] Uyama T, Monden Y, Harada K, Tamaki H, Miura K, Taniki T, et al. Pulmonary varices: a case report and review of the literature. *Jpn J Surg* 1988;18(3):359–62.
- [10] Moro C, Marin E, Sanchez A, Solozabal J. Pulmonary varix: report of a case with additional anomalies of the vascular pulmonary tree. *Am Heart J* 1978;95(2):243–6.
- [11] Nafees M, Abbas G, Amin MU. Pulmonary varices—rare cause of haemoptysis. *J Coll Physicians Surg Pak* 2011;21(7):437–8.
- [12] Narula J, Talwar KK, Bharani A, Mukhopadhyaya S, Rajani M, Bhatia ML. Pulmonary varix associated with mitral valve disease. *Cathet Cardiovasc Diagn* 1987;13:411–13.
- [13] Palker A, Shah R, Greben C, Talwar A. Pulmonary venous varix. *Am J Respir Crit Care Med* 2015;192(12):e59.
- [14] Shida T, Ohashi H, Nakamura K, Morimoto M. Pulmonary varices associated with mitral valve disease: a case report and survey of the literature. *Ann Thorac Surg* 1982;34(4):452–6.
- [15] Davia JE, Golden MS, Price HL, Hastings JE, Cheitlin MD. Pulmonary varix: a diagnostic pitfall. *Circulation* 1974;49:1011–12.
- [16] Shiraishi J, Tatsumi T, Kimata M, Kambayashi D, Mano A, Yamanaka S, et al. Echocardiographic diagnosis of pulmonary vein varix. *Circ J* 2003;67:796–8.
- [17] Steinberg I. Pulmonary varices mistaken for pulmonary and hilar disease. *Am J Roentgenol Radium Ther Nucl Med* 1967;101(4):947–52.
- [18] Batram C, Strickland B. Pulmonary varices. *Br J Radiol* 1971;44:927–35.
- [19] Tajiri S, Koizumi J, Hara T, Kamono M, Hayama N, Kobayashi I, et al. A case of pulmonary varix associated with superior pulmonary vein occlusion. *Ann Vasc Dis* 2012;5(3):381–4.