

# Pleural plaques related to “take-home” exposure to asbestos: An international case series

Alon Peretz<sup>1,2</sup>

Victor C Van Hee<sup>2</sup>

Mordechai R Kramer<sup>3</sup>

Silvio Pitlik<sup>3</sup>

Matthew C Keifer<sup>2</sup>

<sup>1</sup>Occupational Medicine Clinic, General Health Services, Kfar Saba, Israel; <sup>2</sup>Department of Environmental and Occupational Health Sciences, University of Washington, Seattle, Washington, USA; <sup>3</sup>Rabin Medical Center, Petach Tikvah, Israel

**Context:** While a large number of studies indicate the risks of high-level exposures to asbestos in the workplace setting, a relatively small number of studies describe the risk of pleural disease related to “take-home” asbestos brought into the household by workers exposed to asbestos. Consequently, the risk of pleural disease in family members of asbestos-exposed workers is likely underappreciated.

**Case presentations:** Two families of siblings, one in Israel and one in the US, were evaluated because of their significant exposures to asbestos brought into the home by family members with heavy occupational exposures. Two of the four children of an asbestos cement debagger in Petach Tikvah, Israel and two children of a pipe lagger in a naval shipyard near Seattle, Washington, manifested benign pleural disease without parenchymal disease, despite having no occupational exposure to asbestos.

**Discussion:** These cases illustrate that “take-home” asbestos exposure may lead to pleural disease at higher rates than commonly realized.

**Relevance to clinical practice:** Providers should recognize that due to the potential for “take-home” exposures, asbestos-related disease in a patient may be a marker for disease in household contacts. Patients with family members heavily exposed to asbestos should be strongly encouraged to quit smoking in an effort to reduce any further carcinogenic exposures. Additionally, workplace control and regulation of asbestos use should be emphasized to protect both workers and their families.

**Keywords:** take-home, household, asbestos, pleural plaques, case series, environmental, nonoccupational

## Case presentation I: Petach Tikvah, Israel

A 57-year-old asymptomatic man with no medical problems was seen for a routine physical examination in 2003. A chest X-ray previously performed during a self-limited episode of bronchitis had suggested pleural abnormalities, prompting him to undergo high-resolution computed tomography (HRCT) of the chest. This scan showed bilateral thickening of the diaphragmatic pleura suggestive of exposure to asbestos. Subsequent complete pulmonary function testing, including measurement of lung volumes and diffusing capacity, was normal.

A detailed occupational history revealed no sources of occupational asbestos exposure. He had worked as a marketer of fresh produce earlier in life, and for the last fifteen years had been employed as an insurance agent. He was a lifelong nonsmoker.

Family history established that the patient’s father had worked for ten years (1952–1962) as a debagger in a plant that produced asbestos cement sheets and plates. The patient’s father was born in 1921 in Iraq, and he had immigrated to Israel in 1948. At the asbestos cement plant, his primary job task involved manually emptying bags of dry asbestos fibers into a blender in the first stage of the process of asbestos cement manufacture. No exposure monitoring data from the father’s cement plant was available, although data from another asbestos cement plant in the region for a similar

Correspondence: Victor C Van Hee  
Harborview Medical Center,  
325 Ninth Ave., Box 359739,  
Seattle, WA, 98104 USA  
Tel +1 206 744 9380  
Fax +1 206 744 9935  
Email vvanhee@u.washington.edu

time period indicates asbestos fiber composition consisting of about 90% chrysotile and 10% crocidolite fibers, associated with elevated risk of mesothelioma and lung cancer in workers at that plant (Tulchinsky et al 1999). The patient's father had been diagnosed with pleural changes consistent with asbestos exposure based upon a chest X-ray performed in 1958, and in 1970 he was diagnosed with asbestosis. His pulmonary function worsened over the next 7 years, and in 1977 the patient's father died of respiratory failure. An autopsy was not performed.

The patient noted that he had never visited his father's workplace as a child and did not live near the asbestos cement plant. He reported that his father frequently returned home from work with particularly dusty clothing. On detailed history, he described no other occupational or environmental exposure to asbestos.

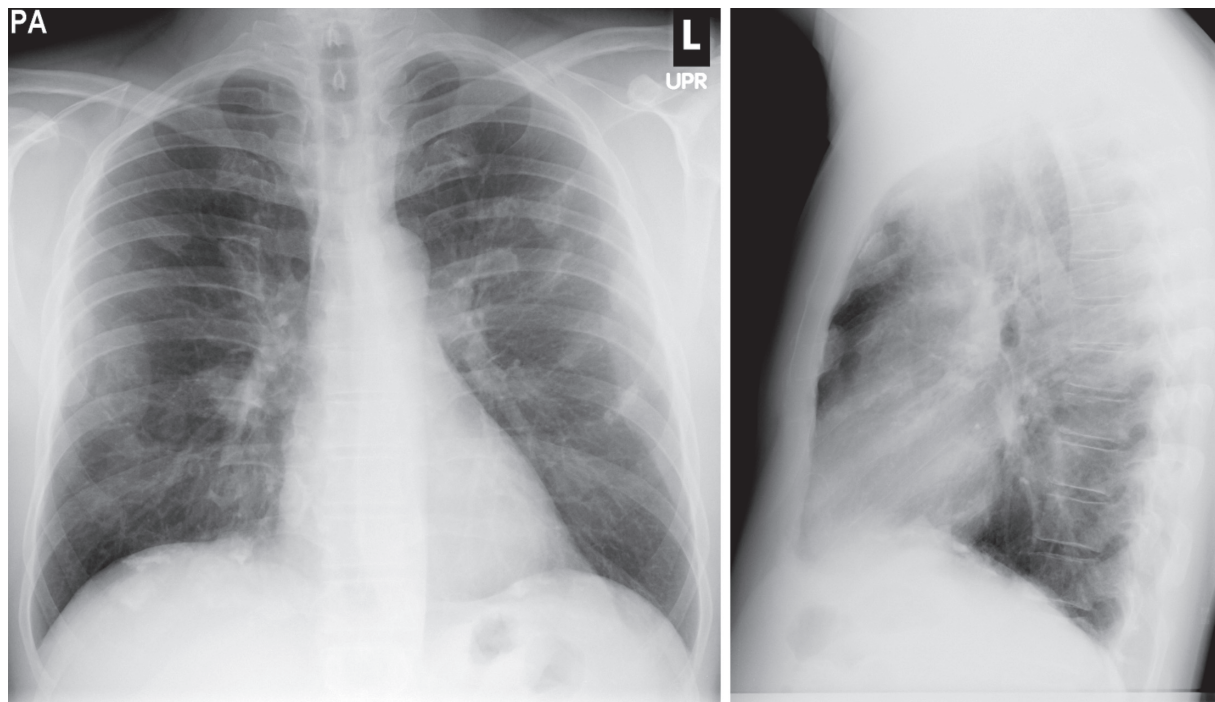
Because of the pleural abnormalities noted on the patient's HRCT and the concern that his condition may have been related to childhood "take-home" exposure to asbestos from his father's workplace, the patient's three siblings were advised to undergo examinations for asbestos-related disease. All three had lived in the same home during childhood, and none had been exposed occupationally to asbestos. All three had HRCT of the chest and complete pulmonary function testing later that year. Due to her advanced age and health status, the patient's mother did not undergo evaluation.

One of the patient's siblings, an asymptomatic and otherwise healthy 55-year-old brother who was also a never-smoker, demonstrated bilateral calcified pleural plaques on HRCT. A detailed occupational history revealed that he had worked with his brother marketing fresh produce earlier in life, and then joined his brother more recently in insurance sales. He had no other occupational or environmental exposure to asbestos. He also had normal pulmonary function tests (PFTs).

The other two siblings (a 59-year-old man and a 52-year-old woman) had no radiographic findings suggestive of asbestos exposure, and both had normal PFTs.

## Case presentation 2: Seattle, Washington, USA

A 52-year-old asymptomatic man presented in 2002 for a baseline physical examination. Screening chest X-ray, performed because of his extensive silica exposure as a laborer, demonstrated multiple bilateral calcified pleural plaques consistent with asbestos exposure (Figure 1). A subsequent HRCT of the chest, performed in the course of a complete evaluation in Seattle, showed the widespread calcified pleural plaques involving the diaphragm and extending to the mid-thoracic lung that had been seen on chest X-ray, and no parenchymal changes consistent with either asbestos-related disease or silicosis. PFTs were normal.



**Figure 1** Postero-anterior and lateral chest radiographs demonstrating extensive, patchy, bilateral calcified pleural plaques.

The patient had been a laborer since 1969, and he had worked in various capacities at multiple job sites throughout Washington State during that time period. A comprehensive occupational history performed by the clinic industrial hygienist spanning 21 sites of employment over the course of 33 years identified no significant asbestos exposure, including no asbestos remediation or demolition work. However, significant exposure to dusts, including silica dust, during concrete finishing work and dry mixing of grout were noted.

A family history established that the patient's father had been a pipe lagger at a naval shipyard beginning in 1953. Prior to that time, his father had been a carpenter in a naval shipyard. Detailed exposure information regarding specific asbestos fiber types during his decades of shipyard work was not available. He had developed asbestosis in his 60s, and he subsequently died of small cell lung cancer at age 62. The patient recalled having visited the shipyard with his father once or twice at a young age. The patient's father removed his overalls and left them at work prior to returning home daily, but brought his overalls home to be washed with the family's clothing weekly.

The patient's mother, who had developed complications related to diabetes, died of a stroke at the age of 58. She had never been noted to have significant pulmonary abnormalities, although imaging was not available. The patient's sister, who was the eldest at age 58 and was asymptomatic, was also evaluated in Seattle. From about the age of 10 to the age of 18, the patient's sister recalled doing the family's laundry about weekly. She remembers shaking out her father's overalls, which were covered in dust, and washing them with the rest of the family's clothing. The sister worked as a switchboard operator for a local phone company, and later worked as a housekeeper. In addition to working for the local phone company, she worked for 30 days as a switchboard operator in a naval base, but recalls no exposure to asbestos during this time. She had a 17 pack-year history of smoking and quit 20 years prior to this evaluation. She was married in 1966 to a rigger at a naval shipyard who noted exposures to asbestos dust in the shipyard while working near ladders between the years of 1966 and 1969. The patient's sister washed her husband's work clothing during this time, and reported shaking the clothing out prior to washing, as she had done with her father's clothing.

The patient's sister was discovered to have bilateral pleural plaques on chest X-ray beginning in 1995, which progressed to diffuse, patchy, calcified plaques by 2003. She had been initially evaluated radiographically in 1995 because of her family history of asbestos-related disease and presumed

exposure to "take-home" asbestos throughout her childhood and young adulthood. On testing performed in Seattle, PFTs with lung volumes were normal. Diffusing capacity was mildly reduced (71% predicted), with a normal resting arterial blood gas. HRCT revealed bilateral calcified pleural plaques (Figure 2). No parenchymal disease was observed.

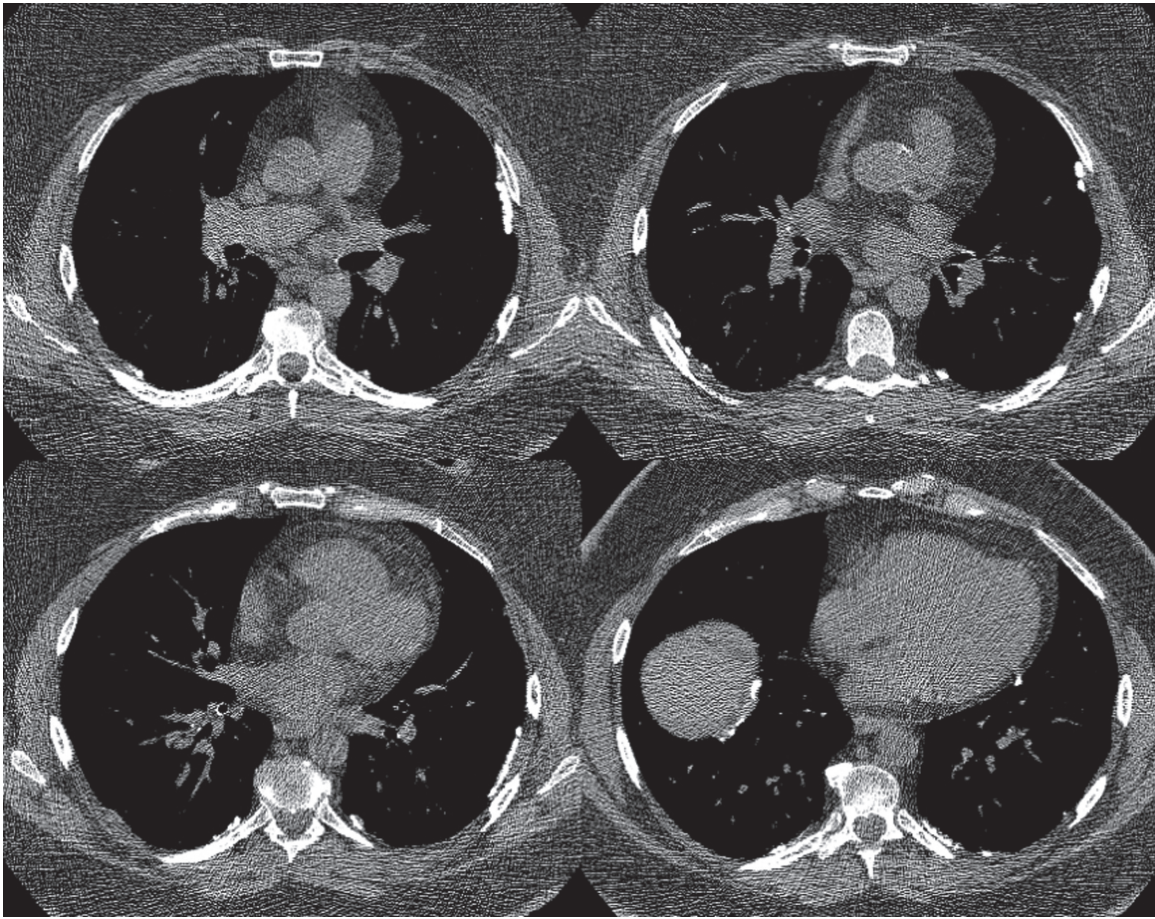
## Discussion

Two families, one in Petach Tikvah and one in Seattle, were evaluated for the presence of asbestos-related lung disease on the basis of significant exposure to asbestos brought home by heavily-exposed workers. Two out of the four siblings in Petach Tikvah, including the index case, had significant but asymptomatic pleural disease without parenchymal disease. None had occupational exposures to asbestos. In Seattle, both siblings, neither of whom had significant occupational exposure to asbestos, had calcified pleural plaques. Both siblings in Seattle were asymptomatic, and neither had parenchymal disease.

Exposure to asbestos has widely-recognized and well-characterized toxicity to lung pleura and parenchyma, including benign pleural disease, malignant pleural disease (mesothelioma), interstitial lung disease (asbestosis), and lung cancer. The use of asbestos in developed nations has been reduced since the 1970s and significantly improved controls have been implemented. However, the use of asbestos in developing nations is increasing, with likely poorer implementation of standards and controls (Kazan-Allen 2005).

Asbestos is a naturally-occurring fibrous silicate mineral often used historically in building materials and clothing for its valuable physical properties including thermal stability and strength. Asbestos fibers occur in two forms: the serpentine chrysotile and the family of needle-like amphiboles. Chrysotile fibers have been involved predominantly in the production of fabric. The amphibole group, of which amosite and crocidolite have had the most commercial use, has often been used in the production of asbestos cement products including pipes and floor tiles, sometimes in combination with chrysotile fibers. Although all types of asbestos are carcinogenic, amphibole fibers appear to have a more deleterious effect upon the pleura than do chrysotile fibers (Bourdes et al 2000), likely in part because they are less biodegradable (Cugell and Kamp 2004).

Although exposure to asbestos typically takes place with highest intensity in occupational settings, environmental and household exposures do occur. Environmental sources of tremolite and chrysotile asbestos in Turkey (Senyigit et al 2000), Greece (Sichletidis et al 2006), and several Mediterranean



**Figure 2** High-resolution computed tomography of the chest demonstrating bilateral calcified parietal pleural plaques, a right calcified diaphragmatic plaque and a left calcified mediastinal plaque.

islands (Rey et al 1993; Paoletti et al 2000), crocidolite in China (Luo et al 2003) and Australia (Reid et al 2007), tremolite in New Caledonia (Luce et al 2004), and chrysotile (Pan et al 2005) and vermiculite (Peipins et al 2003) in the US have been observed to produce health effects. Proximity to industrial sources of asbestos, such as asbestos cement plants (Marconi et al 1989), also represents a source of asbestos exposure. Other sources of nonoccupational exposure include asbestos present in building materials and exposure to asbestos that is taken home from work by workers in the asbestos industry (Goldberg and Luce 2005). Typically, family members of asbestos workers are exposed through contaminated clothes, shoes, skin, and hair of asbestos workers. Brushing asbestos-contaminated clothing may produce airborne concentrations of asbestos as high as 100 fibers/ml, one-hundred times higher than the US Occupational Safety and Health Administration 30-minute excursion limit of 1 fiber/ml (Hillerdal 1999). Asbestos fibers brought home can remain for years in the home environment, unresponsive to standard vacuum cleaning, and becoming resuspended in air when disturbed (Hillerdal 1999).

Because asbestos tends to affect the pleura more readily than the lung parenchyma, lower-level exposures to asbestos are associated most clearly with diseases of the pleura. These include the benign pleural diseases of pleural plaques, pleural effusion, and diffuse pleural fibrosis, and the primary pleural malignancy, mesothelioma (Cugell and Kamp 2004). Benign pleural disease, though frequently asymptomatic, may cause morbidity through reduction in lung function and symptoms if extensive (Chapman et al 2003). In most cases, pleural plaques, and especially bilateral, patchy, diffuse plaques, are considered effectively pathognomonic for asbestos exposure (Peacock et al 2000).

While a large number of studies indicate the risks of high-level exposures to asbestos in the workplace setting (McDonald and McDonald 1996), a relatively small number of studies describe the risk of pleural disease related to nonoccupational or household exposures. Most of these studies report the risk of developing malignant mesothelioma, for which there appears to be no threshold dose of asbestos. Several studies describe the mesothelioma risks related to

living in households containing asbestos materials or in regions environmentally contaminated with asbestos (Bourdes et al 2000). Few report the mesothelioma risks among families of asbestos workers exposed to asbestos brought from the occupational setting into the home environment (Gardner and Saracci 1989; Hillerdal 1999; Miller 2005). Fewer still describe the nonoccupational risk of benign pleural disease among household members of asbestos workers (Anderson et al 1979; Epler et al 1980; Kilburn et al 1985; Sider et al 1987; Whitehouse 2004).

Plaques are the most common radiographic manifestation of asbestos exposure, and individuals who are occupationally-exposed have a prevalence of pleural plaques as high as 58% among insulation workers (Peacock et al 2000). In nonoccupational settings, that prevalence has been thought to reach 8% (Peacock et al 2000), but the often asymptomatic nature of pleural plaques suggests that this condition may be under-diagnosed.

In fact, in the few epidemiologic studies conducted thus far that have examined the prevalence of benign pleural disease related to “take-home” exposures, the observed prevalence was often higher than the previously cited figure of 8%. Sider and colleagues (1987) studied 93 wives of insulation workers exposed to asbestos, of whom eighteen (19.4%) demonstrated pleural changes consistent with asbestos exposure. In Libby, Montana, USA, where widespread environmental contamination with asbestiform fibers of the amphibole group was associated with pulmonary disease (Agency for Toxic Substances and Disease Registry 2000), multiple cases of asbestos-related pulmonary disease among household contacts of former mine workers have been reported (Whitehouse 2004). In an effort to quantify the multiple pathways through which individuals living in Libby could be exposed (occupational, recreational, household, living with a worker occupationally-exposed, etc.) and the risk of disease related to each pathway, Peipens and colleagues (2003) examined radiographic abnormalities of residents of Libby. The authors considered 29 potential exposure pathways and found that 26% of the individuals that lived with a worker demonstrated pleural abnormalities on chest X-ray, although the exposure pathways were not mutually exclusive (Peipens et al 2003). Household members of asbestos factory workers in New Jersey were also found to have a 26% prevalence of benign pleural disease (Anderson et al 1979). A study of the families of shipyard workers in Los Angeles County conducted in the early 1980s revealed a 5% prevalence of pleural disease, although the age of the sons and daughters of workers in this study was relatively low and therefore

the latency period of short duration (Kilburn et al 1985). Recently, a case series reported the development of pleural plaques in three of six siblings environmentally exposed to asbestos in hessian superphosphate fertilizer bags in rural Western Australia as children (Musk et al 2006).

## Conclusion

We have presented two series of cases that graphically demonstrate the development of benign pleural disease in family members of workers exposed to “take-home” asbestos during childhood. All of these patients were asymptomatic on diagnosis, and without radiographic imaging, their condition would not likely have been discovered. These cases illustrate that the incidence of pleural plaques in relation to “take-home” asbestos exposure may be higher than previously realized.

Historically, before widespread knowledge of the toxicity of asbestos and the reduction of asbestos use in industrialized countries with improved controls, workers more frequently returned home carrying quantities of fibers sufficient to significantly increase the risk of benign and malignant pleural disease in their families. The cases presented here should illustrate to the clinician that a family history of asbestos-related disease may indicate substantial lifetime exposure to asbestos. The experiences of these two families of patients should motivate the clinician to intensify smoking cessation efforts in patients with a family history of asbestos-related disease, to diminish further carcinogenic exposures. These cases should also underscore the importance of the full implementation of industrial hygiene ‘hierarchy of control’ to reduce asbestos-related hazards—including elimination, substitution and engineering controls where possible, and administrative controls and personal protective equipment when these higher level controls are not possible. At a minimum, appropriate workplace hygiene practices need to be observed in an effort to reduce not only diseases in workers, but also in their families.

## Disclosure

Alon Peretz and Victor C Van Hee provided equal contributions to this work. The authors would like to thank Nancy Beaudet, CIH, for the very detailed occupational history described in Case Presentation 2. The authors report no conflicts of interest or competing financial interests in this work.

## References

- Agency for Toxic Substances and Disease Registry. 2000. Mortality in Libby, Montana 1979–1998. Libby Asbestos Site, Libby, Lincoln County, Montana. Atlanta, GA.
- Anderson HA, Lillis R, Daum SM, et al. 1979. Asbestosis among household contacts of asbestos factory workers. *Ann NY Acad Sci*, 330:387–99.

- Bourdes V, Boffetta P, Pisani P. 2000. Environmental exposure to asbestos and risk of pleural mesothelioma: review and meta-analysis. *Eur J Epidemiol*, 16:411–7.
- Chapman SJ, Cookson WO, Musk AW, et al. 2003. Benign asbestos pleural diseases. *Curr Opin Pulm Med*, 9:266–71.
- Cugell DW, Kamp DW. 2004. Asbestos and the pleura: a review. *Chest*, 125:1103–17.
- Epler GR, Fitz Gerald MX, Gaensler EA, Carrington CB. 1980. Asbestos-related disease from household exposure. *Respiration*, 39:229–40.
- Gardner MJ, Saracci R. 1989. Effects on health of non-occupational exposure to airborne mineral fibres. *IARC Sci Publ*, (90):375–97.
- Goldberg M, Luce D. 2005. Can exposure to very low levels of asbestos induce pleural mesothelioma? *Am J Respir Crit Care Med*, 172:939–40.
- Hillerdal G. 1999. Mesothelioma: cases associated with non-occupational and low dose exposures. *Occup Environ Med*, 56:505–13.
- Kazan-Allen L. 2005. Asbestos and mesothelioma: worldwide trends. *Lung Cancer*, 49(Suppl 1):S3–8.
- Kilburn KH, Lilis R, Anderson HA, et al. 1985. Asbestos disease in family contacts of shipyard workers. *Am J Public Health*, 75:615–7.
- Luce D, Billon-Galland MA, Bugel I, et al. 2004. Assessment of environmental and domestic exposure to tremolite in New Caledonia. *Arch Environ Health*, 59:91–100.
- Luo S, Liu X, Mu S, et al. 2003. Asbestos related diseases from environmental exposure to crocidolite in Da-yao, China. I. Review of exposure and epidemiological data. *Occup Environ Med*, 60:35–41.
- Marconi A, Cecchetti G, Barbieri M. 1989. Airborne mineral fibre concentrations in an urban area near an asbestos-cement plant. *IARC Sci Publ*, (90):336–46.
- McDonald JC, McDonald AD. 1996. The epidemiology of mesothelioma in historical context. *Eur Respir J*, 9:1932–42.
- Miller A. 2005. Mesothelioma in household members of asbestos-exposed workers: 32 United States cases since 1990. *Am J Ind Med*, 47:458–62.
- Musk AW, Olsen NJ, Reid A, et al. 2006. Asbestos-related disease from recycled hessian superphosphate bags in rural Western Australia. *Aust N Z J Public Health*, 30:312–3.
- Pan XL, Day HW, Wang W, et al. 2005. Residential proximity to naturally occurring asbestos and mesothelioma risk in California. *Am J Respir Crit Care Med*, 172:1019–25.
- Paoletti L, Batisti D, Bruno C, et al. 2000. Unusually high incidence of malignant pleural mesothelioma in a town of eastern Sicily: an epidemiological and environmental study. *Arch Environ Health*, 55:392–8.
- Peacock C, Copley SJ, Hansell DM. 2000. Asbestos-related benign pleural disease. *Clin Radiol*, 55:422–32.
- Peipins LA, Lewin M, Campolucci S, et al. 2003. Radiographic abnormalities and exposure to asbestos-contaminated vermiculite in the community of Libby, Montana, USA. *Environ Health Perspect*, 111:1753–9.
- Reid A, Berry G, de Klerk N, et al. 2007. Age and sex differences in malignant mesothelioma after residential exposure to blue asbestos (crocidolite). *Chest*, 131:376–82.
- Rey F, Boutin C, Steinbauer J, et al. 1993. Environmental pleural plaques in an asbestos exposed population of northeast Corsica. *Eur Respir J*, 6:978–82.
- Senyigit A, Babayigit C, Gokirmak M, et al. 2000. Incidence of malignant pleural mesothelioma due to environmental asbestos fiber exposure in the southeast of Turkey. *Respiration*, 67:610–4.
- Sichletidis L, Chloros D, Chatzidimitriou N, et al. 2006. Diachronic study of pleural plaques in rural population with environmental exposure to asbestos. *Am J Ind Med*, 49:634–41.
- Sider L, Holland EA, Davis TM Jr., et al. 1987. Changes on radiographs of wives of workers exposed to asbestos. *Radiology*, 164:723–6.
- Tulchinsky TH, Ginsberg GM, Iscovich J, et al. 1999. Cancer in ex-asbestos cement workers in Israel, 1953–1992. *Am J Ind Med*, 35:1–8.
- Whitehouse AC. 2004. Asbestos-related pleural disease due to tremolite associated with progressive loss of lung function: serial observations in 123 miners, family members, and residents of Libby, Montana. *Am J Ind Med*, 46:219–25.