

Could It be Wolf Isotopic Response?: Occurrence of Dermatophytoses on Vitiliginous Skin-Case Series of Five Cases from a Tertiary Care Centre in India

Abstract

Wolf isotopic response is the occurrence of new dermatoses on areas of the skin with previous but still active dermatoses. Vitiligo is an acquired disorder characterized by the loss of functional melanocytes which manifests as circumscribed depigmented macules and patches. Dermatophytoses are superficial fungal infections caused by three genera of fungi (*Microsporum*, *Trichophyton*, and *Epidermophyton*) that have the unique ability to invade and multiply within keratinized tissue (skin, hair, and nail). The appearance of dermatophyte infection on previously present vitiligo lesion is an uncommon example of Wolf response. We describe a case series of five vitiligo patients that presented to our OPD over 1 year period.

Keywords: Dermatophytoses, tinea, vitiligo, wolf isotopic response

**Shreya Poddar,
Somnath Das,
Sumit Sen¹,
Gobinda Chatterjee**

Department of Dermatology,
IPGME and R and SSKMH,
Kolkata, West Bengal, ¹Senior
Resident, Asansol District
Hospital, Asansol, West Bengal,
India

Introduction

Vitiligo is an acquired hypopigmentation disorder characterized by loss of functional melanocytes. Broadly, vitiligo can be divided into two categories: segmental and generalized. Dermatophytoses (tinea corporis) is a superficial fungal infection of the skin of the trunk and extremities, characterized by annular scaly lesions associated with pruritus and burning. The most common cause of tinea corporis is *T. rubrum* followed by *T. mentagrophytes*.

Wolf isotopic response is the occurrence of new dermatoses on areas of skin with previous but still active dermatoses. The occurrence of tinea corporis on previously present vitiligo patches is an example of a Wolf response. We describe a case series of five vitiligo patients that presented to our OPD over 1 year period. The cases were diagnosed on the grounds of history and physical examination supplemented with a skin scraping and 10% KOH examination.

Case Reports

Case 1

A 52-year-old male presented with acro-facial vitiligo for the last 25 years

involving upper extremities, lower extremities, and lips. There was no Koebner phenomenon. The patient had associated hypothyroidism and type 2 diabetes. The patient was treated with PUVA-sol and topical superpotent steroids in the past and was receiving no treatment in the present. The patient presented with scaly, pruritic, oval lesions with papules at the active border on the left ankle over a patch of vitiligo for the last 3 months [Figure 1]. On skin scraping and KOH mount, plenty of fungal elements were seen. Culture on fungal media showed growth of *T. mentagrophytes*. He was treated with ketoconazole cream and oral griseofulvin for 6 weeks with complete resolution of tinea.

Case 2

A 52-year-old female attended Dermatology OPD with vitiligo vulgaris for the last 20 years involving the scalp, trunk, upper, and lower extremities. There was no Koebner phenomenon. The patient was known diabetic and hypertensive. The patient was treated with oral corticosteroids and topical superpotent steroids in the past and was

Address for correspondence:

Dr. Somnath Das,
244, AJC Bose Road,
Kolkata - 700 020, West Bengal,
India.
E-mail: bappa.2019@gmail.com

This is an open access journal, and articles are distributed under the terms of the Creative Commons Attribution-NonCommercial-ShareAlike 4.0 License, which allows others to remix, tweak, and build upon the work non-commercially, as long as appropriate credit is given and the new creations are licensed under the identical terms.

For reprints contact: WKHLRPMedknow_reprints@wolterskluwer.com

How to cite this article: Poddar S, Das S, Sen S, Chatterjee G. Could it be wolf isotopic response?: Occurrence of dermatophytoses on vitiliginous skin-case series of five cases from a tertiary care centre in India. Indian Dermatol Online J 2022;13:240-3.

Received: 13-Jun-2021. **Revised:** 24-Jun-2021.

Accepted: 02-Aug-2021. **Published:** 03-Mar-2022.

Access this article online

Website: www.idoj.in

DOI: 10.4103/idoj.idoj_377_21

Quick Response Code:



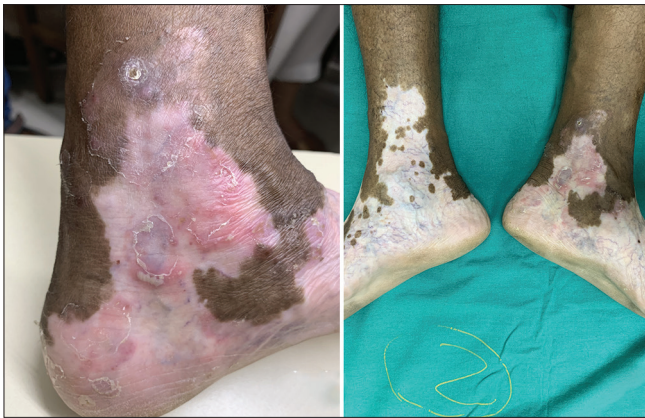

Figure 1: Tinea over vitiligo patches on the left ankle for the last 3 months

receiving no treatment in the present. Scaly, pruritic, erythematous oval lesions with papules at the active border on the anterior abdomen over vitiligo patches were observed for the last 1 month [Figure 2a]. On skin scraping and KOH mount, plenty of fungal elements were seen. Culture on fungal media showed growth of *T. mentagrophytes*. She was treated with ketoconazole cream and oral itraconazole for 6 weeks with complete resolution of tinea.

Case 3

A 50-year-old non-diabetic, nonhypertensive female presented with generalized vitiligo for the last 12 years involving almost the whole body. There was no Koebner phenomenon. The patient received no treatment for vitiligo. Scaly, pruritic, erythematous oval lesions with papules at the active border on the right flank and right lateral trunk were present for the last 1.5 months [Figure 3]. On skin scraping and KOH mount, plenty of fungal elements were seen. Culture on fungal media showed growth of *T. rubrum*. She was treated with sertaconazole cream and oral terbinafine for 8 weeks with complete resolution of tinea.

Case 4

A female patient aged 50 years attended Skin OPD with vitiligo vulgaris for the last 20 years involving the anterior abdomen. There was no Koebner phenomenon. The patient was known diabetic but nonhypertensive. The patient was treated with topical superpotent steroids and calcineurin inhibitors in the past and was receiving no treatment in the present. The patient complained of scaly, pruritic, erythematous polycyclic lesions on the anterior abdomen over vitiligo patches for the last 3 months [Figure 2b]. On skin scraping and KOH mount, plenty of fungal elements were seen. Culture on fungal media showed growth of *T. mentagrophytes*. She was treated with luliconazole cream and oral terbinafine for 10 weeks with complete resolution of tinea.

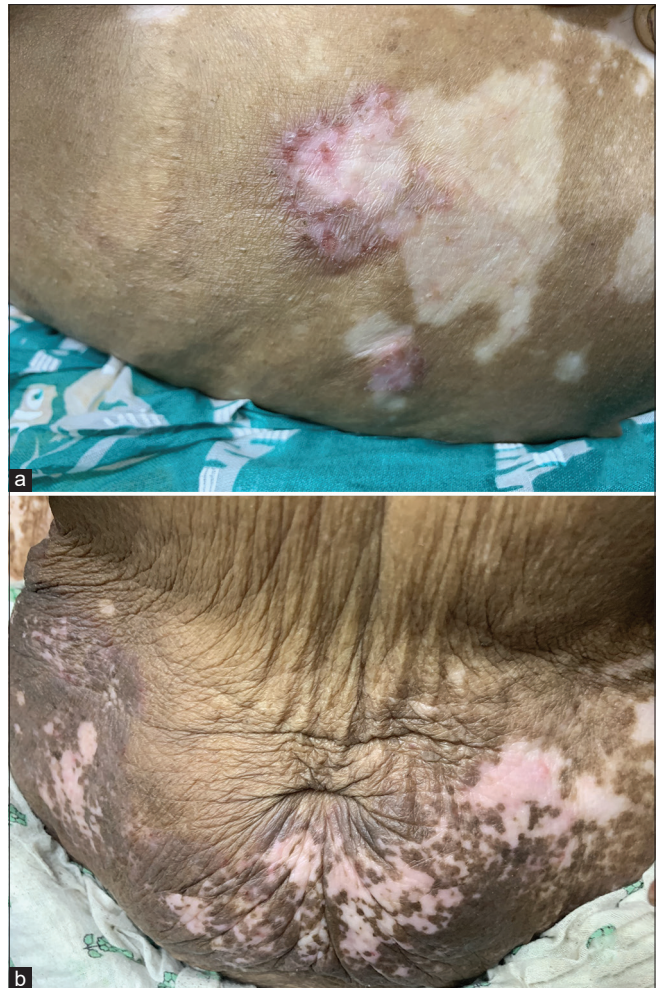

Figure 2: (a): Tinea over vitiliginous skin on the anterior abdomen for the last 1 month; (b): Tinea over vitiliginous skin on the anterior abdomen for the last 3 months

Case 5

A young nondiabetic, nonhypertensive female of 30 years age presented with vitiligo vulgaris for the last 8 months involving the scalp, face, trunk, upper, and lower extremities. There was no Koebner phenomenon. The patient was being treated with topical calcineurin inhibitors. The patient complained of multiple, pruritic, erythematous annular lesions on the left lower neck over the vitiligo patch for the last 20 days [Figure 4]. On skin scraping and KOH mount, plenty of fungal elements were seen. Culture on fungal media showed growth of *T. rubrum*. She was treated with sertaconazole cream and oral terbinafine for 6 weeks with complete resolution of tinea.

Discussion

“Wolf isotopic response” was coined in 1995 to refer to the occurrence of a new dermatosis on areas of skin with previous lesions that had healed and that bore no relationship with the new lesions.^[1] A recent classification defined the *isotopic response* as the occurrence of a

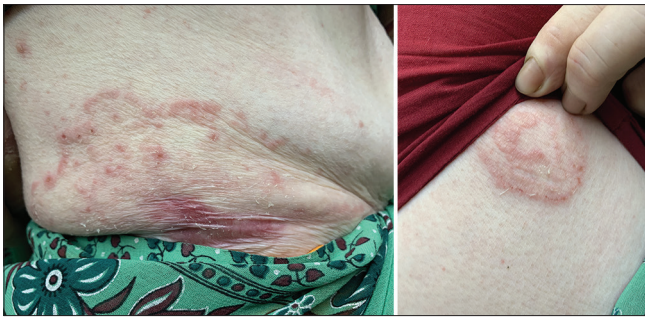

Figure 3: Tinea over vitiliginous skin on the right lateral trunk and right flank for the last 1 month

dermatosis that develops in the same area of skin as another previously present but still active dermatosis.^[2]

In 1955, Wyburn-Mason^[3] first described the occurrence of new skin disease at the site of another skin disease that had already healed. Numerous such cases were reported in the literature till Wolf and Wolf^[1] in 1985 gave it the term “isoloci response” (same locus). It was changed to “isotopic response” (same place) by Wolf *et al.*,^[4] and finally renamed as Wolf’s isotopic response by Ruocco *et al.*^[5] Dermatoses that appear after exposure to external agents such as chemicals and radiation should not be included in the isotopic response.

Although the two dermatoses are unrelated in morphology, the second disease might be due to changes during the healing phase of the first disease. The healed skin shows microscopic and physiologic changes for a long duration after the initial insult, and some of these changes might be responsible for the occurrence of new dermatosis.^[6] The dermatoses which present as a consequence of isotopic response have been categorized into infections, granulomatous reactions, leukemic infiltrates, malignant tumors, dermatoses secondary to immunologic dysfunction, comedonic reactions, and miscellaneous.

The classic examples of Wolf response are lesions of urticaria, comedones, lichen planus, fungal infections, vitiligo, etc. occurring over healed herpes zoster lesions.

Dermatophytosis is a common superficial fungal infection that is precipitated by factors such as advanced age, Cushing’s disease, iatrogenic corticosteroid therapy, hematologic malignancy, chronic mucocutaneous candidiasis, diabetes mellitus, atopy, etc. The local defense against dermatophytoses involves epidermal Langerhans cells, antifungal properties of sebum, T-lymphocytes, and metalloproteases synthesis. Chronic dermatophytoses were found to be associated with poor T-cell-mediated response to fungal antigens. Langerhans cells also act as antigen-presenting cell for dermatophyte antigens.

Vitiligo is associated with many autoimmune diseases. There is well-documented evidence that epidermal dendritic

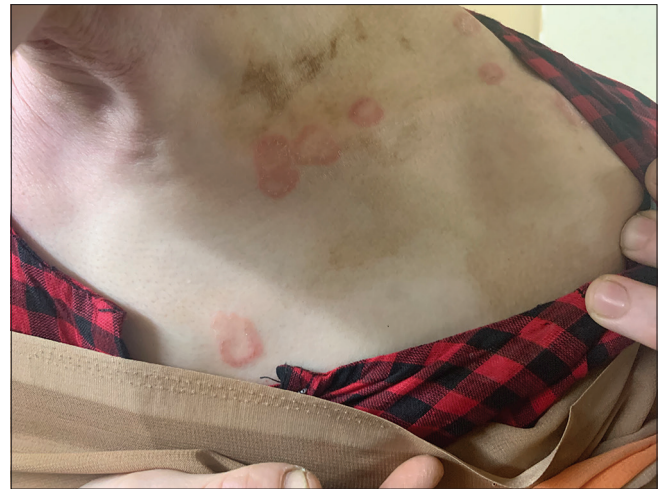

Figure 4: Tinea over vitiliginous skin on the left lower neck for the last 20 days

cells (Langerhans cells and intermediate cells) are absent in vitiligo patches. The epidermal cells derived from vitiligo patches show a lower stimulatory effect in the allogeneic mixed skin cell lymphocyte culture reaction than those from normal skin, suggesting a possibility of functional impairment of Langerhans cells in vitiliginous skin.^[7] The occurrence of dermatophytoses in vitiligo patches might be due to the local immune defects either directly to reduced or absent melanocytes or indirectly to the reduced number of Langerhans cells in a vitiligo patch. There might be some role of altered T-cells in dermatophytoses within the vitiligo patches. Associated diabetes could also play some role and the use of topical steroids, calcineurin inhibitors, and PUVA used in the treatment of vitiligo should also be taken into account, as they have an immunomodulatory effect that lower the local defenses against fungal infections.

Two cases have been reported in the literature. Parimalam *et al.* reported a case of tinea limited to vitiligo patch in a 70-year-old diabetic female.^[8] AG Rao reported a case of tinea bordering vitiligo patch in a 30-year-old nondiabetic female on treatment with tacrolimus and PUVA.^[9]

All of the five patients had developed lesions of tinea that were localized to vitiliginous skin but in two patients, the lesions extended beyond vitiligo borders. Four out of our five patients received immunomodulatory treatment at some point in the past (steroids, PUVA, tacrolimus) for vitiligo, and three patients were diabetic. Four patients were elderly, and only one patient was 30 years old. Four patients had long-standing vitiligo, whereas only one patient had vitiligo for the last 8 months. All patients had no Koebner phenomenon. Fungal elements were demonstrated in KOH mount from all cases [Figure 5]. *T. mentagrophytes* was isolated from three patients, and *T. rubrum* was isolated from two patients. All the patients responded to a combination of oral and topical antifungals, and the lesions of dermatophytoses resolved completely after treatment.

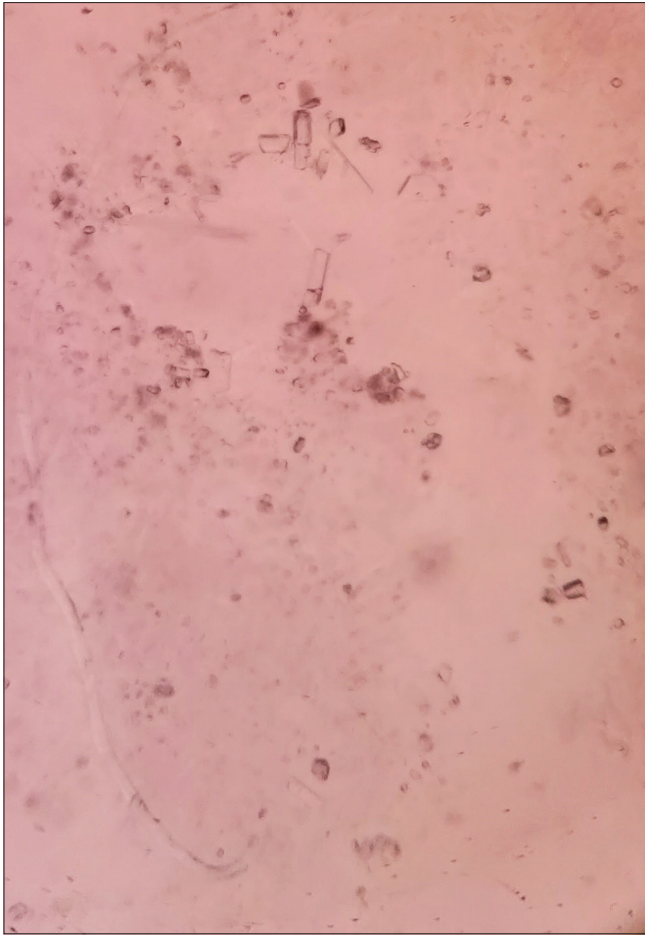


Figure 5: Fungal elements in KOH mount of skin scrapings (40 ×)

Conclusion

The present data shows that in all the cases, there are some factors that contribute to the occurrence of tinea over vitiligo patches such as advanced age, diabetes mellitus, immunomodulatory treatment, apart from local immunosuppression in vitiligo patches inherent to the disease process. The dermatophytoses were also well responsive to antifungal treatment.

There should be judicious use of immunomodulators in vitiligo patients, and one needs to be more vigilant about dermatophytoses in vitiligo patients.

Our case series is unique as there are very few reports of tinea corporis occurring on vitiliginous skin, and the condition is more under-recognized than rare.

Declaration of patient consent

The authors certify that they have obtained all appropriate patient consent forms. In the form the patient(s) has/have given his/her/their consent for his/her/their images and other clinical information to be reported in the journal. The patients understand that their names and initials will not be published and due efforts will be made to conceal their identity, but anonymity cannot be guaranteed.

Financial support and sponsorship

Nil.

Conflicts of interest

There are no conflicts of interest.

References

1. Wolf R, Wolf D, Ruocco E, Brunetti G, Ruocco V. Wolf's isotopic response. *Clin Dermatol* 2011;29:237-40.
2. Kannangara AP, Yosipovitch G, Fleischer AB Jr. Proposed classification for Koebner, Wolf isotopic, Renbok, Koebner nonreaction, isotopic nonreaction and other related phenomena. *Dermatol Online J* 2014;20:13030/qt96s656b4. doi: 10.5070/D32011024682.
3. Wyburn-Mason R. Malignant change arising in tissues affected by herpes. *Br Med J* 1955;2:1106-9.
4. Wolf R, Brenner S, Ruocco V, Filioli FG. Isotopic response. *Int J Dermatol* 1995;34:341-8.
5. Ruocco V, Ruocco E, Ghersetich I, Bianchi B, Lotti T. Isotopic response after herpesvirus infection: An update. *J Am Acad Dermatol* 2002;46:90-4.
6. Gibney MD, Nahass GT, Leonardi CL. Cutaneous reactions following herpes zoster infections: Report of three cases and a review of the literature. *Br J Dermatol* 1996;134:504-9.
7. Hatchome N, Aiba S, Kato T, Torinuki W, Tagami H. Possible functional impairment of Langerhans' cells in vitiliginous skin. Reduced ability to elicit dinitrochlorobenzene contact sensitivity reaction and decreased stimulatory effect in the allogeneic mixed skin cell lymphocyte culture reaction. *Arch Dermatol* 1987;123:51-4.
8. Parimalam K, Dinesh D K, Thomas J. Vitiligo delimiting dermatophyte infection. *Indian J Dermatol* 2015;60:91-3.
9. Rao AG. Dermatophyte infection encircling vitiligo. *Indian Dermatol Online J* 2015;6, Suppl S1:60-3.