

# Extensive Mandibular Odontogenic Keratocysts Associated with Basal Cell Nevus Syndrome Treated with Carnoy's Solution versus Marsupialization

Irshaad Abdoola, Irene T. Munzhelele<sup>1</sup>, Muniera Ibrahim<sup>2</sup>

Department of Maxillofacial and Oral Surgery, Medunsa Oral Health Centre, Sefako Makgatho Health Sciences University, <sup>1</sup>Medunsa Oral Health Centre, Sefako Makgatho Health Sciences University, <sup>2</sup>Infinity Health Medical Center, Kimberley, South Africa

## Abstract

The inherent proliferative capacity of the cystic lining of odontogenic keratocysts and tendency to recur with enucleation led to more aggressive management being widely recommended. Larger lesions preclude the possibility of resection. A case is reported in which extensive odontogenic keratocysts involve almost the entire mandibular medulla of a patient with basal cell nevus syndrome, illustrating the importance of customising treatment to accommodate the clinical and radiographic presentation of individual cases. The clinical outcome of using Carnoy's solution versus marsupialization is radiographically demonstrated in this case. Diagnostic criteria for basal cell nevus syndrome and treatment modalities of odontogenic keratocysts are discussed.

**Keywords:** Basal cell nevus syndrome, Gorlin–Goltz, odontogenic keratocyst

## INTRODUCTION

Odontogenic keratocysts (OKCs) have been the topic of controversy with regard to nomenclature and management. The inherent proliferative capacity of the cyst lining and tendency to recur with enucleation prompted authors to highlight the aggressive nature of the lesion. When associated with basal cell nevus syndrome (BCNS), further considerations are necessary.

## CASE REPORT

A 28-year-old female presented with a 2-month history of pain and enlargement of the mandible. The patient had no known comorbidities. Clinically, the patient displayed frontal bossing, hypertelorism, and bony enlargement of the mandible. Intraorally, the mandibular bony enlargement was noted bilaterally with a soft region palpable on the right corpus suggestive of cortical bone perforation. The radiographic examination included a panoramic radiograph that revealed multiple radiolucent, well-circumscribed, cystic lesions present throughout the mandible; one lesion was associated with an impacted tooth 48 [Figure 1]. A facial posteroanterior radiograph and a computed tomography scan confirmed

calcifications of the falx cerebri and displayed a thickened outer table of the frontal sinus, whereas chest radiographs confirmed multiple bifid ribs [Figures 2 and 3]. Biopsies were performed on the right mandibular corpus, and histological examination confirmed the diagnosis of OKC. Due to the clinical presentation, BCNS was diagnosed clinically. The extensive nature of the mandibular cavitation resulted in a treatment plan that involved a combination of enucleation and marsupialization of the cystic lesions. After removal of the tooth 48, the posterior cavities of the mandibular ramus were enucleated bilaterally, followed by the application of nonmodified Carnoy's solution in three cycles of 3 min. The corpal cavities were marsupialized, with Bismuth Iodoform Paraffin Paste (BIPP) ribbon placement. The BIPP ribbon

**Address for correspondence:** Dr. Irshaad Abdoola, Suite 106, Lenmed Hospital, 6 Welgevonden St, Royldene, Kimberley 8301, South Africa.  
E-mail: maxfax@dr.com

Received : 10-05-2019

Published: 08-06-2020

Accepted : 02-10-2019

This is an open access journal, and articles are distributed under the terms of the Creative Commons Attribution-NonCommercial-ShareAlike 4.0 License, which allows others to remix, tweak, and build upon the work non-commercially, as long as appropriate credit is given and the new creations are licensed under the identical terms.

For reprints contact: WKHLRPMedknow\_reprints@wolterskluwer.com

**How to cite this article:** Abdoola I, Munzhelele IT, Ibrahim M. Extensive mandibular odontogenic keratocysts associated with basal cell nevus syndrome treated with carnoy's solution versus marsupialization. *Ann Maxillofac Surg* 2020;10:47-50.

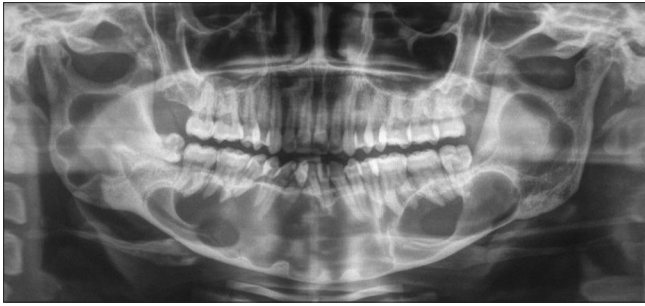### Access this article online

Quick Response Code:

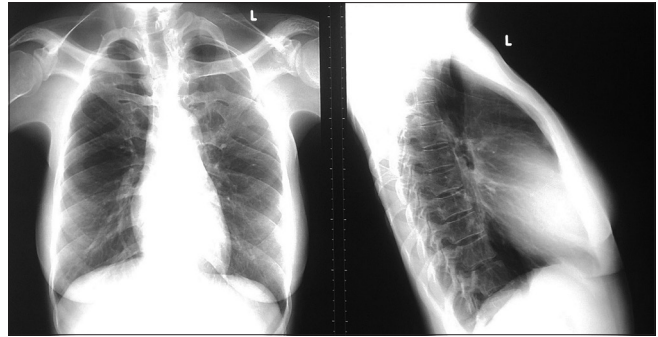


Website:  
www.amsjournal.com

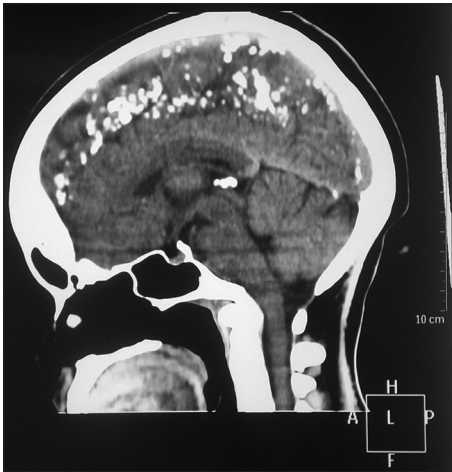DOI:  
10.4103/ams.ams\_134\_19



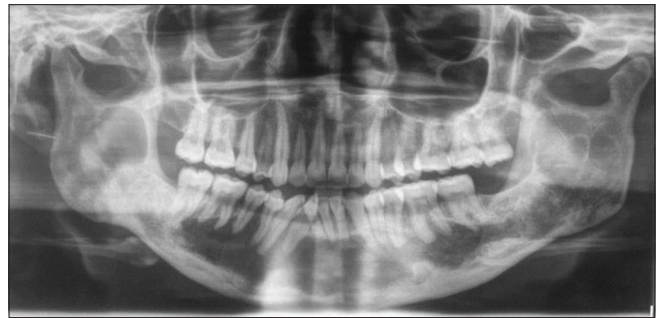**Figure 1:** Initial panoramic radiograph



**Figure 2:** Bifid ribs



**Figure 3:** Calcifications of the falx cerebri



**Figure 4:** Two years' postoperative

was subsequently gradually removed by 10 cm on either side every fortnight, followed by cystectomy. Two years postoperatively, a decrease in the size and radiolucency of the cystic cavities were noted radiographically [Figure 4]. The posterior lesions (treated by enucleation and irrigation with nonmodified Carnoy's solution) displayed greater resolution than the anterior lesions (treated by marsupialization). Recurrence involving the right mandibular ramus was noted 32 months postoperatively [Figure 5]. At the time of writing, irrigation with nonmodified Carnoy's solution and enucleation of the lesion is planned.

## DISCUSSION

Jarish was the first to report a case of BCNS in 1894; when he documented a patient with multiple basal cell carcinomas, scoliosis, and learning impairment. Gorlin and Goltz proposed a triad of multiple basal cell nevi, gnathic keratocysts, and skeletal anomalies as the defining features of the syndrome.

BCNS is an autosomal dominant disorder with high penetrance and variable expressivity, which is caused by mutations of the patched homolog tumor suppressor gene (PTCH1) on chromosome 9q22.3-q31. PTCH1 codes for a 1447 amino acid protein that interacts with the sonic hedgehog protein. The latter is involved in embryonic development of the limbs, eyes, teeth, and cerebral hemispheres.<sup>[1]</sup> The estimated prevalence of BCNS is 1 in 60,000.<sup>[1]</sup> There is a paucity of reports of BCNS

in the African literature, with no report of the incidence of BCNS on the National Cancer Registry of South Africa (2010).

BCNS is classically a clinical diagnosis, with various authors suggesting similar diagnostic criteria [Table 1]. Two major or one major and two minor presentations are required for the diagnosis.<sup>[2-4]</sup> The currently reported patient satisfied the criteria for the diagnosis of BCNS. A variety of other manifestations have been described in BCNS patients, including endocrine and genital manifestations. Although no laboratory test may be employed to test specifically for BCNS, affected patients may have elevated cyclic adenosine monophosphate levels and show impaired phosphate diuresis on parathyroid hormone challenge.<sup>[4]</sup>

Multiple OKCs usually occur as a component of BCNS but have occurred in patients with Ehlers-Danlos, Noonan, and oral-facial-digital syndromes. These may present at a younger age than OKCs encountered in nonsyndromic patients. The cysts may be asymptomatic; which may explain the often incidental and sometimes late presentation, as was seen in this patient who presented with extensive cavitation and even cortical perforation on the first radiographic examination. OKCs associated with BCNS frequently differ in clinical and histopathologic characteristics to solitary OKCs [Table 2].<sup>[4]</sup>

A variety of treatment modalities have been suggested in the literature for patients with OKCs. The potential for recurrence with enucleation has prompted a traditional inclination towards resection. The contemporary management paradigm has shifted toward surgical management intermediate between these two extremes.

**Table 1: Diagnostic criteria for basal cell nevus syndrome**

Major criteria	Minor criteria
More than 2 BCCs or 1 before 30 years of age or <10 basal cell nevi according to Evans <i>et al.</i> <sup>[2]</sup> 1 before 20 years of age according to Kimonis <i>et al.</i> <sup>[3]</sup>	Macrocephaly <sup>[3]</sup> Occipitofrontal circumference >97 <sup>th</sup> percentile, <sup>[2]</sup> with frontal bossing <sup>[2,3]</sup>
Any gnathic OKC (proven histologically) <sup>[2,3]</sup> or polyostotic bone cyst <sup>[2]</sup> 3 or more palmar or plantar pits <sup>[2,3]</sup> Lamellar calcifications of the falx cerebri <sup>[2,3]</sup> before 20 years of age <sup>[2]</sup>	Ovarian <sup>[2,3]</sup> or cardiac fibroma <sup>[2]</sup> Medulloblastoma <sup>[2,3]</sup> Congenital malformations Cleft lip and/or palate <sup>[2]</sup> Eye anomaly (cataract, coloboma, and microphthalmos) <sup>[2]</sup> Coarse facies <sup>[3]</sup> Moderate or severe hypertelorism <sup>[3]</sup> Modeling defects of the hands and feet <sup>[3]</sup> Flame-shaped lucencies of the phalanges <sup>[3]</sup> Marked syndactyly <sup>[3]</sup> Polydactyly <sup>[2]</sup>
Family history of BCNS, <sup>[2,3]</sup> involving a first degree relative <sup>[3]</sup>	Bifid, fused, splayed, or missing rib <sup>[2]</sup> Vertebral anomalies <sup>[3]</sup> Bifid <sup>[2]</sup> Wedging <sup>[2]</sup> Hemivertebrae <sup>[3]</sup> Fusion <sup>[2,3]</sup> Elongation of vertebral bodies <sup>[3]</sup> Other skeletal abnormalities <sup>[3]</sup> Sprengel deformity <sup>[3]</sup> Marked pectus deformity <sup>[3]</sup> Bridging of the sella turcica <sup>[3]</sup> Lymphomesenteric cysts <sup>[2]</sup>
Bifid, fused, hypoplastic, or markedly splayed ribs <sup>[3]</sup>	

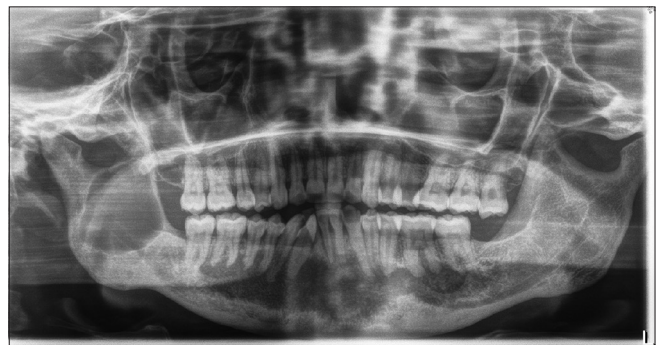OKC: Odontogenic keratocyst, BCNS: Basal cell nevus syndrome, BCCs: Basal cell carcinomas

**Table 2: Comparison of OKCs with and without BCNS association**

	Solitary	Syndromic
Number	Single	Multiple
Age	Middle aged or older	Younger
Gnathic distribution	Predilection for posterior mandible	More equal gnathic distribution
Recurrence rates	61%	82%
Epithelium	Thicker	Thinner
Frequency of odontogenic islands	Less frequent	Frequent

The recurrence rates for OKCs vary: 30%<sup>[5]</sup> following enucleation, 9%<sup>[5]</sup>–17.4%<sup>[6]</sup> following enucleation and irrigation with Carnoy’s solution, 14.5%<sup>[6]</sup>–38%<sup>[5]</sup> following enucleation and cryotherapy, 18%<sup>[5]</sup> following enucleation and peripheral ostectomy, 8%<sup>[5]</sup> following enucleation combined with Carnoy’s solution and peripheral ostectomy, 13%<sup>[5]</sup>–14.6%<sup>[6]</sup> following decompression and cystectomy, 32.3%<sup>[6]</sup>–33%<sup>[5]</sup> following marsupialization alone, and 0%<sup>[5]</sup>–8.4%<sup>[6]</sup> following resection.

Al-Moraissi *et al.* suggested enucleation and irrigation with Carnoy’s solution or cryotherapy as the first-line treatment for primary OKCs, due to low recurrence rates. When marsupialization is indicated, secondary cystectomy should follow to minimize recurrence. Resections should be considered following multiple recurrences and possibly in



**Figure 5:** Recurrence 32 months’ postoperative

syndromic cases.<sup>[6]</sup> The reported patient required aggressive management, as the lesions were associated with BCNS and more prone to recurrence; yet required more conservative management, as the involvement of the entire mandible rendered resection a less favorable option. The individualized management was, therefore, modified to suit the lesions in a specific patient. In the posterior mandible, enucleation followed by irrigation with nonmodified Carnoy’s Solution was used, as the cysts could contain the solution. In the anterior mandible, marsupialization followed by secondary cystectomy was performed, as it was the least aggressive option.

Suggested causes of recurrence include the tendency to multiplicity,<sup>[7]</sup> the fragility of the lining precluding complete

removal in many cases,<sup>[7]</sup> multi-fragmented enucleation,<sup>[7]</sup> intrinsic growth potential of the epithelium,<sup>[7]</sup> incomplete removal of the overlying mucosa,<sup>[7]</sup> retention of daughter cysts,<sup>[7]</sup> and inability to completely remove cystic remnants from around the roots of teeth. OKCs have a higher recurrence potential in BCNS and arise at an earlier age. The cysts are generally parakeratinized and occasionally may transform into aggressive neoplasms, such as ameloblastomas and squamous cell carcinomas.<sup>[7]</sup>

Carnoy's solution is a mixture of 6 ml of absolute ethanol, 3 ml of chloroform, 1 ml of glacial acetic acid, and 1 g of ferric chloride. Originally used as a fixative in the 19<sup>th</sup> century, it is now used as a complementary treatment following the conservative excision of OKCs. Drugs containing chloroform were removed from the U.S. market, and new drug applications are required for approval. Modified Carnoy's solution (containing no chloroform) is currently used as an alternative in some institutions; however, its use has shown greater recurrence rates than the use of conventional Carnoy's solution.<sup>[8]</sup> The solution induces superficial chemical necrosis, destroying epithelial or microcystic remnants, and reducing recurrence rates.<sup>[6]</sup> Contact with nonpathologic soft tissues should be avoided. Gauze soaked in Carnoy's solution may be used to limit excessive soft-tissue contact.

Although Carnoy's solution induces superficial necrosis, safe application over the inferior alveolar neurovascular plexus has been reported.<sup>[9]</sup> Initial animal studies showed no axonal damage following 3 min of direct neural application.<sup>[10]</sup> Human studies confirmed only transient neural deficits following application in the area of an exposed inferior alveolar nerve for 3 min.<sup>[9]</sup>

## CONCLUSION

There are many treatment options available to manage OKCs. The treatment modality should be based on consideration of the extent of the lesion/s and history of recurrence in a specific patient. Lower recurrence rates are expected with more aggressive surgical intervention, but such intervention is neither always necessary nor feasible. The use of more conservative treatment modalities was used in this case, as the lesions involved almost the entire mandible. The 2 year follow-up revealed a better response in those cysts that were treated by enucleation and irrigation with conventional Carnoy's solution, as opposed to those cysts that were treated by marsupialization only.

## Declaration of patient consent

The authors certify that they have obtained all appropriate

patient consent forms. In the form the patient(s) has/have given his/her/their consent for his/her/their images and other clinical information to be reported in the journal. The patients understand that their names and initials will not be published and due efforts will be made to conceal their identity, but anonymity cannot be guaranteed.

## Acknowledgments

Many thanks to Professor Sonja Boy for her advice and guidance; as well as the consultants of the Department of Maxillofacial and Oral Surgery, Medunsa Oral Health Centre, SMU: Professor M.M.R. Bouckaert, Dr. J. Mchenga, Dr. M. Tlholoe, and Dr. A. Dreyer. I would also like to acknowledge the registrars and dental officers of the same department, Dr. C. van Niekerk (previous registrar), Dr. R.S. Ciya, Dr. I.T. Dikgale, Dr. B.R. Legalamitloa, Dr. K.G. Leballo, and Dr. S. Pema.

## Financial support and sponsorship

Nil.

## Conflicts of interest

There are no conflicts of interest.

## REFERENCES

1. Heussler HS, Suri M. Sonic hedgehog. *Mol Pathol* 2003;56:129-31.
2. Evans DG, Ladusans EJ, Rimmer S, Burnell LD, Thakker N, Farndon PA. Complications of the naevoid basal cell carcinoma syndrome: Results of a population based study. *J Med Genet* 1993;30:460-4.
3. Kimonis VE, Goldstein AM, Pastakia B, Yang ML, Kase R, DiGiovanna JJ, *et al.* Clinical manifestations in 105 persons with nevoid basal cell carcinoma syndrome. *Am J Med Genet* 1997;69:299-308.
4. Auluck A, Suhas S, Pai KM. Multiple odontogenic keratocysts: Report of a case. *J Can Dent Assoc* 2006;72:651-6.
5. Madras J, Lapointe H. Keratocystic odontogenic tumour: Reclassification of the odontogenic keratocyst from cyst to tumour. *J Can Dent Assoc* 2008;74:165.
6. Al-Moraissi EA, Dahan AA, Alwadeai MS, Oginni FO, Al-Jamali JM, Alkhatari AS, *et al.* What surgical treatment has the lowest recurrence rate following the management of keratocystic odontogenic tumor?: A large systematic review and meta-analysis. *J Craniomaxillofac Surg* 2017;45:131-44.
7. Tarakji B, Baroudi K, Hanounh S, Azzeghaiby SN, Nassani MZ. Possible recurrence of keratocyst in nevoid basal cell carcinoma syndrome: A review of literature. *Eur J Dent* 2013;7:S126-S134.
8. Dashow JE, McHugh JB, Braun TM, Edwards SP, Helman JI, Ward BB. Significantly decreased recurrence rates in keratocystic odontogenic tumor with simple enucleation and curettage using Carnoy's versus modified Carnoy's solution. *J Oral Maxillofac Surg* 2015;73:2132-5.
9. Júnior OR, Borba AM, Alves CA, Júnior JG. Carnoy's solution over the inferior alveolar nerve as a complementary treatment for keratocystic odontogenic tumors. *Rev Clin Pesq Odontol* 2007;3:199-202.
10. Frerich B, Cornelius CP, Wiethölter H. Critical time of exposure of the rabbit inferior alveolar nerve to Carnoy's solution. *J Oral Maxillofac Surg* 1994;52:599-606.