

Oddities

Urethral diverticulum with urethrocutaneous fistula and giant stone: A case report

Imam Ciptadi Putra^{a,*}, Hendy Mirza^b^a Department of Urology, Faculty of Medicine Universitas Indonesia, Jl. Diponegoro No. 71, Salemba, Jakarta Pusat, DKI Jakarta, 10430, Jakarta, Indonesia^b Persahabatan General Hospital, Jakarta, Indonesia, Jl. Persahabatan Raya No. 1, Pulogadung, Jakarta Timur, DKI Jakarta, 13230, Jakarta, Indonesia

ARTICLE INFO

Keywords:

Urethral diverticulum
Giant stone
Scrotal fistula

ABSTRACT

Male urethral diverticulum is rare and usually associated with urethral obstruction. We report a 62-year-old male presented to emergency room with giant stone coming from scrotum without urinary retention. From clinical findings, a giant stone obviously burst out from his scrotal fistula. Pelvic computed tomography confirmed urethral diverticulum containing a giant stone with multiple smaller stones. Cystourethroscopy was performed to assess diverticulum and luminal obstruction, and no obstruction was found. We performed stones extirpation, diverticulectomy, and urethroplasty consecutively. Intraoperative findings confirmed preoperative detection. Complete stone-free rate and diverticulum removal were successfully accomplished. The patient was discharged postoperatively at day 7.

Introduction

Urethral diverticulum (UD) is a saccular dilation extended from and communicates with urethral lumen. UD in male is a rare finding, often misdiagnosed and undertreated.¹ UD can be either congenital or acquired.² While two-thirds to 90% of UD cases are acquired, a small proportion of UD cases is congenital.¹ Here, we present a case of a male with neglected UD with giant stones and urethrocutaneous fistula.

Case presentation

In this case report, we present a 62-year-old male came to acute and emergency due to scrotal abscess and stones coming out from his scrotal wound 3 hours before hospital admission. The patient complained about dysuria, frequency, and recurrent urinary tract infection (UTI) since a couple years ago. He also reported occasional passages of small stones during micturition. There was no history of hematuria. He felt a small-palpable marble-size lump in his right-side scrotum since 6 months ago. In 3 months, his urination symptoms worsened and the size of the lump within his scrotum increased to a handgrip of an adult. 2 weeks later, he noticed a 2 cm-length wound in his scrotal skin one month ago. The stone was visible from the wound, surrounded by pus and strong foul odor (Fig. 1).

We performed CT urography and urethroscopy to establish a diagnosis. From urethroscopy, interestingly, we found no urethral stricture

or other obstructions within the urethra. UD was identified in the anterior part of bulbous urethra. Due to the size of the giant stone and multiple smaller stones, we decided to perform open diverticulectomy and stone extraction, followed by urethroplasty. We incised the scrotal skin and widened the incision to extract the stone. An oval-shaped stone size 8 cm × 6 cm was successfully extracted. Multiple smaller stones were also evacuated consecutively. After ensuring all of the stones were removed, we continued with diverticulectomy and urethroplasty. We further performed stone analyses and infected stones properties were revealed. Stone composition revealed magnesium, ammonium and phosphate component predominantly, in accordance with infection stone. On 6 months follow up, wound healing went well and he was able to urinate spontaneously (Fig. 2).

Discussion

The prevalence of UD on both male and female is ranging from 0.5 to 5% and it is more commonly found in female.¹ According to its origin, UD is classified into two groups: congenital versus acquired.³ In male, acquired UD is associated with stricture in urethral lumen, untreated chronic infection, prolonged use of an indwelling catheter, or trauma.² UD is usually asymptomatic for years unless complications occur.^{3,4} Both congenital and acquired UD have similar signs and symptoms including obstructive lower urinary tract symptoms (LUTS), recurrent UTIs, and terminal dribbling.³ From the location, congenital

* Corresponding author.

E-mail addresses: imamciptadi@gmail.com (I.C. Putra), hendy2807@gmail.com (H. Mirza).<https://doi.org/10.1016/j.eucr.2019.100862>

Received 22 February 2019; Accepted 5 March 2019

Available online 08 March 2019

2214-4420/ © 2019 The Authors. Published by Elsevier Inc. This is an open access article under the CC BY-NC-ND license

(<http://creativecommons.org/licenses/by-nc-nd/4.0/>).

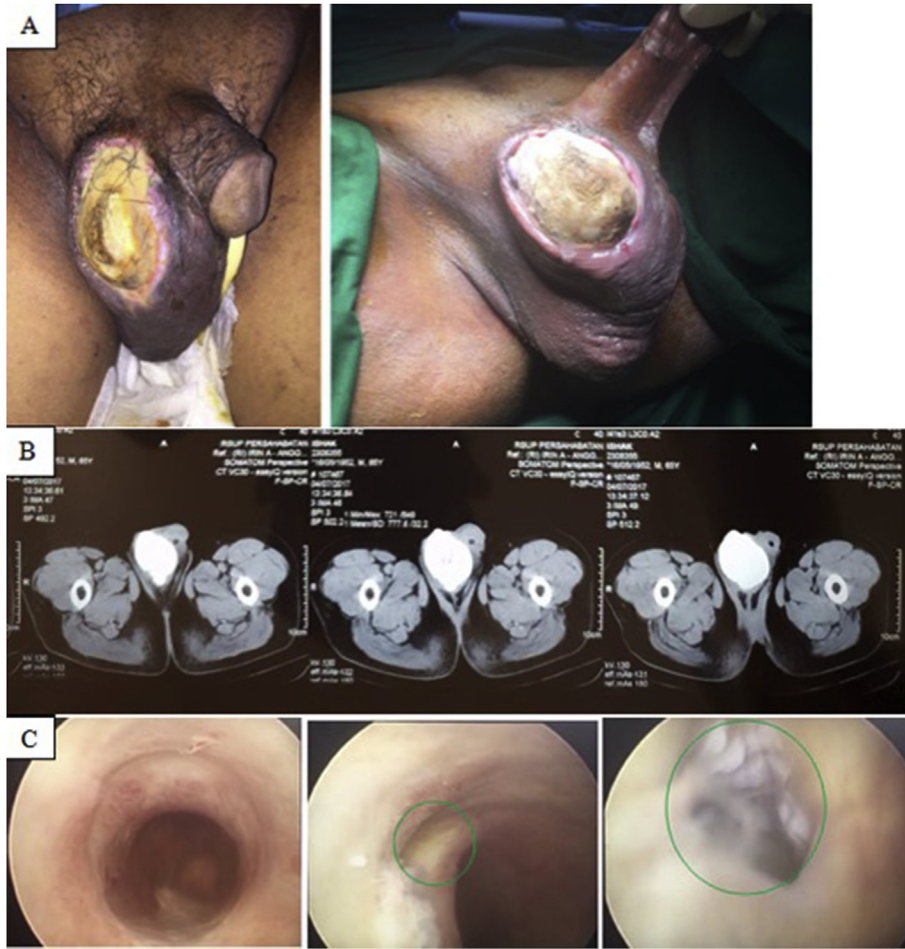


Fig. 1. (A) Clinical finding when the patient came to ER; (B) CT scan; and (C) Urethroscopy revealed diverticulum pouch.

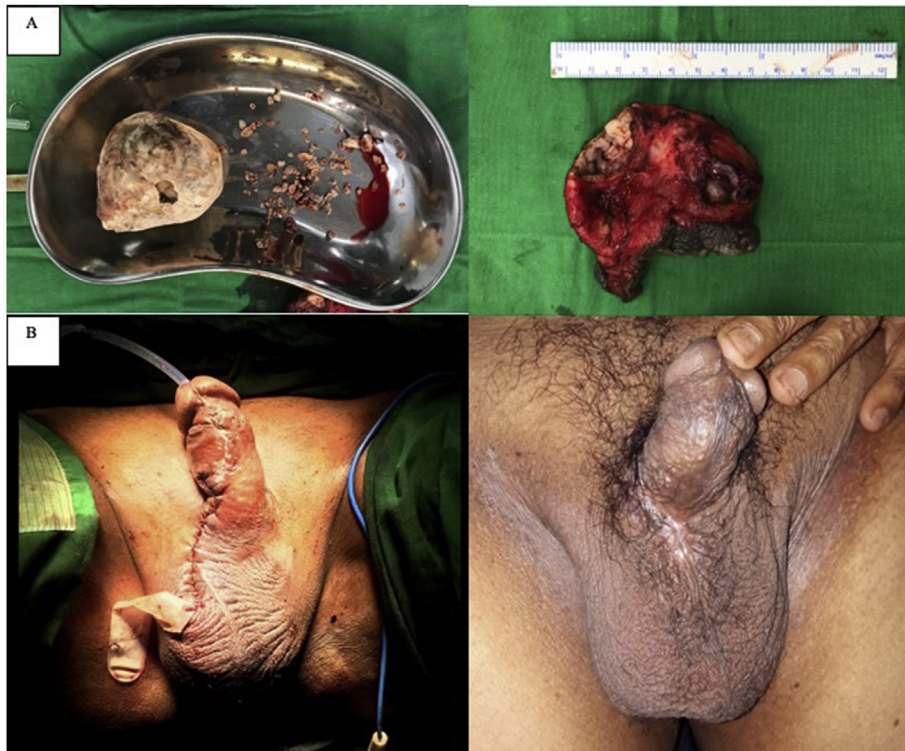

Fig. 2. (A) Intraoperative findings: stones and diverticulum pouch; (B) Postoperative.

UD is majorly found at the level of anterior part of the urethra, and predominantly on the ventral side.⁵ Congenital UD is thought to be related by a defect of development of ectodermal closing of urethral groove.⁵

In our case, it is difficult to define the initial phase, either the stones lead to diverticulum or the obstruction cause diverticulum pouch and stone formation. It is still debatable regarding which phase takes place in the first place regarding the formation of an diverticulum, between obstruction, infection, and stone formation in our case. From histopathological finding, chronic urethritis was found as the main underlying etiology. However, stones can cause similar histopathological appearance that usually can also be found in chronic infection.⁵

Because of UD is not commonly found in male, the established guideline for the management of UD in male is still not available.⁴ Therefore, management of UD in male is individually tailor-made by treating urologist. Treatment of congenital or acquired UD is basically comparable: to excise the diverticulum, and perform primary anastomosis or urethroplasty for residual urethral defects.³ Treatment for UD can be either primary anastomosis or substitution urethroplasty.⁴ Kim et al. reported similar outcomes between primary anastomosis for defect < 4 cm and substitution urethroplasty for defect > 4 cm.⁵ More interestingly, this study concludes that the remaining urethral defect after excision, not the size of diverticulum itself, can be a guidance to decide the appropriate approach for UD management.⁵

A few studies had been published with similar cases. A study by Ho et al. demonstrated 71-year-old man with multiple stones inside penoscrotal diverticulum.² There was no sign of infection and open diverticulectomy was performed. Similarly, we decided to perform open diverticulectomy and urethroplasty respectively. The wound healing, we observed in this patient was significant on 6-month follow up. In addition to that, he is able to urinate spontaneously.

Conclusion

To conclude, UD in male is a rare case. There is no established guideline for UD. We reported UD with giant stone without any obstruction in the urethral lumen. The management of UD should be personalized and tailor-made in an individual setting. For UD with a giant stone, open diverticulectomy and stone extirpation can be the treatment of choice to achieve complete both diverticulum excision and stone removal.

Consent

The patient has already given his consent to be reported and published as a case report.

Conflict of interest

There is no conflict of interest, neither financial or nonfinancial, in the whole process from making to publishing this study.

References

1. Thakur N, Sabale V, Mane D, Mulla A. Male urethral diverticulum uncommon entity: our experience. *Urol Ann.* 2016;8(4):478.
2. Allen D, Mishra V, Pepper W, Shah S, Motiwala H. A single-center experience of symptomatic male urethral diverticula. *Urology.* 2007;70(4):650–653.
3. Gadimaliyev E. Urethral diverticulum calculi in a male: a case report. *Case Rep Urol.* 2013;437106.
4. Cinman NM, McAninch JW, Glass AS, Zaid UB, Breyer BN. Acquired male urethral diverticula: presentation, diagnosis and management. *J Urol.* 2012;188(4):1204–1208.
5. Alphs HH, Meeks JJ, Casey JT, Gonzalez CM. Surgical reconstruction of the male urethral diverticulum. *Urology.* 2010;76(2):471–475.