

UPDATE**Diagnostic challenges in chronic inflammatory demyelinating polyradiculoneuropathy****Filip Eftimov,¹  Ilse M. Lucke,¹  Luis A. Querol,^{2,3} Yusuf A. Rajabally⁴ and Camiel Verhamme¹**

Chronic inflammatory demyelinating polyradiculoneuropathy (CIDP) consists of a spectrum of autoimmune diseases of the peripheral nerves, causing weakness and sensory symptoms. Diagnosis often is challenging, because of the heterogeneous presentation and both mis- and underdiagnosis are common. Nerve conduction study (NCS) abnormalities suggestive of demyelination are mandatory to fulfil the diagnostic criteria. On the one hand, performance and interpretation of NCS can be difficult and none of these demyelinating findings are specific for CIDP. On the other hand, not all patients will be detected despite the relatively high sensitivity of NCS abnormalities. The electrodiagnostic criteria can be supplemented with additional diagnostic tests such as CSF examination, MRI, nerve biopsy, and somatosensory evoked potentials. However, the evidence for each of these additional diagnostic tests is limited. Studies are often small without the use of a clinically relevant control group. None of the findings are specific for CIDP, meaning that the results of the diagnostic tests should be carefully interpreted. In this update we will discuss the pitfalls in diagnosing CIDP and the value of newly introduced diagnostic tests such as nerve ultrasound and testing for autoantibodies, which are not yet part of the guidelines.

- 1 Department of Neurology and Clinical Neurophysiology, Amsterdam Neuroscience, Amsterdam University Medical Centers, University of Amsterdam, Amsterdam, The Netherlands
- 2 Department of Neurology, Hospital de la Santa Creu i Sant Pau, Barcelona, Spain
- 3 Centro para la Investigación en Red en Enfermedades Raras (CIBERER), Madrid, Spain
- 4 Aston Medical School, Aston University, Birmingham, UK

Correspondence to: Camiel Verhamme, MD, PhD
Department of Neurology and Clinical Neurophysiology
Amsterdam UMC – location AMC
Meibergdreef 9
1105 AZ Amsterdam
The Netherlands
E-mail: c.verhamme@amsterdamumc.nl

Keywords: CIDP; diagnostic pitfalls; diagnostic accuracy; misdiagnosis; underdiagnosis

Abbreviations: CIDP = chronic inflammatory demyelinating polyradiculoneuropathy; CMAP = compound muscle action potential; EFNS/PNS = European Federation of Neurological Societies/Peripheral Nerve Society; NCS = nerve conduction studies; SSEP = somatosensory evoked potential

Introduction

Chronic inflammatory demyelinating polyradiculoneuropathies (CIDPs) consists of a spectrum of immune-mediated

neuropathies, causing weakness and sensory symptoms in a progressive, relapsing-remitting or monophasic fashion (Van den Bergh *et al.*, 2010). Early diagnosis is important, as induction of treatment can prevent axonal damage and

Received April 8, 2020. Revised June 7, 2020. Accepted June 17, 2020. Advance access publication November 6, 2020

© The Author(s) (2020). Published by Oxford University Press on behalf of the Guarantors of Brain.

This is an Open Access article distributed under the terms of the Creative Commons Attribution Non-Commercial License (<http://creativecommons.org/licenses/by-nc/4.0/>), which permits non-commercial re-use, distribution, and reproduction in any medium, provided the original work is properly cited. For commercial re-use, please contact journals.permissions@oup.com

permanent disability (Bouchard *et al.*, 1999; Eftimov *et al.*, 2013; Mehndiratta *et al.*, 2015; Hughes *et al.*, 2017). Diagnosis is often challenging, because of the heterogeneous presentation. Clinical presentation and nerve conduction studies (NCS) play a major role in diagnosing CIDP, supplemented with diagnostic tests such as CSF examination, MRI, nerve biopsy and somatosensory evoked potentials (SSEP) (Van den Bergh *et al.*, 2010). Recently, nerve ultrasound and testing for autoantibodies were introduced (Goedee *et al.*, 2017b; Vural *et al.*, 2018). Despite diagnostic guidelines, in clinical practice both mis- and underdiagnosis are common. Misdiagnosis is a major problem, leading to the inappropriate use of expensive and potentially harmful treatment; underdiagnosis means that patients may not get effective treatment (Boukhris *et al.*, 2004; Ayrignac *et al.*, 2013; Allen and Lewis, 2015; Lucke *et al.*, 2019a). In this update we will discuss the frequent pitfalls in diagnosing CIDP and the value of newly introduced diagnostic tests such as nerve ultrasound and testing for autoantibodies.

Clinical signs and symptoms

Typical CIDP is defined as proximal and distal weakness and sensory dysfunction of all extremities, with absent or reduced tendon reflexes in all four limbs, with a progressive, relapsing-remitting or monophasic course, typically progressing over months. Atypical CIDP may be divided, based on clinical presentation, in the asymmetric, focal, distal, pure motor and pure sensory variants (Van den Bergh *et al.*, 2010). Misdiagnosis is common and is reported in up to 50% of patients referred with a CIDP diagnosis, mainly in patients with an atypical presentation (Allen and Lewis, 2015). In patients with a typical presentation of proximal and distal weakness, diagnosing CIDP is often straightforward. It was even suggested to base diagnosis on a typical presentation without further investigations (Koski *et al.*, 2009). However, none of the typical findings are specific for CIDP.

Diagnostic criteria sets

Consensus on the diagnostic criteria for CIDP has proven difficult, which led to many different sets throughout the years. One North American study (Breiner and Brannagan, 2014) compared 15 diagnostic criteria sets, including the revised European Federation of Neurological Societies/Peripheral Nerve Society (PNS/PNS) criteria (Van den Bergh *et al.*, 2010), the van den Bergh and Piéret criteria (2004), the American Academy of Neurology (AAN) criteria (American Academy of Neurology, 1991) and the Koski criteria (Koski *et al.*, 2009) in 57 CIDP patients and 37 patients with diabetic neuropathy and 39 patients with amyotrophic lateral sclerosis as control subjects (Table 1). The EFNS/PNS criteria had the highest sensitivities, with good specificities. Another European study (Rajabally *et al.*, 2009) investigated the specific electrodiagnostic criteria, including the 2006 EFNS/PNS criteria (Hughes *et al.*, 2006),

Table 1 Sensitivities and specificities of different diagnostic criteria sets

Criteria	Sensitivity	Specificity
EFNS/PNS, 2010		
Definite	73% (59.7–84.2%)	88% (78.7–94.4%)
Probable	77% (63.6–87.0%)	84% (74.0–91.6%)
Possible	91% (80.4–97.0%)	65% (54.0–76.3%)
Van den Bergh and Piéret		
Definite	63% (48.5–75.1%)	86% (77.1–93.5%)
Probable	66% (52.2–78.2%)	78% (68.1–87.5%)
AAN		
Definite	4% (0.4–12.3%)	100% (95.3–100%)
Probable	13% (5.2–24.1%)	100% (95.3–100%)
Possible	25% (14.4–38.4%)	100% (95.3–100%)
Koski	50% (36.3–63.7%)	84% (74.0–91.6%)

AAN = American Academy of Neurology; EFNS/PNS = European Federation of Neurological Societies/Peripheral Nerve Society. Adapted from Breiner and Brannagan (2014).

the van den Bergh and Piéret criteria (2004), the AAN criteria (American Academy of Neurology, 1991) and the Koski criteria (Koski *et al.*, 2009) in 151 CIDP patients and 162 patients with axonal neuropathies as control subjects. The EFNS/PNS electrodiagnostic criteria had the highest sensitivity of 81% for definite or probable CIDP, with specificities ranging from 79% to 96%, depending on the extent of the NCS. The specificity of the criteria sets are likely overestimated, as all studies used control patients with clear clinical phenotypes of axonal neuropathies or motor neuron diseases instead of the ideal control population with initially suspected CIDP with alternative diagnosis. As the EFNS/PNS 2010 criteria seem the most accurate and widely used set of criteria, this review will further mainly focus on this set (Rajabally *et al.*, 2014). All diagnostic tests have their pitfalls and should be interpreted in the clinical context, including considering alternative causes of a demyelinating neuropathy (Table 2).

Diagnostic tests

Nerve conduction studies

The diagnosis of CIDP relies heavily on identification of demyelinating features on motor NCS. The electrophysiological demyelinating features are not equivalent to classical demyelination as found in nerve biopsy, but rather are markers for functional disruption or slowing of the saltatory conduction of the myelinated axons. Based on the amount and certainty of demyelinating features, this will lead to a definite, probable or possible electrodiagnosis according to the EFNS/PNS 2010 criteria (Van den Bergh *et al.*, 2010). A definite electrodiagnostic diagnosis requires at least two demyelinating features in two different nerves. A probable diagnosis requires two probable blocks or a probable block and one other demyelinating feature in a different nerve, while a possible diagnosis requires one demyelinating feature in one nerve. Recent studies highlighted the importance of

Table 2 Diagnostic pitfalls

Diagnostic test		Pitfall
Nerve conduction studies	Misdiagnosis	Other diseases that can meet electrodiagnostic criteria MMN Hereditary neuropathies with demyelinating features - CMT (demyelinating and intermediate types) HNLPP IgM monoclonal gammopathy associated with anti-MAG antibodies POEMS syndrome Amyloidosis Vasculitic neuropathy Lumbosacral radiculoplexus neuropathy Neurolymphomatosis Misinterpretation Increased distal latencies and slowed velocities due to severe axonal loss (low CMAP amplitudes), especially for the fibular nerve Demyelinating signs over segments prone to compression [median nerve (carpal tunnel), ulnar nerve (elbow), fibular nerve (fibular head)] interpreting CMAP reduction (abductor digiti minimi muscle) in forearm as a conduction block, without excluding Martin-Gruber anastomosis Uncertainties in determination of motor conduction block in segment axilla to Erb's point Absence of F-waves Distal CMAP duration prolongation with improper cut-off values Non-stringent interpretation of proximal CMAP amplitude reductions and temporal dispersion in the legs, especially for the tibial nerve
	Underdiagnosis	Testing too few (proximal arm) nerve segments Proximal leg nerves, including lumbosacral plexus, and partly brachial plexus are not accessible Criteria mainly based on motor nerves
Lumbar puncture	Misdiagnosis	Elevated CSF protein also found in diabetes mellitus and CMT CSF protein can increase with age
Imaging	Underdiagnosis	Normal CSF protein in atypical CIDP variants
	Misdiagnosis	Enlarged nerves also found in diseases such as vasculitis, diabetes mellitus, amyotrophic neuralgia, demyelinating and intermediate CMT Cut-off values for enlargement need critical attention High inter- and intra-observer variability of qualitative MRI assessment
Evoked potentials	Underdiagnosis	Sensitivity of MRI is unknown High inter- and intra-observer variability of qualitative MRI assessment
	Misdiagnosis	Prolonged SSEP not specific for CIDP
Nerve biopsy	Underdiagnosis	Sensitivity of SSEPs is unknown
	Misdiagnosis	Biopsy findings do not differentiate between CIDP and differential diagnoses such as axonal neuropathies or vasculitis
Autoantibodies	Underdiagnosis	Demyelination is often not seen in biopsy
	Misdiagnosis	Autoantibodies are regarded as specific; however, better standardization of techniques and estimates of the diagnostic accuracy are warranted
	Underdiagnosis	Sensitivity is currently low

CMT = Charcot-Marie-Tooth disease; HNLPP = hereditary neuropathy with liability to pressure palsy; MMN = multifocal motor neuropathy; POEMS = polyneuropathy, organomegaly, endocrinopathy, monoclonal protein, skin changes.

correct interpretation of NCS and electrodiagnostic criteria, as this often led to misdiagnosis (Allen and Lewis, 2015; Allen *et al.*, 2018). A pitfall is that the electrophysiological criteria are sensitive to diagnose a demyelinating neuropathy, but they are also fulfilled in other diseases (Table 2).

Another frequent pitfall is severe axonal loss that can have a profound influence on nerve conduction velocity if the largest, fastest conducting axons are involved. For this reason, several criteria have additional fulfilments for the compound muscle action potential (CMAP) amplitude (Van den Bergh *et al.*, 2010). In general, demyelinating features should be identified with caution in measurements with CMAP

amplitudes <1 mV, with particular focus on the clinical context (Van Asseldonk *et al.*, 2005). Recordings of more proximal muscles, such as the flexor carpi radial muscle to test the median nerve, can sometimes be of added value in case of profound distal axonal loss.

Demyelinating features in segments prone to compression or entrapment should not be considered as supportive for CIDP. The most important reason is that compression or entrapment itself can give demyelinating features. More severe demyelination was not observed at entrapment sites as compared with that observed at other nerve segments in CIDP (Padua *et al.*, 2004; Rajabally and Narasimhan, 2011b).

Interpretation of CMAP amplitude reductions as conduction blocks should be done with care in trajectories of nerves that are adjacent to each other, as co-stimulation and co-registration may occur. Moreover, physiological anastomoses, such as the Martin-Gruber anastomosis, have to be considered. These reasons should be ruled out prior to concluding that (apparent) CMAP reductions are due to conduction blocks, especially in the lower arm segment of the median or the ulnar nerve.

Both severely lengthened minimal F-wave latencies and absent F-waves may be classified as demyelinating features, but these findings are not specific, especially in case of the fibular nerve (Puksa *et al.*, 2003; Argyriou *et al.*, 2006; Pastore-Olmedo *et al.*, 2009). However, F-wave analysis may be of diagnostic utility when more distal NCS are found normal in presence of clinical features suggestive of the diagnosis (Rajabally and Varanasi, 2013).

The distal CMAP duration criterion in the guideline has been debated as it does not take differences in filter settings between centres into account (Iose *et al.*, 2009), which can greatly influence the duration (Rajabally *et al.*, 2012; Mitsuma *et al.*, 2015). However, when cut-off values are adjusted based on the filter settings used in the individual centre, it is a useful criterion that can aid diagnosis with limited testing.

Sensory NCS are not included in the electrodiagnostic criteria but can support sensory involvement and may be of value as one of the supportive criteria in the ENFS/PNS guidelines. Currently, a normal sural with abnormal median (excluding median neuropathy at the wrist from carpal tunnel syndrome) or radial sensory nerve action potential (SNAP) and/or a conduction velocity of <80% of lower limit of normal (<70% if SNAP amplitude <80% of lower limit of normal) are included as supportive criteria (Van den Bergh *et al.*, 2010). Additional review of the literature does not justify a more prominent position for sensory NCS in the guidelines and suggests that the evidence for the currently included supportive criteria, is limited with particularly low sensitivity levels (Kimura *et al.*, 1986; Kincaid *et al.*, 1988; Tamura *et al.*, 2005; Rajabally and Narasimhan, 2007; Bragg and Benatar, 2008; Rajabally and Samarasekera, 2010). Patients with clinically pure sensory involvement often also have motor abnormalities at NCS that can lead to the diagnosis of CIDP. However, an uncertain proportion of these patients with pure sensory involvement do not fulfil the electrophysiological criteria for at least possible CIDP, as these are based on motor NCS (Van den Bergh *et al.*, 2010). Some studies have proposed alternative diagnostic criteria for this specific CIDP phenotype (Ayrygnac *et al.*, 2013).

In clinical practice the order and extensiveness of NCS vary widely. If too few nerve segments are tested, this may lead to underdiagnosis. The guideline advises to first test the median and ulnar nerve at one forearm and the fibular and tibial nerve of one lower leg (Van den Bergh *et al.*, 2010). However, in case of CIDP suspicion, there are arguments to initiate the study with the median and the ulnar nerves up to

Erb's point, including F-waves, as demyelinating features may more often be found in the arms, including the more proximal (above) elbow to axilla and axilla to Erb's point segments, than in the legs (Rajabally *et al.*, 2005; Rajabally and Narasimhan, 2011a; Lucke *et al.*, 2019b). CMAP amplitudes of distal leg muscles are often too low for proper interpretation, while the proximal parts of the leg nerves are not accessible for NCS. Moreover, proximal CMAP amplitude reductions and temporal dispersion in the legs should be interpreted more stringently, taking into account physiological phenomena, especially in the tibial nerve. One study demonstrated that conduction blocks at the axilla and Erb's point were highly specific for CIDP and that proximal investigations improved the sensitivity of the diagnostic criteria (Rajabally and Jacob, 2006). This study defined a block at Erb's point as an amplitude reduction of >50% between wrist and Erb's point (Rajabally and Jacob, 2006). However, determining a block at Erb's point may be challenging, with a higher risk of submaximal stimulation at Erb's point due to the depth of the nerves, and no more proximal sites to verify CMAP amplitude reduction. Optimal stimulation at Erb's point is especially of importance, as CMAP amplitude reductions in normal control subjects may be substantial over longer arm nerve trajectories due to physiological temporal dispersion (Johnsen *et al.*, 2006).

CSF examination

Elevated protein in the CSF with normal leucocytes is found in up to 90% of patients with typical CIDP and is thought to be one of the hallmark features of the disease (Dyck *et al.*, 1975; Prineas and McLeod, 1976; McCombe *et al.*, 1987). In atypical CIDP variants such as the asymmetric subtype, protein elevation might be less pronounced, or absent (Rajabally and Chavada, 2009). Elevation of the CSF protein is not specific for CIDP and especially patients with diabetes mellitus or hereditary demyelinating neuropathies (CMT1) can have slightly elevated protein levels (Bouche *et al.*, 1983; Kobessho *et al.*, 2008). To prevent misdiagnosis, it was recently suggested to increase the cut-off value for CSF protein to 0.6 g/l in patients older than 50 (Breiner *et al.*, 2019). If an elevated leucocyte count (>10/mm³) is found, infections or malignancies should be considered. However, slightly elevated leucocyte counts (>10 mm³) have been reported in up to 11% of CIDP patients (van Doorn *et al.*, 1991; Press *et al.*, 2003; Lucke *et al.*, 2018), meaning that this does not automatically exclude the diagnosis. One study found that 8 of 14 (57%) patients with elevated leucocytes (>10 mm³) had a (sub)acute onset of disease and that leucocytes spontaneously decreased over time (Lucke *et al.*, 2018).

Imaging

MRI and nerve ultrasound can be a valuable addition in the diagnostic work-up, as proximal segments such as the proximal part of the brachial plexus and the lumbosacral plexus

can be assessed, while NCS cannot study these regions. In both techniques, one of the main parameters is nerve hypertrophy. It is noteworthy that this is not an exclusive phenomenon for acquired inflammatory neuropathies such as CIDP and may be seen in other relatively prevalent diseases such as diabetes mellitus, hereditary demyelinating neuropathies and neuralgic amyotrophy (Breiner *et al.*, 2017; Padua *et al.*, 2018; van Rosmalen *et al.*, 2019).

Multiple studies were carried out to evaluate MRI in CIDP with widely varying results: nerve hypertrophy was found in 37–100% of cases (Tazawa *et al.*, 2008; Sinclair *et al.*, 2011; Lozeron *et al.*, 2016; Goedee *et al.*, 2017a; Jongbloed *et al.*, 2017), hyperintensity ranged from 56–100% (Adachi *et al.*, 2011; Sinclair *et al.*, 2011; Shibuya *et al.*, 2015; Goedee *et al.*, 2017a; Jongbloed *et al.*, 2017) and enhancement after gadolinium administration was reported in 0–69% (Midroni *et al.*, 1999; Adachi *et al.*, 2011; Goedee *et al.*, 2017a). Most cohorts had small sample sizes and consisted of prevalent cases with a typical presentation, who met the electrophysiological criteria for definite CIDP. Only few studies included a clinically relevant control group, leading to less generalizable results for the daily practice where distinguishing CIDP from its differential diagnoses is often difficult. A recent study has evaluated the diagnostic performance of MRI in differentiating CIDP and multifocal motor neuropathy from disease controls (segmental spinal muscular atrophy) and healthy control subjects (Oudeman *et al.*, 2020). In that study, intra- and inter-observer agreement for qualitative assessment of nerve hypertrophy and hyperintensity as scored on STIR varied widely. This was also the case for qualitative scoring on magnetic resonance neurography, a newer sequence technique.

Several studies showed changes in diffusion tensor imaging in CIDP, a technique that enables quantitative measurements of water diffusivity within nerve tissue, but the diagnostic contrast seems relatively small and may not be useful in clinical practice (Kakuda *et al.*, 2011; Markvardsen *et al.*, 2016; Kronlage *et al.*, 2017; Oudeman *et al.*, 2020). Given the rapid development of MRI techniques, the aim may be to develop other preferably quantitative measures suited to peripheral nerve tissue in health and disease.

Increases in nerve cross-sectional area on nerve ultrasound have been reported in several studies. Nerve enlargement was found in 69–100% of CIDP patients (Matsuoka *et al.*, 2004; Zaidman *et al.*, 2009; Sugimoto *et al.*, 2013). Studies showed that the CSA of the brachial plexus and the median nerve were the most adequate measurements to distinguish between CIDP and axonal neuropathy (Grimm *et al.*, 2014; Goedee *et al.*, 2017b). A recent single centre study provided cut-off values based on the upper limits for axonal neuropathies and found a 100% specificity for enlargement of one or more segments of the median nerve or the cervical trunci/roots (Goedee *et al.*, 2017b). However, also in this study, only patient controls with a clear-cut diagnosis of axonal neuropathy or amyotrophic lateral sclerosis were studied. A

more recent single centre study that included 100 patients clinically suspected of an acquired inflammatory neuropathy found a high sensitivity (97%) for nerve ultrasound, but the specificity was lower than previously reported (69%) (Herraets *et al.*, 2020). In addition, ultrasound identified patients that responded to treatment but did not meet the electrodiagnostic criteria (Herraets *et al.*, 2020).

A good inter-observer variability of the nerve ultrasound was shown in a multicentre study, including acquired inflammatory neuropathies (Tellemann *et al.*, 2019). An advantage of nerve ultrasound over MRI is that nerve ultrasound is a relatively easy, quick, patient-friendly tool.

Evoked potentials

SSEP and triple stimulation technique (TST) may be of help in diagnosing CIDP. SSEPs are used to assess the functioning of the whole sensory pathway, including the nerve roots. The evidence that supports the use of SSEP in diagnosing CIDP is limited. Proximal sensory nerve involvement as investigated with SSEP was found in 38–100% of CIDP cases (Pineda *et al.*, 2007; Yiannikas and Vucic, 2008; Tsukamoto *et al.*, 2010; Salhi *et al.*, 2014). Sample sizes of these studies were often small. None of the studies investigated the diagnostic utility of SSEP in treatment-naïve patients or with the use of SSEP as a primary investigation. The role of the SSEP in diagnosing CIDP is clearly limited if the electrodiagnostic criteria are met. However, studies showed that in up to 100% of patients with a pure sensory presentation, who did not meet the electrophysiological criteria, SSEP showed involvement of the nerve roots (Sinreich *et al.*, 2004; Ayrygnac *et al.*, 2013). In clinical practice, SSEP should be considered in patients with predominant sensory ataxia and areflexia, if the electrodiagnostic criteria are not fulfilled.

Another potential method to overcome the challenges of assessing demyelination in proximal parts might be motor evoked potentials. Several explorative studies using motor evoked potentials in CIDP showed (very) prolonged peripheral conduction times and, less often, changes in central conduction times, but formal diagnostic accuracy studies have not been performed (Takada and Ravnborg, 2000; Pineda *et al.*, 2007). TST is a specialized diagnostic tool to examine the nerve roots proximal of Erb's point, and includes the use of motor evoked potentials. It may demonstrate proximal motor conduction blocks, even if patients do not meet the electrodiagnostic criteria (Attarian *et al.*, 2015; Cao *et al.*, 2018), indicating that TST can probably increase sensitivity. However, specificity is yet unknown and there is very limited experience with this technique.

Nerve biopsy

Whether nerve biopsy has additional value in diagnosing CIDP has long been a matter of debate. Usually, the nerve selected for biopsy is the sural nerve, as it is easily accessible. The pathological findings are segmental demyelination and

remyelination, onion bulb formation and inflammatory infiltrates (Krendel *et al.*, 1989). These findings were reported in 48–71% of the biopsies in patients that met diagnostic criteria (Barohn *et al.*, 1989; Krendel *et al.*, 1989; Molenaar *et al.*, 1998; Bouchard *et al.*, 1999). However, sample sizes of the studies were small and few studies compared biopsy results from CIDP patients with disease controls. One study suggested that none of the biopsy findings were specific for CIDP, as these findings were also found in vasculitis, axonal and demyelinating hereditary neuropathies and monoclonal gammopathies (Krendel *et al.*, 1989). Other studies also showed that nerve biopsies failed to differentiate between CIDP and axonal neuropathies or diabetic neuropathies (Molenaar *et al.*, 1998; Uncini *et al.*, 1999; Bosboom *et al.*, 2001). Some studies suggested that there might be some value in atypical CIDP cases (Vallat *et al.*, 2003; Ayrygnac *et al.*, 2013). The recent discovery of specific nodal and paranodal abnormalities in the ultrastructural analysis of the nerve in patients with antibodies against node of Ranvier cell adhesion molecules may have diagnostic utility in specific patients (Koike *et al.*, 2017; Vallat *et al.*, 2017; Uncini and Vallat, 2018). Nerve biopsy is considered invasive and will lead to persisting sensory loss in most patients, while persisting pain, infections and dysaesthesias have also been reported in a minority of patients (Gabriel *et al.*, 2000; Ruth *et al.*, 2005).

Autoantibodies

Autoantibody search has been an important topic of research in CIDP in the last decades, but just recently, subgroups of CIDP patients with antibodies targeting the nodes of Ranvier and paranodal regions have been described (Querol *et al.*, 2017a; Vural *et al.*, 2018). The discovery of these antibodies, associating with antibody-specific clinical features, boosted interest in the role of antibodies as diagnostic and prognostic biomarkers. Up to 25% of patients with CIDP show evidence of circulating autoantibodies targeting antigens of the peripheral nerve structures, including nodal and paranodal regions (Querol *et al.*, 2017b; Vural *et al.*, 2018; Broers *et al.*, 2019). Autoantibodies specifically targeting the nodal and paranodal regions are found in ~10% of CIDP patients. Antibodies to neurofascin 155 (NF155) are the most frequent, while antibodies to neurofascin 140 (NF140) and neurofascin 186 (NF186), contactin-1 (CNTN1) and contactin-associated protein 1 (CASPR1) are less common (Querol *et al.*, 2017a; Vural *et al.*, 2018; Bunschoten *et al.*, 2019). Most are of the IgG4 isotype. A systematic review reported a very low sensitivity of these autoantibodies but specificities of 100% in CIDP (Hu *et al.*, 2018). Specific clinical phenotypes have been described in patients with autoantibodies to the nodes and paranodes (Table 3). In general, antibodies to nodal and paranodal proteins, regardless of the autoantibody, associate with a subacute onset and more progressive CIDP phenotypes, initially often classified as Guillain-Barré syndrome, and poorer responses to immunoglobulins than patients without these autoantibodies (Hu *et al.*, 2018; Vural *et al.*, 2018). The

Table 3 Characteristics of patients with autoantibodies in CIDP

	Characteristics
Neurofascin 155 (NF155) (Querol <i>et al.</i> , 2014; Devaux <i>et al.</i> , 2016)	Subacute onset, fast progression Younger age Distal motor involvement Ataxia Prominent, low-frequency tremor
Neurofascin 140 and 186 (NF140 and NF186) (Delmont <i>et al.</i> , 2017; Stengel <i>et al.</i> , 2019)	Subacute onset, fast progression Cranial nerve deficits Ataxia
Contactin-1 (CNTN1) (Querol <i>et al.</i> , 2013; Miura <i>et al.</i> , 2015)	Subacute onset, fast progression Axonal involvement at onset Ataxia
Contactin-associated protein 1 (CASPR1) (Doppler <i>et al.</i> , 2016)	Severe pain

clinical significance of antibodies other than those targeting nodal and paranodal proteins is unclear.

The optimal technical approach to test for nodal/paranodal antibodies is currently under investigation. However, most published studies use cell-based assays (either immunocytochemistry or flow-cytometry) performed with HEK293 cells transfected with the human recombinant protein target of the antibodies, ELISAs using human recombinant proteins as the protein substrate or immunohistochemistry on teased-nerve fibres to detect the typical nodal or paranodal staining. Considering that the detection of these autoantibodies usually leads to the use of therapeutic algorithms that includes therapies (e.g. rituximab) that are not first line therapies in CIDP, it seems reasonable to try to confirm the detected antibodies with at least two different techniques to increase diagnostic specificity (Martín-Aguilar *et al.*, 2020).

Two independent series, in which a total of 113 patients were included, described six patients fulfilling the diagnostic criteria for CIDP, in which anti-MAG antibodies were detected in the absence of IgM paraproteinaemia. These patients presented and progressed similar to anti-MAG-positive patients with IgM paraproteinaemia (Sakamoto *et al.*, 2017; Pascual-Goñi *et al.*, 2019) and two of them developed detectable paraproteinaemia years after disease-onset, suggesting that a subset of patients classified as distal CIDP could indeed be patients with early anti-MAG-positive monoclonal gammopathy of undetermined significance related polyneuropathy (MGUSP) (Allen and Lewis, 2015). It is important to take this into account to avoid misdiagnosis, especially in patients with the distal phenotype.

Testing for antibodies should be considered in treatment unresponsive patients, especially in the presence of atypical symptoms such as a subacute onset, severe ataxia, pain or a tremor. In case of the distal phenotype and treatment unresponsiveness, M-protein reanalysis and anti-MAG antibodies may be considered. International, multicentric studies are currently underway, which focus on standardization of

measuring autoantibodies, but also on providing better estimates of the diagnostic accuracy of autoantibody testing in patients suspected of CIDP. If autoantibody testing is shown to be widely reliable and reproducible, it can be introduced for standard clinical practice.

Discussion

CIDP has a very heterogeneous presentation, and consists of a spectrum of autoimmune diseases of the peripheral nerves based on presumed breach of tolerance leading to autoimmunity against nerve antigens. Different pathophysiological mechanisms have been identified, often sharing clinical features, which makes diagnosis challenging.

The term CIDP was introduced in 1982 describing some of the most common features of the disease in four different domains, namely time of onset, pathophysiology, tissue component involved and anatomical distribution. However, the use of this term has evolved over time to try to incorporate other patients with primary chronic immune-mediated neuropathies susceptible to disease-modifying therapies that share but do not necessarily include all of the original features. More importantly, as our knowledge of the disease deepens, it has become increasingly difficult to unite all clinical presentations and pathophysiological mechanisms under this term, some even contradicting the original terminology. First, CIDP may have an acute onset, that initially resembles Guillain-Barré syndrome (Vural *et al.*, 2018). Also, some

neuropathies meet various supportive criteria, including treatment response, but not the electrophysiological criteria (Lucke *et al.*, 2019a; Herraets *et al.*, 2020). However, the best examples are the recently discovered nodal and paranodal neuropathies that are caused by autoantibodies. Some are autoantibodies to axonal nodal structures, such as CNTN1, so that it became clear that autoimmunity can be primarily directed to axonal antigens, and not only to myelin antigens. In case of anti-CNTN1, electron microscopy examination showed a selective loss of the septate-like junctions at the paranodes and a detachment of the paranodal myelin loops from the axon, but there was an absence of inflammation and classical macrophage-induced demyelination (Kouton *et al.*, 2020). Importantly, this disorganization of the nodes of Ranvier disrupts the saltatory conduction, which leads to electrophysiological findings that are traditionally interpreted as demyelinating features. The electrophysiological criteria for CIDP were originally intended to be able to detect the physiological substrate of demyelination, as this was the only known underlying pathology. However, in essence they are markers for functional disruption or slowing of the saltatory conduction of myelinated axons. In the context of CIDP, conduction block can result from paranodal abnormalities of the myelin sheath, but also from primary dysfunction of the axon at the nodes of Ranvier. Considering that inflammation and demyelination as core features are not present in all CIDP patients, while an autoimmune aetiology is presumed in all patients, the umbrella term ‘chronic autoimmune neuropathies’ may fit

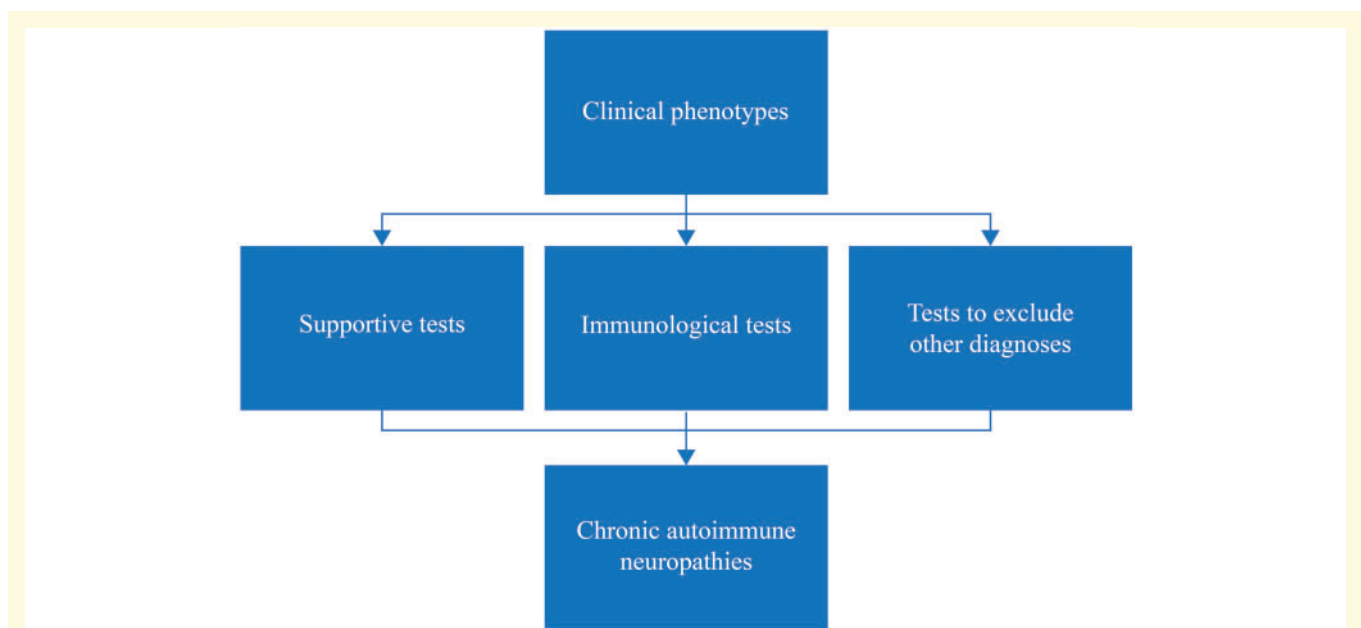


Figure 1 A conceptual framework for a diagnostic work-up in chronic autoimmune neuropathies. A conceptual framework for a diagnostic work-up in chronic auto-immune neuropathies, assuming future emphasis on immunological tests with high specificity to show evidence for autoimmunity. Combinations and number of tests required for diagnosis depend on specificity of clinical phenotypes, of immunological tests and of supportive tests, such as nerve conduction studies, imaging, CSF examination, pathology and response to treatment. NCS currently have the best diagnostic accuracy.

better (Fig. 1). Further discussion will be needed on whether to include other entities such as multifocal motor neuropathy and anti-MAG neuropathy within this term. Recent studies suggested that anti-MAG antibodies can be present in few patients with CIDP without the presence of IgM paraproteinaemia. However, in an overwhelming majority of patients there is also IgM paraproteinaemia, suggesting that the underlying pathomechanism is plasma cell dyscrasia rather than breach of tolerance. Moreover, further studies are needed to determine the diagnostic cut-off of anti-MAG antibodies in those patients without IgM paraproteins as these can also be found in low quantities in other conditions.

Regardless of the nomenclature, if we consider the autoimmune aetiology as the hallmark of the disease, in the future we should also probably focus more on introducing specific immunological tests in our diagnostic work-up. This would be in line with the diagnostic approaches of other, similarly heterogeneous, autoimmune diseases, in which access to tissue is difficult, such as autoimmune encephalopathies (Graus *et al.*, 2016). Unfortunately, despite recent progress, finding proof of autoimmunity is currently difficult as antibodies in blood/CSF are only found in a minority of patients, while unambiguous pathology results from nerve biopsy supporting an autoimmune origin are uncommon. However, other autoantibody reactivities or markers of autoimmunity, including immunity-related genes, may be identified in the future (Nevo *et al.*, 2013; Staudt *et al.*, 2017).

Despite desirable future advances to prove autoimmunity in more patients, the diagnosis of CIDP currently remains a clinical one, with greater complexity and concurrently increased uncertainty for atypical versus typical forms. The absence of a golden standard challenges proper evaluation of diagnostic accuracy of tests. Still, taking surrogate standards, such as fulfilment of consensus criteria and treatment response, partially overcomes this problem. Recognizing the technical difficulties and caveats as outlined in this review, will hopefully reduce the number of patients with misdiagnosis and underdiagnosis, particularly in non-expert environments. Currently, in the majority of patients, the diagnosis is supported by electrophysiological evidence of impaired saltatory conduction, so that NCS still are the most reliable and widely available diagnostic test to support the diagnosis of CIDP. A slightly elevated CSF protein level has a poor specificity, while normal protein levels do not exclude the diagnosis. If imaging is required, nerve ultrasound is probably preferred as it is quicker, easier and has a higher diagnostic accuracy compared to MRI, but further multicentre studies are needed. The role of evoked potentials and nerve biopsy is very limited in most patients and should be reserved for selected cases. Finally, progression should be made in standardized detection of currently available autoantibodies, of new autoantibodies and of other evidence for autoimmunity to improve diagnostic accuracy, so that these tests may become more useful in standard clinical practice. With the last update of the guidelines almost 10 years ago and the

introduction of the nerve ultrasound and the discovery of autoantibodies in CIDP, the update of the EAN/PNS diagnostic guidelines is much awaited.

Funding

No funding was received towards this work.

Competing interests

F.E. reports grants from ZonMw (Dutch Governmental Agency) and Prinses Beatrix Spierfonds. He also reports grants from CSL Behring, Kedrion, Terumo BCT and Takeda Pharmaceutical Company, outside the submitted work. Grants were paid to institution and are used for investigator initiated studies within INCbase, an international CIDP registry. He also received consultancy fees from UCB pharma, paid to institution, outside the submitted work. I.L. has nothing to disclose. L.Q. has provided expert testimony for Grifols, Sanofi-Genzyme, Novartis, UCB, Roche and CSL Behring and received research funds from Novartis Spain, Sanofi-Genzyme and Grifols, outside the submitted work. Y.R. has received speaker/consultancy honoraria from CSL Behring, LFB, Grifols, BPL, Octapharma and Kedrion, has received educational sponsorships from LFB, CSL Behring and Baxter and has obtained research grants from CSL Behring and LFB, outside the submitted work. C.V. is a member of a clinical advisory board (CAB) of Infectis France; payment was made to his organization for attending a CAB meeting, outside the submitted work.

References

- Adachi Y, Sato N, Okamoto T, Sasaki M, Komaki H, Yamashita F, et al. Brachial and lumbar plexuses in chronic inflammatory demyelinating polyradiculoneuropathy: MRI assessment including apparent diffusion coefficient. *Neuroradiology* 2011; 53: 3–11.
- Allen JA, Lewis RA. CIDP diagnostic pitfalls and perception of treatment benefit. *Neurology* 2015; 85: 498–504.
- Allen JA, Ney J, Lewis RA. Electrodiagnostic errors contribute to chronic inflammatory demyelinating polyneuropathy misdiagnosis. *Muscle Nerve* 2018; 57: 542–9.
- American Academy of Neurology (AAN). Research criteria for diagnosis of chronic inflammatory demyelinating polyneuropathy (CIDP). Report from an Ad Hoc Subcommittee of the American Academy of Neurology AIDS Task Force. *Neurology* 1991; 41: 617–8.
- Argyriou AA, Polychronopoulos P, Talelli P, Chroni E. F wave study in amyotrophic lateral sclerosis: assessment of balance between upper and lower motor neuron involvement. *Clin Neurophysiol* 2006; 117: 1260–5.
- Attarian S, Franques J, Elisabeth J, Trébuchon A, Duclos Y, Wybrecht D, et al. Triple-stimulation technique improves the diagnosis of chronic inflammatory demyelinating polyradiculoneuropathy. *Muscle Nerve* 2015; 51: 541–8.
- Ayrignac X, Viala K, Koutlidis RM, Taieb G, Stojkovic T, Musset L, et al. Sensory chronic inflammatory demyelinating polyneuropathy: an under-recognized entity? *Muscle Nerve* 2013; 48: 727–32.

- Barohn RJ, Kissel JT, Warmolts JR, Mendell JR. Chronic inflammatory demyelinating polyradiculoneuropathy. Clinical characteristics, course, and recommendations for diagnostic criteria. *Arch Neurol* 1989; 46: 878–84.
- Bosboom WM, van den Berg LH, Franssen H, Giesbergen PC, Flach HZ, van Putten AM, et al. Diagnostic value of sural nerve demyelination in chronic inflammatory demyelinating polyneuropathy. *Brain Behav* 2001; 124: 2427–38.
- Bouchard C, Lacroix C, Planté V, Adams D, Chedru F, Guglielmi JM, et al. Clinicopathologic findings and prognosis of chronic inflammatory demyelinating polyneuropathy. *Neurology* 1999; 52: 498–503.
- Bouche P, Gherardi R, Cathala HP, Lhermitte F, Castaigne P. Peroneal muscular atrophy. Part 1. Clinical and electrophysiological study. *J Neurol Sci* 1983; 61: 389–99.
- Boukhris S, Magy L, Kabore R, Mabrouk T, Li Y, Sindou P, et al. Atypical electrophysiologic findings in chronic inflammatory demyelinating polyneuropathy (CIDP)—diagnosis confirmed by nerve biopsy. *Neurophysiol Clin* 2004; 34: 71–9.
- Bragg JA, Benatar MG. Sensory nerve conduction slowing is a specific marker for CIDP. *Muscle Nerve* 2008; 38: 1599–603.
- Breiner A, Bourque PR, Allen JA. Updated cerebrospinal fluid total protein reference values improve chronic inflammatory demyelinating polyneuropathy diagnosis. *Muscle Nerve* 2019; 60: 180–3.
- Breiner A, Brannagan TH. Comparison of sensitivity and specificity among 15 criteria for chronic inflammatory demyelinating polyneuropathy. *Muscle Nerve* 2014; 50: 40–6.
- Breiner A, Qrimli M, Ebadi H, Alabdali M, Lovblom LE, Abraham A, et al. Peripheral nerve high-resolution ultrasound in diabetes. *Muscle Nerve* 2017; 55: 171–8.
- Broers MC, Bunschoten C, Nieboer D, Lingsma HF, Jacobs BC. Incidence and prevalence of chronic inflammatory demyelinating polyradiculoneuropathy: a systematic review and meta-analysis. *Neuroepidemiology* 2019; 52: 161–72.
- Bunschoten C, Jacobs BC, Van den Bergh PYK, Cornblath DR, van Doorn PA. Progress in diagnosis and treatment of chronic inflammatory demyelinating polyradiculoneuropathy. *Lancet Neurol* 2019; 18: 784–94.
- Cao D, Guo X, Yuan T, Hao J. Diagnosing chronic inflammatory demyelinating polyradiculoneuropathy with triple stimulation technique. *J Neurol* 2018; 265: 1916–21.
- Delmont E, Manso C, Querol L, Cortese A, Berardinelli A, Lozza A, et al. Autoantibodies to nodal isoforms of neurofascin in chronic inflammatory demyelinating polyneuropathy. *Brain* 2017; 140: 1851–8.
- Devaux JJ, Miura Y, Fukami Y, Inoue T, Manso C, Belghazi M, et al. Neurofascin-155 IgG4 in chronic inflammatory demyelinating polyneuropathy. *Neurology* 2016; 86: 800–7.
- Doppler K, Appeltshauser L, Villmann C, Martin C, Peles E, Krämer HH, et al. Auto-antibodies to contactin-associated protein 1 (Caspr) in two patients with painful inflammatory neuropathy. *Brain* 2016; 139: 2617–30.
- Dyck PJ, Lais AC, Ohta M, Bastron JA, Okazaki H, Groover RV. Chronic inflammatory polyradiculoneuropathy. *Mayo Clin Proc* 1975; 50: 621–37.
- Eftimov F, Winer JB, Vermeulen M, de Haan R, van Schaik IN. Intravenous immunoglobulin for chronic inflammatory demyelinating polyradiculoneuropathy. *Cochrane Database Syst Rev* 2013; CD001797.
- Gabriel CM, Howard R, Kinsella N, Lucas S, McColl I, Saldanha G, et al. Prospective study of the usefulness of sural nerve biopsy. *J Neurol Neurosurg Psychiatry* 2000; 69: 442–6.
- Goedee HS, Jongbloed BA, van Asseldonk J-TH, Hendrikse J, Vrancken AFJE, Franssen H, et al. A comparative study of brachial plexus sonography and magnetic resonance imaging in chronic inflammatory demyelinating neuropathy and multifocal motor neuropathy. *Eur J Neurol* 2017a; 24: 1307–13.
- Goedee HS, van der Pol WL, van Asseldonk J-TH, Franssen H, Notermans NC, Vrancken AJFE, et al. Diagnostic value of sonography in treatment-naive chronic inflammatory neuropathies. *Neurology* 2017b; 88: 143–51.
- Graus F, Titulaer MJ, Balu R, Benseler S, Bien CG, Cellucci T, et al. A clinical approach to diagnosis of autoimmune encephalitis. *Lancet Neurol* 2016; 15: 391–404.
- Grimm A, Heiling B, Schumacher U, Witte OW, Axer H. Ultrasound differentiation of axonal and demyelinating neuropathies. *Muscle Nerve* 2014; 50: 976–83.
- Herraets IJT, Goedee HS, Telleman JA, van Eijk RPA, van Asseldonk JT, Visser LH, et al. Nerve ultrasound improves detection of treatment-responsive chronic inflammatory neuropathies. *Neurology* 2020; 94: e1470–9.
- Hu W, Xin Y, He Z, Zhao Y. Association of neurofascin IgG4 and atypical chronic inflammatory demyelinating polyneuropathy: a systematic review and meta-analysis. *Brain Behav* 2018; 8: e01115.
- Hughes RA, Mehndiratta MM, Rajabally YA. Corticosteroids for chronic inflammatory demyelinating polyradiculoneuropathy. *Cochrane Database Syst Rev* 2017; CD002062.
- Hughes RAC, Bouche P, Cornblath DR, Evers E, Hadden RDM, Hahn A, et al. European Federation of Neurological Societies/Peripheral Nerve Society guideline on management of chronic inflammatory demyelinating polyradiculoneuropathy: report of a joint task force of the European Federation of Neurological Societies and the Peripheral Nerve Society. *Eur J Neurol* 2006; 13: 326–32.
- Isoe S, Kuwabara S, Kokubun N, Sato Y, Mori M, Shibuya K, et al. Utility of the distal compound muscle action potential duration for diagnosis of demyelinating neuropathies. *J Peripher Nerv Syst* 2009; 14: 151–8.
- Johnsen B, Fuglsang-Frederiksen A, de Carvalho M, Labarre-Vila A, Nix W, Schofield I. Amplitude, area and duration of the compound muscle action potential change in different ways over the length of the ulnar nerve. *Clin Neurophysiol* 2006; 117: 2085–92.
- Jongbloed BA, Bos JW, Rutgers D, van der Pol WL, van den Berg LH. Brachial plexus magnetic resonance imaging differentiates between inflammatory neuropathies and does not predict disease course. *Brain Behav* 2017; 7: e00632.
- Kakuda T, Fukuda H, Tanitame K, Takasu M, Date S, Ochi K, et al. Diffusion tensor imaging of peripheral nerve in patients with chronic inflammatory demyelinating polyradiculoneuropathy: a feasibility study. *Neuroradiology* 2011; 53: 955–60.
- Kimura J, Machida M, Ishida T, Yamada T, Rodnitzky RL, Kudo Y, et al. Relation between size of compound sensory or muscle action potentials, and length of nerve segment. *Neurology* 1986; 36: 647–52.
- Kincaid JC, Minnick KA, Pappas S. A model of the differing change in motor and sensory action potentials over distance. *Muscle Nerve* 1988; 11: 318–23.
- Kobessho H, Oishi K, Hamaguchi H, Kanda F. Elevation of cerebrospinal fluid protein in patients with diabetes mellitus is associated with duration of diabetes. *Eur Neurol* 2008; 60: 132–6.
- Koike H, Kadoya M, Kaida KI, Ikeda S, Kawagashira Y, Iijima M, et al. Paranodal dissection in chronic inflammatory demyelinating polyneuropathy with anti-neurofascin-155 and anti-contactin-1 antibodies. *J Neurol Neurosurg Psychiatry* 2017; 88: 465–73.
- Koski CL, Baumgarten M, Magder LS, Barohn RJ, Goldstein J, Graves M, et al. Derivation and validation of diagnostic criteria for chronic inflammatory demyelinating polyneuropathy. *J Neurol Sci* 2009; 277: 1–8.
- Kouton L, Boucraut J, Devaux J, Rajabally YA, Adams D, Antoine JC, et al. Electrophysiological features of chronic inflammatory demyelinating polyradiculoneuropathy associated with IgG4 antibodies targeting neurofascin 155 or contactin 1 glycoproteins. *Clin Neurophysiol* 2020; 131: 921–7.
- Krendel DA, Parks HP, Anthony DC, St Clair MB, Graham DG. Sural nerve biopsy in chronic inflammatory demyelinating polyradiculoneuropathy. *Muscle Nerve* 1989; 12: 257–64.

- Kronlage M, Pitarokoili K, Schwarz D, Godel T, Heiland S, Yoon M-S, et al. Diffusion tensor imaging in chronic inflammatory demyelinating polyneuropathy: diagnostic accuracy and correlation with electrophysiology. *Invest Radiol* 2017; 52: 701–7.
- Lozeron P, Lacour M-C, Vandendries C, Théaudin M, Cauquil C, Denier C, et al. Contribution of plexus MRI in the diagnosis of atypical chronic inflammatory demyelinating polyneuropathies. *J Neurol Sci* 2016; 360: 170–5.
- Lucke IM, Adrichem ME, Wieske L, van der Kooij AJ, Verhamme C, van Schaik IN, et al. Intravenous immunoglobulins in patients with clinically suspected chronic immune-mediated neuropathy. *J Neurol Sci* 2019a; 397: 141–5.
- Lucke IM, Peric S, van Lieferloo GGA, Wieske L, Verhamme C, van Schaik IN, et al. Elevated leukocyte count in cerebrospinal fluid of patients with chronic inflammatory demyelinating polyneuropathy. *J Peripher Nerv Syst* 2018; 23: 49–54.
- Lucke IM, Wieske L, van der Kooij AJ, van Schaik IN, Eftimov F, Verhamme C. Diagnosis and treatment response in the asymmetric variant of chronic inflammatory demyelinating polyneuropathy. *J Peripher Nerv Syst* 2019b; 24: 174–9.
- Markvardsen LH, Vaeggemose M, Ringgaard S, Andersen H. Diffusion tensor imaging can be used to detect lesions in peripheral nerves in patients with chronic inflammatory demyelinating polyneuropathy treated with subcutaneous immunoglobulin. *Neuroradiology* 2016; 58: 745–52.
- Martín-Aguilar L, Pascual-Goñi E, Lleixà C, Frasquet M, Argente H, Cano-Abascal A, et al. Antibodies against nodo-paranodal proteins are not present in genetic neuropathies. *Neurology* 2020; 95: e427–e433.
- Matsuoka N, Kohriyama T, Ochi K, Nishitani M, Sueda Y, Mimori Y, et al. Detection of cervical nerve root hypertrophy by ultrasonography in chronic inflammatory demyelinating polyradiculoneuropathy. *J Neurol Sci* 2004; 219: 15–21.
- McCombe PA, Pollard JD, McLeod JG. Chronic inflammatory demyelinating polyradiculoneuropathy. A clinical and electrophysiological study of 92 cases. *Brain* 1987; 110: 1617–30.
- Mehndiratta MM, Hughes RA, Pritchard J. Plasma exchange for chronic inflammatory demyelinating polyradiculoneuropathy. *Cochrane Database Syst Rev* 2015; CD003906.
- Midroni G, de Tilly LN, Gray B, Vajsar J. MRI of the cauda equina in CIDP: clinical correlations. *J Neurol Sci* 1999; 170: 36–44.
- Mitsuma S, Van den Bergh P, Rajabally YA, Van Parijs V, Martin-Lamb D, Sonoo M, et al. Effects of low frequency filtering on distal compound muscle action potential duration for diagnosis of CIDP: a Japanese-European multicenter prospective study. *Clin Neurophysiol* 2015; 126: 1805–10.
- Miura Y, Devaux JJ, Fukami Y, Manso C, Belghazi M, Wong AH, et al. Contactin 1 IgG4 associates to chronic inflammatory demyelinating polyneuropathy with sensory ataxia. *Brain* 2015; 138: 1484–91.
- Molenaar DS, Vermeulen M, de Haan R. Diagnostic value of sural nerve biopsy in chronic inflammatory demyelinating polyneuropathy. *J Neurol Neurosurg Psychiatry* 1998; 64: 84–9.
- Nevo Y, Ben-Zeev B, Tabib A, Straussberg R, Anikster Y, Shorer Z, et al. CD59 deficiency is associated with chronic hemolysis and childhood relapsing immune-mediated polyneuropathy. *Blood* 2013; 121: 129–35.
- Oudeman JE, Strijkers G, Verhamme C. Diagnostic accuracy of MRI and ultrasound in chronic immune-mediated neuropathies. *Neurology* 2020; 94: e62–74.
- Padua L, Caliandro P, Aprile I, Sabatelli M, Madia F, Tonali P. Occurrence of nerve entrapment lesion in chronic inflammatory demyelinating polyneuropathy. *Clin Neurophysiol* 2004; 115: 1140–4.
- Padua L, Coraci D, Lucchetta M, Paolasso I, Pazzaglia C, Granata G, et al. Different nerve ultrasound patterns in charcot-marie-tooth types and hereditary neuropathy with liability to pressure palsies. *Muscle Nerve* 2018; 57: E18–e23.
- Pascual-Goñi E, Martín-Aguilar L, Lleixà C, Martínez-Martínez L, Simón-Talero MJ, Díaz-Manera J, et al. Clinical and laboratory features of anti-MAG neuropathy without monoclonal gammopathy. *Sci Rep* 2019; 9: 6155.
- Pastore-Olmedo C, Gonzalez O, Geijo-Barrientos E. A study of F-waves in patients with unilateral lumbosacral radiculopathy. *Eur J Neurol* 2009; 16: 1233–9.
- Pineda AA, Ogata K, Osoegawa M, Murai H, Shigeto H, Yoshiura T, et al. A distinct subgroup of chronic inflammatory demyelinating polyneuropathy with CNS demyelination and a favorable response to immunotherapy. *J Neurol Sci* 2007; 255: 1–6.
- Press R, Pashenkov M, Jin JP, Link H. Aberrated levels of cerebrospinal fluid chemokines in Guillain-Barré syndrome and chronic inflammatory demyelinating polyradiculoneuropathy. *J Clin Immunol* 2003; 23: 259–67.
- Prineas JW, McLeod JG. Chronic relapsing polyneuritis. *J Neurol Sci* 1976; 27: 427–58.
- Puksa L, Stalberg E, Falck B. Reference values of F wave parameters in healthy subjects. *Clin Neurophysiol* 2003; 114: 1079–90.
- Querol L, Devaux J, Rojas-García R, Illa I. Autoantibodies in chronic inflammatory neuropathies: diagnostic and therapeutic implications. *Nat Rev Neurol* 2017a; 13: 533–47.
- Querol L, Nogales-Gadea G, Rojas-García R, Díaz-Manera J, Pardo J, Ortega-Moreno A, et al. Neurofascin IgG4 antibodies in CIDP associate with disabling tremor and poor response to IVIg. *Neurology* 2014; 82: 879–86.
- Querol L, Nogales-Gadea G, Rojas-García R, Martínez-Hernández E, Díaz-Manera J, Suárez-Calvet X, et al. Antibodies to contactin-1 in chronic inflammatory demyelinating polyneuropathy. *Ann Neurol* 2013; 73: 370–80.
- Querol L, Siles AM, Alba-Rovira R, Jáuregui A, Devaux J, Faivre-Sarrailh C, et al. Antibodies against peripheral nerve antigens in chronic inflammatory demyelinating polyradiculoneuropathy. *Sci Rep* 2017b; 7: 14411.
- Rajabally YA, Chavada G. Lewis-sumner syndrome of pure upper-limb onset: diagnostic, prognostic, and therapeutic features. *Muscle Nerve* 2009; 39: 206–20.
- Rajabally YA, Fowle AJ, Van den Bergh PY. Which criteria for research in chronic inflammatory demyelinating polyradiculoneuropathy? An analysis of current practice. *Muscle Nerve* 2014; 51: 932–3.
- Rajabally YA, Jacob S. Proximal nerve conduction studies in chronic inflammatory demyelinating polyneuropathy. *Clin Neurophysiol* 2006; 117: 2079–84.
- Rajabally YA, Jacob S, Hbabbih M. Optimizing the use of electrophysiology in the diagnosis of chronic inflammatory demyelinating polyneuropathy: a study of 20 cases. *J Peripher Nerv Syst* 2005; 10: 282–92.
- Rajabally YA, Lagarde J, Cassereau J, Viala K, Fournier E, Nicolas G. A European multicentre reappraisal of distal compound muscle action potential duration in chronic inflammatory demyelinating polyneuropathy. *Eur J Neurol* 2012; 19: 638–42.
- Rajabally YA, Narasimhan M. The value of sensory electrophysiology in chronic inflammatory demyelinating polyneuropathy. *Clin Neurophysiol* 2007; 118: 1999–2004.
- Rajabally YA, Narasimhan M. Distribution, clinical correlates and significance of axonal loss and demyelination in chronic inflammatory demyelinating polyneuropathy. *Eur J Neurol* 2011a; 18: 293–9.
- Rajabally YA, Narasimhan M. Electrophysiological entrapment syndromes in chronic inflammatory demyelinating polyneuropathy. *Muscle Nerve* 2011b; 44: 444–7.
- Rajabally YA, Nicolas G, Pieret F, Bouche P, Van den Bergh PY. Validity of diagnostic criteria for chronic inflammatory demyelinating polyneuropathy: a multicentre European study. *J Neurol Neurosurg Psychiatry* 2009; 80: 1364–8.
- Rajabally YA, Samarasekera S. Electrophysiological sensory demyelination in typical chronic inflammatory demyelinating polyneuropathy. *Eur J Neurol* 2010; 17: 939–44.

- Rajabally YA, Varanasi S. Practical electrodiagnostic value of F-wave studies in chronic inflammatory demyelinating polyneuropathy. *Clin Neurophysiol* 2013; 124: 171–5.
- Ruth A, Schulmeyer FJ, Roesch M, Woertgen C, Brawanski A. Diagnostic and therapeutic value due to suspected diagnosis, long-term complications, and indication for sural nerve biopsy. *Clin Neurol Neurosurg* 2005; 107: 214–7.
- Sakamoto Y, Shimizu T, Tobisawa S, Isozaki E. Chronic demyelinating neuropathy with anti-myelin-associated glycoprotein antibody without any detectable M-protein. *Neurol Sci* 2017; 38: 2165–9.
- Salhi H, Corcia P, Remer S, Praline J. Somatosensory evoked potentials in chronic inflammatory demyelinating polyradiculoneuropathy. *J Clin Neurophysiol* 2014; 31: 241–5.
- Shibuya K, Sugiyama A, Ito S-I, Misawa S, Sekiguchi Y, Mitsuma S, et al. Reconstruction magnetic resonance neurography in chronic inflammatory demyelinating polyneuropathy. *Ann Neurol* 2015; 77: 333–7.
- Sinclair CDJ, Miranda MA, Cowley P, Morrow JM, Davagnanam I, Mehta H, et al. MRI shows increased sciatic nerve cross sectional area in inherited and inflammatory neuropathies. *J Neurol Neurosurg Psychiatry* 2011; 82: 1283–6.
- Sinnreich M, Klein CJ, Daube JR, Engelstad J, Spinner RJ, Dyck PJB. Chronic immune sensory polyradiculopathy: a possibly treatable sensory ataxia. *Neurology* 2004; 63: 1662–9.
- Staudt M, Diederich JM, Meisel C, Meisel A, Klehmet J. Differences in peripheral myelin antigen-specific T cell responses and T memory subsets in atypical versus typical CIDP. *BMC Neurol* 2017; 17: 81.
- Stengel H, Vural A, Brunder AM, Heinius A, Appeltshauser L, Fiebig B, et al. Anti-pan-neurofascin IgG3 as a marker of fulminant autoimmune neuropathy. *Neurol Neuroimmunol Neuroinflamm* 2019; 6: e603.
- Sugimoto T, Ochi K, Hosomi N, Takahashi T, Ueno H, Nakamura T, et al. Ultrasonographic nerve enlargement of the median and ulnar nerves and the cervical nerve roots in patients with demyelinating Charcot-Marie-Tooth disease: distinction from patients with chronic inflammatory demyelinating polyneuropathy. *J Neurol* 2013; 260: 2580–7.
- Takada H, Ravnborg M. Magnetically evoked motor potentials in demyelinating and axonal polyneuropathy: a comparative study. *Eur J Neurol* 2000; 7: 63–9.
- Tamura N, Kuwabara S, Misawa S, Mori M, Nakata M, Hattori T. Superficial radial sensory nerve potentials in immune-mediated and diabetic neuropathies. *Clin Neurophysiol* 2005; 116: 2330–3.
- Tazawa K-I, Matsuda M, Yoshida T, Shimojima Y, Gono T, Morita H, et al. Spinal nerve root hypertrophy on MRI: clinical significance in the diagnosis of chronic inflammatory demyelinating polyradiculoneuropathy. *Intern Med* 2008; 47: 2019–24.
- Telleman JH, Goedee HS, Verhamme C, Nikolakopoulos S, van Asseldonk JT, van der Pol L, et al. Nerve ultrasound: a reproducible diagnostic tool in peripheral neuropathy. *Neurology* 2019; 92: e443–e450.
- Tsukamoto H, Sonoo M, Shimizu T. Segmental evaluation of the peripheral nerve using tibial nerve SEPs for the diagnosis of CIDP. *Clin Neurophysiol* 2010; 121: 77–84.
- Uncini A, De Angelis MV, Di Muzio A, Callegarini C, Ciucci G, Antonini G, et al. Chronic inflammatory demyelinating polyneuropathy in diabetics: motor conduction is important in the differential diagnosis with diabetic polyneuropathy. *Clin Neurophysiol* 1999; 110: 705–11.
- Uncini A, Vallat JM. Autoimmune nodo-paranodopathies of peripheral nerve: the concept is gaining ground. *J Neurol Neurosurg Psychiatry* 2018; 89: 627–35.
- Vallat JM, Tabaraud F, Magy L, Torny F, Bernet-Bernady P, Macian F, et al. Diagnostic value of nerve biopsy for atypical chronic inflammatory demyelinating polyneuropathy: evaluation of eight cases. *Muscle Nerve* 2003; 27: 478–85.
- Vallat JM, Yuki N, Sekiguchi K, Kokubun N, Oka N, Mathis S, et al. Paranodal lesions in chronic inflammatory demyelinating polyneuropathy associated with anti-Neurofascin 155 antibodies. *Neuromuscul Disord* 2017; 27: 290–3.
- Van Asseldonk JTH, Van den Berg LH, Kalmijn S, Wokke JHJ, Franssen H. Criteria for demyelination based on the maximum slowing due to axonal degeneration, determined after warming in water at 37 degrees C: diagnostic yield in chronic inflammatory demyelinating polyneuropathy. *Brain* 2005; 128: 880–91.
- Van den Bergh PY, Hadden RD, Bouche P, Cornblath DR, Hahn A, Illa I, et al. European Federation of Neurological Societies/Peripheral Nerve Society guideline on management of chronic inflammatory demyelinating polyradiculoneuropathy: report of a joint task force of the European Federation of Neurological Societies and the Peripheral nerve society. *Eur J Neurol* 2010; 17: 356–63.
- Van den Bergh PYK, Piéret F. Electrodiagnostic criteria for acute and chronic inflammatory demyelinating polyradiculoneuropathy. *Muscle Nerve* 2004; 29: 565–74.
- van Doorn PA, Vermeulen M, Brand A, Mulder PG, Busch HF. Intravenous immunoglobulin treatment in patients with chronic inflammatory demyelinating polyneuropathy. Clinical and laboratory characteristics associated with improvement. *Arch Neurol* 1991; 48: 217–20.
- van Rosmalen M, Lieba-Samal D, Pillen S, van Alfen N. Ultrasound of peripheral nerves in neuralgic amyotrophy. *Muscle Nerve* 2019; 59: 55–9.
- Vural A, Doppler K, Meinel E. Autoantibodies against the node of Ranvier in seropositive chronic inflammatory demyelinating polyneuropathy: diagnostic, pathogenic, and therapeutic relevance. *Front Immunol* 2018; 9: 1029.
- Yiannikas C, Vucic S. Utility of somatosensory evoked potentials in chronic acquired demyelinating neuropathy. *Muscle Nerve* 2008; 38: 1447–54.
- Zaidman CM, Al-Lozi M, Pestronk A. Peripheral nerve size in normals and patients with polyneuropathy: an ultrasound study. *Muscle Nerve* 2009; 40: 960–6.