

Back to the future in traumatic fracture shapes of lumbar spine: An analysis of risk of kyphosis after conservative treatment

ABSTRACT

Introduction: Nonosteoporotic burst vertebral fracture could commonly be treated with conservative or surgical approach. Currently, decision-making process is based on thoracolumbar (TL) AO spine severity injury score. However, some factors could affect posttraumatic kyphosis (PTK) and could be taken into account. The aim of the present study is to identify if axial and sagittal fracture shape and initial kyphosis are the risk factors for PTK.

Materials and Methods: All consecutive patients treated between 2016 and 2017 for TL vertebral fracture with conservative treatment were retrospectively evaluated in the study. Only type A3 and A4 vertebral fractures were included in the study. Patients suffering from osteoporosis or other metabolic bone disease, aged above 60 years old were excluded from the study. Initial and 6 months X-ray from injury were analyzed to evaluate local kyphosis and region of injury while initial assessment was performed with computed tomography to better identify fracture type and in some cases magnetic resonance imaging to exclude posterior ligament complex injury. Axial and sagittal view of the vertebral plate was analyzed and classified in three shapes according to fragment comminution and dislocation. Statistical analysis was performed through STATA13 software. Student's *t*-test was used to evaluate the differences between initial and follow up kyphosis; odds ratio (OR) was used to evaluate the role of initial kyphosis, vertebral sagittal and axial fracture shape as a risk factor for PTK. Kruskal–Wallis test was used to assess the differences among vertebral shape fractures and final kyphosis. Fisher's exact test was used to assess the differences between fracture patterns and final kyphosis.

Results: An initial kyphosis $>10^\circ$ (OR 36.75 $P = 0.015$), shape c vertebral plate (OR 147 $P = 0.0015$), and sagittal shape 3 (OR 32.25 $P = 0.0025$) are strongly related with PTK. Kruskal–Wallis test revealed a statistically significant difference among axial fracture shape ($P < 0.0001$) and sagittal fracture shape ($P = 0.004$) and also for initial kyphosis $>10^\circ$ ($P < 0.0001$). Fisher's exact test showed a significant difference for final kyphosis among pattern c3 and other patterns of fracture ($P = 0.0001$).

Conclusions: A burst type lumbar vertebral fracture affecting a patient with initial local kyphosis $>10^\circ$ and comminution and displacement of vertebral plate and vertebral body is at high risk to develop a local kyphosis $>20^\circ$ in the follow-up if treated conservatively.

Keywords: Burst fracture, local kyphosis, modifiers vertebral fracture, traumatic vertebral fracture

**FEDERICO FUSINI, GABRIELE COLÒ¹,
SALVATORE RISITANO², ALESSANDRO MASSÈ³,
LAURA ROSSI⁴, ANGELA CONIGLIO⁵, MASSIMO GIRARDO⁵**

Department of Orthopaedic and Traumatology, Regina Montis Regalis Hospital, Cuneo, ¹Department of Orthopaedics and Traumatology, Regional Center for Joint Arthroplasty, Alessandria, ²Department of Orthopaedic and Traumatology, Maggiore Hospital of Chieri, ⁴Division of Orthopedic Oncologic Surgery, Orthopaedic and Traumatology Center, AOU Città della Salute e della Scienza di Torino, Turin, ³Department of Orthopaedic and Traumatology, Orthopaedic and Traumatology Hospital, AOU Città della Salute e della Scienza di Torino, ⁵Department of Orthopaedic and Traumatology, Spine Surgery Unit, Orthopaedic and Traumatology Hospital, AOU Città della Salute e della Scienza di Torino, Torino, Italy

Address for correspondence: Dr. Federico Fusini, Department of Orthopaedic and Traumatology, Regina Montis Regalis Hospital, Azienda Sanitaria locale CN1, Via S Rocchetto 99, Mondovì, Cuneo 12084, Italy.
E-mail: fusinif@hotmail.com

Submitted: 04-Nov-20


Accepted: 13-Nov-20

Published: 04-Mar-21

This is an open access journal, and articles are distributed under the terms of the Creative Commons Attribution-NonCommercial-ShareAlike 4.0 License, which allows others to remix, tweak, and build upon the work non-commercially, as long as appropriate credit is given and the new creations are licensed under the identical terms.

For reprints contact: WKHLRPMedknow_reprints@wolterskluwer.com

How to cite this article: Fusini F, Colò G, Risitano S, Massè A, Rossi L, Coniglio A, *et al.* Back to the future in traumatic fracture shapes of lumbar spine: An analysis of risk of kyphosis after conservative treatment. *J Craniovert Jun Spine* 2021;12:38-43.

Access this article online	
Website: www.jcvjs.com	Quick Response Code 
DOI: 10.4103/jcvjs.JCVJS_189_20	

INTRODUCTION

Traumatic burst fractures are very common in orthopedic practice counting about 15% of all thoracolumbar (TL) vertebral fractures.^[1] TL spine is the most affected region due to its anatomical features. Currently, incomplete and complete burst fractures, classified as type A3 and A4,^[2] are both treated with surgical or conservative treatment in the absence of neurological symptoms and injury of posterior ligament complex (PLC) according to TL Arbeitsgemeinschaft für Osteosynthesefragen (AO) spine injury severity score (AOSIS).^[3,4]

However, AO classification did not take in consideration several factors which could be related to not satisfying results, despite the purpose to improve previous thoracolumbar injury classification and severity (TLICS) and Magerl classifications.^[5,6] Some other factors proper of the patients, such as age and body mass index (BMI), or of the fracture as level of injury and local fracture kyphosis are assumed to be potentially connected to higher operative risks and end of treatment outcomes.^[7,8]

The aim of the present study is to identify if initial local kyphosis, sagittal vertebral shape, and vertebral plate shape are the potential risk factors for posttraumatic kyphosis (PTK) at the end of conservative treatment.

MATERIALS AND METHODS

All consecutive patients treated by our institution between 2016 and 2017 for TL vertebral fracture with conservative treatment were retrospectively evaluated, while data were collected prospectively during each outpatient evaluation. Only type A3 (incomplete burst) and A4 (complete burst) vertebral fractures were included in the study. Patients suffering from osteoporosis or other metabolic bone disease, aged above 65 years old were excluded from the study. Gender, age, location of fracture, and BMI were recorded.

Patients wore a thoraco-lumbo-sacral-orthosis (TLSO) for 3 months when in standing position, with restriction of bed rest for the first 10 days as part of conservative treatment.

Radiological assessment

All patients underwent an initial X-ray in the standing position at time of trauma and after that at 1, 2, 3, and 6 months from trauma. Time of trauma and 6 months of follow-up standing X-ray were considered for the study. Initial assessment also included computed tomography (CT) scans to better identify fracture type; in case of high-energy trauma, magnetic resonance imaging was performed to exclude PLC injury. Axial CT view of the vertebral plate was analyzed to obtain

a qualitative measure of vertebral plate fragmentation. Major types were classified in three shapes (a, b, and c) according to fragment comminution and displacement similar to McCormack load-sharing classification:^[9]

- Shape a: Marginal fragments with solid central core [Figure 1a]
- Shape b: Big fragments involving vertebral plate [Figure 1b]
- Shape c: Comminution of fragments with displacement [Figure 1c].

If fracture involved both plates, the plate with the higher fragmentation and displacement was considered for the classification.

From CT sagittal view, vertebral body fractures were classified in three shapes (1, 2, and 3), according to fragment comminution:

- Shape 1: Fragmentation involving about 1/3 of vertebral body [Figure 2a]
- Shape 2: Fragmentation involving about 2/3 of vertebral body [Figure 2b]
- Shape 3: Fragmentation involving the entire vertebral body [Figure 2c].

Initial and 6 months X-ray from injury were analyzed to evaluate the region of injury and local kyphosis measured with Cobb angle. A local kyphosis $\geq 20^\circ$, despite not sufficient to describe a PTK, was considered a bad outcome.

Statistical analysis

Statistical analysis was performed through STATA13 software. Quantitative data were reported as mean \pm standard deviation. Student's *t*-test was used to evaluate the differences between injury time kyphosis and follow-up kyphosis, whereas odds ratio (OR) was used to evaluate the role of initial kyphosis $>10^\circ$, vertebral plate and sagittal fracture shape and sagittal fracture shape as a risk factor for PTK. Kruskal–Wallis test was used to evaluate the difference among vertebral shapes and final kyphosis. Fisher's exact test was used to assess the difference between each pattern of fracture and kyphosis. $P < 0.05$ was set as statistically significant.

RESULTS

Fifty-eight patients were included in the study. Demographic characteristics, fractures distribution, and cause of injury are reported in Table 1. Twenty-six patients had a TL AOSIS of 3, 30 a score of 5, 2 patients a score of 6. Mean preoperative local kyphosis was $10.5^\circ \pm 3.1^\circ$. Student's *t*-test showed a significant difference for vertebral kyphosis was

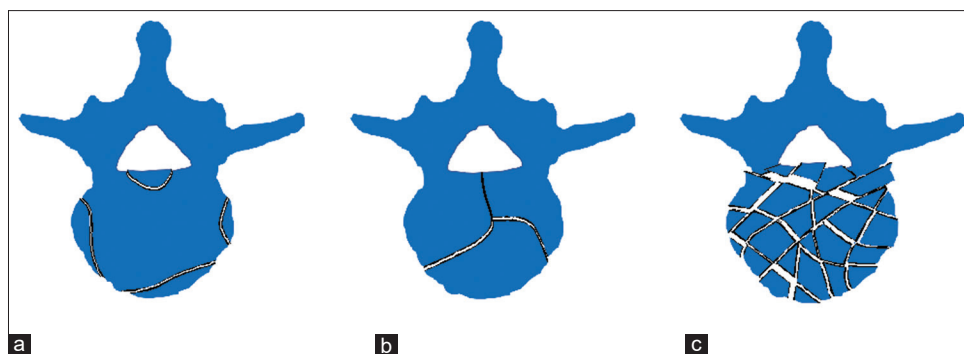


Figure 1: Drawing of different axial shape of vertebral plate fracture: (a) Marginal fragment involving vertebral plate; (b) Fracture of vertebral plate without major fragmentation and displacement; (c) Comminution of fragments with displacement

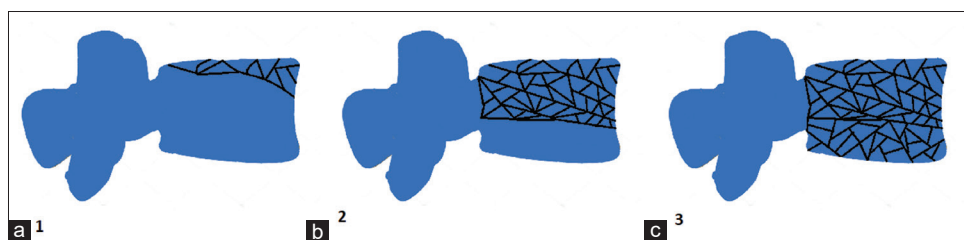


Figure 2: Drawing of different sagittal shape of the vertebral body: (a) Minor involvement, less than 1/3 of vertebral body; (b) Involvement of 2/3 of vertebral body; (c) Involvement of entire vertebral body

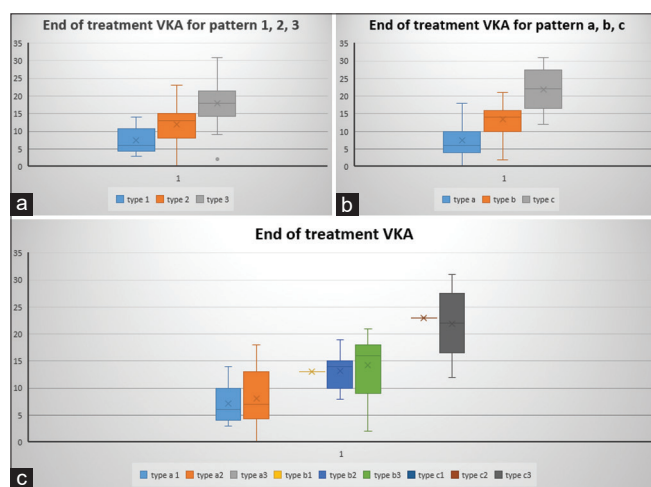


Figure 3: Distribution of different types of fracture shape and final kyphosis: (a) Distribution of fracture according to sagittal shape 1, 2, and 3; (b) Distribution of fracture according to vertebral plate shape a, b, and c; (c) Distribution of each pattern of fracture according to sagittal and axial shape a1, a2, a3, b1, b2, b3, c1, c2, and c3

found ($P = 0.0002$) between time of injury and 6 months after treatment.

Apretreatment kyphosis $>10^\circ$ was found 15/58 patients (28.9%), whereas a posttreatment kyphosis $>20^\circ$ was found in 7/58 patients (12.1%). An initial kyphosis $>10^\circ$ had an OR = 36.75 ($P = 0.0015$), axial vertebral shape had an OR = 0.08 ($P = 0.083$), shape b had an OR = 0.22 ($P = 0.175$), and shape c had an OR = 147 ($P = 0.0001$) of correlation with a posttreatment kyphosis $>20^\circ$. A sagittal vertebral shape 1

had an OR = 0.1 ($P = 0.126$), a sagittal vertebral shape 2 had an OR = 0.2 ($P = 0.153$), and a sagittal vertebral shape 3 had an OR = 32.25 ($P = 0.0025$). Kruskal–Wallis test found a statistically significant difference among axial vertebral shape a, b, and c for a final kyphosis $>20^\circ$ ($P < 0.00001$) and among sagittal vertebral shape 1, 2, and 3 ($P = 0.0004$) for a final kyphosis $>20^\circ$. Kruskal–Wallis test found a statistically significant difference among axial vertebral shape a, b, and c for a final kyphosis $>20^\circ$ ($P < 0.00001$) and among sagittal vertebral shape 1, 2, and 3 ($P = 0.0004$) for a final kyphosis $>20^\circ$ [Figure 3].

A significant difference at Fisher’s exact test was found between all types of fracture and type C3 pattern ($P = 0.0001$) for end of treatment kyphosis, while the same was not found for all other of fracture’s patterns (A1 $P = 0.083$, A2 $P = 0.577$, A3 $P = 1$, B1 $P = 1$, B2 $P = 0.173$, B3 $P = 1$, C1 $P = 1$, C2 $P = 0.121$).

Anatomical fracture distribution and rate of kyphosis $>20^\circ$ are reported in Table 2.

DISCUSSION

According to TLAOSIS score,^[3] a wide spectrum of treatments is proposed, ranging from conservative to surgical.

The aim of our research is to investigate if the factors analyzed in the results above are connected with PTK and

if we could predict this risk before the end of treatment. In this way, it is possible to decide if a burst-like fracture

Table 1: Main demographic characteristics of patients involved in the study, body mass index, affected vertebrae distribution, cause of injury, and AO type classification

Demographic characteristics	Results
Patients	58
Gender	
Male	27
Female	31
Mean age (years)	43.8±4.6
BMI (kg/m ²)	26.3±2.1
Location of injury	
L1	12
L2	13
L3	12
L4	10
L5	15
Cause of injury	
Car or motor accident	22/58
Fall from height	9/58
Pedestrian hit	2/58
Sports trauma (i.e., downhill, cycling, etc.)	21/58
Others	4/58
AO type	
26 type AO A3 (%)	
12 a1	46.16
4 a2	15.38
0 a3	0
0 b1	0
7 b2	26.92
3 b3	11.54
0 c1	0
0 c2	0
0 c3	0
32 type AO A4 (%)	
7 a1	21.87
4 a2	12.5
0 a3	0
1 b1	3.13
8 b2	25
4 b3	12.5
0 c1	0
1 c2	3.13
7 c3	21.87

BMI - Body mass index

without neurological involvement, which could be treated conservatively, is more likely to develop a PTK. Since a PTK is always very challenging for spine surgeon, the possibility to know precociously how an unstable fracture could evolve at the end of conservative treatment is very important.

Despite the use of TLSO is not recommended by any international guideline to prevent subsequent vertebral collapse,^[10] in our country their use is very extensive especially for pain control in the standing position. A possible alternative treatment is the use of cast on traction bed to reduce and contain TL vertebral fracture; however, a great dislocation of the posterior wall is a contraindication.^[11] On the other hand, surgical stabilization of unstable burst fracture with or without poly methyl methacrylate augmentation could be a valuable choice and suitable to different age of patients according to bone mineral density.^[12-16]

The chance to undertake a conservative treatment in complete and incomplete burst fracture is very important to preserve a good range of motion. After posterior stabilization even without fusion, the mobility of the spine diminishes. Chou *et al.* reported comparable clinical and radiological outcomes if implant is retained or removed, and segment range of motion did not increase after removal of the implant.^[17]

It is important to note that severity scores recommending a conservative treatment (i.e., TLICS or TL AOSIS <3) did not rule out for correction loss.^[18] As author states, some factors involving vertebral plates comminution, involvement of both endplate or entire body and amount of kyphotic deformity could interfere with bone healing process and increase the amount of kyphotic deformity at the end of treatment.

Several authors already highlighted the inadequacy of both TLICS and TL AOSIS score^[19,20] because of the lack of factors cited above, but at the same time, it must be noted that they are useful and widely used in the clinical practice. Moreover, the authors also empathized that patients with comminute

Table 2: Fracture distribution of patients recruited in the study

Vertebra	Rate on total number of fracture	Mean kyphosis at injury time (VKA)	Mean kyphosis at follow-up (VKA)	Rate of final kyphosis (VKA) > 20°
L1	11/58	7.92±4.85	11.83±6.42	2/7
L2	13/58	8.15±5.90	12.38±9.27	2/7
L3	12/58	6.92±4.54	11.08±5.88	1/7
L4	10/58	6.8±4.76	9.9±5.59	1/7
L5	11/58	8.91±2.66	13.73±5.41	1/7

We report fracture location, VKA mean±SD at injury time and follow-up and distribution of final VKA>20° at follow up. VKA - Vertebral Kyphotic angle; SD - Standard deviation

burst fractures deserve special attention, even if initially classified as nonoperative. In such cases, a close follow-up is recommended due to the high likelihood of long-term kyphotic deformity.

In this background, our research showed some interesting point of view. In fact, a patient with a complete or incomplete burst, with fragmentation of one or both vertebral plate, fragmentation and comminution of vertebral body and with an initial kyphosis $>10^\circ$ should be considered for surgical treatment since the patients have a high risk of subsequent kyphosis.

Our results showed that pattern of fracture with high fragmentation on axial and sagittal plane are more likely to develop a kyphosis at the end of treatment $>20^\circ$. For that reason, a pattern c3 should always considered unstable and worthy of surgical treatment.

We described several cumulative patterns of injury, as for the McCormack classification; however, we did not retrieve any type a3 and c1 patterns in our analysis. This could be explained by the low number of patients involved in the study but also to the energy of trauma.^[21] It seems that a high fragmentation of the vertebral plate could be related with high fragmentation of vertebral body, whereas patterns with extreme mixed type (lowest fragmentation–highest fragmentation) seem to be incompatible or at least rare.

Taking in consideration the anatomy of lumbar spine, lower segments are more likely to develop less kyphotic deformity despite fragmentation of vertebral plates and body; while upper spine seems to develop higher grade of kyphosis with less fragmented patterns. These results are related with the different biomechanics of the lumbar spine since the upper segments (L1 and L2) are part of TL junction, which is a particular spine segment where lumbar lordosis transform into thoracic kyphosis with different biomechanical load on vertebral body^[22] [Table 2].

Some limitation to this study must be acknowledged. Some of them are intrinsic to study design, such as the retrospective nature of this study and the lack of a control group. Another major limitation is the lack of clinical score to evaluate pain and functional outcomes and the short follow-up period; however, it was not the aim of this study the evaluation of clinical score of conservatively treated fractures. Moreover, a standard angular cutoff to determine what is a “PTK” is still not defined. According to the survey of Schoenfeld *et al.*, the universal definition of PTK is “a painful kyphotic angulation of the injured spine,” and about 50% of spine surgeons involved

used a specific angular measurement, although the amount of this measure varied from 5° to 30° .^[23] To avoid this problem, we decided to set the limit of tolerance for local kyphosis over 20° , which could be a reasonable bad radiological outcome.

We believe that also coronal angulation must be evaluated as the potential risk factor of conservative treatment failure. According to Deutsche Gesellschaft für Orthopädie und Unfallchirurgie (DGOU) recommendations,^[24] a coronal angulation of more than 10° could alter spine biomechanics and should act as modifier for surgery choice; however, coronal alignment was not investigated in this study.

Moreover, despite our results are very interesting, it must be noted that power analysis was not performed due to the low number of cases involve in the analysis.

CONCLUSIONS

Not all burst and incomplete burst fractures of the lumbar spine are the same; some of them are more likely to be unstable and became a PTK. A vertebral fracture with initial local kyphosis $>10^\circ$ and comminution and displacement of vertebral plate and vertebral body is at high risk to develop a local kyphosis $>20^\circ$ in the follow-up if treated conservatively.

Financial support and sponsorship

Nil.

Conflicts of interest

There are no conflicts of interest.

REFERENCES

1. Esses SI, Botsford DJ, Kostuik JP. Evaluation of surgical treatment for burst fractures. *Spine (Phila Pa 1976)* 1990;15:667-73.
2. Vaccaro AR, Oner C, Kepler CK, Dvorak M, Schnake K, Bellabarba C, *et al.* AOSpine thoracolumbar spine injury classification system: Fracture description, neurological status, and key modifiers. *Spine (Phila Pa 1976)* 2013;38:2028-37.
3. Kepler CK, Vaccaro AR, Schroeder GD, Koerner JD, Vialle LR, Aarabi B, *et al.* The thoracolumbar AOSpine injury score. *Glob Spine J* 2016;6:329-34.
4. Vaccaro AR, Schroeder GD, Kepler CK, Cumhuri Oner F, Vialle LR, Kandziora F, *et al.* The surgical algorithm for the AOSpine thoracolumbar spine injury classification system. *Eur Spine J* 2016;25:1087-94.
5. Magerl F, Aebi M, Gertzbein SD, Harms J, Nazarian S. A comprehensive classification of thoracic and lumbar injuries. *Eur Spine J* 1994;3:184-201.
6. Vaccaro AR, Lehman RA Jr., Hurlbert RJ, Anderson PA, Harris M, Hedlund R, *et al.* A new classification of thoracolumbar injuries: The importance of injury morphology, the integrity of the posterior ligamentous complex, and neurologic status. *Spine (Phila Pa 1976)* 2005;30:2325-33.
7. Descamps J, Lamerain M, Chenguel Z, Jubert P, Rousseau MA. Vertebral compression fractures treated in acute by instrumented kyphoplasty: Early and mid-term clinical and radiological results. *Biomed Res Int* 2019;2019:1-7.

8. Paik JM, Rosen HN, Katz JN, Rosner BA, Rimm EB, Gordon CM, *et al.* BMI, waist circumference, and risk of incident vertebral fracture in women. *Obesity (Silver Spring)* 2019;27:1513-9.
9. McCormack T, Karaikovic E, Gaines RW. The load sharing classification of spine fractures. *Spine (Phila Pa 1976)* 1994;19:1741-4.
10. Spiegl UJ, Fischer K, Schmidt J, Schnoor J, Delank S, Josten C, *et al.* The conservative treatment of traumatic thoracolumbar vertebral fractures. *Dtsch Arztebl Int* 2018;115:697-704.
11. Rava A, Fusini F, Cinnella P, Masse A, Girardo M. Is cast an option in the treatment of thoracolumbar vertebral fractures? *J Craniovertebr Junction Spine* 2019;10:51-6.
12. Girardo M, Rava A, Aprato A, Massè A, Fusini F. The use of percutaneous vertebral augmentation systems in osteoporotic fractures of thoracolumbar spine. *Minerva Ortop Traumatol* 2019;2:86-90. [doi: 10.23736/S0394-3410.19.03915-8].
13. Girardo M, Rava A, Coniglio A, Cinnella P, Aprato A, Massè A, Fusini F. Importance of polymethylmethacrylate augmentation in the treatment of thoracolumbar osteoporotic vertebral fractures. *Minerva Ortop Traumatol* 2019;2:65-9. [doi: 10.23736/S0394-3410.19.03920-1].
14. Girardo M, Rava A, Fusini F, Gargiulo G, Coniglio A, Cinnella P. Different pedicle osteosynthesis for thoracolumbar vertebral fractures in elderly patients. *Eur Spine J* 2018;27 Suppl 2:198-205.
15. Girardo M, Zenga F, Bruno LL, Rava A, Masse A, Maule M, *et al.* Treatment of aggressive vertebral haemangiomas with poly vinyl alcohol (PVA) microparticles embolization, PMMA and short segment stabilization. Preliminary results with at least 5 years of follow up. *World Neurosurg* 2019;128:e283-8.
16. Gargiulo G, Girardo M, Rava A, Coniglio A, Cinnella P, Massè A, *et al.* Clinical comparison between simple laminectomy and laminectomy plus posterior instrumentation in surgical treatment of cervical myelopathy. *Eur J Orthop Surg Traumatol* 2019;29:1-8.
17. Chou PH, Ma HL, Liu CL, Wang ST, Lee OK, Chang MC, *et al.* Is removal of the implants needed after fixation of burst fractures of the thoracolumbar and lumbar spine without fusion? *Bone Joint J* 2016;98B: 109-16.
18. Elzinga M, Segers M, Siebenga J, Heilbron E, de Lange-de Klerk ES, Bakker F. Inter- and intraobserver agreement on the Load Sharing Classification of thoracolumbar spine fractures. *Injury* 2012;43:416-22.
19. Mattei TA, Hanovnikian J, Dinh DH. Progressive kyphotic deformity in comminuted burst fractures treated non-operatively: The Achilles tendon of the Thoracolumbar Injury Classification and Severity Score (TLICS). *Eur Spine J* 2014;23:2255-62.
20. Piazzolla A, Solarino G, Moretti B. Letter to the Editor concerning "The surgical algorithm for the AOSpine thoracolumbar spine injury classification system" by A. R. Vaccaro *et al.* *Eur Spine J* 2016;25:1087-1094. *Eur Spine J.* 2017;26:2214-5. doi: 10.1007/s00586-017-5174-8. Epub 2017 Jun 9. PMID: 28597299.
21. Joaquim AF, Patel AA, Schroeder GD, Vaccaro AR. A simplified treatment algorithm for treating thoracic and lumbar spine trauma. *J Spinal Cord Med* 2019;42:416-22.
22. Oxland TR. Fundamental biomechanics of the spine-What we have learned in the past 25 years and future directions. *J Biomech* 2016;49:817-32.
23. Schoenfeld AJ, Wood KB, Fisher CF, Fehlings M, Oner FC, Bouchard K, *et al.* Posttraumatic kyphosis: Current state of diagnosis and treatment: Results of a multinational survey of spine trauma surgeons. *J Spinal Disord Tech* 2010;23:e1-8.
24. Verheyden AP, Spiegl UJ, Ekkerlein H, Gercek E, Hauck S, Josten C, *et al.* Treatment of fractures of the thoracolumbar spine: Recommendations of the spine section of the german society for orthopaedics and trauma (DGOU). *Global Spine J* 2018;8:34S-45.