

Received: 2010.10.27
Accepted: 2011.02.15
Published: 2012.04.01

Salvage surgery of recurrence after laryngectomy – when should the alt free flap be modified?

Authors' Contribution:

- A** Study Design
- B** Data Collection
- C** Statistical Analysis
- D** Data Interpretation
- E** Manuscript Preparation
- F** Literature Search
- G** Funds Collection

Adam Maciejewski^{A,B}, Łukasz Krakowczyk^{A,B,F}, Cezary Szymczyk^{B,G},
Janusz Wierzgoń^F, Maciej Grajek^G, Mirosław Dobrut^{G,D}, Ryszard Szumniak^G,
Piotr Jędrzejewski^{G,B}, Rafał Ulczok^A, Stanisław Półtorak^G

Department of Oncologic and Reconstructive Surgery, Centre of Oncology, M. Skłodowska-Curie Memorial Institute, Gliwice, Poland

Source of support: Departmental sources

Summary

Background:

Reconstruction of the pharynx and cervical esophagus has significantly progressed in the last 2 decades. A revolution in microvascular surgery has provided numerous choices for primary restoration, or in secondary reconstructions necessary for recurrences or complications of primary surgery. The goals of reconstruction after laryngopharyngoesophagectomy are to provide continuity of the alimentary tract, to protect major blood vessels, to heal the primary wound, and to restore the swallowing and breathing functions with minimal donor site and neck morbidity and deformation.

Case Report:

We present 3 cases with complex defects of the laryngopharynx, cervical esophagus and trachea and anterior neck skin following central neck exenteration safely reconstructed with a single anterolateral thigh flap. No postoperative complications occurred in any of the 3 cases of reconstructions, each using a single anterolateral thigh flap.

Conclusions:

This approach significantly simplified the reconstruction, with quick recovery, short hospital stay and excellent functional and aesthetic results.

key words:

pharyngoesophageal reconstruction • free flap • head and neck cancer

Full-text PDF:

<http://www.medscimonit.com/fulltxt.php?ICID=882606>

Word count:

2285

Tables:

–

Figures:

3

References:

16

Author's address:

Adam Maciejewski, Department of Oncologic Surgery, Centre of Oncology, Wybrzeże Armii Krajowej 15 St., 44-101 Gliwice, Poland, e-mail: adammac@o2.pl

BACKGROUND

The goals of reconstruction after laryngopharyngoesophagectomy are to provide continuity of the alimentary tract, to protect major blood vessels, to heal the primary wound, and to restore the swallowing and breathing functions with minimal donor site and neck morbidity and deformation. Pharyngoesophageal reconstruction remains one of the most challenging reconstructions the surgeon faces today. Postoperative complications are not rare, and functional outcome usually is not great.

Use of the ALTFL (anterolateral thigh flap) has recently been introduced for pharyngoesophageal reconstruction. The anatomical advantages made it a flap of choice in many institutions. Although other flaps, such as the jejunal, have a similar fistula and strictures rate, the ALTFL provides better swallowing and speech function. For defects extended to, for example, the oral cavity or tongue, the ALTFL is able to cover such defects with no need of a second flap [1,2].

The recurrence after total or partial laryngectomy is usually unresectable due to the uni- or bilateral major blood vessels' infiltration, posterior expansion, and/or infiltration of the mediastinum. Surgical qualification should therefore be based on careful and detailed examination with CT, MRI and endoscopy [3,4].

In some cases the recurrent tumor locates in the tracheostomy region, so the radical resection has to be extended to the upper mediastinum, making the defect much more complex and difficult to restore. In those cases the reconstruction has to deal not only with restoration of the alimentary tract, but also with the lack of a lower trachea. Moreover, the majority of advanced laryngeal cancer patients postoperatively undergo relatively high-dose radiotherapy. The anterior neck skin quality is often very poor, frozen or even damaged, so the additional goal of salvage reconstruction is to restore the cervical wall with the protection of the reconstructed esophagus and major vessels [5,6].

We present 3 cases of squamous cell cancer salvage surgery after laryngectomies where ALT flaps were modified to reconstruct complex defects.

CASE REPORT

Case no. 1 (Figure 1)

A 64-year-old male developed recurrence in the tracheostomy region, infiltrating the cervical esophagus and hypopharynx. CT scans revealed a neoplastic mass of 6×4 cm, with no major vessel invasion. The patient was operated on – resection of a recurrent tumor with 9 cm of the pharynx and esophagus, tracheostomy region, 3 cm of lower trachea

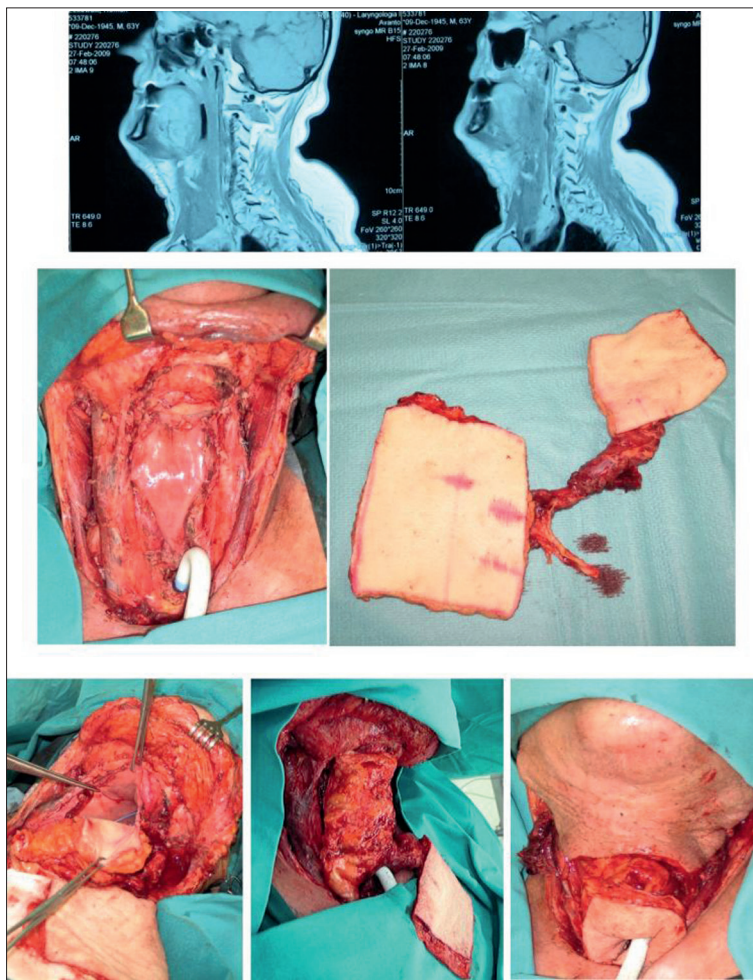


Figure 1. A 64-year-old male with recurrence in the tracheostomy region, infiltrating the cervical esophagus and hypopharynx. Reconstruction with two skin islands of left ALTFL.

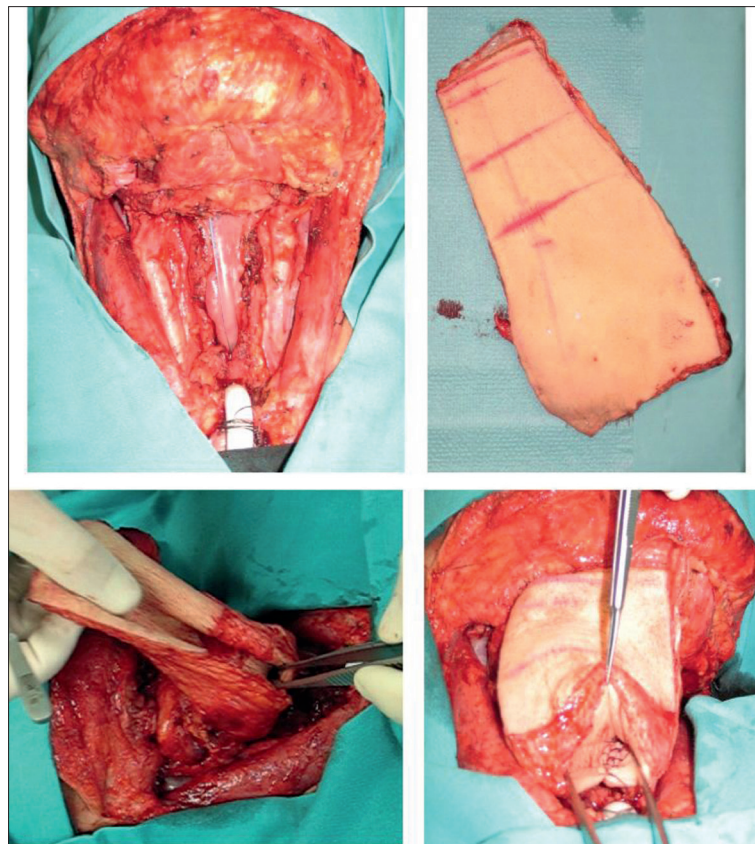


Figure 2. A 68-year-old male after laryngectomy and postoperative radiotherapy due to larynx cancer with a large defect of the anterior neck, pharynx and cervical esophagus. Reconstruction with two skin islands of ALTF.

CS

and bilateral neck nodes dissection was performed. The 2 cm width of the posterior pharyngeal wall was preserved, and the right thyroid superior artery and internal jugular vein were prepared for microanastomoses.

Simultaneously, the left ALTF was harvested, with dimensions of 12×18 cm, based on 2 cutaneous perforators. Two skin islands were designed (each on an independent perforator); the first was 12×11 cm and the second was 12×7 cm. The pedicle was cut off, the flap was transferred to the defect, and microanastomoses were performed with the right thyroid superior artery (end-to-end 9.0 nylon sutures) and the right internal jugular vein (end-to-side 10.0 nylon sutures). The first island was sutured to the remaining distal pharynx, bilateral edges of posterior pharyngeal wall, and proximal esophagus, recreating upper digestive tract continuity. For suture line protection, the fascia lata created a second layer surrounding the neopharynx and neoesophagus. The second skin island was distally sutured to the tracheal stump 3 cm below the line of the clavicles, and a tube was taken to the neck's skin surface to recreate the upper part of the trachea. The wound was closed with 2 suction drains, and a tracheostomy tube was placed through the skin tube in the trachea. No postoperative complications occurred, and the tracheal tube was taken out on the 10th postoperative day. The patient returned to an oral diet on the 14th postoperative day. Three days later he was discharged from the ward.

Case no. 2 (Figure 2)

A 68-year-old male underwent laryngectomy and postoperative radiotherapy due to larynx cancer in November 2008.

During the radiation he developed a pharyngeal fistula, and 1 month later he was referred to the Reconstructive and Microsurgery Group in Gliwice Cancer Center, with a gastric tube placed through the mediastinal esophagus and with a permanent tracheostomy. Physical examination revealed a large defect of the anterior neck – the skin (10×8 cm), pharynx and cervical esophagus – from 3 cm below the tongue base down to the tracheostomy line. The surrounding neck skin was frozen. CT and MRI showed no evidence of recurrent or distant disease. The patient was admitted to the Dept. of Oncological and Reconstructive Surgery and he was operated on in April 2009. The primary site was re-explored, refreshed, the margins were excised and their frozen sections were negative. Bilateral re lymphadenectomy of levels II–V were performed and the right transverse cervical artery and vein were prepared for microanastomoses. The length of the pharyngo-esophageal defect was 9 cm, and the skin defect was 11×9 cm. Simultaneously, a left double skin island ALTF (I – 10×11 cm, II – 10×10 cm) was designed and harvested. Unfortunately, only 1 reliable skin perforator was found; therefore the 4 cm border of 2 skin components was just deepithelialized. The flap was disconnected and transferred to the defect. End-to-end microanastomoses were performed between the pedicle and transverse cervical artery and vein with the use of 9.0 and 10.0 nylon sutures. The first (upper) skin component was sutured longitudinally to create a 4 cm width and 11 cm-long tube. Its free lumen was sutured to the proximal end of the pharynx, while the opposite flap's skin island end was sutured to the mediastinal esophagus below the tracheostomy line. The lower skin component was rolled over the reconstructed pharynx and esophagus to recreate the

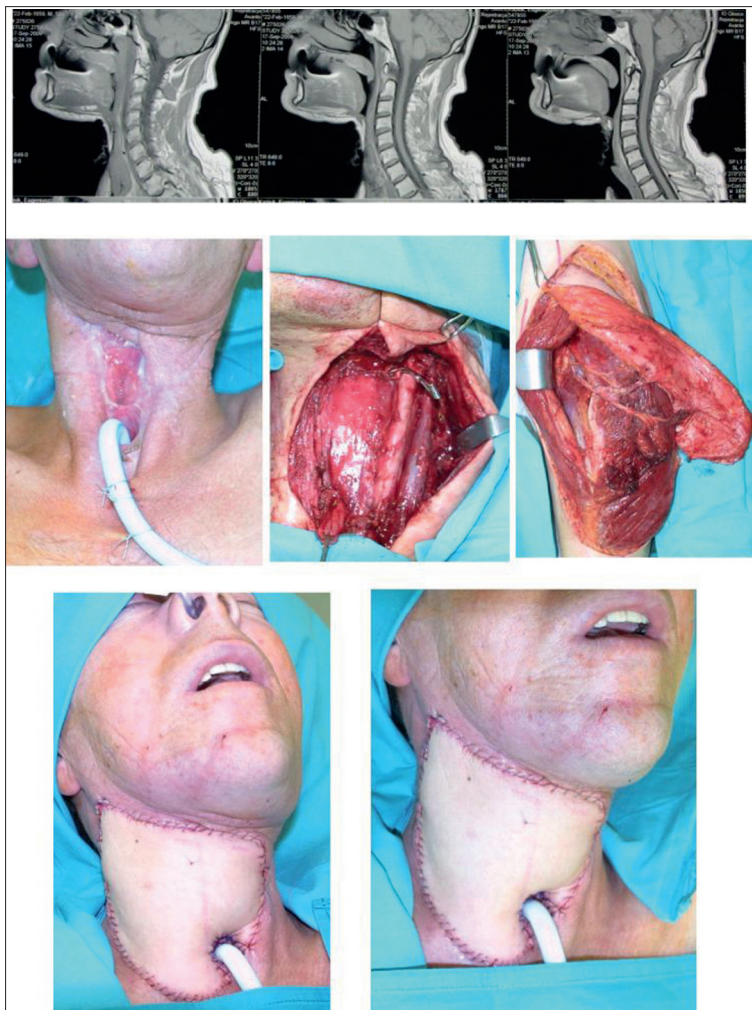


Figure 3. A 64-year-old male with complex defect of the anterior neck, hypopharynx and cervical esophagus. Reconstruction with ALT.

neck skin. Therefore, the de-epithelialized skin portion was located horizontally in front of the upper edge of the trachea. Two suction drains were placed on both sides of the neck and the wounds were closed. No postoperative complications occurred and the patient was discharged from the ward after 14 days (the gastric tube was taken out on the 11th postoperative day).

Case no. 3 (Figure 3)

A 64-year-old male was referred to the Cancer Center in Gliwice with complex defect of the anterior neck, hypopharynx and cervical esophagus. He underwent combined oncological treatment (laryngectomy, bilateral neck nodes dissection and postoperative radiotherapy) in a different hospital 18 months earlier. After radiotherapy he developed radionecrosis of the structures mentioned above. Two attempts at locoregional reconstructions were ineffective. The gastrostomy was performed, and the patient was sent to our department. A detailed examination based on CT and MRI showed no evidence of recurrent disease. In angiotomography only the right facial artery and internal jugular vein were reliable for microanastomoses. In June 2009 the patient was operated on. Necrotic neck skin with wide safe margins was excised, as well as the remaining posterior wall of the pharynx and esophagus. The skin defect measured

15×12 cm and the length of the pharyngoesophageal defect was 8 cm. The left ALT flap was design based on location of 2 skin perforators. After the flap was raised, it was divided into 2 mobile parts, each based on an independent perforator. The flap was detached from the thigh, transferred to the defect, and the pedicle was connected to the right facial artery and right jugular internal vein. The first skin island (9×7 cm) restored almost circumferential defect of alimentary tract, while the second island was able to resurface the anterior neck. Both skin components were harvested with fascia lata, therefore this ALTTF was able to create 4 layers, making this reconstruction more reliable. The wound was closed with 2 suction drains. No postoperative complications occurred. On the 14th postoperative day endoscopy and contrast X-ray showed no evidence of fistula, and when the patient returned to an oral diet the gastrostomy was removed.

DISCUSSION

Reestablishment of gastrointestinal tract continuity and normal oral alimentation are the main goals of hypopharynx and cervical esophagus reconstruction. Although the majority of patients with larynx or hypopharyngeal cancer undergo combined chemo- and radiotherapy, the surgery is usually the only treatment for locoregional recurrences.

Reconstruction of the pharynx and cervical esophagus has significantly progressed in the last 2 decades. A revolution in microvascular surgery has produced numerous options for primary restoration, or in secondary reconstructions necessary for recurrences or complications of primary surgery. Choice of a superior method from the literature is difficult, mainly because of the limited number of reports, the relative rarity of this clinical problem, and significant risk of severe complications (death, technique failure, fistula stenosis and dysphagia). Moreover, the choice of reconstructive procedure is influenced by the amount of pharynx and esophagus resected, whether the defect is circumferential or partial, and whether the defect extends to the thorax or the neck skin. For defects limited to the upper alimentary tract only, the free jejunum or radial forearm flap are the most popular options [7,8]. The main advantages of the jejunal flap is its fistula rate of below 10% and no need of longitudinal suturing to form a tube.

There have been only few comparisons between free jejunal transfers and fasciocutaneous flaps. Harii published 10 years experience in the pharyngoesophagus reconstruction, presenting 93% success with 0% mortality for jejunum and 100% success with 2.5% mortality with radial forearm flap [9]. In the opinion of many authors, different fasciocutaneous flaps such as the scapula, lateral arm or thigh, share the high success rate of the radial forearm free flap. Hayden demonstrated 97% swallowing success and flaps survival, with only 11% leak rate with the use of lateral arm free flap [10]. Li reported 95% flap survival, 15% fistula rate and 90% swallowing success rate with the ulnar forearm free flap [4].

In the opinion of Anthony and Takato, the use of the radial forearm flap allows the patient to achieve loud and soft speech, with parameters comparable to those seen in patients who do not require flap reconstruction after laryngectomy. Moreover, in their opinion the radial flap is the most successful method of reconstruction, with overall success rate between 50% and 85% [7]. Although this characteristic refers to defects limited to the pharynx and upper esophagus, a different situation appears when the resection is extended to other neck structures (eg, neck skin, mediastinal trachea). In those situations that need additional flap components or a second flap, the jejunum is not sufficient. A second free flap is usually not practical, though, due to the complex nature of reconstruction and limited availability of recipients' vessels. In the past the pedicled pectoralis major myocutaneous flap was probably the most frequently used flap for this purpose [11,12].

The advantages of the radial forearm flap are not enough to make it the flap of choice in complex and extended defects, which usually require flaps of large dimensions, where two or more skin components can be designed and harvested, like ALT flaps where the skin component is larger than in the RFFF. In Koshima's opinion, its maximum dimension is 28x18 cm, and Yildirim reports the maximum size is 26x20 cm. The ALT has all the advantages of a fasciocutaneous reconstruction over the gastric pull-up or free jejunal transfer. It is distant to the resection site and therefore not in the zone of radiotherapy, allows a 2-term approach, and does not violate the thoracic or abdominal cavities [13]. A recent comparison between free jejunum and the ALT

for the reconstruction of circumferential defects has confirmed the impression that the ALT produced improved speech and swallowing outcomes as well as shorter intensive care and hospital stays [6]. The complications after ALT reconstructions include the incidence of fistula, which rate is rather low compared to other flaps (6% vs. <10%), and strictures that usually develop several months after surgery and which are able to be treated with endoscopic balloon dilatation. Because skin over the anterolateral aspect of the thigh is supplied by septo- or musculocutaneous perforators, in the majority of flaps it allows design of double skin paddles. In cases where only 1 reliable perforator is chosen, the skin island still can be divided into 2 parts by de-epithelialization of some dermal area. This maneuver allows creation of 2 paddles connected by a subdermal bridge. The main disadvantage of this modification is that these islands are not separate with limited arc of rotation and mobilization, in comparison to 2 skin island flaps based on perforators that are separated.

Yu and all reported that speech and swallowing functions were better with use of the anterolateral thigh flap. In addition, postoperative recovery was faster, length of hospital stay was shorter, and hospital costs were significantly lower in patients who had reconstruction with ALT in comparison with jejunal free flaps. Furthermore, more patients with the jejunal flap reconstruction required readmission for various complications, mostly related to the added abdominal surgery, such as small bowel obstruction, nausea and vomiting leading to inadequate tube feeding, and subsequent fluid and electrolyte imbalance [14].

In Murray's opinion, supported by Yu, another advantage of the ALT is the ability to harvest the robust fascia, which allows a 2-layered closure, and the presence of 2 or more perforators frequently allows the ALT to be raised with separate skin paddles or in combination with a muscle flap [15,16]. Our experience supports this opinion. In the presented cases, 2 independent skin islands or a large single skin paddle of ALT divided into 2 parts by middle de-epithelialization are good choices when the surgeon has to deal not only with a pharyngoesophageal defect, but also when the defect extends into surrounding tissues.

CONCLUSIONS

The 3 presented cases demonstrate that complex defects of the laryngopharynx, cervical esophagus and trachea and anterior neck skin following central neck exenteration can be safely reconstructed with a single anterolateral thigh flap. This approach significantly simplified the reconstruction, and resulted in quick recovery, short hospital stay and excellent functional and aesthetic results.

REFERENCES:

- Farace F, Fois VE, Manconi A et al: Free anterolateral thigh flap versus free forearm flap: Functional results in oral reconstruction. *J Plast Reconstr Aesthet Surg*, 2007; 6: 583-87
- Genden EM, Jacobson AS: The role of the anterolateral thigh flap for pharyngoesophageal reconstruction. *Arch Otolaryngol Head Neck Surg*, 2005; 131: 796-99
- Nakatsuka T, Kato H, Ebihara S et al: Free forearm flap reconstruction of the posterior tracheal wall invaded by esophageal carcinoma. *J Reconstr Microsurg*, 1998; 14: 305-8

4. Li XM, Tao ZF, Song Q et al: Multi-modalities for reconstruction of circumferential defects in the pharyngoesophageal region. *Zhonghua Er Bi Yan Hou Tou Jing Wai Ke Za Zhi*, 2007; 42: 408–12
5. Anthony JP, Singer MI, Deschler DG et al: Long-term functional results after pharyngoesophageal reconstruction with the radial forearm free flap. *Am J Surg*, 1994; 168: 441–45
6. Lewis JS, Barringer DA, May AH et al.: Functional outcomes after circumferential pharyngoesophageal reconstruction. *Laryngoscope*, 2005; 115: 1266–71
7. Anthony JP, Singer MI, Mathes SJ: Pharyngoesophageal reconstruction using the tubed free radial forearm flap. *Clin Plast Surg*, 1994; 21: 137–47
8. Zhang B, Tang PZ, Xu ZG et al: Reconstruction of hypopharyngeal circumferential defects: pharyngogastric anastomosis or free jejunal interposition. *Zhonghua Er Bi Yan Hou Ke Za Zhi*, 2004; 39: 419–24
9. Harii K, Ebihara S, Ono I et al: Pharyngoesophageal reconstruction using a fabricated forearm free flap. *Plast Reconstr Surg*, 1985; 75: 463–76
10. Hayden RE, Deschler DG: Lateral thigh free flap for head and neck reconstruction. *Laryngoscope*, 1999; 109: 1490–94
11. Disa JJ, Cordeiro PG: Reconstruction of the hypopharynx and cervical esophagus. *Clin Plast Surg*, 2001; 28: 349–56
12. Scharpf J, Esclamado RM: Reconstruction with radial forearm flaps after ablative surgery for hypopharyngeal cancer. *Head Neck*, 2003; 25: 261–70
13. Koshima I, Moriguchi T, Soeda S et al: Extended latissimus dorsi musculocutaneous flaps for extremely wide cervical skin defects involving the cervical esophagus. *Ann Plast Surg*, 1992; 29: 149–52
14. Yu P, Lewin JS, Reece GP, Robb GL: Comparison of clinic and functional outcomes and hospital costs following pharyngoesophageal reconstruction with the anterolateral thigh free flap versus the jejunal flap. *Plast Reconstr Surg*, 2006; 117: 968–75
15. Murray DJ, Gilbert RW, Vesely MJ et al: Functional outcomes and donor site morbidity following circumferential pharyngoesophageal reconstruction using an anterolateral thigh flap and salivary bypass tube. *Head Neck*, 2007; 29: 147–54
16. Yu P: One-stage reconstruction of complex pharyngoesophageal, tracheal and anterior neck defects. *Plast Reconstr Surg*, 2005; 116: 949–56