



Contents lists available at ScienceDirect

# Indian Pacing and Electrophysiology Journal

journal homepage: [www.elsevier.com/locate/IPEJ](http://www.elsevier.com/locate/IPEJ)

## Multi-site multi-polar left ventricular pacing through persistent left superior vena cava in tricuspid valve disease

Ernest W. Lau

Department of Cardiology, Royal Victoria Hospital, Grosvenor Road, Belfast BT12 6BA, Northern Ireland, UK

### ARTICLE INFO

#### Article history:

Received 27 March 2017

Received in revised form

25 May 2017

Accepted 29 May 2017

Available online 30 May 2017

#### Keywords:

Multi-site pacing

Multi-polar pacing

Persistent left superior vena cava

Tricuspid valve

### ABSTRACT

Multi-site multi-polar left ventricular pacing through the coronary sinus (CS) may be preferred over endocardial right ventricular or surgical epicardial pacing in the presence of tricuspid valve disease. However, the required lead placement can be difficult through a persistent left superior vena cava (PLSVC), as the CS tends to be hugely dilated and side branches tend to have sharp angulations ( $>90^\circ$ ) when approached from the PLSVC. Pre-shaped angiography catheters and techniques used for finding venous grafts from the ascending aorta post coronary bypass surgery may help with lead placement in such a situation.

Copyright © 2017, Indian Heart Rhythm Society. Production and hosting by Elsevier B.V. This is an open access article under the CC BY-NC-ND license (<http://creativecommons.org/licenses/by-nc-nd/4.0/>).

### 1. Introduction

Reliable ventricular pacing can be achieved without involving the tricuspid valve (TV), the endocardial surface of the right ventricle (RV) or cardiac surgery by placing 2 leads into the middle cardiac vein (MCV) and another side branch of the coronary sinus (CS) [1]. However, multi-site left ventricular (LV) pacing can be challenging to achieve through a persistent left superior vena cava (PLSVC), as the CS tends to be hugely dilated, side branches tend to have sharp angulations ( $>90^\circ$ ) when approached from the PLSVC, and a lead has to change from going with the physiological direction of blood flow in the PLSVC into against the physiological direction of blood flow in the side branch [2,3]. (In contrast, a lead placed through the CS os into a side branch consistently moves against the physiological direction of blood flow.) A case of multi-site LV pacing through a PLSVC in TV disease is presented.

### 2. Case history

A 47 year old man with a PLSVC developed complete heart block after TV repair with an annuloplasty ring for severe regurgitation. Multi-site LV pacing through the CS was preferred over transvenous endocardial RV or surgical epicardial pacing. An active fixation

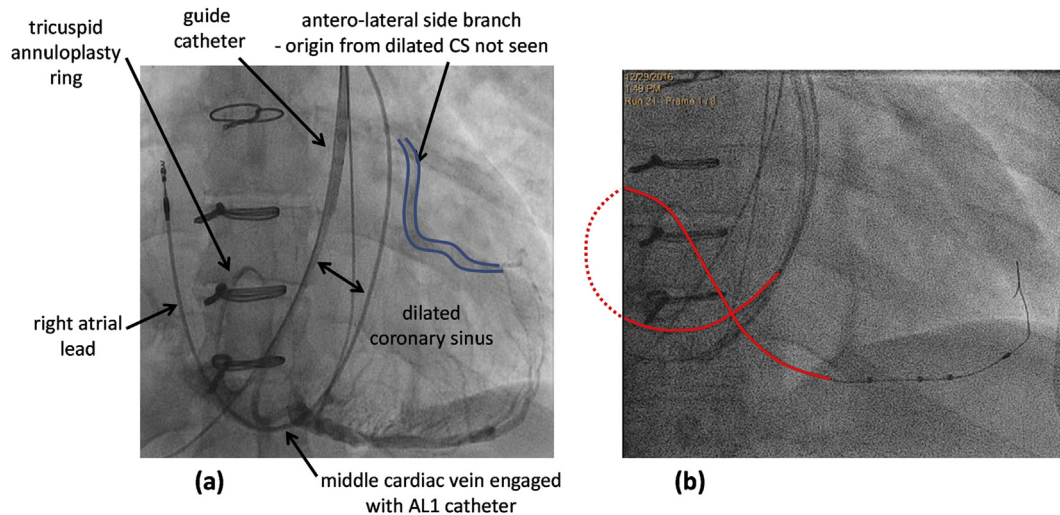
pacing lead (Tendril STS 2088TC 52cm; Abbott, Sylmar, CA, USA) was positioned through the PLSVC onto the right atrial (RA) wall without much difficulty. The CS was hugely dilated and could not be adequately opacified by direct contrast injection through the guide catheter (CPS Direct SLII DS2C003 135, Abbott). A balloon catheter passed through the PLSVC would not help as the catheter tip would be closer to the CS os than the balloon.

Through trial and error, a 5F Amplatz AL1 angiography catheter (Infiniti 534545T, Cordis, Milpitas, CA, USA) engaged the MCV. Contrast venography of the MCV outlined an antero-lateral side branch faintly through retrograde filling, but its origin from the main CS was not clearly seen (Fig. 1a). The AL1 angiography catheter was exchanged for an Amplatz AL2 sub-selection catheter (CPS AIM SL DS2N025-65, Abbott) to provide a conduit for a quadripolar LV lead (Quartet 1458Q 86cm, Abbott) into the MCV. The distal 2 electrodes could not achieve LV capture up to  $5V@0.4ms$  despite exhausting all the pacing vectors involving them. The proximal 2 electrodes achieved LV capture with a best threshold of  $1.5V@0.4ms$ . As soon as the sub-selection catheter was slit, the lead prolapsed out of the MCV. The quadripolar LV lead was repositioned, but the sub-selection catheter was slit with extra lead length continuously fed into RA. A large loop of the lead skirted around the entire RA, but its distal end stayed in the MCV (Fig. 1b).

The ostium of the antero-lateral side branch from the CS was eventually engaged with a 5F Judkins JR6 catheter (Infiniti 534525T, Cordis), after an AL1 (Infiniti 534545T), a Judkins JR4 (Infiniti 534521T) and an internal mammary (IM LBT 556-190-0L) catheters

E-mail address: [ernest.lau@btinternet.com](mailto:ernest.lau@btinternet.com).

Peer review under responsibility of Indian Heart Rhythm Society.

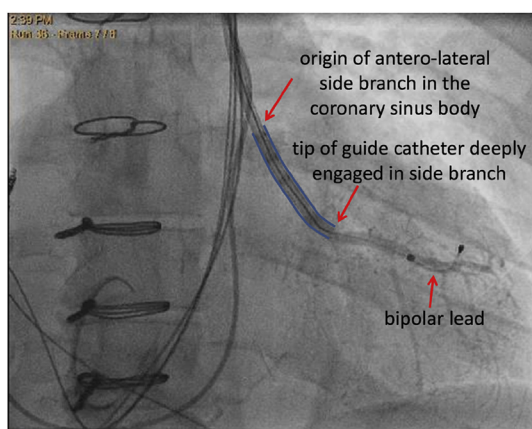


**Fig. 1.** Contrast venogram of the middle cardiac vein and lead course after slitting of sub-selection catheter. (a) The coronary sinus (CS) was hugely dilated, as reflected by the wide separation between the guide catheter and the right atrial lead. An Amplatz AL1 angiography catheter was used to engage the ostium of the middle cardiac vein (MCV). Retrograde filling from the MCV outlined an antero-lateral side branch faintly, but its origin from the main CS body was not clearly seen. (b) As soon as an Amplatz AL2 sub-selection catheter was slit, the quadripolar left ventricular lead immediately formed a large loop in the right atrium without disturbing the distal lead tip position. Any slight reduction of the loop caused the lead tip to move basally out of the MCV.

had been tried. A 0.014" angioplasty guide wire was manipulated into the side branch, providing a rail for the JR6 and then the guide catheter to follow. The JR6 catheter was taken out of the guide catheter and exchanged for a bipolar LV lead (QuickFlex  $\mu$  1258T, Abbott), which passed easily into the side branch and achieved good electrical parameters (Fig. 2). After the guide catheter was slit, the bipolar LV lead retracted to a slightly more proximal position in the side branch but remained electrically functional. The bipolar LV lead was plugged into the RV port of a cardiac resynchronisation therapy (CRT) pacemaker (Quadra Allure MP™ RF, PM3262, Abbott, Fig. 3). At 3 months follow-up, both the patient and the pacing system were doing well.

### 3. Discussion

Endocardial leads crossing the TV can damage (through stenosis

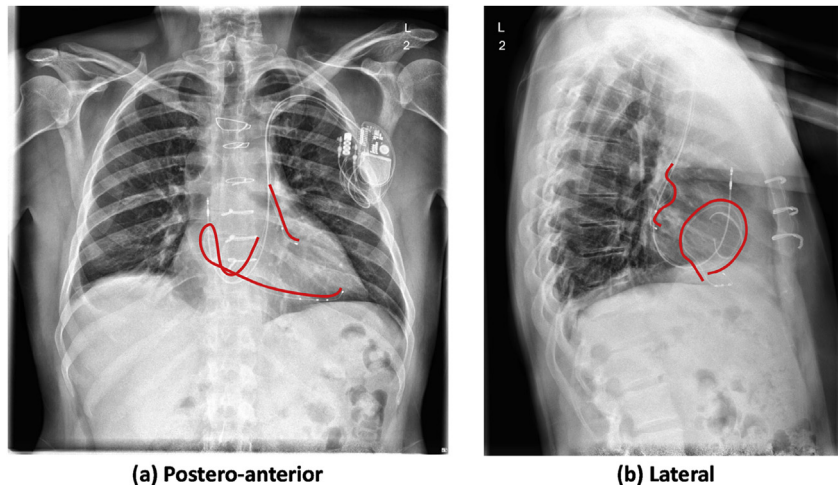


**Fig. 2.** Direct engagement of an antero-lateral side branch of the coronary sinus through persistent left superior vena cava. The origin of antero-lateral side branch from the coronary sinus was not well visualized by cross-filling from the middle cardiac vein. The side branch was only partially engaged with a Judkins JR6 catheter after trying multiple other angiography catheters. An angioplasty guide wire manipulated into the side branch provided enough support for the JR6 and then the guide catheter to enter the branch, allowing a bipolar lead to be placed within.

or regurgitation) [4–13] and be damaged by (through insulation abrasion [11,14] or conductor fracture [15]) the valve, especially after surgical correction of severe pre-existent disease [16]. Tricuspid regurgitation is more common and severe in the presence of transvenous leads, and is then associated with increased mortality [17–19]. Epicardial leads require invasive pericardial intervention or surgery for placement and may not be as reliable as endocardial leads (rising pacing threshold, insulation breach and conductor fracture) over time [20]. Transvenous epicardial LV pacing through the CS suffers less from these issues, but has its own drawbacks from lack of suitable side branches, lead dislodgement, phrenic nerve stimulation, and less reliable pacing and sensing characteristics [21,22].

Quadripolar LV leads offer many extra pacing options than bipolar LV leads [23], reducing the need for compromise among positional stability, phrenic nerve stimulation and capture threshold, and are associated with fewer complications [24–27]. In this case, the proximal 2 electrodes of the quadripolar lead in the MCV provided pacing while the distal 2 electrodes provided anchorage. If only 2 electrodes were available (as for a bipolar LV lead) and they had to serve both pacing and anchorage, the lead would very likely have dislodged. Quadripolar leads may produce extra haemodynamic and clinical benefits through multi-point pacing [28–31], but can only be used with CRT devices, which still exclusively employ the bipolar RV channel for the timing cycle. Thus a bipolar lead needs to be inserted into another side branch of the CS along with the quadripolar lead in the MCV.

The bipolar LV lead in this case retracted slightly from its intended position in the antero-lateral side branch after the guide catheter had been slit. The antero-lateral side branch was probably too short for a quadripolar lead, and its 2 most proximal electrodes would likely have stayed outside the side branch in the main CS body had it been used. An alternative strategy to solving the compromise among positional stability, phrenic nerve stimulation and capture threshold is to have an active fixation mechanism on the lead body. An early embodiment of such a design concept is a unipolar lead with deployable side loops (Attain Starfix 4195, Medtronic, Minneapolis, MN, USA), which would not be suitable in this patient as the PLSVC might be torn if the lead ever needed to be



**Fig. 3.** Chest X-rays showing bipolar and quadripolar left ventricular leads in different side branches of the coronary sinus. The left ventricular lead courses are outlined in red. The lead in the middle cardiac vein has a large hairpin loop skirting around the entire right atrium. The tricuspid annuloplasty ring can be clearly seen in the lateral view.

extracted [32]. Any tear of a PLSVC would result in very catastrophic tamponade and be very difficult to repair surgically because of its relative anatomical inaccessibility. More recent embodiments involve mounting an exposed helix sideways on the lead body: proximal to the LV2 (most proximal) electrode on the bipolar Attain Stability 20066/4796 lead [33,34], and between the LV3 and LV4 (most proximal) electrodes on the quadripolar Attain Stability Quad MRI SureScan 4798 lead (Medtronic). In contrast to the Attain Starfix lead [35], a chronic Attain Stability lead may be extracted with relative ease, with preservation of side branch patency up to 8 months post implantation [36]. The bipolar Attain Stability lead has been successfully extracted from and re-implanted in the same target vein 7 months after the initial implantation [37], and securely placed in a side branch anatomically predisposed to lead dislodgement in another case of PLSVC [38].

Multi-site multi-polar LV pacing by a CRT device may be especially suitable for patients with TV disease [1,39–44]. Selective cannulation of the individual CS side branches in the presence of a PLSVC is akin to searching for venous grafts in the ascending aorta post coronary bypass surgery, and similar skills and tools can be used. A large loop of the LV lead skirting around the entire RA may be necessary to keep its distal end in the MCV when it is placed through a PLSVC.

### Conflicts of interest

EWL consultancy for Abbott.

### References

- [1] Lau EW, McEntee T, Ashfield KB, Graham AN. Radial multi-site, longitudinal multi-polar epicardial left ventricular pacing in tricuspid valve disease. *Ulst Med J* 2016;85:193–5.
- [2] Lane RE, Chow AW, Mayet J, Davies DW. Biventricular pacing exclusively via a persistent left-sided superior vena cava: case report. *Pacing Clin Electrophysiol* 2003;26:640–2.
- [3] Steinhagen J, Meijer A, Bracke FA, van Gelder BM. Coronary sinus atresia and persistent left superior vena cava with the presence of thrombus complicating implantation of a left ventricular pacing lead. *Europace* 2008;10:384–7.
- [4] Shah BN, Bethell HW, Senior R. Pacemaker-related reversible right heart failure. *Postgrad Med J* 2013;89:486–7.
- [5] Addetia K, Maffessanti F, Mediratta A, Yamat M, Weinert L, Moss JD, et al. Impact of implantable transvenous device lead location on severity of tricuspid regurgitation. *J Am Soc Echocardiogr* 2014;27:1164–75.
- [6] Mediratta A, Addetia K, Yamat M, Moss JD, Nayak HM, Burke MC, et al. 3D echocardiographic location of implantable device leads and mechanism of associated tricuspid regurgitation. *JACC Cardiovasc Imaging* 2014;7:337–47.
- [7] Uijlings R, Kluijn J, Salomonsz R, Burgmans M, Cramer MJ. Pacemaker lead-induced severe tricuspid valve stenosis. *Circ Heart Fail* 2010;3:465–7.
- [8] Cassagneau R, Jacon P, Defaye P. Pacemaker lead-induced severe tricuspid valve stenosis: complete percutaneous extraction under extracorporeal life support. *Europace* 2013;15:1248.
- [9] Baquero GA, Yadav P, Skibba JB, Banchs JE, Linton-Frazier LN, Lengerich EJ, et al. Clinical significance of increased tricuspid valve incompetence following implantation of ventricular leads. *J Interv Card Electrophysiol* 2013;38:197–202.
- [10] Polewczyk A, Kutarski A, Tomaszewski A, Brzozowski W, Czajkowski M, Polewczyk M, et al. Lead dependent tricuspid dysfunction: analysis of the mechanism and management in patients referred for transvenous lead extraction. *Cardiol J* 2013;20:402–10.
- [11] Novak M, Dvorak P, Kamaryt P, Slana B, Lipoldova J. Autopsy and clinical context in deceased patients with implanted pacemakers and defibrillators: intracardiac findings near their leads and electrodes. *Europace* 2009;11:1510–6.
- [12] Arabi P, Ozer N, Ates AH, Yorgun H, Oto A, Aytemir K. Effects of pacemaker and implantable cardioverter defibrillator electrodes on tricuspid regurgitation and right sided heart functions. *Cardiol J* 2015;22:637–44.
- [13] Lee JH, Kim TH, Kim WS. Permanent pacemaker lead induced severe tricuspid regurgitation in patient undergoing multiple valve surgery. *Korean J Thorac Cardiovasc Surg* 2015;48:129–33.
- [14] Lau EW. External insulation breach near the tip of a single ventricular pacing lead. *J Innovations Cardiac Rhythm Manag* 2012;3:668–70.
- [15] Clarke B, Jones S, Gray HH, Rowland E. The tricuspid valve: an unusual site of endocardial pacemaker lead fracture. *Pacing Clin Electrophysiol* 1989;12:1077–9.
- [16] Hauser RG, Abdelhadi RH, McGriff DM, Kallinen RL. Failure of a novel silicone-polyurethane copolymer (Optim) to prevent implantable cardioverter-defibrillator lead insulation abrasions. *Europace* 2013;15:278–83.
- [17] Al-Bawardy R, Krishnaswamy A, Rajeswaran J, Bhargava M, Wazni O, Wilkoff B, et al. Tricuspid regurgitation and implantable devices. *Pacing Clin Electrophysiol* 2015;38:259–66.
- [18] Delling FN, Hassan ZK, Piatkowski G, Tsao CW, Rajabali A, Markson LJ, et al. Tricuspid regurgitation and mortality in patients with transvenous permanent pacemaker leads. *Am J Cardiol* 2016;117:988–92.
- [19] Chang JD, Manning WJ, Ebrille E, Zimetbaum PJ. Tricuspid valve dysfunction following pacemaker or cardioverter-defibrillator implantation. *J Am Coll Cardiol* 2017;69:2331–41.
- [20] Tomaske M, Gerritse B, Kretzers L, Pretre R, Dodge-Khatami A, Rahn M, et al. 12-year experience of bipolar steroid-eluting epicardial pacing leads in children. *Ann Thorac Surg* 2008;85:1704–11.
- [21] Lau EW. Achieving permanent left ventricular pacing-options and choice. *Pacing Clin Electrophysiol* 2009;32:1466–77.
- [22] Lau EW. Cardiac resynchronization therapy – the remaining challenges. *J Innovations Cardiac Rhythm Manag* 2012;3:747–57.
- [23] O'Donnell D, Sperzel J, Thibault B, Rinaldi CA, Pappone C, Gutleben KJ, et al. Additional electrodes on the Quartet LV lead provide more programmable pacing options than bipolar and tripolar equivalents. *Europace* 2017;19:588–95.
- [24] Mehta PA, Shetty AK, Squirrel M, Bostock J, Rinaldi CA. Elimination of phrenic nerve stimulation occurring during CRT: follow-up in patients implanted with a novel quadripolar pacing lead. *J Interv Card Electrophysiol* 2012;33:43–9.
- [25] Oswald H, Asbach S, Kobe J, Weglage H, Schulte-Pitzke B, Brachmann J. Effectiveness and reliability of selected site pacing for avoidance of phrenic

- nerve stimulation in CRT patients with quadripolar LV leads: the EffaceQ study. *Pacing Clin Electrophysiol* 2015;38:942–50.
- [26] Rijal S, Wolfe J, Rattan R, Durrani A, Althouse AD, Marroquin OC, et al. Lead related complications in quadripolar versus bipolar left ventricular leads. *Indian Pacing Electrophysiol J* 2017;17:3–7.
- [27] Turagam MK, Afzal MR, Iskander S, Madhu R, Biase LD, Natale A, et al. A meta-analysis of quadripolar versus bipolar left ventricular leads on post-procedural outcomes. *J Atr Fibrillation* 2016;9:1472. 1Sep.
- [28] Zanon F, Baracca E, Pastore G, Marcantoni L, Fraccaro C, Lanza D, et al. Multipoint pacing by a left ventricular quadripolar lead improves the acute hemodynamic response to CRT compared with conventional biventricular pacing at any site. *Heart Rhythm* 2015;12:975–81.
- [29] Pappone C, Calovic Z, Vicedomini G, Cuko A, McSpadden LC, Ryu K, et al. Improving cardiac resynchronization therapy response with multipoint left ventricular pacing: twelve-month follow-up study. *Heart Rhythm* 2015;12:1250–8.
- [30] Menardi E, Ballari GP, Goletto C, Rossetti G, Vado A. Characterization of ventricular activation pattern and acute hemodynamics during multipoint left ventricular pacing. *Heart Rhythm* 2015;12:1762–9.
- [31] Pappone C, Calovic Z, Vicedomini G, Cuko A, McSpadden LC, Ryu K, et al. Multipoint left ventricular pacing in a single coronary sinus branch improves mid-term echocardiographic and clinical response to cardiac resynchronization therapy. *J Cardiovasc Electrophysiol* 2015;26:58–63.
- [32] Maytin M, Carrillo RG, Baltodano P, Schaerf RH, Bongiorno MG, Di CA, et al. Multicenter experience with transvenous lead extraction of active fixation coronary sinus leads. *Pacing Clin Electrophysiol* 2012;35:641–7.
- [33] Johar S, Luqman N. Early experience with attain stability, an activefixation LV lead: virtues and pitfalls. *Pacing Clin Electrophysiol* 2015;38:297–301.
- [34] Yee R, Gadler F, Hussin A, Bin OR, Khaykin Y, Verma A, et al. Novel active fixation mechanism permits precise placement of a left ventricular lead: early results from a multicenter clinical study. *Heart Rhythm* 2014;11:1150–5.
- [35] Cronin EM, Ingelmo CP, Rickard J, Wazni OM, Martin DO, Wilkoff BL, et al. Active fixation mechanism complicates coronary sinus lead extraction and limits subsequent reimplantation targets. *J Interv Card Electrophysiol* 2013;36:81–6.
- [36] Bontempi L, Vassanelli F, Ashofair N, Inama L, Mariggio D, Cerini M, et al. The novel active fixation coronary sinus lead: efficacy and safety of transvenous extraction procedure. *Europace* 2016;18:301–3.
- [37] Ziacchi M, Diemberger I, Martignani C, Boriani G, Biffi M. New left ventricular active fixation lead: The experience of lead extraction. *Indian Heart J* 2015;67 Suppl 3:S97-9. <http://dx.doi.org/10.1016/j.ihj.2015.10.379>. Epub;2015 Dec 18.:S97-S99.
- [38] Biffi M, Massaro G, Diemberger I, Martignani C, Corzani A, Ziacchi M. Cardiac resynchronization therapy in persistent left superior vena cava: can you do it two-leads-only? *Hear Case Rep* 2017;3:30–2.
- [39] Grimard C, Clementy N, Fauchier L, Babuty D. Ventricular pacing through coronary sinus in patients with tricuspid prosthesis. *Ann Thorac Surg* 2010;89:e51–2.
- [40] Bos HS, Pop GA, Stel EA, van Gelder BM. Dual site coronary sinus pacing in a patient with an artificial tricuspid valve prosthesis. *Pacing Clin Electrophysiol* 2004;27:1451–2.
- [41] Nguyen LS, Swaroop S, Prejean CA. Pacing in the middle cardiac vein in a patient with tricuspid prosthesis. *Pacing Clin Electrophysiol* 2002;25:243–4.
- [42] Herre JM, Bullaboy CA, Derkac WM, Dow MT. Permanent transvenous dual-chamber pacing using the coronary sinus in a patient with a mechanical prosthetic tricuspid valve. *Pediatr Cardiol* 2004;25:65–6.
- [43] Padeletti L, Colella A, Michelucci A, Pieragnoli P, Ricciardi G, Porciani MC, et al. Dual-site left ventricular cardiac resynchronization therapy. *Am J Cardiol* 2008;102:1687–92.
- [44] Sohal M, Shetty A, Niederer S, Lee A, Chen Z, Jackson T, et al. Mechanistic insights into the benefits of multisite pacing in cardiac resynchronization therapy: the importance of electrical substrate and rate of left ventricular activation. *Heart Rhythm* 2015;12:2449–57.