

Contrast-induced Hyperemia as an Alternative to Drug-induced Hyperemia in the Evaluation of the Fractional Flow Reserve in Coronary Lesions

Nobuo Shiode¹, Tomokazu Okimoto², Hiromichi Tamekiyo², Tomoharu Kawase², Kenichi Yamane², Yuzo Kagawa², Yuto Fujii², Yusuke Ueda², Naoya Hironobe², Yasuko Kato² and Yasuhiko Hayashi²

Abstract

Objective Measuring the fractional flow reserve (FFR) requires the induction of coronary hyperemia, usually with adenosine, adenosine triphosphate (ATP), or papaverine. However, adenosine can induce rhythmic complications, and intracoronary boluses of papaverine that prolong the QT interval can cause ventricular tachycardia. Injection of contrast media, which is routinely performed to validate the FFR guidewire placement, also induces hyperemia and may be an alternative method of measuring the FFR. We evaluated the diagnostic accuracy of the FFR after contrast hyperemia (FFRcont) compared to FFR evaluated after intracoronary papaverine (FFRpp).

Methods This study included 109 lesions in 93 patients (mean age 70.4±8.7 years) with stable coronary disease. The FFR was measured as follows: 1) baseline pressure value; 2) FFRcont after intracoronary contrast injection (iopamidol, 8 mL for left coronary artery [LCA] or 6 mL for right coronary artery [RCA]); 3) FFRpp after intracoronary injection of papaverine (12 mg for LCA or 8 mg for RCA).

Results FFRcont values were strongly correlated with FFRpp ($R=0.940$, $p<0.0001$; $FFRpp = FFRcont \times 1.007-0.032$). The best cut-off point in the receiver operator curve analysis for predicting a $FFRpp < 0.80$ was 0.82 (area under the curve =0.980; sensitivity 95.1%, specificity 91.2%, positive predictive value 86.7%, negative predictive value 96.9%).

Conclusion FFRcont is highly accurate for predicting FFRpp. An FFRcont threshold value of 0.82 provides excellent sensitivity and a negative predictive value. FFRcont is an alternative method of inducing hyperemia.

Key words: hyperemia, contrast, fractional flow reserve, papaverine

(Intern Med 56: 253-257, 2017)

(DOI: 10.2169/internalmedicine.56.7602)

Introduction

The fundamental limitations of coronary angiography and its poor correlation with the severity of functional stenosis in terms of blood flow are well recognized (1). Fractional flow reserve (FFR) is an accurate invasive index in the catheterization laboratory for determining whether or not an angiographically equivocal stenosis is of functional signifi-

cance (2). Recent randomized trials assessing the value of FFR-guided percutaneous coronary intervention have demonstrated reduced rates of major adverse cardiac events, mainly due to a decreased need for repeat revascularization (3, 4). These results have led to changes in practice guidelines. The use of FFR is recommended for assessing lesions of intermediate severity (5, 6). For the measurement of the FFR in humans, some drugs are currently used to produce maximal coronary hyperemia, such as intracoronary

¹Department of Cardiology, Hiroshima City Hiroshima Citizens Hospital, Japan and ²Division of Cardiology, Cardiovascular Center, Akane Foundation Tsuchiya General Hospital, Japan

Received for publication April 18, 2016; Accepted for publication June 6, 2016

Correspondence to Dr. Nobuo Shiode, nobucode.0317@kfd.biglobe.ne.jp

Table 1. Patients' Characteristics.

Patients		N=93
age (years)		70.4±8.7
Male (%)		68(73.1)
Cardiac Status		
	Stable Angina	83
	Previous MI	10
Risk Factors		
	Hypertension	73
	Dyslipidemia	54
	Diabetes	35
	(Insulin)	6
	(Oral Medication)	26
	Smoking	24
	Hemodialysis	12
non Hemodialysis Patients		N=81
	Cr (mg/dL)	0.81±0.20
	eGFR (mL/min/1.73m ²)	68.9±18.0

Table 2. Lesions' Characteristics.

Lesions		N=109
Lesion Location		
	LAD	83
	LCx	3
	RCA	23
QCA data		
	Lesion Length (mm)	9.5±5.4
	RVD (mm)	2.64±0.63
	MLD (mm)	1.34±0.50
	% stenosis	49.0±16.2

LAD: left anterior descending artery, LCx: left circumflex artery, RCA: right coronary artery, RVD: reference vessel diameter, MLD: minimum lesion diameter

bolus of papaverine or intravenous infusion of adenosine or adenosine triphosphate (ATP) (7-9). However, intracoronary boluses of papaverine prolong the QT interval and can cause polymorphous ventricular tachycardia. In some patients, the arterial pressure falls during intravenous infusion rates, causing submaximal coronary dilatation with adenosine or ATP (8, 9). Injection of contrast media, routinely performed to validate FFR guidewire placement, also induces hyperemia and may be an alternative method of measuring the FFR (10). We evaluated the diagnostic accuracy of the FFR after contrast hyperemia (FFR_{cont}) compared to the FFR evaluated after intracoronary papaverine (FFR_{pp}).

Materials and Methods

Patients

Ninety-three patients with mild or moderate coronary stenosis undergoing coronary angiography were selected for this study. The patients' characteristics are shown in Table 1. Written informed consent was obtained from all patients prior to the coronary angiography, and this study protocol was approved by the ethics committee of Tsuchiya General Hospital.

Study design

Diagnostic coronary angiography was performed through a standard percutaneous radial or femoral arterial approach. After vascular access had been obtained, 3,000 units of heparin were given intravenously. A 6F guide catheter was introduced into the left or right coronary arteries. The FFR was measured with a coronary pressure guide wire (Verrata guide wire; Volcano Corporation, San Diego, CA, USA) as follows: 1) baseline pressure value; 2) FFR_{cont} (Iopamidol, 8 mL for left coronary artery [LCA] or 6 mL for right coronary artery [RCA]); 3) FFR_{pp} (12 mg for LCA or 8 mg for RCA). The FFR, electrocardiogram findings, and arterial

blood pressure were recorded until the FFR value returned to baseline value. The duration of hyperemia after contrast media was short, so the FFR_{cont} was measured just after flushing of the guiding catheter with saline following intracoronary injection of contrast media.

Quantitative coronary angiography (QCA) analysis

The results from the single most severe view were recorded. Lesion length, minimum lumen diameter (MLD), reference vessel diameter (RVD) and percent diameter stenosis (%DS) were analyzed using a computerized, automated, edge detection algorithm (Philips Medical System, Best, The Netherlands), as previously described (11).

Statistical analysis

Continuous variables were expressed as mean ± standard deviation (SD) and compared using the paired t-test. The performance of FFR_{cont} in predicting a positive FFR (< 0.80) was assessed using sensitivity, specificity, positive predictive value (PPV), negative predictive value (NPV), and diagnostic accuracy, together with their 95% confidence intervals (CIs). Agreement between the studied indices was evaluated by Bland-Altman plots with 95% limits of agreement. The receiver operating characteristic (ROC) curve was used to measure the accuracy of the test (area under the ROC curve, AUC) and identify the FFR_{cont} optimal cut-off corresponding to FFR < 0.80.

Results

Patients and lesion characteristics

The patients' characteristics are summarized in Table 1. Ten patients had a history of myocardial infarction. Twelve patients had end-stage renal dysfunction and were on hemodialysis. The mean ± SD creatinine value of non-hemodialysis patients was 0.81±0.20 mg/dL. The lesion characteristics are summarized in Table 2. Eighty-three, 3, and 23 lesions were located in the left anterior descending coronary artery (LAD), left circumflex coronary artery

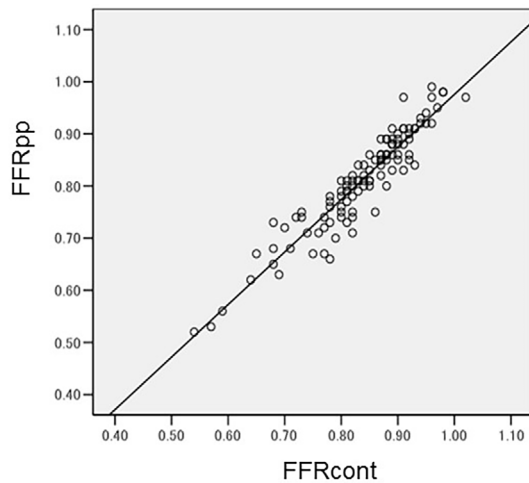


Figure 1. The correlation between FFRcont and FFRpp. The correlation of FFRcont and FFRpp was $r=0.940$ ($p<0.0001$, $FFR_{pp}=FFR_{cont}\times 1.007-0.032$).

(LCx), and RCA, respectively. The mean % stenosis was $49.0\pm 16.2\%$.

Correlation between FFRcont and FFRpp

The FFRcont correlated strongly with the FFRpp, with a correlation of $r=0.940$ ($p<0.0001$, $FFR_{pp} = FFR_{cont} \times 1.007-0.032$) (Fig. 1) and a close agreement between the two indices in a Bland-Altman analysis (95% limits of agreement from -0.0385 to 0.0896) (Fig. 2). The best cut-off point in the ROC curve analysis for predicting an $FFR_{pp} < 0.80$ was 0.82 (AUC 0.980 ; 95% CI $0.961-1.000$, $p<0.001$) (Fig. 3). The sensitivity, specificity, positive predictive value, and negative predictive value were 95.1% , 91.2% , 86.7% , and 96.9% , respectively.

Hemodynamics

The systolic and diastolic blood pressure significantly decreased both after contrast and papaverine injection. The heart rate significantly decreased after contrast injection but increased after papaverine. The degree of change in the blood pressure and heart rate was significantly larger after papaverine than after contrast injection (Table 3).

Discussion

The FFR strongly influences the treatment decisions for coronary artery lesions of patients in routine clinical practice (12, 13). Furthermore, FFR-guided percutaneous coronary intervention has been proven to be superior to angiography-guided procedures with respect to long-term clinical outcomes and is recommended by the European Society of Cardiology and the American Heart Association (5, 6).

Adenosine or ATP use is usually uneventful and safe in most patients, particularly when the intracoronary route is used (8, 9). However, many catheterization laboratories use intravenous adenosine or ATP, which comes with a risk of

side effects such as hypotension or chest discomfort and is contraindicated in patients with asthma and severe chronic obstructive pulmonary disease. In addition, intracoronary boluses of papaverine prolong the QT interval and can cause polymorphous ventricular tachycardia (7). Fortunately, in the present study, no patients had serious arrhythmic side effects like ventricular tachycardia, but QT prolongation was observed in all of the patients after papaverine injection. The systolic blood pressure, diastolic blood pressure, and heart rate significantly changed both after contrast and papaverine injection. However, the degree of hemodynamic change was significantly less after contrast injection than after papaverine injection. These findings suggest that, in clinical practice, contrast-induced FFR is safe even in patients with poor left ventricular function.

The FFRcont values were strongly correlated with the FFRpp. The optimum cut-off point was 0.82 , and the negative predictive value was 96.9% . Our study showed that contrast-induced FFR is reproducible and is highly correlated with FFR. Therefore, in clinical practice, the lesions can be deferred if the FFRcont is more than 0.82 . In addition, during coronary intervention procedures, the endpoint of the procedure can be evaluated simultaneously based on the FFRcont and coronary angiography findings. Such a treatment approach might become acceptable in clinical practice.

The recovery time from hyperemia with contrast was shorter than with papaverine. Spagnoli et al. reported that the mean recovery time from hyperemia with nonionic iso-osmolar contrast iodixanol (Visipaque 270 mg/mL) 10 mg was 12.6 ± 0.95 seconds (14). Performing FFR measurement with contrast-induced coronary hyperemia is therefore not considered to be suitable for the functional assessment of tandem lesions using the pull-back method.

Several investigators have reported the relationship between conventional FFR and contrast-induced FFR (14-16). Kanaji et al. found that the value of standard FFR was 0.03 higher than by contrast-induced FFR, and the optimal cut-off value for $FFR \leq 0.80$ calculated from the ROC curve analysis was 0.76 . Leon et al. reported that an ROC curve analysis showed an excellent accuracy in predicting an FFR value ≤ 0.80 using a contrast-induced FFR cut-off of ≤ 0.83 . Other reports have also shown a strong correlation between conventional FFR and contrast-induced FFR. However, the cut-off values in predicting an FFR value < 0.80 were slightly different across these studies, possibly due to the volume or type of the contrast media, or the manner of hyperemia for conventional FFR measurement. For example, Leon et al. used 6 mL of nonionic low-osmolar contrast medium iomeprol for contrast-induced FFR and intracoronary or intravenous administration of adenosine for conventional FFR; Kanaji et al. used 6 mL of iomeprol400 and intravenous administration of ATP; and Spagnoli et al. used 10 mL of nonionic iso-osmolar contrast iodixanol and intracoronary administration of adenosine. Therefore, the contrast-induced FFR protocol was slightly different in the previous studies,

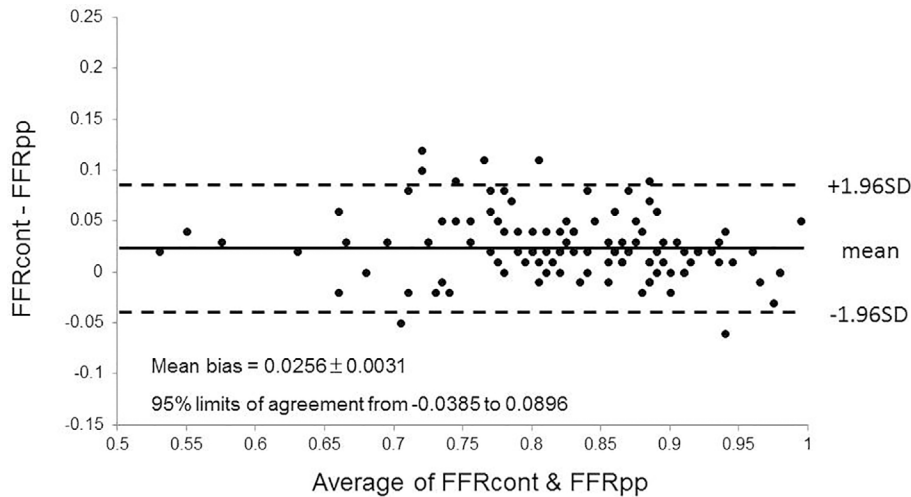


Figure 2. Bland-Altman plots of the differences in the means for FFRcont. The mean bias is represented by a solid line; the 95% confidence interval is represented by a dashed line.

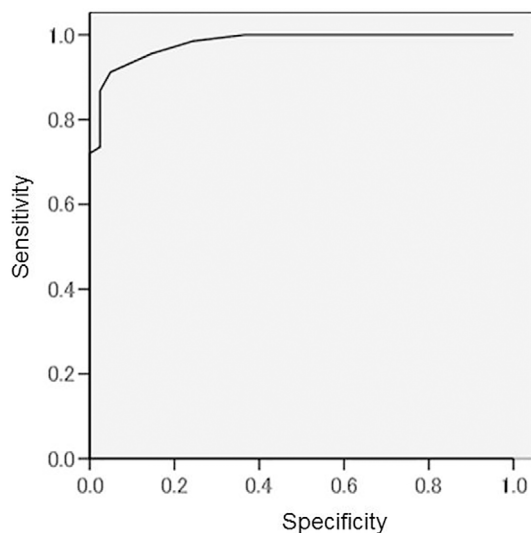


Figure 3. Receiver operator curve (ROC) analysis for predicting FFRpp < 0.08 (AUC 0.980; 95% CI 0.961-1.000 p < 0.001).

which may have affected the findings.

Contrast media induces a significant increase in the coronary blood flow due to vasodilation. The intracoronary administration of contrast media results in nearly instantaneous contact of contrast media with myocardial cells, causing transient ischemia with a metabolic stimulus provoking a transient increase in coronary blood flow (17). The viscosity of the contrast media differs among iopamidol, iomeprol and iodixanol (9.1, 13.6, and 5.8 mPa.s, respectively). Highly viscous contrast media can induce massive perturbations in the microcirculation and ischemia (18). Therefore, the hyperemic response may differ according to the degree of contrast media viscosity, leading to different contrast-induced FFR cut-off values for predicting FFR < 0.80.

Further studies on the contrast-induced FFR are needed to confirm the present findings and determine the cut-off value. Nevertheless, we expect that our data will prove useful in

Table 3. Hemodynamic Change.

	baseline	contrast	papaverine
sys BP (mmHg)	133±21	130±20*	122±18*
dia BP (mmHg)	68±10	66±9*	62±9*
HR (beats/min)	72±11	70±11*	75±11*
Δ sys BP (mmHg)		3.3±6.5	10.9±10.9**
Δ dia BP (mmHg)		2.1±5.1	6.3±7.0**
Δ HR (beats/min)		1.6±3.6	3.8±5.4**

*p < 0.01 vs. baseline, **p < 0.01 vs. contrast,

sys BP: systolic blood pressure, dia BP: diastolic blood pressure, HR: heart rate

clinical practice.

Conclusion

The contrast-induced FFR is highly accurate for predicting the papaverine-induced FFR. A contrast-induced FFR threshold value of 0.82 provides excellent sensitivity and a negative predictive value. The contrast-induced FFR might be an alternative method for evaluating the function of coronary artery lesions in clinical practice.

The authors state that they have no Conflict of Interest (COI).

References

- Whittle CW, Wright CB, Doty DB, et al. Does visual interpretation of the coronary arteriogram predict the physiologic importance of a coronary stenosis? *N Engl J Med* **310**: 819-824, 1984.
- Pijls NH, De Bruyne B, Peels K, et al. Measurement of fractional flow reserve to assess the functional severity of coronary-artery stenoses. *N Engl J Med* **334**: 1703-1708, 1996.
- Tonino PA, De Bruyne B, Pijls NH, et al. FAME Study Investigators; FAME Study Investigators. Fractional flow reserve versus angiography for guiding percutaneous coronary intervention. *N Engl J Med* **360**: 213-224, 2009.
- De Bruyne B, Pijls NH, Kalesan B, et al; FAME 2 Trial Investiga-

- tors. Fractional flow reserve-guided PCI versus medical therapy in stable coronary disease. *N Engl J Med* **367**: 991-1001, 2012.
5. Montalescot G, Sechtem U, Achenbach S, et al; Task Force Members. 2013 ESC guidelines on the management of stable coronary artery disease: the Task Force on the management of stable coronary artery disease of the European Society of Cardiology. *Eur Heart J* **34**: 2949-3003, 2013.
 6. Patel MR, Dehmer GJ, Hirshfeld JW, Smith PK, Spertus JA. ACCF/SCAI/STS/AATS/AHA/ASNC/HFSA/SCCT 2012 appropriate use criteria for coronary revascularization focused update: a report of the American College of Cardiology Foundation Appropriate Use Criteria Task Force, Society for Cardiovascular Angiography and Interventions, Society of Thoracic Surgeons, American Association for Thoracic Surgery, American Heart Association, American Society of Nuclear Cardiology, and the Society of Cardiovascular Computed Tomography. *J Am Coll Cardiol* **59**: 857-881, 2012.
 7. Wilson RF, White CW. Serious ventricular dysrhythmias after intracoronary papaverine. *Am J Cardiol* **62**: 1301-1302, 1988.
 8. Wilson RF, Wyche K, Christensen BV, Zimmer S, Laxson DD. Effects of adenosine on human coronary arterial circulation. *Circulation* **82**: 1595-1606, 1990.
 9. Shiode N, Kato M, Nakayama K, et al. Effect of adenosine triphosphate on human coronary circulation. *Intern Med* **37**: 818-825, 1998.
 10. Drobinski G, Montalescot G, Moussallem N, Canny M, Grosgeat Y. Coronary blood flow reserve measured by contrast media injection depends on myocardial viability. *Eur Heart J* **12**: 44-49, 1991.
 11. van der Zwet PM, Pinto IM, Serruys PW, Reiber JH. A new approach for the automated definition of path lines in digitized coronary angiograms. *Int J Card Imaging* **5**: 75-83, 1990.
 12. Silber S, Albertsson P, Avilés FF, et al. Guidelines for percutaneous coronary interventions. Task Force for Percutaneous Coronary Interventions of the European Society of Cardiology. *Eur Heart J* **26**: 804-847, 2005.
 13. Xu B, Whitbourn R, Wilson A, et al. Clinical impact of fractional flow reserve in a real-world cohort of patients. *Int J Cardiol* **172**: 251-252, 2014.
 14. Spagnoli V, Amabile N, Dillinger JG, et al. Myocardial fractional flow reserve measurement using contrast media as a first-line assessment of coronary lesions in current practice. *Can J Cardiol* **32**: 739-746, 2016.
 15. Kanaji Y, Murai T, Lee T, et al. Efficacy of pressure parameters obtained during contrast medium-induced submaximal hyperemia in the functional assessment of intermediate coronary stenosis. *Int J Cardiol* **202**: 207-213, 2016.
 16. Leone AM, Scalone G, De Maria GL, et al. Efficacy of contrast medium induced Pd/Pa ratio in predicting functional significance of intermediate coronary artery stenosis assessed by fractional flow reserve: insights from the RINASCI study. *EuroIntervention* **11**: 421-427, 2015.
 17. Higgins CB. Contrast media in cardiovascular system. (6)coronary circulation. In: *Radio Contrast Agents*. Sorak M, Ed. Springer-Verlag, Berlin, 1982: 238-240.
 18. Jung F, Mrowietz C, Gerk U, Franke RP. Influence of a radiographic contrast media (Iopentol) with different viscosities on capillary perfusion in patients with coronary artery disease. *Clin Hemorheol Microcirc* **53**: 201-208, 2013.

The Internal Medicine is an Open Access article distributed under the Creative Commons Attribution-NonCommercial-NoDerivatives 4.0 International License. To view the details of this license, please visit (<https://creativecommons.org/licenses/by-nc-nd/4.0/>).