

# Management of neovascular glaucoma with intravitreal ranibizumab, panretinal photocoagulation, and subsequent 5-fluorouracil augmented trabeculectomy

## A case report

Xinyue Zhao, MD, Zhi Wang, MD, Xiaobo Yang, MD\*

### Abstract

**Rationale:** Neovascular glaucoma (NVG) is one of the most refractory types of glaucoma caused by high ischemic retinal disorders, resulting in severe visual loss. Intravitreal injections of ranibizumab have been reported to have anatomical and functional success in treating NVG.

**Patient concerns-Diagnoses-Interventions:** We report a case with neovascular glaucoma due to central retinal vein occlusion who received combination therapy with intravitreal ranibizumab (IVR) injection, panretinal photocoagulation (PRP) and subsequent 5-fluorouracil (5-FU) augmented trabeculectomy.

**Outcomes:** One week after IVR injection, the intraocular pressure (IOP) had partially decreased to 33 mmHg, and there was a complete regression of neovascularization of the iris (NVI) and the angle (NVA). PRP was feasible after IVR due to improvement of corneal edema which made an adequate view of the posterior pole of fundus. The surgery of trabeculectomy with 5-FU was performed 2 weeks after IVR to control the IOP. The intraoperative and postoperative courses were uneventful without any adverse complication. Post trabeculectomy, his vision remained stable and the IOP was in the range of 4-15 mmHg without topical antiglaucoma medications. A functioning bleb was maintained and there was no recurrence of NVI and NVA during the complete follow-up period of 6 months.

**Lessons:** Combined treatment of IVR, PRP, and subsequent 5-FU augmented trabeculectomy is demonstrated to be a possible new paradigm for the management of advanced NVG with angle closure and intractable elevation of IOP.

**Abbreviations:** CRVO = central retinal vein occlusion, 5-FU = 5-fluorouracil, IOP = intraocular pressure, IVR = intravitreal ranibizumab, MMC = mitomycin C, NVA = neovascularization of the angle, NVG = neovascular glaucoma, NVI = neovascularization of the iris, PRP = panretinal photocoagulation, VEGF = vascular endothelial growth factor.

**Keywords:** intravitreal ranibizumab, neovascular glaucoma, trabeculectomy, vascular endothelial growth factor

## 1. Introduction

Neovascular glaucoma (NVG) is one of the most refractory types of secondary glaucoma commonly caused by high ischemic retinal disorders such as proliferative diabetic retinopathy and central retinal vein occlusion (CRVO). NVG is typically

characterized by the formation of neovascularization of the iris (NVI) and the anterior chamber angle (NVA) with eventual angle closure and intractable elevation of intraocular pressure (IOP). In managing NVG, it is important to treat underlying ischemic diseases responsible for NVI in addition to the elevated IOP.<sup>[1]</sup> Vascular endothelial growth factor (VEGF) is the key angiogenic factor in the pathogenesis of NVI. Furthermore, VEGF also mediates the fibroblast proliferation and scar formation after glaucoma filtration surgery.<sup>[2,3]</sup> Therefore, anti-VEGF antibody may serve as a useful adjunctive to the therapy of NVG via its antiangiogenic and antifibroblastic properties.

Currently, there are 3 main anti-VEGF antibodies, bevacizumab, ranibizumab, and aflibercept used in therapy. Several reports have recently documented the role of anti-VEGF in the treatment of NVG, almost concerned with the use of bevacizumab whereas investigations of ranibizumab and aflibercept in treating NVG are relatively rare. Comparison with bevacizumab, ranibizumab has increased potency, enhanced tissue penetration and lower possibility of cytotoxicity.<sup>[2]</sup> In addition, ranibizumab is approved by the USFDA and is formulated for intraocular injection. These advantages have increased the appeal of ranibizumab in the treatment of NVG. This case report, to the best of our knowledge, demonstrates for the first time the

Editor: Satyabrata Pany.

The authors have no funding and conflicts of interest to disclose.

Department of Ophthalmology, Union Hospital, Tongji Medical College, Huazhong University of Science and Technology, Wuhan, China.

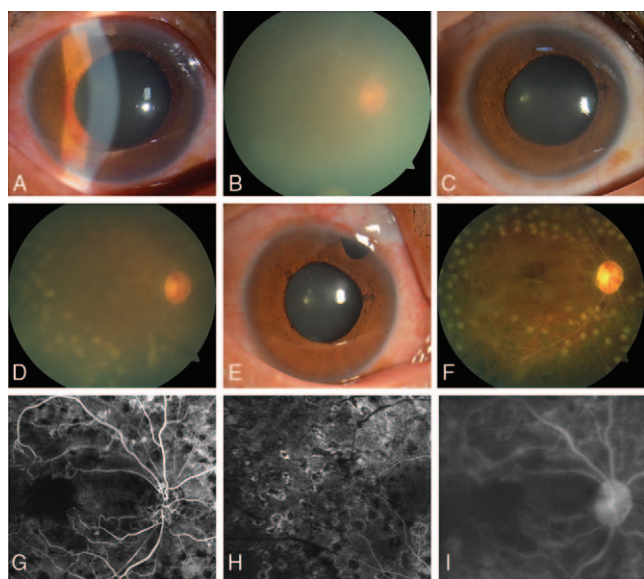
\* Correspondence: Xiaobo Yang, Department of Ophthalmology, Union Hospital, Tongji Medical College, Huazhong University of Science and Technology, 1277 Jiefang Avenue, Wuhan 430022, China (e-mail: yxb0244@163.com).

Copyright © 2017 the Author(s). Published by Wolters Kluwer Health, Inc. This is an open access article distributed under the terms of the Creative Commons Attribution-Non Commercial-No Derivatives License 4.0 (CCBY-NC-ND), where it is permissible to download and share the work provided it is properly cited. The work cannot be changed in any way or used commercially without permission from the journal.

Medicine (2017) 96:25(e7221)

Received: 20 November 2016 / Received in final form: 27 May 2017 / Accepted: 30 May 2017

<http://dx.doi.org/10.1097/MD.0000000000007221>



**Figure 1.** At presentation, examination of the right eye revealed massive NVI and NVA and corneal edema (A) with inadequate fundus visualization (B). One week after intravitreal ranibizumab injection, there was a complete regression of NVI and NVA and improvement of corneal edema (C) which made panretinal photocoagulation feasible due to an adequate view of the posterior pole of fundus (D). A functioning bleb was maintained and there was no recurrence of NVI and NVA (E) at the end of the follow-up period of 6 months. Eleven days after trabeculectomy, fundus photography and fluorescein angiography were performed which revealed a few scattered old retinal hemorrhages, marked sheathing around veins (F), macular ischemia with attenuated arteries (G), and incomplete retinal venous filling (H), as well as disc hyperfluorescence in the later period (I). NVA=neovascularization of the angle, NVI=neovascularization of the iris.

effectiveness of the adjunctive use of ranibizumab with panretinal photocoagulation (PRP) followed by 5-fluorouracil (5-FU) augmented trabeculectomy for advanced NVG.

## 2. Case presentation

A 48-year-old man complained of decreased vision for 2 weeks and severe pain for 10 days in the right eye. His medical history was remarkable for a 5-year history of hypertension as well as a 9-month ocular history of right CRVO. At presentation, his best-corrected visual acuity was hand movement in the right eye and 1.0 in the left eye. IOPs were 48 mmHg in the right eye and 13 mmHg in the left eye by Goldmann applanation tonometry. Anterior segment examination and gonioscopy revealed corneal edema, massive NVI and NVA (Fig. 1A), and almost circumferential peripheral anterior synechiae in the right eye. The fundus view in the right eye was obscured (Fig. 1B), and PRP was not feasible because of the IOP-dependent corneal edema. Despite maximal tolerable topical therapy, his IOP was 40 mmHg and the patient continued to experience marked discomfort.

Treatment options were explained in detail, and after the patient gave consent, an intravitreal injection of 0.5 mg (0.05 mL) of ranibizumab (Lucentis, 10 mg/mL; Novartis, Switzerland) was performed. Topical anesthetic drops were given. After cleaning of the injection side with 5% povidone-iodine, a drape was applied and a lid speculum inserted. The injection was performed with a 30-gauge needle via pars plana to inject 0.05 mL of ranibizumab. The off-label use of ranibizumab was undertaken with the approval of the institutional review board of Wuhan Union

Hospital. The patient was given topical antibiotics and previous antiglaucoma medicines after injection until the performance of following trabeculectomy surgery.

One week after intravitreal ranibizumab (IVR) injection, the IOP had partly decreased to 33 mmHg, and there was a complete regression of NVI and NVA and improvement of corneal edema (Fig. 1C) which made an adequate view of the posterior pole of fundus (Fig. 1D). PRP consisting of a total of 1200 burns was administered in 3 sessions within 1 week starting 1 week after IVR.

Due to the persistently uncontrolled IOP, the surgery of trabeculectomy with 5-FU was performed 2 weeks after IVR. A fornix-based conjunctival flap was made in the superonasal quadrant. After creation of a 4 × 4 mm, half-thickness scleral flap, 5-FU was applied under the conjunctival and sclera flaps by a sponge soaked with 25 mg/mL of 5-FU for 3 minutes, followed by irrigation with 200 mL of physiological saline. Trabeculectomy was performed followed by peripheral iridectomy. The scleral flap was closed with 5 interrupted 10-0 nylon sutures. The conjunctiva was closed at the limbus with interrupted 10-0 nylon sutures. Postoperatively, the patient was prescribed antibiotic, steroid (6 times/day), and cycloplegia eye drops (3 times/day) for 2 weeks, and then gradually tapered the dose over the subsequent 3 weeks.

The patient was followed up for 6 months. The intraoperative and postoperative courses were uneventful without any adverse complication such as hyphema and postoperative hypotony. Posttrabeculectomy, his vision remained hand movement and IOP was in the range of 4 to 15 mmHg without topical antiglaucoma medications. A functioning bleb was maintained and there was no recurrence of NVI and NVA (Fig. 1E) during the complete follow-up period of 6 months.

Eleven days after trabeculectomy, with a complete resolution of corneal edema, fundus photography and fluorescein angiography were performed which revealed a few scattered old retinal hemorrhages, marked sheathing around veins, and macular ischemia with attenuated arteries and incomplete retinal venous filling, as well as disc hyperfluorescence in the later period (Fig. 1F–I). According to the results of angiography, the right eye received additional PRP.

## 3. Discussion

Currently, PRP is the gold standard for initial treatment of NVG. Although the effect to decrease VEGF secretion from PRP is long lasting, it often takes several weeks to occur. During this period, progressive angle closure and optic nerve damage may ensue from elevated IOP. And in patients with media opacity such as corneal edema or cataract, it is sometimes difficult to perform PRP. Furthermore, PRP alone is not completely successful in halting NVI in patients with severe and rapid neovascular progression.<sup>[4]</sup> Therefore, direct targeting of VEGF with anti-VEGF pharmacotherapy may be another possible therapeutic strategy to treat ocular neovascularization. In the present case, NVI and NVA resolved completely within 1 week after IVR. In addition, PRP was feasible after IVR due to a partial reduction of IOP and improvement of corneal edema which made an adequate view of the posterior pole of fundus. It was shown that the use of ranibizumab beforehand presented as an emergency shock therapy in NVG providing a therapeutic window for PRP in this patient who initially was unable to undergo PRP.

Trabeculectomy for NVG has been considered to be a difficult treatment with low success rates, because of intraoperative or

early postoperative bleeding and inflammation caused by neovascularization, irrespective of whether an antimetabolite is used during the operation.<sup>[5]</sup> However, the advent of anti-VEGF therapy has recently resulted in increasing use of the trabeculectomy in NVG. Several studies have shown that decreasing neovascularization via inhibition of angiogenesis with anti-VEGF agents may reduce possible complications and postoperative inflammation, thereby improving the success rate of trabeculectomy in NVG.<sup>[5-8]</sup> The patient in the current case obtained remarkably stable surgical results without bleeding complications because the active intraocular neovascularization was stabilized after the combination treatment of IVR and PRP.

In addition to suppressing existing NVI and NVA, IVR treatment may improve the results of filtration surgery in NVG by reducing postoperative scar formation. A number of studies have demonstrated the potential inhibitory effect of anti-VEGF antibodies on postoperative fibroblastic proliferation and wound healing.<sup>[4-6,9]</sup> On the other hand, VEGF has been reported to have an important role in promoting neovascularization during wound healing. Thus, preoperative IVR treatment may also contribute to improvement of the surgical outcomes by preventing further neovascularization at the filtering site.<sup>[5]</sup>

Given the complexity of the wound-healing cascade, compelling evidence shows that more than 1 agent may be needed to provide additive or synergistic effects on the process.<sup>[9]</sup> A previous animal study has demonstrated that a combination of bevacizumab and 5-FU exhibited stronger antiscarring effect over either therapy alone in a model of glaucoma filtration surgery, indicating a synergistic effect may be present.<sup>[3,10]</sup> Moreover, it has been reported that in comparison to use of mitomycin C (MMC) alone, combination IVR and topical MMC during trabeculectomy resulted in larger, more diffuse blebs with decreased bleb vascularity.<sup>[3,9]</sup> In the present case, the patient obtained an IOP control with a well-functioning bleb over 6 months after trabeculectomy, also suggesting a possible synergistic antifibrotic effect between IVR and 5-FU in the early postoperative period.

In this NVG case, we use the intravitreal route of administering ranibizumab, rather than the subconjunctival or intracameral route used in other case reports injecting anti-VEGF antibodies, in order to influence the filtering site over a longer period of time. It is believed that anti-VEGF agents clear more rapidly after subconjunctival or intracameral injection compared to intravitreal injection.<sup>[9]</sup> In addition, in comparison with subconjunctival or intracameral injection, the intravitreal method for delivery seems to be more effective to treat the underlying retinal ischemia secondary to CRVO in this case.

In the current case, because extensive peripheral anterior synechiae persisted at the time of presentation, IOP was only slightly lowered after IVR injection. As such, this patient underwent subsequent 5-FU augmented trabeculectomy. This finding was in agreement with the previous studies which demonstrated that anti-VEGF alone was insufficient for IOP control in advanced NVG with angle closure which should receive further pressure lowering interventions.<sup>[11-13]</sup> The possible mechanism for an IOP reduction in the angle-closure NVG after IVR was the resolution of intraocular inflammation and exudation associated with leaking NVI.<sup>[14]</sup>

We chose trabeculectomy rather than drainage device implantation as the antiglaucoma surgical intervention in this case, because several studies have confirmed that augmented trabeculectomy had similar or even better IOP reduction and surgical success rate in NVG eyes than the latter.<sup>[8,15]</sup> 5-FU was

preferentially used as the intraoperative antifibrotic in this case over MMC, because MMC is usually associated with higher rates of complications such as thin avascular blebs which carries the risk of hypotony and endophthalmitis.<sup>[16]</sup> And previous studies did not report significant differences in outcomes between the 2 medications in eyes undergoing primary trabeculectomy.<sup>[17]</sup>

In summary, the present case reveals IVR can be used as a useful adjunctive therapy in NVG patients with an obscured fundus resulting from IOP-dependent corneal edema to open a therapeutic window for PRP. In addition, via its anti-angiogenic and anti-fibrotic properties, preoperative IVR results in a rapid and complete regression of NVI and NVA which is beneficial as a surgical adjuvant to minimizing intraoperative and postoperative bleeding and inflammation, and may reduce the fibroblast proliferation and scar formation after trabeculectomy. Thus, preoperative IVR may greatly contribute to improvement of the surgical outcome in subsequent trabeculectomy in NVG eyes. Taken together, these results in the present case suggest that combined treatment of IVR, PRP, and subsequent 5-FU augmented trabeculectomy seems to be a possible new paradigm for the management of advanced NVG with angle closure and intractable elevation of IOP. Further studies with a larger sample size, longer follow-up period, prospective, and randomized design will be needed to evaluate the safety and efficacy of this treatment regimen for NVG.

## References

- [1] Moraczewski AL, Lee RK, Palmberg PF, et al. Outcomes of treatment of neovascular glaucoma with intravitreal bevacizumab. *Br J Ophthalmol* 2009;93:589-93.
- [2] Park SC, Su D, Tello C. Anti-VEGF therapy for the treatment of glaucoma: a focus on ranibizumab and bevacizumab. *Expert Opin Biol Ther* 2012;12:1641-7.
- [3] Kim M, Lee C, Payne R, et al. Angiogenesis in glaucoma filtration surgery and neovascular glaucoma: a review. *Surv Ophthalmol* 2015;60:524-35.
- [4] Elmekawey H, Khafagy A. Intracameral ranibizumab and subsequent mitomycin C augmented trabeculectomy in neovascular glaucoma. *J Glaucoma* 2014;23:437-40.
- [5] Kobayashi S, Inoue M, Yamane S, et al. Long-term outcomes after preoperative intravitreal injection of bevacizumab before trabeculectomy for neovascular glaucoma. *J Glaucoma* 2016;25:281-4.
- [6] Kitnarong N, Sriyakul C, Chinwattanakul S. A prospective study to evaluate intravitreal ranibizumab as adjunctive treatment for trabeculectomy in neovascular glaucoma. *Ophthalmol Ther* 2015;4:33-41.
- [7] Saito Y, Higashide T, Takeda H, et al. Beneficial effects of preoperative intravitreal bevacizumab on trabeculectomy outcomes in neovascular glaucoma. *Acta Ophthalmol* 2010;88:96-102.
- [8] Liu L, Xu Y, Huang Z, et al. Intravitreal ranibizumab injection combined trabeculectomy versus Ahmed valve surgery in the treatment of neovascular glaucoma: assessment of efficacy and complications. *BMC Ophthalmol* 2016;16:65.
- [9] Kahook MY. Bleb Morphology and vascularity after trabeculectomy with intravitreal ranibizumab: a pilot study. *Am J Ophthalmol* 2010;150:399-403.
- [10] How A, Chua JL, Charlton A, et al. Combined treatment with bevacizumab and 5-fluorouracil attenuates the postoperative scarring response after experimental glaucoma filtration surgery. *Invest Ophthalmol Vis Sci* 2010;51:928-32.
- [11] Iliev ME, Domig D, Wolf-Schnurrbursch U, et al. Intravitreal bevacizumab (Avastin) in the treatment of neovascular glaucoma. *Am J Ophthalmol* 2006;142:1054-6.
- [12] Sagong M, Kim J, Chang W. Intravitreal bevacizumab for the treatment of neovascular glaucoma associated with central retinal artery occlusion. *Korean J Ophthalmol* 2009;23:215-8.
- [13] Wakabayashi T, Oshima Y, Sakaguchi H, et al. Intravitreal bevacizumab to treat iris neovascularization and neovascular glaucoma secondary to ischemic retinal diseases in 41 consecutive cases. *Ophthalmology* 2008;115:1571-80.

- [14] Wong YH, Koo CY, Yuen SY, et al. Intravitreal ranibizumab for neovascular glaucoma: an interventional case series. *HKJ Ophthalmol* 2011;15:6–11.
- [15] Shen CC, Salim S, Du H, et al. Trabeculectomy versus Ahmed Glaucoma Valve implantation in neovascular glaucoma. *Clin Ophthalmol* 2011;5: 281–6.
- [16] Masoumpour MB, Nowroozzadeh MH, Razeghinejad MR. Current and future techniques in wound healing modulation after glaucoma filtering surgeries. *Open Ophthalmol J* 2016;10:68–85.
- [17] Palanca-Capistrano AM, Hall J, Cantor LB, et al. Long-term outcomes of intraoperative 5-fluorouracil versus intraoperative mitomycin C in primary trabeculectomy surgery. *Ophthalmology* 2009;116:185–90.