



Infected Aortic Aneurysm with Infective Spondylitis in a Patient with Pre-Aortic Confluence of the Iliac Veins: An Unusual Triple Combination

Thilina Gunawardena, Manujaya Godakandage, Sachith Abeywickrama, Rezni Cassim, and Mandika Wijeyaratne

University Vascular Surgical Unit, National Hospital of Colombo, Colombo, Sri Lanka

It is uncommon for infective spondylitis to coexist with an infected aneurysm of the adjacent abdominal aorta. Also, pre-aortic confluence of the iliac veins or marsupial vena cava is a rare anatomical variant, which increases the potential for venous injury and hemorrhage during an emergency operation. Herein, we report the case of a 57-year-old male with these three pathologies, who was successfully treated with emergency open surgery. During surgery, we noted this anomaly and extensive destruction of the lumbar vertebral bodies. We discuss options to treat these rare pathologies with literature review.

Key Words: Infected aneurysm, Spondylitis, Inferior vena cava, Iliac vein, Marsupial vena cava

Received September 14, 2021
Revised November 22, 2021
Accepted December 17, 2021
Published on December 29, 2021

Corresponding author: Thilina Gunawardena
University Vascular Surgical Unit, National Hospital of Colombo, Colombo 01000, Sri Lanka
Tel: 94-777030315
E-mail: thilina mg@gmail.com
<https://orcid.org/0000-0002-3867-2780>

Copyright © 2021 The Korean Society for Vascular Surgery

This is an Open Access article distributed under the terms of the Creative Commons Attribution Non-Commercial License (<http://creativecommons.org/licenses/by-nc/4.0>) which permits unrestricted non-commercial use, distribution, and reproduction in any medium, provided the original work is properly cited.

Cite this article; Vasc Specialist Int 2021. <https://doi.org/10.5758/vsi.210066>

INTRODUCTION

Congenital abnormalities of the inferior vena cava (IVC) have a reported incidence of 2% to 3% [1]. Pre-aortic confluence of the iliac veins is one such anomaly that has an unknown incidence, as it is extremely rare [2]. The presence of this anomaly can have far-reaching implications during aortic surgery with the potential for venous injury and massive hemorrhage, especially during emergencies. Coincident infective spondylitis and an infected aneurysm of the adjacent aorta are rare [3,4]. The management of such cases can be extremely challenging, especially in resource-poor settings.

We present the case of a patient who underwent emergency repair of an infected aneurysm of the infrarenal aorta. During surgery, we noted pre-aortic iliac vein confluence and extensive destruction of the lumbar vertebral

bodies. Cultures obtained from the patient's blood, aneurysm wall, and bone isolated *Staphylococcus aureus*. This case report aims to discuss the multiple rare presentations encountered in this patient, with particular emphasis on the IVC anomaly.

Written informed consent was obtained from the patient. This study was exempt from approval by the Ethics Committee of the National Hospital of Colombo, Sri Lanka.

CASE

A 57-year-old male patient with a history of stable arterial claudication of the left lower limb for 1 year was investigated for worsening back pain over the previous 8 months. The patient was a heavy smoker and had a history of alcohol abuse. Imaging identified bilateral non-obstructing renal calculi, and the back pain was attributed

to those findings. While under the care of the urology team for renal stones, the patient developed sudden and severe worsening of the left lower limb pain. Acute limb ischemia was suspected, and he was referred to the on-call vascular surgical team at the National Hospital of Colombo.

Upon admission, the patient was experiencing agonizing pain. Careful examination revealed that the pain originated in the lower back region and radiated along the left lower limb. Left lower limb pulses were absent from the groin downwards, and the left foot was cold. We found no tissue loss and no neurological abnormalities. In comparison to the left lower extremity, neurovascular examination of the right lower extremity yielded completely normal results. Examination findings were suggestive of Rutherford grade I acute limb ischemia involving the left lower limb.

Basic blood investigations suggested an ongoing bacterial infection. We identified an increased white blood cell count of $17.73 \times 10^3 \mu\text{L}$ (normal, $4\text{--}10 \times 10^3$), with 81.9% neutrophils, and a C-reactive protein level of 297 mg/L (normal, <6 mg/L). The patient did not have a history of fever, and over the previous few months experienced poor appetite and unintentional weight loss. Renal function was within normal limits, and urine microscopy was not suggestive of infection. Pending results of the blood cultures, intravenous co-amoxiclav (amoxicillin/clavulanic acid) was initiated. Two-dimensional echocardiogram was negative for infective endocarditis. Urgent contrast-enhanced computed tomography (CT) angiography of the abdomen and pelvis

was performed to exclude a possible intra-abdominal septic focus, and to assess left lower limb perfusion. Contrary to our expectations, a saccular aneurysm of the infrarenal aorta was detected (Fig. 1). The aneurysm had a predominantly posterior extension with features suggesting leakage. Erosive destruction of the adjacent vertebral bodies was also noted. The left common and external iliac arteries were occluded with collaterals perfusing the common femoral artery (CFA).

Because of ongoing severe back pain resistant to narcotic analgesics, and the possibility of leaking, a decision was made to repair the aneurysm as an emergency case. During laparotomy, a pre-aortic iliac vein confluence was found, and the vein was carefully separated from the aorta by sharp dissection (Fig. 2A). Infrarenal aortic control was taken, and the bilateral iliac arteries were mobilized. After clamping, opening into the aneurysm revealed extensive inflammatory destruction of the anterior segments of the L3 and L4 vertebral bodies and the intervening intervertebral disc (Fig. 2B). Culture samples were taken from the wall of the aneurysm and vertebral bodies. After thorough debridement of all infected tissues, in situ aortic reconstruction was performed using a 14 mm \times 7 mm bifurcated polyester graft. The right graft limb was anastomosed to the right common iliac artery, and the left graft limb was anastomosed to the left CFA at the groin. After reperfusion, the right pedal pulses failed to reappear. We suspected a technical issue with the anastomosis, and a jump graft was

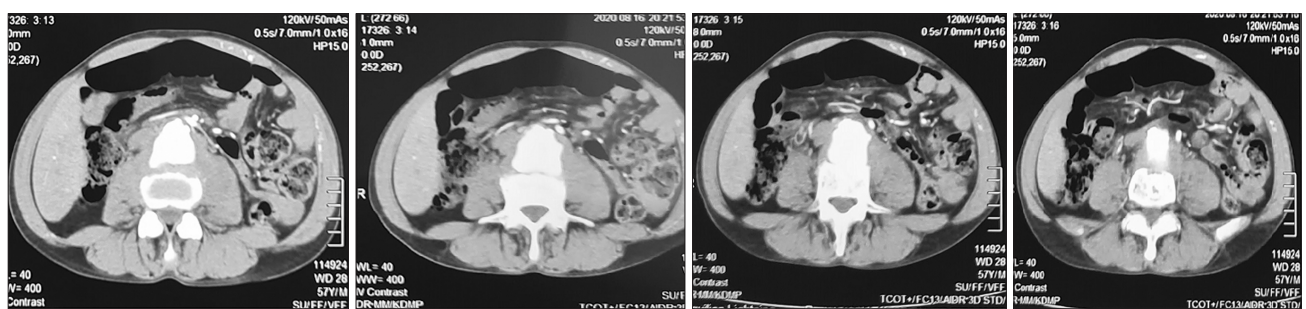

Fig. 1. Contrast computed tomography demonstrated the saccular aneurysm.

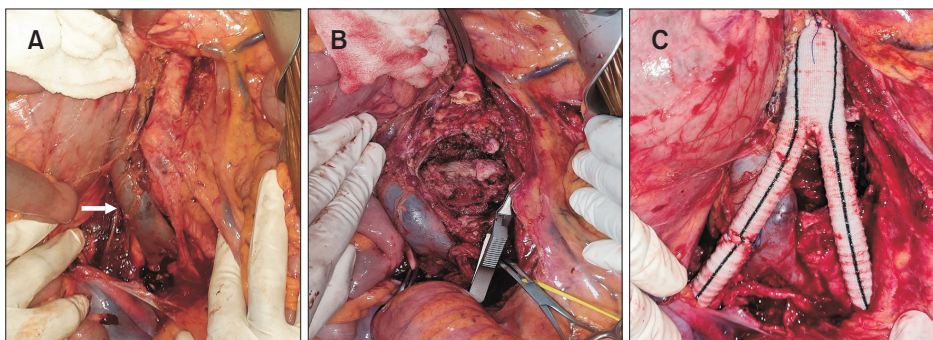


Fig. 2. Intraoperative images. (A) The arrow indicates pre-aortic iliac vein confluence. (B) After resection of the aortic aneurysm, eroded vertebral bodies were revealed. (C) The right limb of the graft was extended to the right femoral artery and positioned anterior to the venous confluence.

taken from the right graft limb to the right CFA, which restored limb perfusion. The right graft limb was positioned anterior to the iliac venous confluence (Fig. 2C), and the final reconstruction was wrapped with the omentum. Post-operative recovery was uneventful.

Cultures of blood, aneurysm wall, and bone tissue isolated methicillin-sensitive *S. aureus*. The organism was sensitive to flucloxacillin, and the drug was administered 500 mg four times per day for 6 weeks, intravenously. The patient was discharged on long-term oral flucloxacillin, and at the 1-year follow-up, he remained well and free from graft infection.

DISCUSSION

Pre-aortic confluence of the iliac veins is an anatomical variant where the IVC or the left common iliac vein (CIV) is located anterior to the aortic bifurcation. Marsupial vena cava is an alternative term for this anomaly, as an anteriorly positioned IVC is considered a normal finding in marsupials. This anomaly is extremely rare in humans, and the affected individuals tend to be asymptomatic, therefore the exact incidence is unknown [1,2]. On an embryological basis, a pre-aortic iliac vein confluence represents the persistent ventral limb of the circumaortic venous ring with regression of the dorsal limb. This condition is the opposite of the development during normal embryogenesis [1,5]. Depending on the relationship between the iliac veins and the aortic bifurcation, three morphological variants of this anomaly have been described. Our patient had the IVC anterior to the aortic bifurcation with the iliac veins in the conventional position behind the arteries. This arrangement

is consistent with the classic description of the anomaly. In the second variation, the left CIV is located anterior to the aortic bifurcation. The third configuration contains an iliac vein confluence in front of the aortic bifurcation, with the right CIV traveling in front of its arterial counterpart [1].

The presence of pre-aortic iliac vein confluence increases the potential for venous injury and hemorrhage during aortic surgery. This can have a profound effect during emergencies such as a leaking aortic aneurysm, where the patient's physiology is already taxed, and the surgeon is pressed for time [1]. In addition, the anomaly can be easily missed on preoperative cross-sectional imaging unless it is actively searched for. Notably, this oversight occurred in our case as the retrospective review of the CT images revealed the presence of the anatomical variation (Fig. 3).

Once a pre-aortic iliac vein confluence is confirmed during open aortic surgery, careful mobilization of the vein is required to expose the aortic bifurcation. An alternative technique is to perform limited mobilization of the aortic bifurcation, leaving the venous confluence undisturbed as much as possible. Schiavetta et al. [6] suggested this approach when veins appear to be densely adherent to the aorta. In patients with a preoperative diagnosis of this anomaly, the right retroperitoneal approach should not be used to access the aortic bifurcation or the right CIA [6]. When a bifurcated graft is used for aortic reconstruction in these cases, the graft limbs can be tunneled anterior or posterior to the veins, and both are acceptable techniques [1,7]. In our case, an anterior approach was used.

It is rare for infective spondylitis to coexist with an infected aortic aneurysm [3,4]. However, when it does occur, it is often difficult to determine whether the infection originated in the aorta or the spine. The clinical presentation of patients with this combined pathology can be non-specific, and a delayed diagnosis is common [4,8]. In our patient, the initial presentation was back pain, which was attributed to the presence of renal calculi.

Contrast-enhanced CT is the preferred imaging modality for the evaluation of suspected infected aortic aneurysms. The sacular shape of the aneurysm, presence of periaortic gas, fat stranding, and adjacent vertebral body destruction are the CT features suggestive of an infective pathology. Blood cultures may fail to isolate the causative organism in up to 50% of patients with aortic infections [9]. In our patient, culture of blood, aneurysm wall, and bone all isolated *S. aureus*, which was highly indicative of a contiguous infective process. Management of patients with attendant infective spondylitis and infected aortic aneurysms can be extremely challenging. Conservative management with antibiotics alone has yielded poor outcomes [8]. In cases where an operative approach is pursued, debridement of all

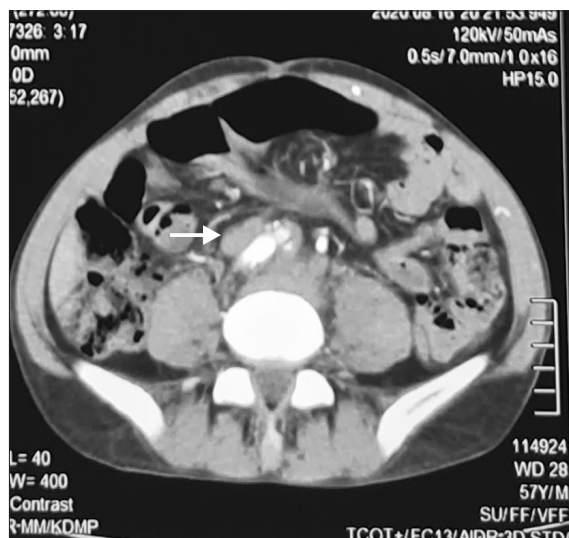

Fig. 3. A computed tomography image depicted the vena cava (arrow), located anterior to the aortic bifurcation.

infected tissues is mandatory. However, this approach can result in instability of the spinal column, requiring bone grafting and fixation. Cord compression caused by vertebral body collapse is another indication for such interventions. Fortunately, these measures are rarely required, and in the majority of cases, adequate debridement followed by antibiotics will be sufficient to manage spondylitis [4]. Notably, this was also a successful approach for our patient.

Extra-anatomic bypass was previously considered the gold standard for reconstruction in the treatment of infected aortic aneurysms [8,10]. Compared to in situ revascularization, extra-anatomic bypass has poor graft patency rates [10,11]. As a result, thorough debridement of all infected tissue followed by in situ reconstruction is becoming more common. If a prosthetic graft is used for this purpose, grafts impregnated with antimicrobial substances, such as rifampicin, are preferred. Cryopreserved aortic allografts and neo-aorto-iliac systems constructed with the patient's femoral veins are alternative conduits [11,12]. Some reports have described the use of composite grafts made from autologous femoral veins combined with antibiotic-impregnated prosthetic grafts when native veins are of insufficient length or quality [13]. Along with more widespread adoption of endovascular aortic aneurysm repair, the use of stent grafts to treat infected aneurysms has also increased. In comparison to open surgery, endovascular repair is associated with improved short-term outcomes [14]. For severely ill patients with coexisting spondylitis and infected aortic aneurysms, stent grafting and long-term antimicrobial therapy may be a more suitable option [15].

In our setup, we do not have emergency access to aortic stent grafts, cryopreserved aortic allografts, or antibiotic-impregnated prosthetic grafts. At the time of surgery, our opinion was that the patient was not a suitable candidate for the creation of a neo-aortoiliac system as he was unlikely to tolerate prolonged anesthetic times and the associated surgical trauma. Unfortunately, a bifurcated expanded polytetrafluoroethylene graft was not available. Therefore, after thorough debridement, we performed an in situ repair

using a standard bifurcated prosthetic graft. This, combined with prolonged treatment with culture-directed antibiotics, led to a favorable outcome in our case.

In summary, pre-aortic confluence of the iliac veins is an extremely rare anatomical variation that vascular surgeons should be aware of. The combination of infective spondylitis and infected aortic aneurysms is also very uncommon and management of such cases can be challenging, especially in resource-constrained settings.

FUNDING

None.

CONFLICTS OF INTEREST

The authors have nothing to disclose.

ORCID

Thilina Gunawardena

<https://orcid.org/0000-0002-3867-2780>

Manujaya Godakandage

<https://orcid.org/0000-0002-1859-480X>

Sachith Abeywickrama

<https://orcid.org/0000-0002-8016-2258>

Rezni Cassim

<https://orcid.org/0000-0002-4826-6196>

Mandika Wijeyaratne

<https://orcid.org/0000-0001-9073-5446>

AUTHOR CONTRIBUTIONS

Concept and design: TG. Analysis and interpretation: none. Data collection: TG, MG, SA. Writing the article: TG, MG, SA. Critical revision of the article: RC, MW. Final approval of the article: all authors. Statistical analysis: none. Obtained funding: none. Overall responsibility: TG.

REFERENCES

- 1) Ruemenapf G, Rupprecht H, Schweiger H. Preaortic iliac confluence: a rare anomaly of the inferior vena cava. *J Vasc Surg* 1998;27:767-771.
- 2) Rocha Mde S, Lourenço RB, Chang YS, Gebrim EM, Cerri GG. Preaortic iliac confluence (marsupial vena cava): report of 4 cases. *J Comput Assist Tomogr* 2008;32:706-709.
- 3) Chen SH, Lin WC, Lee CH, Chou WY. Spontaneous infective spondylitis and mycotic aneurysm: incidence, risk factors, outcome and management experience. *Eur Spine J* 2008;17:439-444.
- 4) Zhang R, Teebken OE, Bisdas T, Haverich A, Pichlmaier M. Surgical outcome in patients with concomitant-infected abdominal aortic aneurysm and spondylitis. *Vascular* 2011;19:34-41.

- 5) Reis Filho AJS, Rocha MA, Lemos GR, Yamauchi FI, Tachibana A, Baroni RH. Marsupial vena cava mimicking lymph node enlargement on tomography. *Einstein (Sao Paulo)* 2018;16:eAI4394.
- 6) Schiavetta A, Cerruti R, Cantello C, Patrone P. "Marsupial cava" and ruptured abdominal aortic aneurysm. A case report and review of the literature. *J Vasc Surg* 1998;28:719-722.
- 7) Masood M, Neary W, Ashley S. Pre aortic confluence of the common iliac veins complicating elective abdominal aortic aneurysm surgery. *EJVES Extra* 2008;15:31-32.
- 8) McHenry MC, Rehm SJ, Krajewski LP, Duchesneau PM, Levin HS, Steinmuller DR. Vertebral osteomyelitis and aortic lesions: case report and review. *Rev Infect Dis* 1991;13:1184-1194.
- 9) Lee WK, Mossop PJ, Little AF, Fitt GJ, Vrazas JI, Hoang JK, et al. Infected (mycotic) aneurysms: spectrum of imaging appearances and management. *Radiographics* 2008;28:1853-1868.
- 10) Dubois M, Daenens K, Houthoofd S, Peetermans WE, Fourneau I. Treatment of mycotic aneurysms with involvement of the abdominal aorta: single-centre experience in 44 consecutive cases. *Eur J Vasc Endovasc Surg* 2010;40:450-456.
- 11) Lee CH, Hsieh HC, Ko PJ, Li HJ, Kao TC, Yu SY. In situ versus extra-anatomic reconstruction for primary infected infrarenal abdominal aortic aneurysms. *J Vasc Surg* 2011;54:64-70.
- 12) Pallister ZS, Chung J. Femoral vein reconstruction for aortic infections. *Vasc Specialist Int* 2021;37:4-13.
- 13) Chatzigakis PK, Barmparessos EM, Katsikas VC. Variant neo-aortoiliac system operation using a composite conduit of silver-coated Dacron graft and autologous femoral veins: a report of two cases. *Vasc Specialist Int* 2021;37:20.
- 14) Sörelius K, Budtz-Lilly J, Mani K, Wanhainen A. Systematic review of the management of mycotic aortic aneurysms. *Eur J Vasc Endovasc Surg* 2019;58:426-435.
- 15) Li W, Sun X, Li H, Meng Z, Yang Y, Yao S. Endovascular treatment of a ruptured thoracic aortic pseudoaneurysm secondary to Pott disease during a spine surgery: a case report and a literature review. *Medicine (Baltimore)* 2019;98:e15306.