

Case report

Open Access

Cutaneous horns: are these lesions as innocent as they seem to be?

Eray Copcu*¹, Nazan Sivrioglu¹ and Nil Culhaci²

Address: ¹Plastic and Reconstructive Surgery Department, Medical Faculty, Adnan Menderes University, Aydin, Turkey and ²Pathology Department, Medical Faculty, Adnan Menderes University, Aydin, Turkey

Email: Eray Copcu* - ecopcu@adu.edu.tr; Nazan Sivrioglu - nsivrioglu@adu.edu.tr; Nil Culhaci - nculhaci@adu.edu.tr

* Corresponding author

Published: 03 June 2004

Received: 26 March 2004

World Journal of Surgical Oncology 2004, **2**:18

Accepted: 03 June 2004

This article is available from: <http://www.wjso.com/content/2/1/18>

© 2004 Copcu et al; licensee BioMed Central Ltd. This is an Open Access article: verbatim copying and redistribution of this article are permitted in all media for any purpose, provided this notice is preserved along with the article's original URL.

Abstract

Background: Cutaneous horns (*cornu cutaneum*) are uncommon lesions consisting of keratotic material resembling that of an animal horn. Cutaneous horn may arise from a wide range of the epidermal lesions, which may be benign, premalignant or malignant.

Patients and methods: In this respective study, we describe our experience of eleven patients with cutaneous horn treated at our centre between January 2000 and January 2004. The clinical, pathological and treatment details were extracted from the case records. Data is presented as frequency distribution.

Results: There were 8 male and 3 female patients with a median age of 57 years. Most of the lesions were located on the ear, hand and scalp. Surgical resection was carried out in all the lesions. There were two cases of squamous cell carcinoma, and one case of basal cell carcinoma, other 8 cases were benign. None of the lesions recurred and no adjuvant treatment was given to any of the malignant lesions.

Conclusion: Cutaneous horn is a clinical diagnosis that refers to a conical projection above the surface of the skin. The lesions typically occurs in sun exposed areas, particularly the face, ear, nose, forearms, and dorsum of hands. Even though our 60% of the cutaneous horns are benign possibility of skin cancer should always be kept in mind.

Introduction

Cutaneous horn (*cornu cutaneum*), is a projectile, conical, dense, hyperkeratotic nodule that resembles the horn of an animal [1]. The horn is composed of compacted keratin. A number of skin lesions can be found at the base of this keratin mound. Cutaneous horns most frequently occur in sites that are exposed to actinic radiation or burns, and hence, are typically found on upper parts of the face. Other locations include scalp, nose, eyelid, ear, lip, chest, neck and shoulder. Forearm, cartilaginous por-

tion of the ear, leg and back of hands may also be involved [2]. Over 60% of the lesions are benign, however, malignant or premalignant lesions might be associated with it [3]. Keratosis, sebaceous molluscum, verruca, trichilemma, Bowen's disease, epidermoid carcinoma, malignant melanoma, and basal cell carcinoma have all been described in association with cutaneous horns [4]. For appropriate histopathological diagnosis, this lesion should undergo biopsy at the base of the horn for smaller lesions excision should be considered. A sex predilection

Table 1: Patient characteristics

No	Age	Sex	Location	Diameter (in mm)	Pathology	Previous history of skin cancer
1	57	male	Ear	45 × 10	actinic keratosis	none
2	60	male	Ear	40 × 15	squamous cell carcinoma	yes
3	45	female	buccal mucosa	20 × 8	basal cell carcinoma	none
4	58	male	Hand	15 × 5	keratoacanthoma	none
5	54	male	Scalp	25 × 8	solar keratosis	none
6	65	male	Scalp	35 × 10	solar keratosis	yes
7	67	female	Lip	25 × 6	actinic keratosis	none
8	52	male	Hand	45 × 15	squamous cell carcinoma	none
9	54	male	Scalp	30 × 10	solar keratosis	none
10	62	female	Ear	20 × 5	solar keratosis	none
11	51	male	Ear	25 × 8	keratoacanthoma	yes

has not been shown; however the possibility of harboring malignancy at the base of the lesion is increased in men when compared with age-matched women. This article describes our experience with cutaneous horns.

Patients and methods

Eleven patients with *cornu cutaneum* treated between January 2000 and January 2004 at the Department of Plastic and Reconstructive Surgery, Adnan Menderes University forms the basis of this report. These patients were diagnosed preoperatively based on the appearance of their lesions. After careful and detailed physical examinations all patients underwent surgical excision under local anesthesia. Defects were closed primarily if diameter was less than 2 cm, split thickness skin grafting was performed if the defects could not be closed primarily. Specimens were evaluated microscopically. Patients with malignant lesions were followed-up for minimum six months for any signs of recurrence. Data is presented as frequency.

Results

The age of the patients ranged from 45 to 67 years with a median age of 57 years. Median age was 55 years in males and 65 years in females. A male to female ratio of 3:8 was observed. All patients had history of long-term sun exposure due to farm activities and had solar keratosis on face and extremities. Three patients had past history of skin cancer (Table 1). Majority of the lesions were located on ears (4/11) (Figure 1 and 2). Three patients had a lesion on the scalp and two patients on the hand (Figure 3, and 4). One patient each had a *cornu cutaneum* on the lip and the buccal mucosa (Figure 5). The diagnosis of cutaneous horn was confirmed histopathologically (Figure 6). Base of the lesions were diagnosed as solar keratosis in four patients, well differentiated squamous cell carcinoma in two, actinic keratosis in two, keratoacanthoma in two, and basal cell carcinoma in one patient. One of the squamous cell carcinoma was located on ear and other on

hand, while basal cell carcinoma was located on buccal mucosa. Surgical margins of the specimens were tumor free in all patients. There was no recurrence and complication in postoperative period. No adjuvant therapy given to the patients with skin cancer. Sun protection was advised to all patients.

Discussion

Cutaneous horns, though grossly similar to horns in animals are histologically quite different from them. The animal horns are composed of superficial hyperkeratotic epidermis, dermis, and centrally positioned bone. No such axially positioned well-formed bone is observed in the gigantic human horns. On the other hand, no cystic structures lined by tricholemmal-type epithelium are seen in of the true animal horns [5]. The earliest well documented case of *cornu cutaneum* from London in 1588 is of Mrs. Margaret Gryffith, an elderly Welsh woman. A showman, who advertised it in a pamphlet, exhibited her for money. However, earliest observations on cutaneous horns in humans were described by the London surgeon Everard Home in 1791 [6]. Farris from Italy first described the gigantic horn in man as a well documented a case report with adequate histology [7]. A cutaneous horn (*cornu cutaneum*) is a protrusion from the skin consisting of cornified material organized in the shape of a horn. These horns can be derived from a variety of benign or malignant epidermal lesions. The histological appearance of the basal layer of the cutaneous horn is in the spectrum of seborrheic keratosis to infiltrated squamous cell carcinoma [1,6]. The important issue is not the horn itself which is dead keratin, but rather the underlying condition, which may be benign (seborrheic keratosis, viral warts, histiocytoma, inverted follicular keratosis, verrucous epidermal nevus, molluscum contagiosum, etc.), premalignant (solar keratosis, arsenical keratosis, Bowen's disease) or malignant (squamous cell carcinoma, rarely, basal cell carcinoma, metastatic renal carcinoma, granular

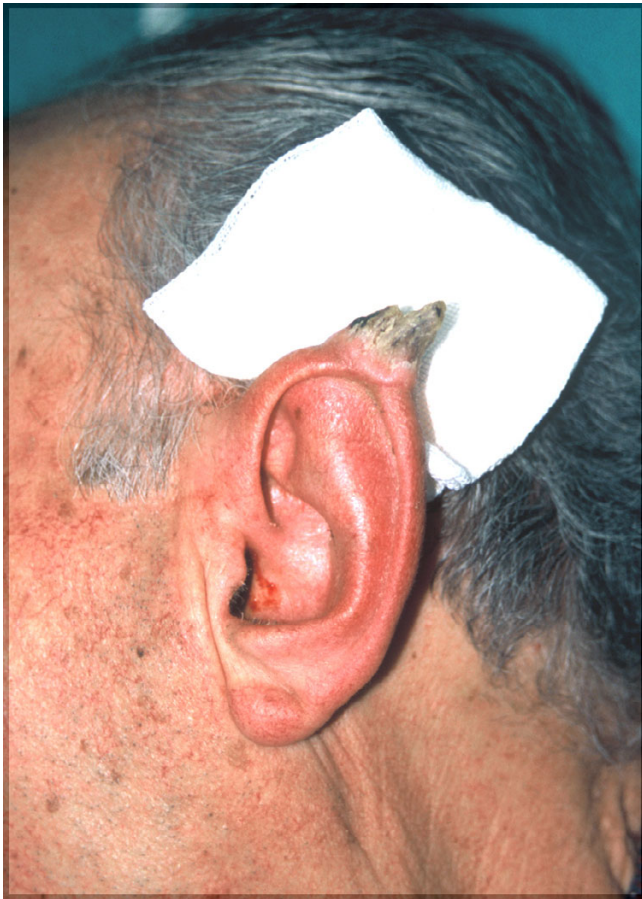

Figure 1
Cornu cutaneum on the left ear. Histologically lesion was reported as actinic keratosis.

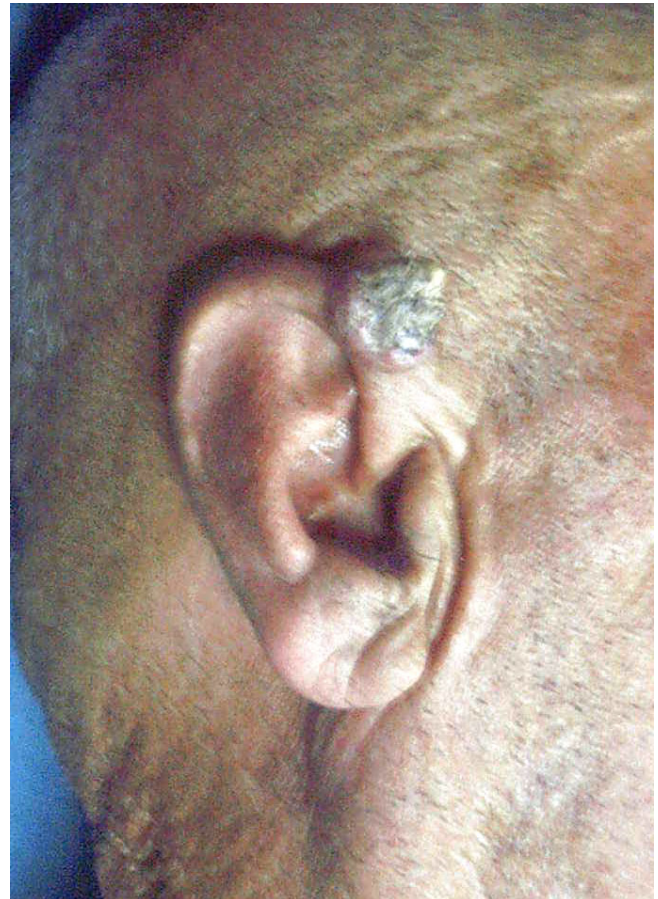

Figure 2
Cornu cutaneum on the right ear histologically reported as well differentiated squamous cell carcinoma.

cell tumor, sebaceous carcinoma or Kaposi's sarcoma). Most commonly, they are single and arise from a seborrheic keratosis lesion [8]. Largest study of 643 cutaneous horns was reported by Yu *et al* [6]. According to them 39% of cutaneous horns were derived from malignant or premalignant epidermal lesions, and 61% from benign lesions. Two other larger studies on cutaneous horn too showed 23–37% of these to be associated with actinic keratosis or Bowen's disease and another 16–20% with malignant lesions [3,9]. In the study of Bart *et al* [10] 44% patients had underlying malignancy. Three of their patients had past history of skin cancers [10]. Spira and Rabonovitz concluded that cutaneous horns in associated with a malignant or premalignant base is more common in patients with a past history of other malignant or premalignant lesions [11]. In our part of the country exposure to the sun is most common. Majority of the population is involved in farm activity mostly without sun protection. We believe that sun exposure is the most

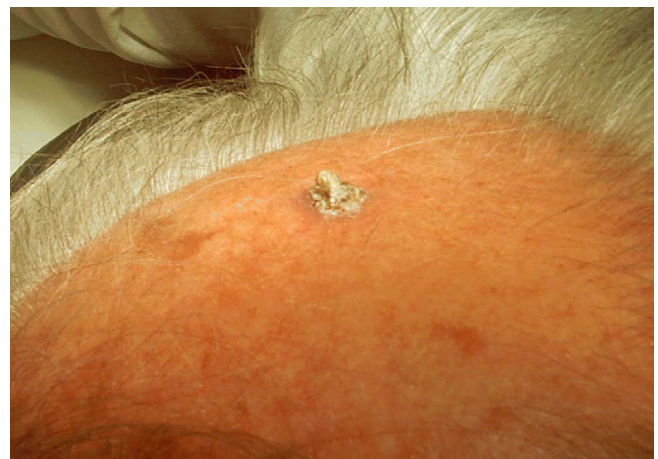

Figure 3
Cornu cutaneum due to solar keratosis of the scalp.

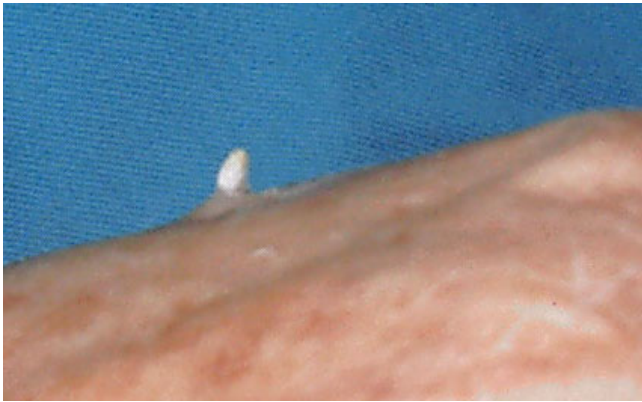

Figure 4
Cornu cutaneum on the hand due to keratoacanthoma.

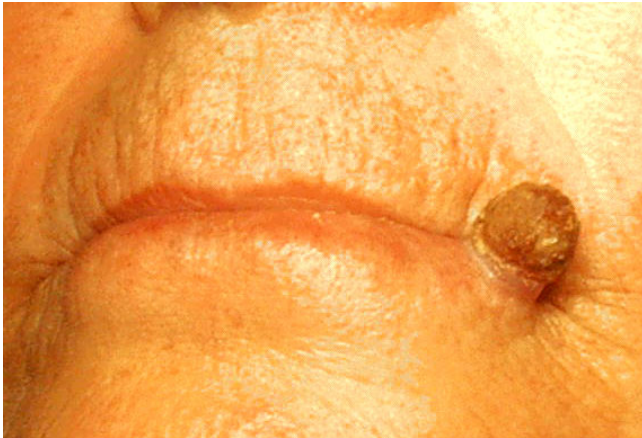

Figure 5
Cornu cutaneum on the lip due to actinic keratosis.

important etiological factor in pathogenesis of the *cornu cutaneum* like other skin lesions. Histopathological examination of the base of the lesion is necessary to rule out associated carcinoma, and full excision is the treatment of choice. In general, malignant or premalignant conditions are more common in older male patients, especially when the cutaneous horn is found on the face, pinna, dorsum of hands, forearms, or scalp, or when it has a larger base or base-height ratio [3]. Surgical excision remains the treatment of choice.

Conclusions

Cutaneous horns are predominantly benign lesions; however possibility of nearly one third of them harboring

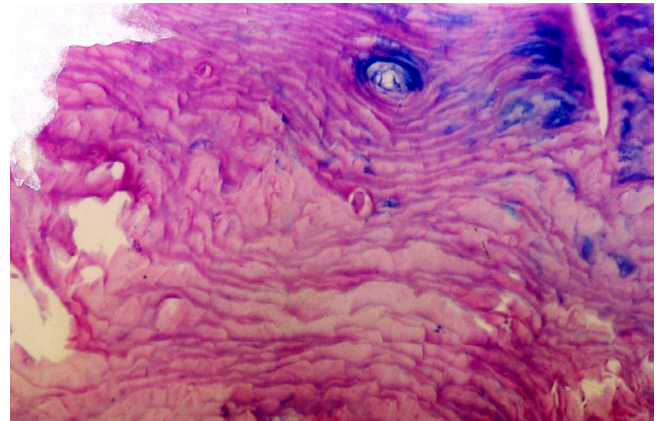


Figure 6
Photomicrograph showing diffuse hyperkeratosis and parakeratosis consistent with cutaneous horn. (Hematoxylin & Eosin $\times 100$).

malignant or premalignant skin lesions should be kept in mind.

Competing interests

None declared.

Authors' contributions

EC conceived the study and prepared the manuscript draft for submission. NS and NC did the literature search and participated in the preparation of the manuscript.

All authors read and approved the final manuscript.

References

1. Korkut T, Tan NB, Oztan Y: **Giant cutaneous horn: a patient report.** *Ann Plast Surg* 1997, **39**:654-655.
2. Souza LN, Martins CR, de Paula AM: **Cutaneous horn occurring on the lip of a child.** *Int J Paediatr Dent* 2003, **13**:365-367.
3. Yu RC, Pryce DW, Macfarlane AW, Stewart TW: **A histopathological study of 643 cutaneous horns.** *Br J Dermatol* 1991, **124**:449-452.
4. Akan M, Yildirim S, Avci G, Akoz T: **Xeroderma pigmentosum with a giant cutaneous horn.** *Ann Plast Surg* 2001, **46**:665-666.
5. Michal M, Bisceglia M, Di Mattia A, Requena L, Fanburg-Smith JC, Mukensnabl P, Hes O, Cada F: **Gigantic cutaneous horns of the scalp: lesions with a gross similarity to the horns of animals: a report of four cases.** *Am J Surg Pathol* 2002, **26**:789-794.
6. Bondeson J: **Everard Home, John Hunter, and cutaneous horns: a historical review.** *Am J Dermatopathol* 2001, **23**:362-369.
7. Farris G: **Histological considerations on a case of a voluminous cutaneous horn.** *Minerva Dermatol* 1953, **28**:159-165.
8. Thappa M, Laxmisha C: **Cutaneous horn of eyelid.** *Indian Pediatr* 2004, **41**:195.
9. Schosser RH, Hodge SJ, Gaba CR, Owen LG: **Cutaneous horns: a histopathologic study.** *South Med J* 1979, **72**:1129-1131.
10. Bart RS, Andrade R, Kopf AW: **Cutaneous horns. A clinical and histopathologic study.** *Acta Derm Venereol* 1968, **48**:507-515.
11. Spira J, Rabinovitz H: **Cutaneous horn present for two months.** *Dermatol Online J* 2000, **6**:11 [<http://dermatology.cdlib.org/DQ/vol6num1/unknowns/horn/horn1.html>]. last accessed on May 26, 2004