

# Retropharyngeal hematoma following anterior cervical spine surgery

## Lessons from a case report (CARE-compliant)

Haiyong Ren, MD\*, Jin Wang, MD, Leijun Yu, MD

### Abstract

**Rationale:** Retropharyngeal hematoma (RH) is an infrequent but potentially life-threatening complication of anterior cervical spine surgeries (ACSS). Challenging situations might be confronted and catastrophic events or even deaths still occurred occasionally during the treatment. Currently, no widely accepted protocol has been developed.

**Patient concerns:** A 55 years old male underwent ACSS due to cervical myelopathy. Thirty-three hours after surgery the patient presented cervical swelling and obstructive dysphagia. Conservative treatment resulted in no recovery and cervical swelling progressed.

**Diagnoses:** Emergent magnetic resonance imaging and plain radiograph established massive incisional and RHs. RH was shown to extend from the base of the skull to T1.

**Interventions:** An emergent surgery was performed under local anesthesia and cervical hematoma was evacuated. Nonetheless, evacuation of the blood clots in the vision field resulted into incomplete recovery of throat blockage. A gloved finger was used to explore the retropharyngeal space and some hidden blood clots were found and evacuated, then the patient obtained complete relief of the symptoms.

**Outcomes:** Normal respiration and swallowing functions were obtained after the surgery. Obviously, recovery of motor function was noted while no other complication was found at 3-month follow-up

**Lessons:** Our case illustrated that dysphagia was an early symptom of RH. Posterior compression from RH could cause obstruction of the pharyngeal airway and lead to difficulty of intubation. Hematoma could spread through the retropharyngeal space, a hematoma exploration beyond the visual range might be necessary in some cases for fear of the hidden hematoma.

**Abbreviations:** ACSS = anterior cervical spine surgeries, CT = computed tomography, MRC = Medical Research Council, MRI = magnetic resonance imaging, RH = retropharyngeal hematoma.

**Keywords:** anterior cervical spine surgery, dysphagia, dyspnea, hematoma evacuation, retropharyngeal hematoma

## 1. Introduction

Anterior cervical spine surgeries (ACSS) are among the most commonly performed procedures by spine surgeons. Its clinical outcome is excellent. Cervical hematoma is an infrequent but potentially life-threatening complication of ACSS, with acute

airway obstruction as its most commonly reported manifestation.<sup>[1,2]</sup> The reported incidence of this complication has varied from 0.2% to 5.6%.<sup>[2-5]</sup>

Management of this complication is challenging due to the often rapid onset of airway compression and limited time was available to act. Postoperative hematoma requires fast recognition and treatment decisions need to be made in a short time according to different conditions. The incidence of this complication is low, current treatment protocols are based on case reports, retrospective series with small sample sizes as well as expert opinions.<sup>[6,7]</sup> Although most cases of this complication could finally obtain complete recovery without major morbidity after timely management, challenging situations might be confronted during the treatment and catastrophic events or even deaths still occurred.<sup>[1,8,9]</sup> Herein we report a case of a male who developed massive retropharyngeal hematoma (RH) without dyspnea after ACSS. And from this case and a review of literature, we found several points needing attention for management of postoperative hematoma in this specific location.

## 2. Consent

Written informed consent was obtained from the patient for publication of this case report and accompanying images. The

Editor: N/A.

The authors have no conflicts of interest to disclose.

Department of Orthopaedics, Tongde Hospital of Zhejiang Province, Hangzhou, P.R. China.

\* Correspondence: Haiyong Ren, Department of Orthopaedics, Tongde Hospital of Zhejiang Province, No. 234 Gucui Road, Hangzhou 310012, Zhejiang Province, P.R. China (e-mail: renhaiyong1991@126.com).

Copyright © 2019 the Author(s). Published by Wolters Kluwer Health, Inc. This is an open access article distributed under the terms of the Creative Commons Attribution-Non Commercial-No Derivatives License 4.0 (CCBY-NC-ND), where it is permissible to download and share the work provided it is properly cited. The work cannot be changed in any way or used commercially without permission from the journal.

How to cite this article: Ren H, Wang J, Yu L. Retropharyngeal hematoma following anterior cervical spine surgery. *Medicine* 2019;98:38(e17247).

Received: 22 February 2019 / Received in final form: 29 July 2019 / Accepted: 26 August 2019

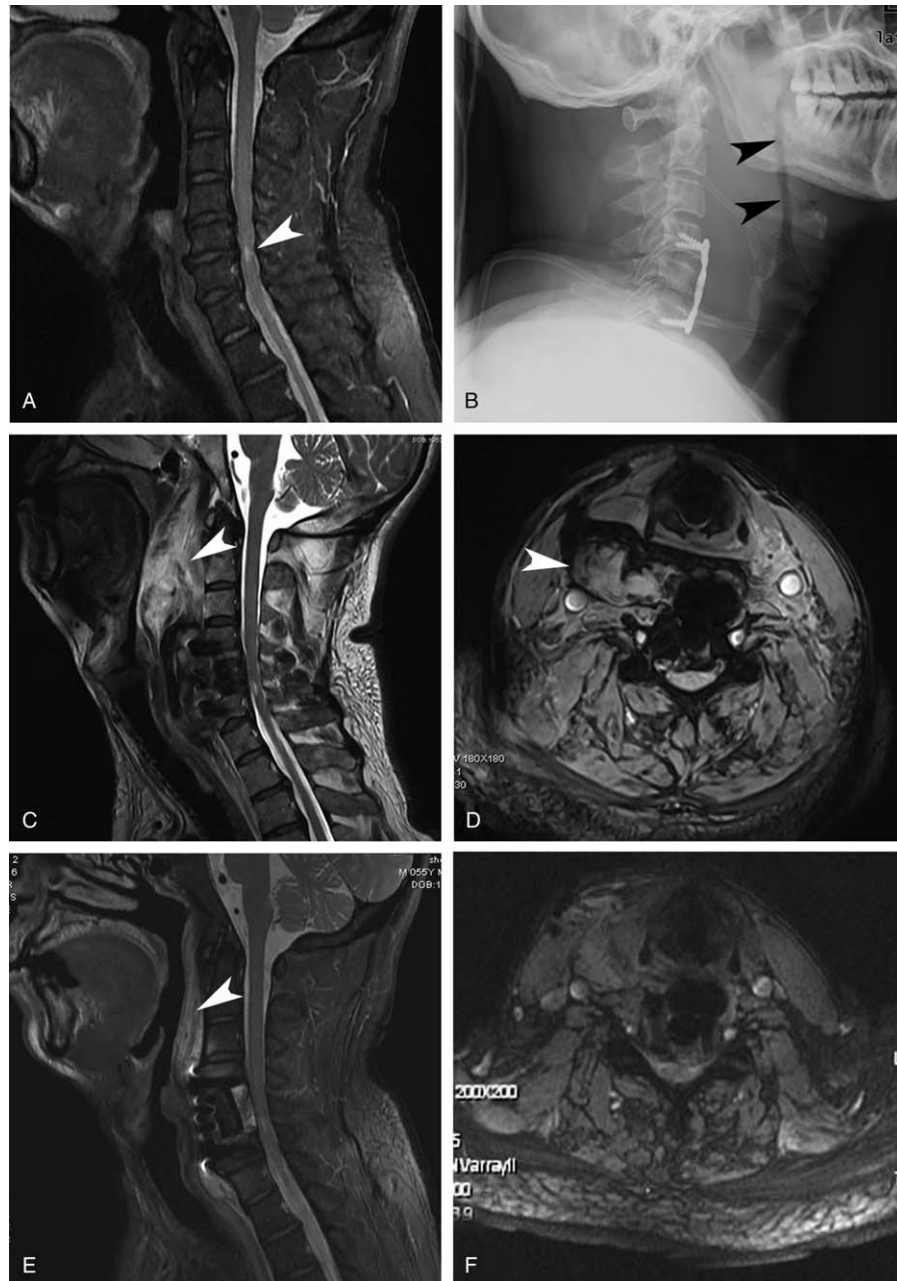
<http://dx.doi.org/10.1097/MD.00000000000017247>

ethical approval of this study was waived by the Ethics Committee of Tongde Hospital of Zhejiang Province because this study was a case report and fewer than 3 patients were involved.

### 3. Case report

A previously healthy 55 years old male presented with a 10-year history of lower extremities weakness and a 5-year history of left

upper extremity weakness, and he could only walk 20 meters before admission. Muscle strength test showed the Medical Research Council (MRC) Grade 3/5 paresis in his left triceps and bilateral iliopsoas, and MRC Grade 2/5 paresis in bilateral tibialis anterior and extensor hallucis longus. Magnetic resonance imaging (MRI) of the cervical spine showed large C4/5 and C5/6 disc herniation with severe spinal cord compression, with an abnormal hyperintense signal on T2-weighted images in spinal cord at C5/6 level (Fig. 1A). Conditions of the patient were consistent with the



**Figure 1.** Sagittal cervical spine MRI (A) showing large C4/5 and C5/6 disc herniation with severe spinal cord compression, with an abnormal hyperintense signal on T2-weighted images in spinal cord at C5/6 level (arrow head). Lateral radiograph (B) at 35 h postoperatively showing severe prevertebral swelling and the pharyngeal airway is severely compressed (arrow head), leaving a narrow gap. Sagittal T2-weighted MRI (C) at 35 h postoperatively showing massive RH extending from the base of the skull to T1 (arrow head), oropharynx and laryngopharynx is severely compressed posteriorly by hematoma, and Axial T2-weighted MRI (D) showing massive incisional hematoma between carotid sheath and trachea (arrow head). Sagittal (E) T2-weighted MRI at 5 days postoperatively showing RH apparently eliminated (arrow head), and the pharyngeal airway space is greatly wider after hematoma evacuation, and axial (F) T2-weighted MRI showing incisional hematoma is also eliminated. MRI = magnetic resonance imaging, RH = retropharyngeal hematoma.

diagnosis of cervical myelopathy. Subtotal corpectomy of C5 and reconstruction using allogenic bone graft were performed through anterior approach with only slight intraoperative bleeding. The patient felt extremities weakness relieved immediately after surgery, no difficulties in breathing, swallowing, or other complications were presented. Drainage tube was removed uneventfully 30 hours after surgery. However, 3 hours later, the patient felt cervical swelling, pressure sensation of the neck, and mild obstructive dysphagia. No breathing difficulty or abnormal vital signs was shown, oxygen saturation was >95% on room air. Cervical hematoma was primarily suspected. A sitting position was maintained and oxygen was provided but cervical swelling still progressed. As the vital sign was normal and no dyspnea or labored breathing was manifested, emergent plain radiograph and MRI was performed, and massive incisional and RHs were established (Fig. 1B–D). RH was shown to extend from the base of the skull to T1, in front of the spine. Pharyngeal airway was severely compressed posteriorly by the hematoma, leaving only a narrow gap for respiratory ventilation. Tachypnea was presented afterwards. Considering the apparent oppression of airway and progressed symptoms, emergent hematoma evacuation was then arranged. Anesthetist evaluated the patient and suggested that intubation would be difficult due to the distorted hypopharyngeal anatomy. In addition, general anesthesia might further cause muscle relaxation, leading to more severe respiratory tract compression and respiratory difficulty. Thus, an emergent surgical re-exploration was performed under local anesthesia with close monitoring. We reopened the surgical incision, a large cervical hematoma was directly viewed in the wound, further exploration with medially retraction of the trachea and esophagus found large hematoma located anterior to the cervical spine. Nonetheless, through the incision of ACSS, the exposure range is relatively limited, only the hematoma from the lower margin of C3 vertebral body to the level of upper margin of C7 vertebral body could be directly seen, hematoma at higher levels was difficult to be exposed. After the blood clots in the vision field had been evacuated, the patient regained normal breathing. Swallowing saliva was asked and he felt relieved but incomplete recovery of throat blockage. A gloved finger was used to explore the retropharyngeal space upwards and downwards, some hidden blood clots were found and evacuated at higher levels of the vision field. The patient was asked to swallow saliva again and he achieved almost complete recovery of swallowing with no apparent throat blockage. No active bleeding points were identified. Tube drainage was placed before suturing the wound. Normal swallowing function was confirmed by a standard timed 150 mL water swallow test after the surgery. Drain was removed 3 days after surgery with minimal blood drainage. Postoperatively, the patient obtained constant normal swallowing function, no abnormality of respiration and phonation was shown. MRI at 5 days postoperatively showed that retropharyngeal and incisional hematomas were apparently eliminated (Fig. 1E and F), and the pharyngeal airway space was greatly wider after hematoma evacuation. The patient achieved about 1-grade recovery of muscle power in the involved weak extremities when he discharged on day 7 postoperatively. At the 3-month follow-up visit, the motor function of the extremities was obviously recovered and no other complication was found.

#### 4. Discussion

The retropharyngeal space is a potential space of the neck and the largest interfascial compartment. It extends from the cranial base

to the posterior mediastinum.<sup>[9,10]</sup> Blood accumulation in this space causes RH. They are clinically important because of the close proximity of the retropharyngeal space to the upper airway.

Surgical exposure for ACSS creates a potential space between the carotid sheath and the midline viscera and it is posteriorly connected to the retropharyngeal space. Bleeding in any site of the surgical incision could cause blood accumulation in incision or retropharyngeal space, and the RH could bulge anteriorly into the airway and cause its obstruction.<sup>[11]</sup> RH is an infrequent complication of ACSS, and limited articles have illustrated its clinical features and management strategies.

The symptoms of RH are hoarseness, inspiratory stridor, and dysphagia, and its 3 primary signs are the Capps triad: tracheal and esophageal compression, ventral displacement of the trachea, and subcutaneous ecchymosis over the neck and anterior chest wall.<sup>[1,9,12]</sup> Our case illustrated that dysphagia was an early symptom of cervical hematoma; it could show before onset of tachypnea or dyspnea and should be given close attention after ACSS.

The diagnosis of RH is made by X-ray, computed tomography (CT), or MRI.<sup>[1,13]</sup> Lateral neck X-ray examination is a simple and useful method for detecting RH, while CT and MRI could contribute to more accurate estimation of the amount of blood clots and extent of oppression on surrounding tissues. But given the often acute onset of airway obstruction, limited time was available for these examinations. Relatively mild symptoms provided an opportunity for our case to perform radiological examinations. Massive incisional and RHs were displayed by MRI and plain radiograph in our case. And the pharyngeal airway was apparently compressed rather than the rigid trachea, leaving only a narrow gap for respiratory ventilation. Retropharyngeal space is a large potential space; large amount of hematoma could accumulate in this space before onset of breathing difficulty. Intubation would be difficult considering the distorted hypopharyngeal anatomy and it also had the risk of rupture of the hematoma resulting in bleeding in the airway. Thus we abandoned attempt of intubation and instead underwent the surgery under local anesthesia. As a matter of fact, difficulty of intubation was not a rare situation to be encountered during RH management with several cases have been reported.<sup>[11,6,9]</sup> Former articles explained difficulty of intubation by swelling of the pharyngeal wall, epiglottis and vocal cords, or shift of trachea. But MRI images of our case suggested that intubation difficulty might be due to narrowing of the pharyngeal space which caused by posterior oppression of RH. RH was shown to extend from the base of the skull to T1. However, the surgical exposure range for hematoma evacuation is relatively limited through the incision of ACSS; only the hematoma from the lower margin of C3 vertebral body to the level of upper margin of C7 vertebral body could be directly seen. After evacuation of hematoma in visual field, the patient obtained incomplete recovery of throat blockage. A gloved finger was used to explore and evacuate the hidden hematoma at higher levels beyond the vision field, and then he achieved almost complete recovery of swallowing with no apparent throat blockage. Hematoma could spread through the retropharyngeal space, and the hidden hematoma might easily be neglected during the surgery, leading to insufficient evacuation of blood clot or delayed reopening of airway compression. It is mournful that Dedouit et al reported a fatal case who manifested acute dyspnea after ACSS, intubation was unsuccessful after anesthesia and emergent hematoma evacuation was performed, but intubation was failed again after hematoma evacuation.<sup>[9]</sup>

The surgeon continued hematoma evacuation but the patient then developed cardiocirculatory arrest and unfortunately died. Massive retropharyngeal and mediastinal hematomas were finally diagnosed through medicolegal autopsy. Cervical hematoma often had an acute onset of airway obstruction and commonly no time was available for radiological examinations. We suggest a hematoma exploration beyond the visual range by gloved finger or other methods for fear of hidden hematoma presenting outside of the surgical exposure.

Conservative treatment is also a choice for RH management and several cases have been reported who had successfully recovered without surgical treatment.<sup>[4,6,7]</sup> Song et al reported a case who manifested with dyspnea and firm edema at the surgical site and the patient was treated by providing oxygen and maintaining in the sitting position.<sup>[6]</sup> Although severe prevertebral swelling was still showed on lateral radiograph at 10 days postoperatively, the patient was discharged without complications and no prevertebral swelling was showed on lateral radiograph at the 12-month follow-up. However, some authors suggested that whenever a patient presented with airway issues, reoperation was recommended and preoperative symptoms could be resolved rapidly after the evacuation.<sup>[2]</sup> Currently, no widely accepted indications were available for helping determination of management strategies. Only those patients with stable vital signs and none severe symptoms, especially excluding the manifestation of respiratory stridor, cyanosis or aggravated neurological deterioration, could consider conservative management. Meanwhile, close observation was warranted and surgical management should be readily prepared all the time. More clinical studies are demanded for the development of management guidelines for ACSS related hematoma.

It is known that only a few minutes of brain hypoxia can cause irreversible damage.<sup>[14]</sup> Repetition of failed intubation attempts should be avoided which may delay the re-establishment of the airway ventilation and even result in the rupture of the hematoma with bleeding. Furthermore, hematoma evacuation cannot guarantee the compressed airway be reopened in a short time for all patients, especially for those patients with large hematoma at hidden locations. Dedouit et al<sup>[4]</sup> presented a typical case of this situation that the patient died during the hematoma evacuation procedure. Degree of dyspnea, duration time of symptoms, as well as change of oxygen saturation and other conditions should all be monitored and assessed during the surgical management. If necessary, cricothyroidotomy, which provides a rapid means of airway ventilation, should be performed decisively.

Hematoma following ACSS may result from inadequate control of arterial or venous bleeding during the operation, coagulopathy, increased blood pressure, elevated venous pressure triggered by sneezing, violent coughing or a Valsalva, and drain removal also might contribute to the hematoma forming.<sup>[1,2,15]</sup> Presence of diffuse idiopathic skeletal hyperostosis, presence of ossification of the posterior longitudinal ligament, therapeutic heparin use, longer operative time, and greater number of surgical levels, were reported to be risk factors of postoperative RH.<sup>[2,7]</sup> Meticulous hemostasis, avoidance of prolonged or vigorous soft tissue retraction during the ACSS as well as maintaining a stable blood pressure, avoidance of sneezing, violent coughing or a Valsalva after surgery may be some measures that can prevent the emergence of a wound hematoma.

## 5. Conclusion

Blood accumulation in retropharyngeal space is an infrequent but potentially life-threatening complication of ACSS. Dysphagia was an early symptom of RH. Posterior oppression from RH could cause narrowing of the pharyngeal space and result in difficulty of intubation. Repetition of failed intubation attempts should be avoided during the hematoma surgical treatment, and cricothyroidotomy should be performed decisively if necessary. Hematoma could spread through the retropharyngeal space and locate beyond the incisional visual range. Given the often acute onset of airway obstruction, limited time was available for radiological examinations, hematoma exploration beyond the visual range for fear of hidden hematoma might be necessary in some cases.

## Author contributions

**Conceptualization:** Leijun Yu.

**Data curation:** Haiyong Ren.

**Investigation:** Haiyong Ren, Jin Wang.

**Resources:** Leijun Yu.

**Supervision:** Leijun Yu.

**Writing – original draft:** Haiyong Ren.

**Writing – review & editing:** Haiyong Ren, Jin Wang.

## References

- [1] Palumbo M, Aidlen J, Daniels A, et al. Airway compromise due to wound hematoma following anterior cervical spine surgery. *Open Orthop J* 2012;6:108–13.
- [2] O'Neill K, Neuman B, Peters C, et al. Risk factors for postoperative retropharyngeal hematoma after anterior cervical spine surgery. *Spine* 2014;39:E246–52.
- [3] Emery S, Bohlman H, Bolesta M, et al. Anterior cervical decompression and arthrodesis for the treatment of cervical spondylotic myelopathy. Two to seventeen-year follow-up. *J Bone Joint Surg Am* 1998;80:941–51.
- [4] Fountas K, Kapsalaki E, Nikolakakos L, et al. Anterior cervical discectomy and fusion associated complications. *Spine* 2007;32:2310–7.
- [5] Marotta N, Landi A, Tarantino R, et al. Five-year outcome of stand-alone fusion using carbon cages in cervical disc arthrosis. *Eur Spine J* 2011;20(Suppl 1):S8–12.
- [6] Song K, Choi B, Lee D, et al. Acute airway obstruction due to postoperative retropharyngeal hematoma after anterior cervical fusion: a retrospective analysis. *J Orthop Surg Res* 2017;12:19.
- [7] Miao W, Ma X, Liang D, et al. Treatment of hematomas after anterior cervical spine surgery: a retrospective study of 15 cases. *Neurochirurgie* 2018;64:166–70.
- [8] Sethi R, Tandon M, Ganjoo P. Neck hematoma causing acute airway and hemodynamic compromise after anterior cervical spine surgery. *J Neurosurg Anesthesiol* 2008;20:69–70.
- [9] Dedouit F, Grill S, Guilbeau-Frugier C, et al. Retropharyngeal hematoma secondary to cervical spine surgery: report of one fatal case. *J Forensic Sci* 2014;59:1427–31.
- [10] Higa K, Hirata K, Hirota K, et al. Retropharyngeal hematoma after stellate ganglion block: analysis of 27 patients reported in the literature. *Anesthesiology* 2006;105:1238–45.
- [11] Senel A, Gunduz A. Retropharyngeal hematoma secondary to minor blunt neck trauma: case report. *Rev Bras Anesthesiol* 2012;62:731–5.
- [12] Cox S, Zimmerman E, Collins D, et al. Novel multidisciplinary management of a retropharyngeal hematoma with pulmonary stenting. *J Bronchology Interv Pulmonol* 2016;23:239–41.
- [13] Duvillard C, Ballester M, Romanet P. Traumatic retropharyngeal hematoma: a rare and critical pathology needed for early diagnosis. *Eur Arch Otorhinolaryngol* 2005;262:713–5.
- [14] Busl K, Greer D. Hypoxic-ischemic brain injury: pathophysiology, neuropathology and mechanisms. *NeuroRehabilitation* 2010;26:5–13.
- [15] Yu NH, Jahng T-A, Kim CH, et al. Life-threatening late hemorrhage due to superior thyroid artery dissection after anterior cervical discectomy and fusion. *Spine* 2010;35:E739–42.