

## Case Report

# An adolescent case of familial hyperparathyroidism with a germline frameshift mutation of the *CDC73* gene

Takako Takeuchi<sup>1</sup>, Yuko Yoto<sup>1</sup>, Takeshi Tsugawa<sup>1</sup>, Hotaka Kamasaki<sup>1</sup>, Atsushi Kondo<sup>2</sup>, Jiro Ogino<sup>3</sup>, Tadashi Hasegawa<sup>3</sup>, Naoya Yama<sup>4</sup>, Sawa Anan<sup>5</sup>, Shinya Uchino<sup>6</sup>, Aki Ishikawa<sup>7</sup>, Akihiro Sakurai<sup>7</sup>, and Hiroyuki Tsutsumi<sup>1</sup>

<sup>1</sup>Department of Pediatrics, Sapporo Medical University School of Medicine, Sapporo, Japan

<sup>2</sup>Department of Otolaryngology, Sapporo Medical University School of Medicine, Sapporo, Japan

<sup>3</sup>Department of Surgical Pathology, Sapporo Medical University School of Medicine, Sapporo, Japan

<sup>4</sup>Department of Radiology Oncology, Sapporo Medical University School of Medicine, Sapporo, Japan

<sup>5</sup>Department of Pediatrics, Kinikyo Fushiko Jujo Clinic, Sapporo, Japan

<sup>6</sup>Department of Surgery, Noguchi Thyroid Clinic and Hospital Foundation, Beppu, Japan

<sup>7</sup>Department of Medical Genetics, Sapporo Medical University School of Medicine, Sapporo, Japan

**Abstract.** A 13-yr-old boy who complained of persistent nausea, vomiting and weight loss had hypercalcemia and an elevated intact PTH level. Computed tomography confirmed two tumors in the thyroid gland. The tumors were surgically removed and pathologically confirmed as parathyroid adenoma. Because his maternal aunt and grandmother both had histories of parathyroid tumors, genetic investigation was undertaken for him, and a germline frameshift mutation of the *CDC73* gene was identified. *CDC73* gene analysis should be done on individuals who are at risk of familial hyperparathyroidism, including those who are asymptomatic, and they should be followed for potential primary hyperparathyroidism and associated disorders including resultant parathyroid carcinoma.

**Key words:** hypercalcemia, primary hyperparathyroidism, *CDC73*

---

### Introduction

Primary hyperparathyroidism (PHPT) is common in the elderly, especially women, but is rare in children (1, 2). Most cases of

PHPT are sporadic, and familial cases make up less than 10% of cases (2, 3), but onset in childhood or adolescence raises concern about familial diseases with a genetic background, e.g., multiple endocrine neoplasia (MEN), hyperparathyroidism-jaw tumor (HPT-JT), familial isolated hyperparathyroidism (FIHP), and familial hypocalciuric hypercalcemia (FHH) (4). To date, several *CDC73* gene mutations in patients with HPT-JT and FIHP have been reported (2, 3, 5–14). HPT-JT and FIHP are autosomal dominant disorders, and hyperparathyroidism in these patients is often diagnosed in adolescence (15). We cared for an

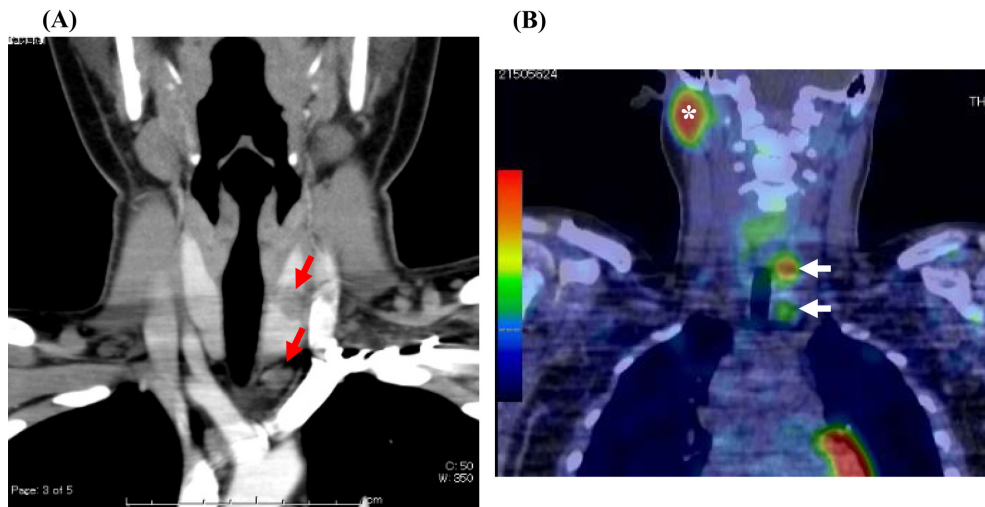
---

Received: December 5, 2014

Accepted: May 26, 2015

Corresponding author: Yuko Yoto, Department of Pediatrics, Sapporo Medical University School of Medicine, S1 W17, Chuo-ku, Sapporo 060-8556, Japan  
E-mail: yoto@sapmed.ac.jp

This is an open-access article distributed under the terms of the Creative Commons Attribution Non-Commercial No Derivatives (by-nc-nd) License <<http://creativecommons.org/licenses/by-nc-nd/3.0/>>.



**Fig. 1.** Diagnostic imaging for the left neck tumors. (A) Enhanced computed tomography of the neck. Two tumors in the left lobe and lower side of the thyroid gland are visible (red arrows). (B)  $^{99m}\text{Tc}$ -MIBI SPECT/CT fusion image. Two hot spots are present in the thyroid gland (white arrows). The upper right hot spot in the neck represents the normal right parotid gland (\*).

adolescent boy with hyperparathyroidism whose maternal grandmother and aunt, but not mother, had a history of parathyroid adenoma.

### Case Report

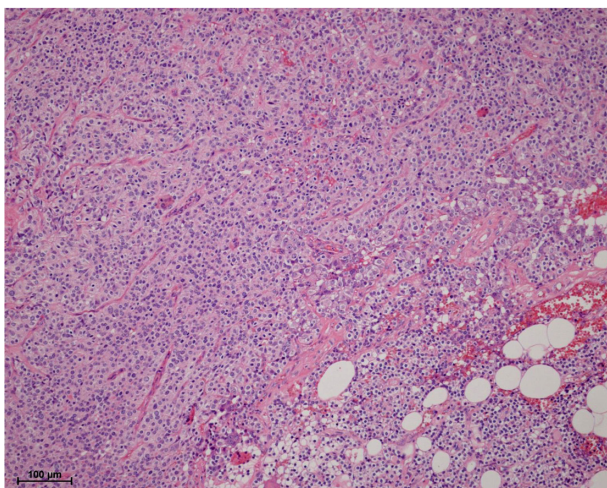
A 13-yr-old boy attended our hospital for investigation of the cause of hypercalcemia. Ten days before admission, he developed fever, cough, nausea, and vomiting. Diagnosed as having bronchitis, he was prescribed several medicines at a local clinic. Cough and fever remitted, but his nausea and anorexia persisted, and he lost weight (about 1 kg per a wk). His pediatrician arranged blood tests and discovered hypercalcemia.

After admission, his laboratory data in our department revealed hyperparathyroidism, that is, serum calcium 15.8 mg/dl, phosphate 3.0 mg/dl, intact PTH 639.2 pg/ml (reference range: 15–65 pg/ml). Total lumbar bone mineral density was only slightly decreased at 0.715 g/cm<sup>2</sup> (Z-score -1.3). There were no other endocrinological abnormalities in his laboratory data. Cervical ultrasound revealed two tumors in the left lobe of the thyroid gland. Enhanced

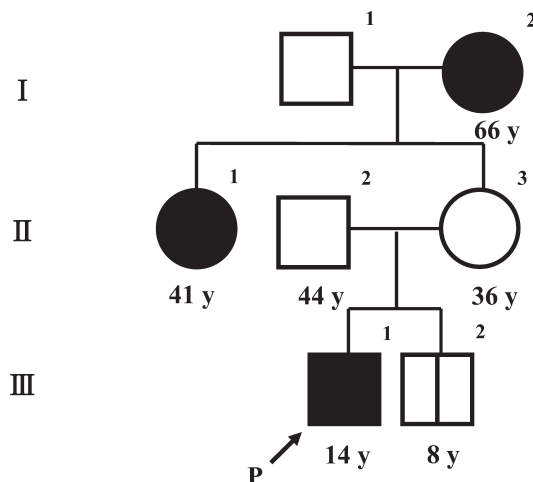
computed tomography also confirmed two mass lesions in the left lobe of thyroid gland (Fig. 1A). Two spots were detected in  $^{99m}\text{Tc}$ -MIBI SPECT/CT fusion images (Fig. 1B). Based on the diagnosis of multiple parathyroid tumors, surgery was performed, and two solid tumors were resected. Pathological examination of the tumors revealed polygonal chief cells having an acidophilic cytoplasm and variable nuclei in cords or gland-like patterns, which characterize the features of parathyroid adenoma (Fig. 2).

After parathyroidectomy, hypocalcemia developed as a consequence of an abrupt decrease in intact PTH, and transient supplements of calcium gluconate or calcium aspartate in addition to alfacalcidol were needed. His serum phosphorus level temporarily fell slightly after surgery and then gradually rose to 5 mg/dl.

He had a family history of hyperparathyroidism (Fig. 3). His maternal grandmother had undergone double parathyroidectomy when she was in her 40s. A maternal aunt had multiple parathyroidectomy when she was between 26 and 40 yr old. Meanwhile, his mother and his younger brother (8 yr old) had no apparent symptoms. We



**Fig. 2.** Histology of the parathyroid tumor. Polygonal chief cells having an acidophilic cytoplasm and variable nuclei in cords or gland-like patterns, which represents parathyroid adenoma, are present. Normal rhyme is present in the right lower side of this photo. Capsule and vascular invasions are not present.



**Fig. 3.** Pedigree diagram. The proband is III-1. His maternal grandmother (I-2) underwent parathyroidectomy when she was in her 40s. A maternal aunt (II-1) had total parathyroidectomy by the time she was 40 yr old.

performed a blood examination for his younger brother and concluded that he had no apparent hyperparathyroidism because his serum intact PTH, calcium and phosphate levels were all in normal ranges (intact PTH 62.1 pg/ml, Ca 9.3 mg/dl, P 5.3 mg/dl). A cervical ultrasound investigation was also normal. His mother did not agree to any blood tests for herself.

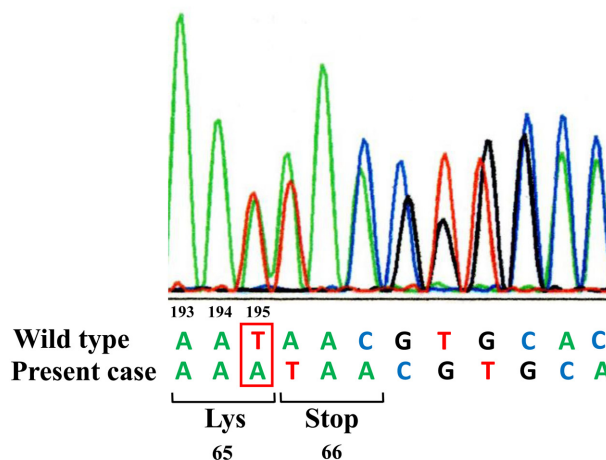
After obtaining informed consent from his parents and assent from the brothers, total DNA was isolated from leukocytes of them, and a genetic investigation was performed. No mutations were found in the *MEN1* gene, while a germline frameshift mutation (Exon 2 c. 194dupA (codon 65)) was identified in the *CDC73* gene (Fig. 4).

We examined if the brothers had any other disorders related to HPT-JT syndrome, but no abnormal findings were identified.

**Discussion**

We reported a boy who had a frameshift mutation of the *CDC73* gene, i.e., Exon 2 c.

**Exon 2 c. 194dupA (codon 65)**



**Fig. 4.** Mutation of the *CDC73* gene. DNA sequences revealed the insertion of A in one allele at nucleotide 195, resulting in a frameshift mutation at codon 65 in the *CDC73* gene. The patient’s younger brother had the same mutation.

194dupA (codon 65). This is a novel mutation in the germline, although it was initially reported in the somatic cells of a 63-yr-old man with parathyroid carcinoma (2). Our patient

was the third childhood case with familial hyperthyroidism caused by a *CDC73* gene mutation in Japan (5, 6).

*CDC73*, which encodes parafibromin, is one of the cancer suppressor genes (16–18). About 55% and 20% of cases with *CDC73* mutation develop HPT-JT syndrome and FIHP, respectively (15). These are autosomal dominant disorders, and hyperparathyroidism is often diagnosed in adolescence (15). Although FIHP manifests only PHPT, HPT-JT syndrome is characterized by other renal and bone disorders (15, 19) and by uterine cancer in women. However, co-existence of these disorders might not be detected until adult life (7–11), and this is more likely to become apparent as time passes. Our case has no other clinical symptoms except PHPT.

About 15% of cases with a *CDC73* gene mutation are complicated by parathyroid carcinoma (7, 8, 14, 20), including a few reports in young adults and adolescents (5, 12, 13). Kutcher (12) and Kelly (13) reported interesting cases with *CDC73* gene mutations who developed two parathyroid tumors, and one of the cases evolved into a parathyroid carcinoma. In our case, both tumors were diagnosed as adenomas histologically; however, further close follow-up to detect relapse of PHPT or growth of parathyroid tumors will be needed.

Most cases of PHPT with a *CDC73* gene mutation have family histories; in particular, one of the parents usually shows apparent PHPT (11–13, 15). But the mother of our case was supposedly healthy and free of any apparent symptoms of PHPT. She had not been recognized as a possible carrier of a *CDC73* gene mutation until our case was diagnosed with PHPT. Diagnosis of PHPT with a *CDC73* gene mutation may be difficult because of incomplete penetrance of PHPT and the unsettled age for onset of PHPT itself. Low penetrance of PHPT among patients with a *CDC73* gene mutation, which is estimated at 70–90% (7, 11, 14), might yield carriers who would be unaware of the possible inheritance of hyperparathyroidism in the next generation. The

younger brother of our case, who has the same *CDC73* gene mutation, might develop PHPT or parathyroid carcinoma in the future. We will follow-up each family member from different points of view, that is, early detection of recurrent PHPT and other disorders for the present case, early discovery of PHPT for the growing younger brother and recommendation of examination to find asymptomatic hypercalcemia or PHPT for their mother.

Genetic testing and biochemical screening are recommended for young patients with PHPT and in all patients with a newly diagnosed multigland disease in accordance with the proceedings of the Fourth International Workshop on the Management of Asymptomatic Primary Hyperparathyroidism (21). We should also perform *CDC73* gene analysis for asymptomatic individuals who are at risk of familial PHPT and share the genetic information with them and their families to manage not only possible future onset of PHPT and associated disorders but also the issue of transmission of the gene mutation to offspring.

## References

1. Ishida T, Yokoe T, Sensyou M. Domestic report of parathyroid tumor (cases of 1980-1989). *Endocrine Surgery* 1991;8: 37–45 (In Japanese).
2. Cetani F, Pardi E, Borsari S, Viacava P, Dipollina G, Cianferotti L, *et al.* Genetic analyses of the HRPT2 gene in primary hyperparathyroidism: germline and somatic mutations in familial and sporadic parathyroid tumors. *J Clin Endocrinol Metab* 2004;89: 5583–91. [[Medline](#)] [[CrossRef](#)]
3. Simonds WF, Robbins CM, Agarwal SK, Hendy GN, Carpten JD, Marx SJ. Familial isolated hyperparathyroidism is rarely caused by germline mutation in HRPT2, the gene for the hyperparathyroidism-jaw tumor syndrome. *J Clin Endocrinol Metab* 2004;89: 96–102. [[Medline](#)] [[CrossRef](#)]
4. Kollars J, Zarroug AE, van Heerden J, Lteif A, Stavlo P, Suarez L, *et al.* Primary hyperparathyroidism in pediatric patients.

- Pediatrics 2005;115: 974–80. [[Medline](#)] [[CrossRef](#)]
5. Mizusawa N, Uchino S, Iwata T, Tsuyuguchi M, Suzuki Y, Mizukoshi T, *et al.* Genetic analyses in patients with familial isolated hyperparathyroidism and hyperparathyroidism-jaw tumour syndrome. *Clin Endocrinol (Oxf)* 2006;65: 9–16. [[Medline](#)] [[CrossRef](#)]
  6. Yamashita Y, Akiyama T, Mizusawa N, Yoshimoto K, Goto M. A case of hyperparathyroidism-jaw tumour syndrome found in the treatment of an ossifying fibroma in the maxillary bone. *Int J Oral Maxillofac Surg* 2007;36: 365–9. [[Medline](#)] [[CrossRef](#)]
  7. Teh BT, Farnebo F, Kristoffersson U, Sundelin B, Cardinal J, Axelson R, *et al.* Autosomal dominant primary hyperparathyroidism and jaw tumor syndrome associated with renal hamartomas and cystic kidney disease: linkage to 1q21-q32 and loss of the wild type allele in renal hamartomas. *J Clin Endocrinol Metab* 1996;81: 4204–11. [[Medline](#)]
  8. Szabó J, Heath B, Hill VM, Jackson CE, Zarbo RJ, Mallette LE, *et al.* Hereditary hyperparathyroidism-jaw tumor syndrome: the endocrine tumor gene HRPT2 maps to chromosome 1q21-q31. *Am J Hum Genet* 1995;56: 944–50. [[Medline](#)]
  9. Schmidt BP, Bradrick JP, Gabali A. Hyperparathyroidism-jaw tumor syndrome: a case report. *J Oral Maxillofac Surg* 2009;67: 423–7. [[Medline](#)] [[CrossRef](#)]
  10. Mizukoshi T, Sato H, Takahashi Y, Imai K, Suzuki Y, Uchino S, *et al.* (2006) A case of familial isolated hyperparathyroidism with *HRPT2* mutation. *Nihon Naibunpitsugakkai zasshi* 2006;82: 42–5 (In Japanese).
  11. Iacobone M, Masi G, Barzon L, Porzionato A, Macchi V, Ciarleglio FA, *et al.* Hyperparathyroidism-jaw tumor syndrome: a report of three large kindred. *Langenbecks Arch Surg* 2009;394: 817–25. [[Medline](#)] [[CrossRef](#)]
  12. Kutcher MR, Rigby MH, Bullock M, Trites J, Taylor SM, Hart RD. Hyperparathyroidism-jaw tumor syndrome. *Head Neck* 2013;35: E175–7. [[Medline](#)] [[CrossRef](#)]
  13. Kelly TG, Shattuck TM, Reyes-Mugica M, Stewart AF, Simonds WF, Udelsman R, *et al.* Surveillance for early detection of aggressive parathyroid disease: carcinoma and atypical adenoma in familial isolated hyperparathyroidism associated with a germline HRPT2 mutation. *J Bone Miner Res* 2006;21: 1666–71. [[Medline](#)] [[CrossRef](#)]
  14. Bradley KJ, Cavaco BM, Bowl MR, Harding B, Cranston T, Fratter C, *et al.* Parafibromin mutations in hereditary hyperparathyroidism syndromes and parathyroid tumours. *Clin Endocrinol (Oxf)* 2006;64: 299–306. [[Medline](#)] [[CrossRef](#)]
  15. Newey PJ, Bowl MR, Cranston T, Thakker RV. Cell division cycle protein 73 homolog (*CDC73*) mutations in the hyperparathyroidism-jaw tumor syndrome (HPT-JT) and parathyroid tumors. *Hum Mutat* 2010;31: 295–307. [[Medline](#)] [[CrossRef](#)]
  16. Woodard GE, Lin L, Zhang JH, Agarwal SK, Marx SJ, Simonds WF. Parafibromin, product of the hyperparathyroidism-jaw tumor syndrome gene *HRPT2*, regulates cyclin D1/PRAD1 expression. *Oncogene* 2005;24: 1272–6. [[Medline](#)] [[CrossRef](#)]
  17. Yart A, Gstaiger M, Wirbelauer C, Pecnik M, Anastasiou D, Hess D, *et al.* The *HRPT2* tumor suppressor gene product parafibromin associates with human PAF1 and RNA polymerase II. *Mol Cell Biol* 2005;25: 5052–60. [[Medline](#)] [[CrossRef](#)]
  18. Cui C, Lal P, Master S, Ma Y, Baradet T, Bing Z. Expression of parafibromin in major renal cell tumors. *Eur J Histochem* 2012;56: e39. [[Medline](#)] [[CrossRef](#)]
  19. Carpten JD, Robbins CM, Villablanca A, Forsberg L, Presciuttini S, Bailey-Wilson J, *et al.* HRPT2, encoding parafibromin, is mutated in hyperparathyroidism-jaw tumor syndrome. *Nat Genet* 2002;32: 676–80. [[Medline](#)] [[CrossRef](#)]
  20. Sharretts JM, Simonds WF. Clinical and molecular genetics of parathyroid neoplasms. *Best Pract Res Clin Endocrinol Metab* 2010;24: 491–502. [[Medline](#)] [[CrossRef](#)]
  21. Udelsman R, Åkerström G, Biagini C, Duh QY, Miccoli P, Niederle B, *et al.* The surgical management of asymptomatic primary hyperparathyroidism: proceedings of the Fourth International Workshop. *J Clin Endocrinol Metab* 2014;99: 3595–606. [[Medline](#)] [[CrossRef](#)]