

Magnetocardiographic evaluation of nonarrhythmogenic flecainide-induced electrocardiographic T-wave inversion

Donatella Brisinda, Anna Rita Sorbo, Lara La Brocca, Riccardo Fenici
Biomagnetism and Clinical Physiology International Center, Catholic
University of Sacred Heart, Rome-Italy

Introduction

Flecainide is used for pharmacological conversion of atrial fibrillation (AF), to maintain sinus rhythm in patients with paroxysmal AF and/or supraventricular tachycardia, or to prevent catecholaminergic polymorphic ventricular tachycardia (1, 2). However, flecainide has been shown to be proarrhythmic in vitro (3) and was associated with threefold increase in arrhythmic death in Cardiac Arrhythmia Suppression Trial patients with low ejection fraction. Thus, flecainide use is restricted to patients without structural heart disease (1, 2). Reported cases showing torsade de pointes with JT/QTc interval prolongation, increased spatial dispersion of ventricular repolarization (VR), and/or T wave inversion in the electrocardiogram (ECG) precordial leads (4), even in the absence of ischemia or other cardiomyopathy, suggest that comprehensive noninvasive monitoring of VR may be useful at least during the early phase of treatment with flecainide.

In addition to 12-lead ECG, body surface electric mapping technique of contactless magnetocardiographic mapping (MCG), which measures the magnetic field (MF) generated by the same ionic currents underlying ECG, has been proposed for noninvasive imaging of VR with higher spatial and temporal resolution (5). MCG has proven more sensitive than ECG to abnormal currents associated with acute ischemia and to correlation of such events with arrhythmogenic risk (5–7).

Case Report

Presently described is the case of a 72-year-old female patient, admitted for humeral fracture, with clinical history of arterial hypertension (treated with angiotensin II receptors blocker), metabolic syndrome (treated with metformin), multifocal extrasystoles (under sotalol therapy), and no evidence of ischemic heart disease (IHD). Baseline cardiac examination and transthoracic echocardiography (TTE) were normal. ECG evidenced only nonspecific VR abnormalities (Fig. 1a) and 24-hour ECG evidenced frequent atrial (15.500/24 h) and ventricular (1910/24 h) extrasystoles. After sotalol washout, flecainide (100 mg twice a day) promptly depressed both arrhythmias (only few hundred atrial extrasystoles/24 h) with moderate increase in resting heart rate (from 52 to 78 bpm), but appearance of asymptomatic T wave inversion in V2-V6 leads (Fig. 1b) without QTc prolongation. Electrolytes and cardiac enzymes were not significantly

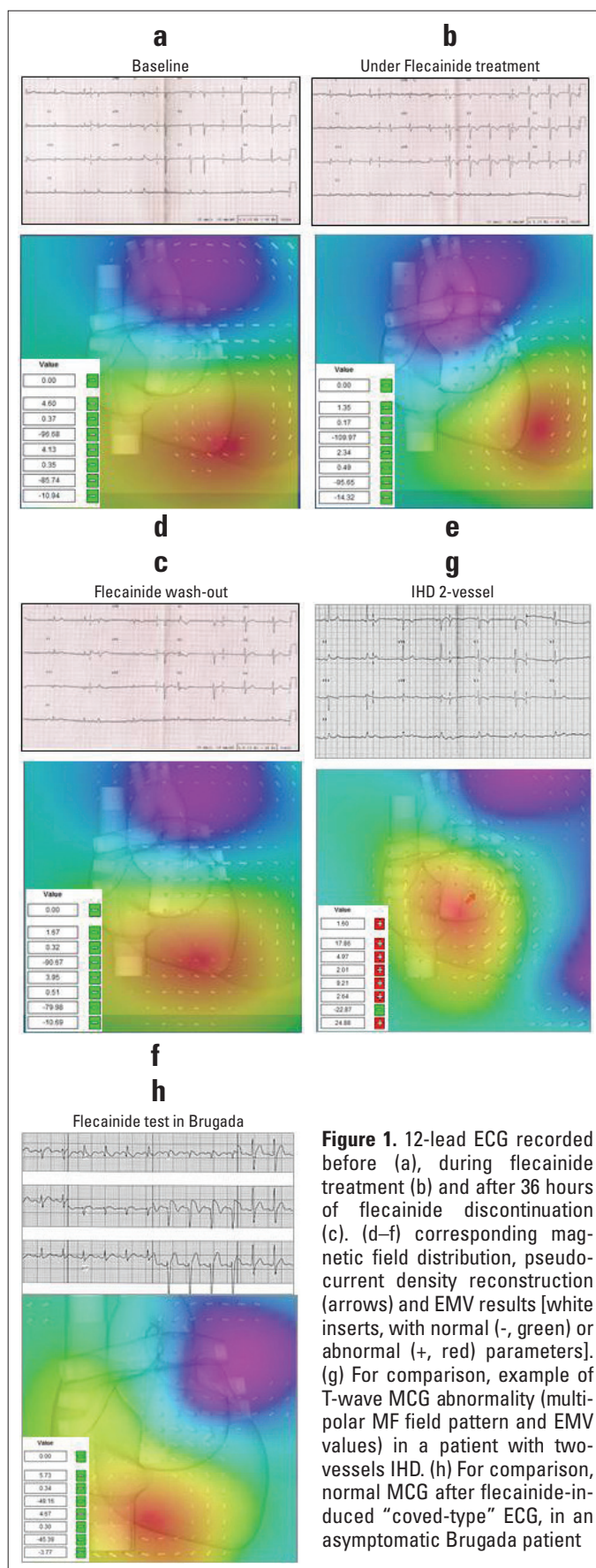


Figure 1. 12-lead ECG recorded before (a), during flecainide treatment (b) and after 36 hours of flecainide discontinuation (c). (d–f) corresponding magnetic field distribution, pseudo-current density reconstruction (arrows) and EMV results [white inserts, with normal (-, green) or abnormal (+, red) parameters]. (g) For comparison, example of T-wave MCG abnormality (multipolar MF field pattern and EMV values) in a patient with two-vessels IHD. (h) For comparison, normal MCG after flecainide-induced “coved-type” ECG, in an asymptomatic Brugada patient

Table 1. Patient's EMDV dynamics with and without flecainide

EMDV parameters	Baseline	Flecainide	Discontinuation	Normal range
Pre- T wave peak				
EMDV trajectory, cm	4.6	1.35	1.67	<7.5
EMDV angular deviation, radians	0.37	0.17	0.32	<1.0
EMDV angle, degrees	-96.68	-109.97	-90.67	>-110 and <-15
Post- T wave peak				
EMDV trajectory, cm	4.13	2.34	3.95	<5.0
EMDV angular deviation, radians	0.35	0.49	0.51	<0.7
EMDV angle, degrees	-85.74	-95.65	-79.98	>-100 and <-22
Pre-to post- T wave peak				
Difference in EMDV angle, degrees	-10.9	-14.32	10.69	>- 35 and <12
EMDV dynamics score	0	0	0	0
The automatic Effective Magnetic Dipole Vector (EMDV) analysis calculates 40 magnetic vectors at equally spaced time intervals around the peak of the T-wave (pre- and post- T wave peak). The detection of VR abnormalities is directly related to the direction and three-dimensional (3-D) dynamic motion of the EMDV around the peak of the T-wave, which is described by seven pre-defined parameters. If any of the seven parameters lies in the abnormal range a EMDV dynamics score above zero is assigned, suggestive of ischemia (see ref 6)				

altered. Nuclear imaging (SPECT) ruled out myocardial ischemia. Follow-up TTE was also normal. VR normalized within 36 hours after discontinuation of flecainide (Fig. 1c).

At first visit, after providing informed consent and in compliance with Declaration of Helsinki ethical standards, the patient underwent resting MCG (CardioMag Imaging, Inc., Latham, NY - USA) which was repeated during flecainide-induced ECG abnormalities and 36 hours after drug discontinuation. MCG was recorded with unshielded 36-channel direct current (DC) superconducting quantum interference device (sensitivity: 20 fT/ $\sqrt{\text{Hz}}$; bandwidth: DC-100 Hz; 1 kHz sampling with 24-bit analog to digital conversion) (5).

MCG provides quantitative estimate of VR through automatic effective magnetic dipole vector (EMDV) analysis during T wave (Table 1) (1, 2). Interestingly, all EMDV parameters, normal at baseline (Fig. 1d), were unchanged (Fig. 1e) during flecainide-induced VR abnormalities on ECG (Fig. 1b).

Discussion

Early diagnosis of IHD in patients with chest pain but normal ECG and cardiac enzymes may be difficult. Similarly, acute ischemic-like T wave abnormalities occurring in absence of IHD or other cardiomyopathy often require further testing with imaging methods and/or invasive angiography, which imply radiation exposure (8, 9).

Total of 90 seconds of contactless, radiation-free resting MCG recording is sufficient to detect and analyze MFs reflecting the electrical properties of the heart with high predictive accuracy to rule out acute ischemia, because impaired coronary blood flow causes typical VR MF changes (Fig. 1g) (5–7). The present case confirms that MCG excludes ischemic etiology of ECG abnormalities. Thus, if accepted as a routine diagnostic tool, MCG would avoid patient exposure to radioisotope radiation.

A possible electrophysiological mechanism underlying the flecainide-induced ECG abnormality seen in this case could be rate-dependent nonarrhythmic delay of epicardial repolarization time, inducing inversion of T-wave and arrhythmic effects reported in the literature (3, 4). Interestingly, similar MCG pattern was reported in an asymptomatic Brugada syndrome patient (with de novo missense mutation in the DII–DIII linker); although flecainide induced marked coved-type ECG, MCG VR parameters remained normal and no arrhythmia occurred during more than 15 years of follow-up (Fig. 1h) (10).

Conclusion

The normality of MCG parameters was consistent with SPECT-validated absence of myocardial ischemia and with non-arrhythmic nature of the flecainide-induced VR alteration. Whereas predictive accuracy of MCG to rule out IHD is already known (5–7), further investigation is needed to confirm MCG as a useful tool to noninvasively monitor electrophysiological effects of flecainide.

References

- Kirchhof P, Benussi S, Kotecha D, Ahlsson A, Atar D, Casadei B, et al. 2016 ESC Guidelines for the management of atrial fibrillation developed in collaboration with EACTS The Task Force for the management of atrial fibrillation of the European Society of Cardiology (ESC) Developed with the special contribution of the European Heart Rhythm Association (EHRA) of the ESC Endorsed by the European Stroke Organization (ESO). *Eur Heart J* 2016; 37: 2893-962.
- Lieve KV, Wilde AA, van der Werf C. The role of flecainide in the management of catecholaminergic polymorphic ventricular tachycardia. *Arrhythm Electrophysiol Rev* 2016; 5: 45-9.
- Krishnan SC, Antzelevitch C. Flecainide-induced arrhythmia in canine ventricular epicardium. Phase 2 re-entry?. *Circulation* 1993; 87: 562-72.

4. Osadchii OE. Flecainide-induced prolongation of ventricular repolarization contributes to the proarrhythmic profile action. *Int J Cardiol* 2015; 197: 81-2.
5. Fenici R, Brisinda D, Meloni AM. Clinical application of magnetocardiography. *Expert Rev Mol Diagn* 2005; 5: 291-313.
6. Tolstrup K, Madsen BE, Ruiz JA, Greenwood SD, Camacho J, Siegel RJ, et al. Non-invasive resting magnetocardiographic imaging for the rapid detection of ischemia in subjects presenting with chest pain. *Cardiology* 2006; 106: 270-6.
7. Kwong JS, Leithäuser B, Park JW, Yu CM. Diagnostic value of magnetocardiography in coronary artery disease and cardiac arrhythmias: A review of clinical data. *Int J Cardiol* 2013; 167: 1835-42.
8. Amsterdam EA, Wenger NK, Brindis RG, Casey DE Jr, Ganiats TG, Holmes DR Jr, et al. 2014 AHA/ACC Guideline for the management of patients with Non-ST-elevation acute coronary syndromes a report of the American College of Cardiology/American Heart Association Task Force on Practice Guidelines. *J Am Coll Cardiol* 2014; 64: e139-e228,
9. Said SA, Bloo R, de Nooijer R, Slootweg A. Cardiac and non-cardiac causes of T-wave inversion in the precordial leads in adult subjects: A Dutch case series and review of the literature. *World J Cardiol* 2015; 7: 86-100.
10. Brisinda D, Fenici R, Meloni AM, Fenici P. Multichannel magnetocardiographic mapping at rest, after effort and during flecainide test, in a patient with idiopathic brugada ECG pattern. *Biomed Tech* 2004; 48: 125-7.

Address for Correspondence: Prof. Riccardo Fenici, MD.
Biomagnetism and Clinical Physiology International Center
Catholic University of Sacred Heart, Largo A. Gemelli, 8
00168 Rome-Italy
Phone: +39 06 3051193
Fax: +39 06 3051343
E-mail: feniciri@rm.unicatt.it

©Copyright 2017 by Turkish Society of Cardiology - Available online
at www.anatoljcardiol.com
DOI:10.14744/AnatolJCardiol.2017.7556



From Prof. Dr. Arif Akşit's collections