

# A Comparative Randomized Prospective Clinical Study on Modified Erich Arch Bar with Conventional Erich Arch Bar for Maxillomandibular Fixation

V. Venugopalan, G. Satheesh, A. Balatandayoudham, S. Duraimurugan, T. S. Balaji

Department of Oral and Maxillofacial Surgery, Indira Gandhi Institute of Dental Sciences, Puducherry, India

## Abstract

**Introduction:** Erich arch bar used for maxillomandibular fixation (MMF) since decades has several disadvantages such as risks of injury, additional operating room time, and gingival trauma. To overcome these downsides, modified Erich arch bar was introduced; however, there is not much available literature, indicating the efficacy of modified Erich arch bar over that of conventional arch bar wire. Therefore, the present study focuses on comparing efficiency of modified arch bar with conventional arch bar. **Materials and Methods:** This comparative randomized study was conducted on 32 patients that required MMF and were divided into Group A patients who received intermaxillary fixation (IMF) with modified Erich arch bars and Group B patients with conventional Erich arch bars. The parameters recorded were average surgical time required, wire prick injuries, IMF stability, occlusal stability, screw loosening, oral hygiene status, and vitality response of the teeth. The variables were statistically analyzed using Student's *t*-test and Wilcoxon signed-rank test. **Results:** The wire prick injury, intraoperative time noted in Group A was significantly reduced in comparison to Group B ( $P < 0.0001$ ). Debris indices were significantly good in Group A in comparison to Group B ( $P < 0.0001$ ). Nonvitality response of tooth was significantly more in Group B than in Group A patients ( $P < 0.05$ ). **Discussion:** The efficiency of modified Erich arch bar group was superior to the conventional arch bar with very limited restrictions.

**Keywords:** Mandibular fracture, maxillomandibular fixation, modified Erich arch bar, surgical time, tooth vitality

## INTRODUCTION

Immobilization is the most important part in management of facial bone fracture. "Wiring the jaw shut" is a proven method of allowing fracture to heal and ensuring that future occlusion is normal. Since then, different methods with various uses and shapes have been incorporated in the management of patients with maxillofacial trauma.<sup>[1]</sup> The frequently used methods for attaining intermaxillary fixation (IMF) include arch bars, eyelet wiring, direct interdental (Gilmer) wiring, and IMF screws.<sup>[1]</sup>

Since ages, the most time-tested and cost-effective method followed for IMF is interdental wiring using Erich arch bars on the mandibular and maxillary teeth.<sup>[2]</sup> Although reliable, they nevertheless have certain fundamental drawbacks. Most of these techniques are wired around the cervical tooth portion and, therefore, are likely to cause ischemic necrosis<sup>[3]</sup> and trauma to the marginal gingiva and the adjacent mucosa.<sup>[4]</sup> These techniques have presented with poor patient compliance owing

to difficulty in maintaining good oral hygiene often paving way to gingival and periodontal disease conditions. They also carry a menace of needle stick injury often leading to potentially fatal disease conditions such as hepatitis and other blood borne disorders. There is also extrusion of the teeth on which perpetual traction is applied. In addition, these techniques cannot be used in patients with partially edentulous arches or periodontally compromised patients. They are also inapplicable for patients with extensive crown and bridge work.<sup>[5]</sup>

**Address for correspondence:** Dr. V. Venugopalan,  
Department of Oral and Maxillofacial Surgery, Indira Gandhi Institute of  
Dental Sciences, Puducherry - 607 402, India.  
E-mail: abilashv3@gmail.com

**Received:** 21-01-2020

**Revised:** 04-06-2020

**Accepted:** 20-08-2020

**Published:** 04-11-2020

This is an open access journal, and articles are distributed under the terms of the Creative Commons Attribution-NonCommercial-ShareAlike 4.0 License, which allows others to remix, tweak, and build upon the work non-commercially, as long as appropriate credit is given and the new creations are licensed under the identical terms.

**For reprints contact:** WKHLRPMedknow\_reprints@wolterskluwer.com

**How to cite this article:** Venugopalan V, Satheesh G, Balatandayoudham A, Duraimurugan S, Balaji TS. A comparative randomized prospective clinical study on modified erich arch bar with conventional erich arch bar for maxillomandibular fixation. *Ann Maxillofac Surg* 2020;10:287-91.

### Access this article online

Quick Response Code:



**Website:**  
www.amsjournal.com

**DOI:**  
10.4103/ams.ams\_20\_20

To overcome these shortcomings, the preference can be given for the use of Erich arch bar with screws as a method for IMF that can be applied promptly and painlessly. Accessibility, rapidity, shortened operating time, and minimal distress to the gingival margin are obvious advantages of Erich arch bar with IMF, the disadvantages being cost factor and the risk of root injury.<sup>[6]</sup> Recently, a new modification of the conventional Erich arch bar has been improved by Queiroz in 2012 to overcome these disadvantages.<sup>[7]</sup> Perforations were carved in between the winglets using a No. 701 bur. This modified Erich arch bar is positioned by creating a gap in the interradiolar spaces of the maxillary and mandibular arches with 1.3 mm bur and the arch bar is locked using 1.5 mm screws (2 screws anterior and 2 screws posterior), thus avoiding the hazard of root injuries.<sup>[7]</sup>

The main advantage of modified Erich bar is that in case of multiple fractures, distribution of force with elastics is much more efficient than IMF screws. Mucosal coverage of the screw head is not noticed in modified Erich arch bar when compared with IMF screws. Hardware ingestion and aspiration which is a common complication in IMF screws is not observed in modified technique.<sup>[7,8]</sup>

However, there is not much available documentation about the efficacy of this modified Erich arch bar. Therefore, the present study was done to gauge the advantages, disadvantages, efficiency, and probable complications such as incidence of wire prick as well as iatrogenic injury to the patient associated with Erich arch bar versus modified Erich arch bar in the management of maxillary and mandibular fractures.

## MATERIALS AND METHODS

### Study design

This present comparative randomized study was conducted at the department of oral and maxillofacial surgery from April 2015 to December 2016. Before commencement of the study, ethical approval was attained from the Institutional Ethical Committee (IGIDSIEC2015NDP01PGVVOMS). Prior informed consent was obtained from the study subjects. A total of 32 patients of either gender between 15 and 60 years with a nonpathological fracture of the mandible, maxillary fractures where occlusion was affected, that required maxillomandibular fixation (MMF) for intraoperative/definitive reduction were included in this study.<sup>[8,9]</sup>

Patients who fall under American Society of Anesthesiologists III and IV, edentulous patients, comminuted fracture of facial bone (in maxilla/mandible), pathologic fractures, multiple fractures (parasymphysis with angle, maxillary fractures, and associated condylar fractures), comorbidities such as fractures in other bones (femur fractures, pelvic bone fractures, etc.), and patients having primary and mixed dentition were excluded from this study.<sup>[8,9]</sup>

A random selection of patients into Group A receiving IMF with modified Erich arch bars, and Group B receiving IMF with conventional Erich arch bars was done.

### Data collection

Demographic data, including age and gender of the subjects, were recorded. In Group A, open reduction and internal fixation were done after careful analysis of interradiolar space with the help of investigations such as prefabricated cast model of maxillary and mandibular arches and panoramic radiograph. After analyzing the interradiolar space, three perforations were made in the maxilla and mandible correlating to the arch bar holes which were made pre-operatively. The modified arch bar was taken to the preferred length. To prevent ischemic necrosis of the mucosa, screws were not to be overtightened. The first hole was directed between the incisors, so that enough holes would correlate with the interradiolar spaces needed for the settlement of the arch bar. MMF fixation was achieved by wiring or elastics<sup>[8,9]</sup> [Figure 1].

The dimension of the screw to stabilize/fix the Modified Arch bars was 1.5 mm width and 6 mm in length screws. The screws were placed for 4–6 weeks. The fixation of the screws was estimated instantly postinsertion, using an intraoral periapical radiograph or panoramic radiograph and a secondary radiograph after screw removal. A follow-up of 1 month following the removal of the arch bar and IMF screws were included<sup>[9]</sup> [Figure 2].

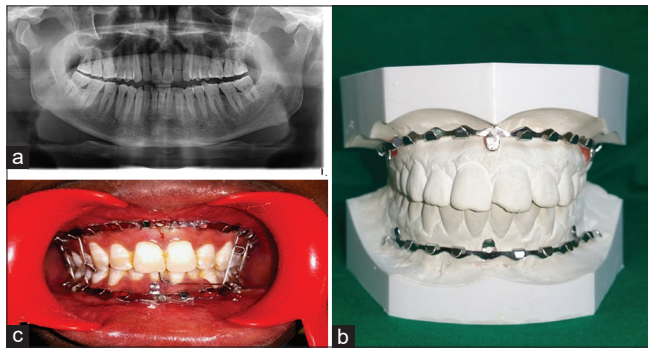
The conventional Erich arch bar was placed in Group B patients using a 26 gauge pre-stretched 18–8 stainless steel wire. Open reduction and internal fixation of all the cases were uniformly done using conventional miniplate system/screw system with single design and configuration, i.e., with 2 mm 4-hole plate with a gap in all cases following Champy's lines of osteosynthesis. To correct minor discrepancies in occlusion, the arch bar was placed for 4 weeks to enable the postoperative traction.<sup>[9,10]</sup>

The duration for the surgical procedure required in minutes from the start of procedure till IMF was achieved. Needle stick/wire prick injury and incidence of perforations in the gloves of the surgeon and primary assistant were identified by water inflation method.<sup>[11]</sup> At the time of arch bar removal, tooth vitality was checked using electronic pulp tester (Vitality Scanner™ 2006), a diagnostic tool traditionally used to determine the vitality of dental pulp preoperatively and postoperatively.<sup>[9,10]</sup> Oral hygiene was assessed using the Oral Hygiene Index-Simplified (OHI-S)<sup>[12]</sup> by examination of debris, stains, and calculus on specific surfaces of 6 index teeth that included the buccal and lingual surfaces of maxillary and mandibular molars and central incisors.<sup>[12]</sup> The Index values were calculated using the debris score and calculus score. The average individual or group score was known as the Simplified Debris Index (DI-S) and Simplified Calculus Index (CI-S), respectively. The combination of these scores gave the Simplified Oral Hygiene Index. The CI-S and DI-S values may range from 0 to 3; the OHI-S values from 0 to 6.<sup>[12]</sup>

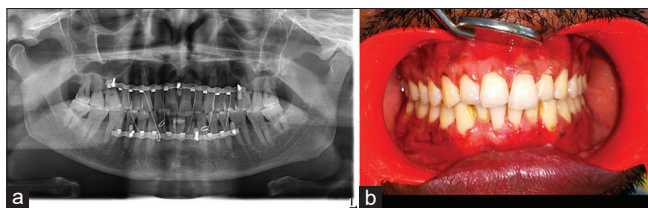
In both groups, surgeon-induced injuries to the tooth, IMF stability, and postoperative occlusion were also noted. Intraoperative pain assessment was done using visual analog scale (VAS score), a psychometric pain measuring instrument that consists of a horizontal line with verbal descriptors at each end to express the extremes of feeling.<sup>[13]</sup>

### Statistical analysis

The data were analyzed using R statistical software (version 4.0.1), Auckland, New Zealand. The compiled information comprising of potential complications, frequency of mucosal tears, root perforations and comparison of postoperative stability, occlusion, and device replacement was investigated using Student's *t*-test. Wilcoxon signed-rank test was used to assess the debris index and calculus index between the groups.  $P < 0.05$  was considered statistically significant.



**Figure 1:** (a) Preoperative X-ray image. (b) Prefabricated model of modified arch bar. (c) Intra-operative image of modified Erich arch bar placed in the mouth



**Figure 2:** (a) Representative image of a postoperative X-ray image. (b) Representative image post removal of modified Erich arch bar

## RESULTS

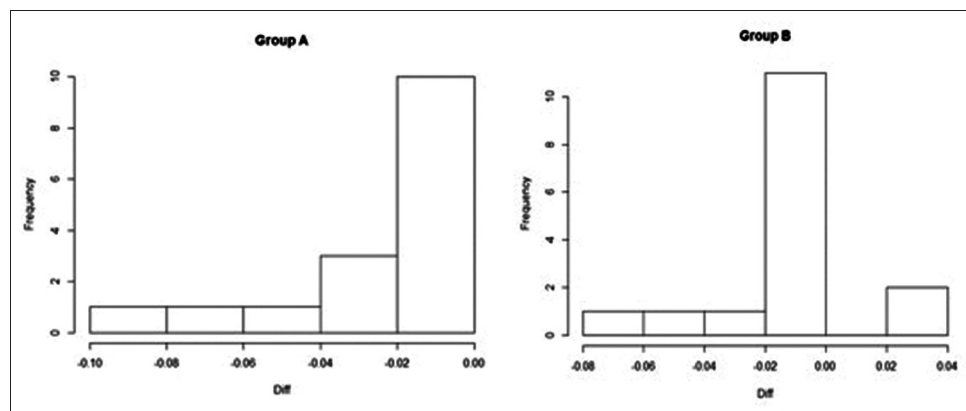
Of the 32 patients enrolled for the study, there were 15 males and 1 female in Group B and 16 males in Group A. The mean age of the patient in Group A and B was 31.93 years and 34.12 years, respectively. Most reported fracture was parasymphiseal fracture (Group A - 8 patients; Group B - 12 patients) followed by symphysis fracture (Group A - 2; Group B - 3), condyle (Group A - 3; Group B - 0), mandibular angle fracture (Group A - 1; Group B - 0); Le Fort I (Group A - 1; Group B - 0), and Le Fort II fractures (Group A - 1; Group B - 1).

Needle prick/wire prick injury to the surgeons and assistants were reported to be 18.8% in Group A and 56.3% in Group B ( $P = 0.0005$ ). There was one screw loosened in 4 cases in Group A, whereas the frequency of one screw loosened in Group B was zero which was also statistically significant. The median operating time of Group A was significantly less than the median operating time of Group B. As per the VAS scale, the pain during procedure was significantly less in Group A than in Group B. There was no reported frequency of mucosal tear in modified arch bar, unlike that in conventional arch bar group that revealed 4 mucosal tears in 6.3% of the patients [Table 1].

Group A patients recorded 1 case of postoperative instability, whereas there were 21 patients in Group B with postoperative instability. Requirement of device replacement was more in Group B (15) unlike Group A (14). The postoperative occlusion was found satisfactory in 15 patients in Group A, which was parallel to Group B [Table 2]. The mean of debris index was significantly lower in Group A than Group B ( $P < 0.005$ ). Statistically insignificant difference was observed for Calculus index between the groups [Table 3]. Significantly increased nonvital tooth response was observed in Group B than in Group A ( $P < 0.005$ ) [Figure 3].

## DISCUSSION

Even though arch bars deliver an active and resourceful means of MMF, their use is not without concern. To overcome the



**Figure 3:** A comparative histogram depicting tooth vitality difference between Group A and Group B

**Table 1: Distribution of potential complications and intraoperative time and pain between two groups**

	Count	Group		P
		A (%)	B (%)	
Wire prick/needle stick injury	0	13 (81.3)	2 (12.5)	0.0005*
	1	3 (18.8)	9 (56.3)	
	2	0	5 (31.3)	
Screws loosened	0	9 (56.3)	16 (100.0)	0.003*
	1	4 (25.0)	0 (0)	
	2	0 (0)	3 (18.8)	
Intraoperative time <sup>a</sup>		21.81±1.32	76.25±6.19	<0.0001*
Pain <sup>b</sup>		15.9	49.2	<0.0001*
Mucosal tear	0	16 (100.0)	3 (18.8)	
	1	-	7 (43.8)	
	2	-	3 (18.8)	
	3	-	2 (12.5)	
	4	-	1 (6.3)	

\*Significant. <sup>a</sup>Wilcoxon rank-sum test; <sup>b</sup>T-Student's *t*-test. Group A=Modified Erich arch bar; Group B=Conventional Erich arch bar

**Table 2: Comparison of postoperative stability, occlusion, and device replacement between groups**

Variables	Group A (%)	Group B (%)	Total (%)
Postoperative stability			
Stable	14 (87.5)	15 (93.8)	29 (90.6)
Unstable	1 (6.3)	21 (2.5)	3 (9.4)
Device replacement			
Not required	2 (12.5)	1 (6.3)	3 (9.4)
Required	14 (87.5)	15 (93.8)	29 (90.6)
Postoperative occlusion			
Stable occlusion	15 (93.8)	15 (93.8)	30 (93.8)
Unstable occlusion	1 (6.3)	1 (6.3)	2 (6.3)

\*Significant. Group A=Modified Erich arch bar; Group B=Conventional Erich arch bar

**Table 3: Comparison of debris index and calculus index on the 4<sup>th</sup> week after device removal between groups**

	Group A	Group B	P
Debris index	0.80±0.18	1.97±0.38	<0.05
Calculus index	0.323±0.095	0.322±0.183	0.6741

Wilcoxon rank-sum test for debris index; *t*-test for calculus index. Group A=Modified Erich arch bar; Group B=Conventional Erich arch bar

drawbacks of traditional arch bars, the current document highlights the efficacy of modified Erich arch bar wires.

The maximum intraoperative time duration for arch bar fixation was less for modified arch bar group which was in line with the study done by Ingole *et al.* who reported that the time taken for intraoperative procedure with modified Erich arch bar was 2.1 min unlike 6 min for conventional arch bar wires.<sup>[14]</sup>

Our results revealed the frequency of wire prick injury and mucosal tear was far less with the usage of modified Erich arch wire bar than the conventional arch wires which was in

agreement with the research by Qureshi *et al.* who reported that the wire prick injury and mucosal tear was observed more with conventional Erich arch wire (20 cases) and only 2 cases with modified Erich arch wire.<sup>[15]</sup> The possible reason for this could be the manifestation of extended wires in conventional arch bars.

The postoperative stability, occlusion was better in patients with modified Erich arch wire than the conventional arch bars.<sup>[16]</sup> Device replacement was required more in conventional arch wires. These observations were parallel to the Balakrishna *et al.*'s study who reported 80% stability in postoperative occlusion of patients who were treated with modified Erich arch bar.<sup>[17]</sup>

Oral hygiene was observed to be significantly enhanced postoperatively after scrupulous oral hygiene instructions with modified arch bars than with the conventional Erich arch bars. In the current study, only 2 cases in Group A, the oral hygiene was poor credited to patient's negligence. The findings were substantiated with the results of various studies reported in literature that revealed significantly good oral hygiene in Group A patients than Group B patients.<sup>[18-20]</sup>

A study conducted by Kirk *et al.* concluded that vitality test was positive in 60% of cases managed with conventional arch bar whereas vitality test was positive in 100% of the cases managed with modified arch bar.<sup>[21]</sup> These findings were parallel with our study where nonvitality of teeth was seen maximum in conventional Erich arch bar group.

The pragmatic reason for the efficiency of modified arch bar wires could be attributed to the fact that modified arch bar were adapted to the vestibular surface of the maxilla and mandible, and not to the cervical portion of the teeth and perforations were made in the interradicular spaces, thus avoiding the chances of root perforation, tooth nonvitality and necrosis of the gingival tissues and restoring adequate postoperative occlusal stability as well.

The results accomplished in the current document provide adequate novelty, indicating that modified arch bar technique is a good alternative to conventional arch bars for temporary IMF in mandibular and other facial fractures which required IMF as the modified arch bar provides greater stability between the screws with no incidence of bending, bowing or deformation of segments of arch bar used as observed in the current study. It is, thus, an innocuous and effective technique; however, with restrictions or possible consequences about which the surgeon must be mindful of to provide effective and safe treatment.

The study has a few potential limitations as well. First, the modified arch bar technique although safe is still not indicated in incidents of comminute fractures where the role of tension band and postoperative directional traction is a prerequisite, pediatric patients, and patients with severe osteoporosis. These outcomes must be judiciously interpreted, and it needs advanced investigations to be executed on a big sample size

along with specificity of technique to extend their use in the management of other facial fractures.

## CONCLUSION

IMF with modified Erich arch bars is more efficient when equated to the conventional Erich arch bars in the treatment of MMF fractures. Even though both devices offer a better temporary fixation intraoperatively to evaluate occlusion and for postoperative IMF, the modified Erich arch bar greatly diminishes the operating time and the risk of needle stick and wire prick damages to the operating surgeon and assistant and consequently the spread of blood borne diseases was reduced. They are also concomitant to minimal trauma for the periodontium; and good patient compliance compared to conventional arch bars and serves as an effective substitute to traditional arch bar for the management of facial and mandibular fractures.

## Financial support and sponsorship

Nil.

## Conflicts of interest

There are no conflicts of interest.

## REFERENCES

1. Hashemi HM, Parhiz A. Complications using intermaxillary fixation screws. *J Oral Maxillofac Surg* 2011;69:1411-4.
2. Rai A, Datarkar A, Borle R, Rai M. Comparative assessment between eye let wiring and direct interdental wiring for achieving intermaxillary fixation: A prospective randomized clinical study. *J Oral Maxillofac Surg* 2012;70:1914-7.
3. Satish M, Rahman NM, Reddy VS. Use of cortical bone screws in maxillofacial surgery a prospective study. *J Int Oral Health* 2014;6:62-7.
4. Ghazali N, Benlidayi ME, Abizadeh N, Bentley RP. Leonard buttons: A reliable method of intraoperative intermaxillary fixation in bilateral mandibular fractures. *J Oral Maxillofac Surg* 2012;70:1131-8.
5. Rai A, Datarkar A, Borle RM. Are maxillomandibular fixation screws a better option than Erich arch bars in achieving maxillomandibular fixation: A randomized clinical study. *J Oral Maxillofac Surg* 2011;69:3015-8.
6. Engelstad ME, Kelly P. Embrasure wires for intraoperative maxillomandibular fixation are rapid and effective. *J Oral Maxillofac Surg* 2011;69:120-4.
7. de Queiroz SB. Modification of arch bars used for intermaxillary fixation in oral and maxillofacial surgery. *Int J Oral Maxillofac Surg* 2013;42:481-2.
8. Sahoo NK, Sinha R, Menon PS, Sharma R. Retrospective Study on efficacy of intermaxillary fixation screws. *Med J Armed Forces India* 2009;65:237-9.
9. Mansuri S, Abdulkhayum AM, Gazal G, Hussain MA. Treatment of mandibular angle fracture with a 2mm, 3-dimensional rectangular grid compression miniplates: A prospective clinical study. *J Int Oral Health* 2013;5:93-100.
10. Purmal K, Alam MK, Pohchi A, Hayati N, Razak A. 3D mapping of safe and danger zones in the maxilla and mandible for the placement of intermaxillary fixation screws. *PLoS One* 2013;8:e84202.
11. Rai A. A simple method of preventing needle stick type injury to the operator's finger while performing intermaxillary fixation. *J Maxillofac Oral Surg* 2014;13:215-6.
12. Greene JC, Vermillion Jr. The simplified oral hygiene index. *J Am Dent Assoc* 1964;68:7-13.
13. Coletti DP, Salama A, Caccamese JF Jr. Application of intermaxillary fixation screws in maxillofacial trauma. *J Oral Maxillofac Surg* 2007;65:1746-50.
14. Ingole PD, Garg A, Sheno SR, Badjate SJ, Budhreja N. Comparison of intermaxillary fixation screw versus eyelet interdental wiring for intermaxillary fixation in minimally displaced mandibular fracture: A randomized clinical study. *J Oral Maxillofac Surg* 2014;72:958.e1-7.
15. Qureshi AA, Reddy UK, Warad NM, Badal S, Jamadar AA, Qurishi N. Intermaxillary fixation screws versus Erich arch bars in mandibular fractures: A comparative study and review of literature. *Ann Maxillofac Surg* 2016;6:25-30.
16. Barker GR. A modified arch bar for immobilisation of the jaws following trauma and facial deformity surgery. *Br J Oral Maxillofac Surg* 1986;24:143-6.
17. Nandini GD, Balakrishna R, Rao J. Self-tapping Screws v/s Erich arch bar for inter maxillary fixation: A comparative clinical study in the treatment of mandibular fractures. *J Maxillofac Oral Surg* 2011;10:127-31.
18. Jones DC. The intermaxillary screw: A dedicated bicortical bone screw for temporary intermaxillary fixation. *Br J Oral Maxillofac Surg* 1999;37:115-6.
19. Poeschl PW, Ploder O, Seemann R, Poeschl E. Maxillomandibular fixation using intraoral cortical bone screws and specially designed metal hooks (Ottenhaken) in the conservative treatment of mandibular fractures. *J Oral Maxillofac Surg* 2008;66:336-41.
20. Florescu VA, Kofod T, Pinholt EM. Intermaxillary fixation screw morbidity in treatment of mandibular fractures a retrospective study. *J Oral Maxillofac Surg* 2016;74:1800-6.
21. Kirk D, Whitney J, Shafer D, Song L. Tight placement of Erich arch bar while avoiding wire fatigue failure. *J Oral Maxillofac Surg* 2016;74:562-8.