



Received: 2016.05.13
Accepted: 2016.05.30
Published: 2017.01.09

Authors' Contribution:

- A** Study Design
- B** Data Collection
- C** Statistical Analysis
- D** Data Interpretation
- E** Manuscript Preparation
- F** Literature Search
- G** Funds Collection

Scalloping Characteristics in a Patient with Extra-Cranial Hemangioma

Amit Agrawal^{1ABCDEF}, Ranjan K. Jena^{1ABCDEF}, Umamaheswara Reddy V.^{2ABCDEF}

¹ Department of Neurosurgery, Narayana Medical College Hospital, Chinthareddypalem, Nellore, Andhra Pradesh, India

² Department of Radiology, Narayana Medical College Hospital, Chinthareddypalem, Nellore, Andhra Pradesh, India

Author's address: Amit Agrawal, Department of Neurosurgery, Narayana Medical College Hospital, Chinthareddypalem, Nellore-524003, Andhra Pradesh, India, e-mail: dramitagrawal@gmail.com

MeSH Keywords:

Hemangioma, Capillary • Pectinidae • Scalp

PDF file:

<http://www.polradiol.com/abstract/index/idArt/899536>

Summary

Infantile hemangiomas are the most common benign tumors of infancy and childhood with a reported incidence of 4% to 10% in infants. We report of a 9 year-old male child with a history of progressively increasing swelling over the right eyebrow region. The lesion was present since childhood; however, it increased in size over the previous 3–4 months. The CT scan showed scalloping over the right supra-orbital ridge with an intact bone. The child underwent total excision of the lesion. A characteristic scalloping seen on imaging (depression in the outer or inner table of the skull) can help differentiate lesions of extracranial and intracranial origins.

Dear Editor,

Infantile hemangiomas are the most common benign tumors of infancy and childhood with a reported incidence of 4% to 10% in infants [1]. The majority of them are located in the head and neck region [2]. A 9 year-old male child presented with a history of progressively increasing swelling over the right eyebrow region. The lesion was present since childhood; however, it increased in size over the previous 3–4 months. The lesion was not associated with pain. There was no history of trauma, fever, headache or seizures. There was no history of visual disturbances. Local examination revealed a 3×3 cm, soft, fluctuant swelling over the right eye brow region (Figure 1). The swelling was non-pulsatile and there was no bruit. Skin over the swelling was healthy and there was a palpable depression over the right supra-orbital ridge. The trans-illumination test was negative. The CT scan showed scalloping over the right supra-orbital ridge with an intact bone (Figure 2). An initial diagnosis of calvarial hemangioma was made. Because the parents feared that accidental injury can lead to a rupture of the lesion and as the lesion was growing in size, a decision to excise the lesion was made. The child underwent a total excision of the lesion. Intra-operatively, there was smooth scalloping of the right frontal bone (Figure- 3). Histopathology confirmed the diagnosis of infantile hemangioma. The child was in good condition on one-year follow-up.

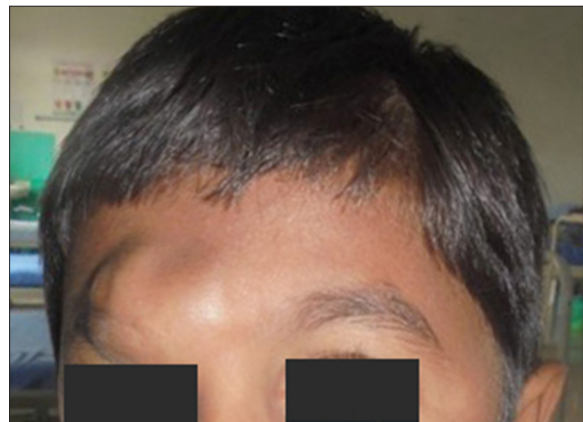

Figure 1. Clinical photography showing a large lesion over the right supra-orbital region covered by normal and healthy skin.

The clinical presentation of infantile hemangioma depends on the age of the child, size of the lesion, its extent and morphological characteristics[1,3,4]. Many of these lesions can proliferate rapidly during early infancy but most of the superficial hemangiomas (80%) achieve maximum growth by 3 months of age [5]. It is reported that discoloration of the skin usually disappears in children aged 5 to 7 years, and skin appears normal in at least 50% of them [6]. Many other congenital and acquired lesions of the scalp

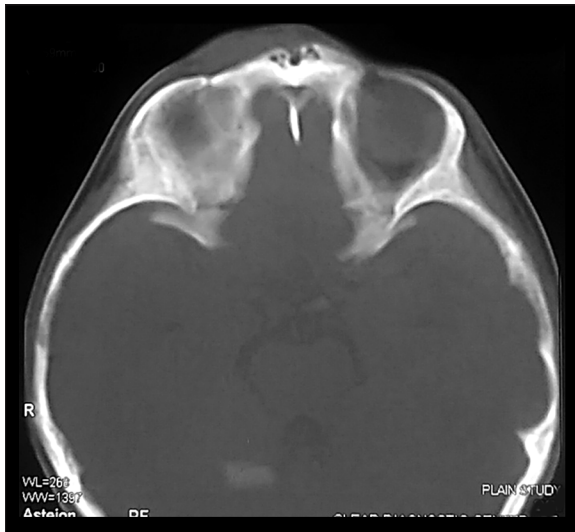

Figure 2. CT scan of the brain (bone window) showing a hypodense, well-defined extracranial swelling over the right supra-orbital region producing a characteristic "scalloping sign".

and calvarial region (including scalp dermoid, sebaceous cysts, lipomas, hemangiomas, anterior meningoencephalocele, cephalhematoma, subgaleal hematoma, lymphangioma, sinus pericranii and abscess) need to be considered in the differential diagnosis of scalp hemangioma in children [7–11]. Based on clinical presentation and examination, scalp infantile hemangiomas (which are usually soft and non-pulsatile masses) can be differentiated from other lesions [4,12]. Computerized tomography (CT scan) with in the bone window is the most appropriate investigation to see the details of the scalp and calvarial lesions (intra-cranial versus extra-cranial location and extent) and to help decide on subsequent management [8,9,13–15]. A

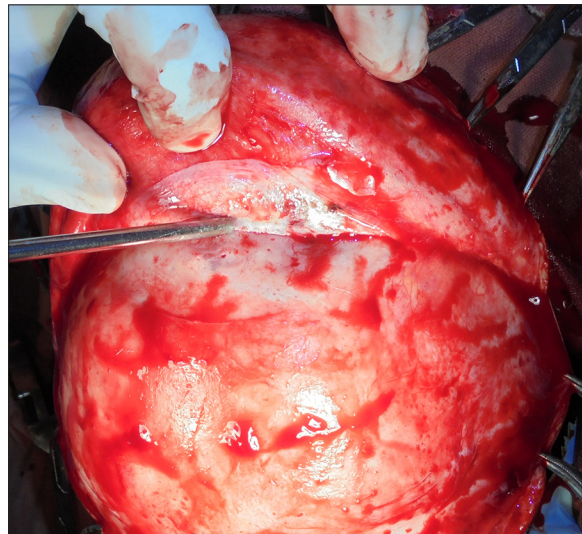


Figure 3. Intra-operative photograph showing a depression in the outer table of the calvaria in the supra-orbital region.

characteristic scalloping on imaging (depression in the outer or inner table of the skull) has been described to differentiate between extracranial and intracranial origin of these lesions (extra-cranial lesions produces depression in the outer table of the skull and intra-cranial lesions produces depression in the inner table of the skull) [8,9,13,15,16]. It has been described that infantile hemangiomas can also produce a similar mass effect on the local skeleton [6] and can create scalloping in the bone giving rise scalloping signs. For smaller calvarial hemangiomas, a conservative approach has been recommended. For larger lesions or the lesions which continue to grow or produce cosmetic deformity, a complete surgical excision (to avoid ulceration and hemorrhage) is recommended [1,6,17–21].

References:

- Mulliken JB, Rogers GF, Marler JJ: Circular excision of hemangioma and purse-string closure: the smallest possible scar. *Plast Reconstr Surg*, 2002; 109: 1544–54; discussion 1555
- Fishman SJ, Mulliken JB: Vascular anomalies. A primer for pediatricians. *Pediatr Clin North Am*, 1998; 45: 1455–77
- Mulliken JB, Glowacki J: Hemangiomas and vascular malformations in infants and children: A classification based on endothelial characteristics. *Plast Reconstr Surg*, 1982; 69: 412–22
- Finn MC, Glowacki J, Mulliken JB: Congenital vascular lesions: Clinical application of a new classification. *J Pediatr Surg*, 1983; 18: 894–900
- Maguiness SM, Frieden IJ: Management of difficult infantile haemangiomas. *Arch Dis Child*, 2012; 97: 266–71
- Marler JJ, Mulliken JB: Current management of hemangiomas and vascular malformations. *Clin Plast Surg*, 2005; 32: 99–116
- Adeloye A, Odeku EL: Congenital subgaleal cysts over the anterior fontanelle in Nigerians. *Arch Dis Child*, 1971; 46: 95–98
- Agrawal A, Goel S, Trehan S et al: Scalloping characteristics in anterior fontanelle dermoid cyst. *J Pediatr Neurosci*, 2011; 6: 92–93
- Aslan O, Ozveren F, Kotil K et al: Congenital dermoid cyst of the anterior fontanelle in Turkish children – four case reports. *Neurol Med Chir (Tokyo)*, 2004; 44(3): 150–52
- de Aquino HB, de Miranda CCV, de Britto Filho CA et al: Congenital dermoid inclusion cyst over the anterior fontanel: Report of three cases. *Arq Neuropsiquiatr*, 2003; 61(2B): 448–52
- Glasauer FE, Levy LE, Auchterlonie WC: Congenital inclusion dermoid cyst of the anterior fontanel. *J Neurosurg*, 1978; 48: 274–78
- Enjolras O, Mulliken JB, Boon LM et al: Noninvoluting congenital hemangioma: A rare cutaneous vascular anomaly. *Plast Reconstruct Surg*, 2001; 107: 1647–54
- Agrawal A, Pratap A, Sinha AK et al: Epidermoid cyst of anterior fontanelle with clear contents. *Surg Neurol*, 2007; 68: 313–15; discussion 316
- Parmar H, Gujar S, Shah G, Mukherji SK: Imaging of the anterior skull base. *Neuroimaging Clin N Am*, 2009; 19(3): 427–39
- Agrawal A, Santhi V, Reddy VU: Subgaleal dermoid cyst of the anterior fontanelle in a child. *The Egyptian Journal of Radiology and Nuclear Medicine*, 2015; 46: 1171–74
- Ogle RF, Jauniaux E: Fetal scalp cysts – dilemmas in diagnosis. *Prenat Diagn*, 1999; 19: 1157–59
- Enjolras O, Gelbert F: Superficial hemangiomas: Associations and management. *Pediatr Dermatol*, 1997; 14: 173–79
- Hsiao C-H, Tsao P-N, Hsieh W-S, Chou H-C: Huge, alarming congenital hemangioma of the scalp presenting as heart failure and Kasabach-Merritt syndrome: A case report. *Eur J Pediatr*, 2007; 166: 619–20
- Schneider D, Lee MS, Harrison AR, Sidman J: Excision of periorbital hemangiomas to correct visual abnormalities. *Arch Facial Plast Surg*, 2011; 13: 195–98
- Bowers R, Graham E, Tomlinson K: The natural history of the strawberry nevus. *Archives of Dermatology*, 1960; 82: 667–80
- Khan IS, Kiehna EN, Satti KF et al: Surgical management of large scalp infantile hemangiomas. *Surg Neurol Int*, 2014; 5: 41