

Teaching Point  
(Section Editor: F.P. Schena)

## JC viraemia in kidney transplant recipients: to act or not to act?

N. Rao<sup>1</sup>, S. Schepetiuk<sup>2</sup>, M. Choudhry<sup>1</sup>, R. Juneja<sup>1</sup>, G. Passaris<sup>1</sup>, G. Higgins<sup>2</sup> and J. Barbara<sup>1</sup>

<sup>1</sup>Department of Nephrology, Flinders Medical Centre and Flinders University, Bedford Park, SA, Australia and <sup>2</sup>Microbiology and Infectious Diseases, Institute of Medical and Veterinary Sciences, Adelaide, SA, Australia

Correspondence and offprint requests to: Nitesh Rao; E-mail: nitesh.rao@health.sa.gov.au

**Keywords:** immunosuppression; JC virus; renal transplantation

### Introduction

Human polyomaviruses have entered the domain of clinical decision-making in renal transplantation and this has coincided with the use of more potent immunosuppressive regimens. BK polyomavirus has predominated, resulting in nephropathy and ureteral strictures with the potential for graft loss [1]. JCV is a type of human polyomavirus, named with the initials of the patient from whom the virus was first isolated. JC polyomavirus is known to cause progressive multifocal leukoencephalopathy (PML) which has been reported in the renal transplant population [2]. Polymerase chain reaction (PCR) screening for BK polyomavirus in the early post-transplant period is routinely performed worldwide but is not known to occur for JC polyomavirus.

### Case report

#### Case 1

A 52-year-old man with end-stage renal failure secondary to presumed hereditary nephritis received a renal allograft from a deceased donor in May 2008 and had a 2 of 6 HLA (human leucocyte antigen) match. He received immunosuppression with basiliximab, tacrolimus, mycophenolate mofetil and prednisolone. JC virus was detected in the plasma 5 months after transplantation (Tables 1 and 2; Figure 1). As this was the first case of JC virus detection in a renal allograft recipient in our centre, he underwent a magnetic resonance imaging scan of his head which was normal. His immunosuppression was altered by replacing mycophenolate mofetil with azathioprine (1 mg/kg) and aiming for a tacrolimus level of 5 µg/L (12 h trough) (Table 3). JC virus PCR in the plasma became negative 3 months after the conversion.

#### Case 2

A 22-year-old man with end-stage renal failure secondary to posterior urethral valves received a pre-emptive renal transplant in November 2008 from a living-related donor (one haplotype match). He experienced

complications post-transplantation which included delayed graft function, urosepsis and distal ureteric ischaemia. He underwent reimplantation of his transplant ureter. Once again, immunosuppression took the form of basiliximab, tacrolimus, mycophenolate mofetil and prednisolone. JC virus was detected in the plasma 6 months post-transplantation during routine screening for polyomavirus. The immunosuppressive regimen was altered by replacing mycophenolate mofetil with azathioprine (1 mg/kg) and the 12-h trough level for tacrolimus was reduced to 5 µg/L. JC virus PCR in the plasma became negative 3 months after conversion.

#### Case 3

A 65-year-old man with end-stage renal failure secondary to IgA nephropathy received a renal allograft in May 2009. The allograft was from a deceased donor with no HLA match. The immunosuppressive treatment was the same as in Cases 1 and 2. He became PCR positive for JC virus in the plasma 4 months post-transplantation. Mycophenolate mofetil was again replaced by azathioprine (1 mg/kg) and tacrolimus trough levels were targeted to 5 µg/L. He became PCR negative for JC virus in the plasma 5 months later.

In all three patients there was no deterioration in renal function. BK virus was not detected in the plasma or urine of these patients. There was no clinical evidence for PML and all three cases remain positive for JC virus in the urine.

### Discussion

Human populations are continuously exposed to BK and JC polyomaviruses. Both viruses are closely related to 70% homology at the nucleic acid level and considered harmless in immunocompetent hosts. Low-level replication has been observed in 5–20% of healthy individuals and involves JC virus in 95% of cases, whereas BK virus is shed only intermittently, in <5% of cases [1–3]. BK polyomavirus reactivation usually occurs 3 months post-transplantation, whereas JC polyomavirus viraemia is seen earlier [4].

**Table 1.** JC virus detection and clearance; immunosuppression at the time of detection

Case	Plasma positive (months post-transplantation)	Urine positive (months post-transplantation)	Plasma negative (months post-transplantation)	Tacrolimus level (12-h trough level in µg/L)	Mycophenolate level (12-h trough level in mg/L)	Prednisolone dose (mg/day)
1	5	4	8	7.6	1.95	10
2	6	5	9	7.8	3.88	10
3	4	4	9	6.8	2.40	10

**Table 2.** JC viral loads detected by PCR

Case	At detection		Current status	
	Plasma (copies/mL)	Urine (copies/mL)	Plasma (copies/mL)	Urine (copies/mL)
1	3900	51 100	0	4960
2	8330	85 000	0	2080
3	6880	160 million	0	54 000

### Should we screen for JC virus?

JC virus PCR is not routinely performed in renal transplant recipients in most centres. In the cases presented here JC virus was detected when PCR-specific probes (see supplementary material) for JC virus were utilized [2, 4]. This is now done as a standard practice in our centre whenever we screen for BK virus. Eighteen out of the 80 recipients screened over 3 years for polyomavirus in our centre had JC viraemia, including the three cases mentioned above who had viraemia. Whilst there is published literature available for BK virus screening, detection and management, the same cannot be said of JC virus, and its implications for renal transplantation are uncertain [1, 5]. It would be prudent to screen for this virus given the potential for renal injury or PML and the more frequent use of mycophenolate mofetil and rituximab in our immunosuppressive protocols.

### What level of JC viraemia predisposes to renal injury or PML?

Although there is literature on the viral load and renal damage by BK virus, there is little evidence to show correlation between viral loads and clinical implication in JC virus. The main concern for these three cases was the potential risk of developing PML given the detected presence of JC viraemia and being immunosuppressed [5, 6]. Our aim was therefore to clear the plasma of JC virus and this was achieved in all three cases by modifying the immunosuppression.

### What modification of immunosuppression should be undertaken?

Manitpisitkul *et al.* [7] provided data suggesting that reducing the tacrolimus dose has a prominent role in controlling BK virus reactivation and replication. However, there have also been concerns about the association of mycophenolate mofetil with PML [8, 9].

In our three cases we decided to decrease the tacrolimus dose and cease mycophenolate mofetil, given our

experience with reducing tacrolimus in BK viraemia and concerns of association of mycophenolate mofetil with PML. The tacrolimus dose was reduced, aiming for 12-h trough levels of 5 µg/L. Mycophenolate mofetil was substituted by azathioprine. Shah *et al.* and Remuzzi *et al.* [10, 11] report that azathioprine and mycophenolate mofetil provide comparable long-term outcomes in renal transplant patients.

In addition to the reduction in the immunosuppression, intravenous immunoglobulin therapy, cidofovir and conversion from tacrolimus to sirolimus have also been shown to be beneficial in JC virus nephropathy [5, 12, 13].

It is thought that JC virus can cause significant interstitial inflammation and fibrosis resulting in renal dysfunction [2, 5, 9]. Nine cases of PVAN (polyomavirus-associated nephropathy) due to JC virus have been reported so far. The three cases described here did not demonstrate any significant loss of renal function and therefore did not undergo renal biopsy [5].

The therapeutic armamentarium for transplant immunosuppression continues to broaden with agents such as belatacept, sotrastaurin, tofacitinib and alefacept. It is interesting to note that there have been case reports of PML and PVAN with the use of belatacept [14].

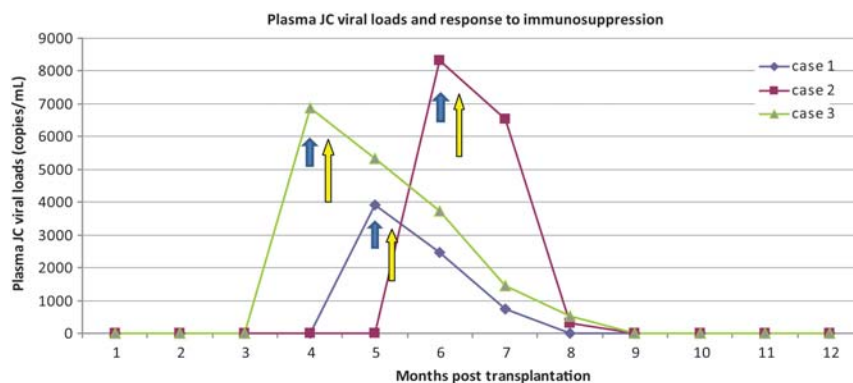
In the three cases described in our report, JC viraemia was detected early in the post-transplant period and the viraemia was cleared within 5 months of detection. The significance of persistent JC virus in the urine is yet to be determined.

One can only speculate about the true incidence and prevalence of JC viraemia post-renal transplantation and its possible impact on long-term renal allograft function or presentation with PML. However, given our present immunosuppressive regimens and the potential for JC viraemia to cause harm, it would seem prudent to screen for this virus and alter the immunosuppression accordingly.

Although there have been previous reports on JC viraemia in renal transplant recipients, this report provides additional support for the screening of JC virus in this population and also demonstrates that prompt identification and modification of immunosuppression can eliminate viraemia, thereby reducing the risk for PML.

### Teaching points

- (i) It is important to screen for JC virus in kidney transplant recipients, given the more frequent use of tacrolimus and mycophenolate mofetil combinations and the use of rituximab in our immunosuppressive protocols.
- (ii) Prompt recognition and reduction in immunosuppression can result in the clearance of viraemia thereby reducing the risk for PML and graft dysfunction.



**Fig. 1.** Blue arrows indicate the modification in immunosuppression; yellow arrows indicate the substitution of mycophenolate mofetil with azathioprine.

**Table 3.** Current plasma JCV status, renal function and immunosuppressive regimen

Case	Plasma JCV status (months post-transplant)	Serum creatinine (µmol/L)	Azathioprine (mg)	Tacrolimus (12-h trough, µg/L)	Prednisolone (mg/day)
1	Negative at 36	85	100	5.9	8
2	Negative at 30	170	75	5.2	5
3	Negative at 17	90	100	5.6	5

**Supplementary data**

Supplementary data is available online at <http://ckj.oxfordjournals.org>.

**Authors' contributions**

N.R. was involved in the management of the involved patients and compiling the manuscript. J.A.J.B. was involved in compiling the manuscript and the management of involved patients. S.S. and G.H. developed the in-house technique of detection of JC virus and conducted the tests. M.C. was involved in compiling the manuscript. G.P. was involved in the management of patients. R.J. was involved in patient management and compiling the manuscript.

*Conflict of interest statement.* None declared.

**References**

1. Wiseman AC. Polyomavirus nephropathy: a current perspective and clinical considerations. *Am J Kidney Dis* 2009; 54: 131–142
2. Drachenberg CB, Hirsch HH, Papadimitriou JC. Polyomavirus BK versus JC replication and nephropathy in renal transplant recipients: a prospective evaluation. *Transplantation* 2007; 84: 323–330
3. Hussein MI, Anastasi B, Singer J et al. A comparative study of Merkel cell, BK and JC polyomavirus infections in renal transplant recipients and healthy subjects. *J Clin Virol* 2010; 49: 137–140
4. Saundh BK, Tibble S, Baker R. Different patterns of BK and JC polyomavirus reactivation following renal transplantation. *J Clin Pathol* 2010; 63: 714–718

5. Kantarci G, Eren Z, Demirağ A. JC virus-associated nephropathy in a renal transplant recipient and comparative analysis of previous cases. *Transpl Infect Dis* 2010. doi:10.1111/j.1399-3062.2010.00567.x
6. Nickleit V, Mihatsch MJ. Polyomavirus nephropathy in native kidneys and renal allografts: an update on an escalating threat. *Transpl Int* 2006; 19: 960–973
7. Manitpisitkul W, Drachenberg C, Ramos E et al. Maintenance immunosuppressive agents as risk factors for BK virus nephropathy: a case-control study. *Transplantation* 2009; 88: 83–88
8. Weber SC, Uhlenberg B, Raile K. Polyoma virus-associated progressive multifocal leukoencephalopathy after renal transplantation: regression following withdrawal of mycophenolate mofetil. *Pediatr Transplant* 2010. doi: 10.1111/j.1399-3046.2010.01368
9. Michael M, Magali M, Radermacher J et al. Incidence of polyomavirus nephropathy in renal allografts: influence of modern immunosuppressive drugs. *Nephrol Dial Transplant* 2003; 18: 1190–1196
10. Shah S, Collett D, Johnson R et al. Long term graft outcome with mycophenolate mofetil and azathioprine: a paired kidney analysis. *Transplantation* 2006; 82: 1634–1639
11. Remuzzi G, Cravedi P, Costantini M et al. Mycophenolate mofetil versus azathioprine for prevention of chronic allograft dysfunction in renal transplantation: The MYSS follow-up randomized, controlled clinical trial. *J Am Soc Nephrol* 2007; 18: 1973–1985
12. Nickleit V, Singh HK, Mihatsch MJ. Polyomavirus nephropathy: morphology, pathophysiology, and clinical management. *Curr Opin Nephrol Hypertens* 2003; 12: 599–605
13. Johnston O, Jaswal D, Gill JS et al. Treatment of polyomavirus infection in kidney transplant recipients: a systematic review. *Transplantation* 2010; 89: 1057–1070
14. Durrbach A, Pestana JM, Pearson T et al. A phase III study of belatacept versus cyclosporine in kidney transplants from extended criteria donors (BENEFIT-EXT study). *Am J Transplant* 2010; 10: 547–557

Received for publication: 21.5.12; Accepted in revised form: 27.7.12