



Since January 2020 Elsevier has created a COVID-19 resource centre with free information in English and Mandarin on the novel coronavirus COVID-19. The COVID-19 resource centre is hosted on Elsevier Connect, the company's public news and information website.

Elsevier hereby grants permission to make all its COVID-19-related research that is available on the COVID-19 resource centre - including this research content - immediately available in PubMed Central and other publicly funded repositories, such as the WHO COVID database with rights for unrestricted research re-use and analyses in any form or by any means with acknowledgement of the original source. These permissions are granted for free by Elsevier for as long as the COVID-19 resource centre remains active.

Specific Diseases of the Respiratory System: Upper Airway

David Jardine, Omar J. Bhutta, and Andrew Inglis

PEARLS

- Diseases leading to compromise of the airway are the most frequent cause of cardiac arrest in pediatric patients. A small reduction in the caliber of the child's airway may lead to a life-threatening reduction of airflow.
- Laryngomalacia is the most common congenital anomaly of the larynx. Infants tend to outgrow this problem during the first year of life; however, the condition may be of sufficient severity in some infants that activities such as feeding are compromised.
- The trachea may be compressed by the presence of an abnormal vascular structure. Children affected by this problem may have such diverse symptoms as stridor, wheezing, lobar atelectasis, or recurrent pulmonary infections.
- The practice of treating laryngotracheobronchitis with corticosteroids is standard of care, especially for hospitalized patients. A meta-analysis in which the efficacy of corticosteroids was evaluated suggests that corticosteroids may reduce the need for endotracheal intubation and hasten improvement when given in the first 24 hours of illness.
- Epiglottitis, a bacterial infection of the supraglottic tissues historically caused by *Haemophilus influenzae* type B, is now most frequently caused by group A β -hemolytic streptococcus.
- Patients with bacterial tracheitis usually do not respond to inhaled racemic epinephrine, have a high fever, and appear very ill.

Diseases leading to compromise of the airway are the most frequent cause of cardiac arrest in pediatric patients. Prompt recognition of these illnesses can lead to timely intervention and improve the outcome of these patients. The small size of the infant's trachea makes airway obstruction more likely and particularly dangerous. The normal anteroposterior diameter of the infant's glottis is 4.5 mm. One millimeter of circumferential tracheal edema reduces the glottic lumen to 30% of its normal size. Poiseuille's law stipulates that laminar flow of gas through a tube is inversely proportional to the fourth power of the radius of the lumen:

$$R = \frac{8ln}{\pi r^4}$$

where R is the resistance to gas flow, l is the length of the tube, n is the viscosity of the gas, and r is the radius. Unfortunately, airflow through a narrowed trachea is usually turbulent, which worsens the situation because resistance to turbulent flow of gas past an obstruction is inversely proportional to the fifth power of the radius of the lumen.^{1,2} Gas exchange will be dramatically reduced by minor degrees of impingement on an infant's trachea. Consequently, a child will not tolerate lesions that would not even produce symptoms in an adult.

Initial Management

Once the diagnosis of upper airway obstruction is made, efforts should be undertaken to minimize disturbing the patient unless the respiratory embarrassment is severe enough to be life-threatening. Airway obstruction often worsens when infants and children are alarmed during a diagnostic evaluation. Humidified oxygen should be administered through a nasal cannula or facemask. These devices may frighten younger children who may more readily accept oxygen delivered through flexible tubing held by the parent. If the child will tolerate placement of a pulse oximeter probe, this provides a noninvasive way of evaluating oxygenation. If oxygen saturation by pulse oximeter measurement is within an acceptable range (>95%), arterial blood gas determination may be unnecessary. An arterial blood gas is useful to identify the patient who may be hypercapnic, but to obtain these data may further upset the child.

After upper airway obstruction has been diagnosed, a combination of physical and radiographic findings may help localize the lesion. With identification of the anatomic site of the lesion, the diagnostic possibilities are greatly narrowed. During the diagnostic evaluation, the child may sit in the parent's lap if this reduces anxiety. This position usually does not interfere with diagnostic evaluation, like lateral neck and chest radiography. The dose of radiation to a nonpregnant parent is small and should be of little concern.

If it is thought to be safe, examination of the patient's head and neck may reveal the cause of the illness. Depending on the patient's condition, the degree of respiratory embarrassment may be quantified with a rating scale (Table 44-1). One of the primary benefits of using such a scale is that signs of respiratory obstruction are systematically sought and objectively documented. This information may be valuable in helping

Table 44-1 Subjective Assessment of Clinical Severity of Laryngotracheobronchitis

	0	1	2	3
Stridor	None	Mild	Moderate at rest	Severe on inspiration and expiration or none with markedly decreased air entry
Retractions	None	Mild	Moderate	Severe, marked use of accessory muscles
Air entry	Normal	Mild decrease	Moderate decrease	Marked decrease
Color	Normal	Normal (0 score)	Normal (0 score)	Dusky or cyanotic
Level of consciousness	Normal	Restless when disturbed	Anxious, agitated; restless when undisturbed	Lethargic, depressed

From Davis HW, Gartner JC, Galvis AG, et al: Acute upper airway obstruction: croup and epiglottitis, *Pediatr Clin North Am* 28:859, 1981.

to define the course of the patient's illness and the response to treatment. During the initial evaluation, an assessment may be made regarding the likely location of the obstruction. Extrathoracic airway obstruction usually results in stridor (the obstruction is most severe during inspiratory phase), while intrathoracic airway obstruction usually results in wheezing (the obstruction is most severe during expiratory phase). Localizing the obstruction in this manner helps to narrow the diagnostic possibilities.

The initial evaluation should allow one to make important triage decisions about management and further evaluation of the patient with upper airway compromise. Depending on the severity of the illness, a decision must be made about which diagnostic tests will be undertaken. In the case of severe respiratory compromise, it may be necessary to plan for invasive procedures (endotracheal intubation or operative intervention) while the diagnostic evaluation is being performed. Finally, it should not be forgotten that pulmonary edema might follow relief of severe upper airway obstruction.³ Postobstructive pulmonary edema may be severe enough to require vigorous therapy, including endotracheal intubation, mechanical ventilation, and positive end-expiratory pressure.

Congenital Malformations

A variety of congenital malformations can affect the pediatric airway. Many of these become evident in the delivery room. Some congenital malformations do not present until the child is older and somatic growth has made the airway impairment more evident.

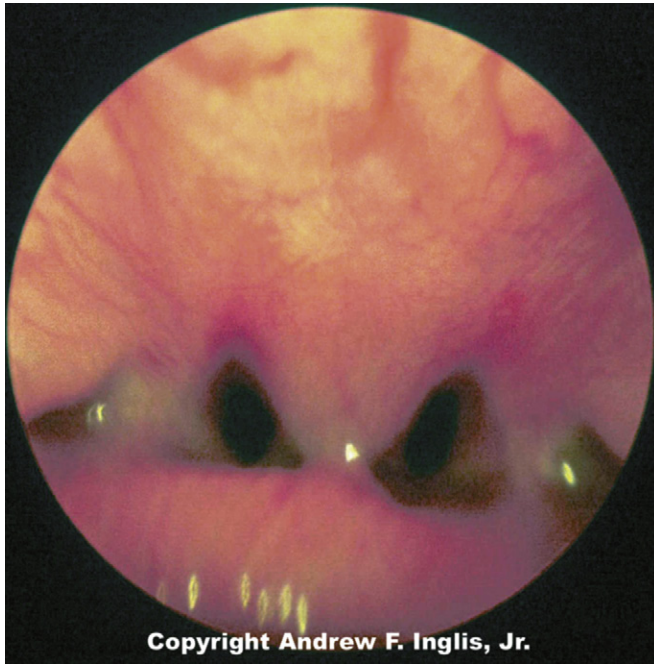
Choanal Atresia

Choanal atresia is estimated to occur about once in every 5000 to 9000 live births.⁴ Choanal atresia is seen commonly with other defects, especially CHARGE syndrome, which accounts for 25% of all patients with choanal stenosis.⁵ Unilateral choanal atresia, the most common form, is often seen without accompanying congenital defects and may not be diagnosed at the time of delivery. Bilateral choanal atresia almost always occurs in the presence of other congenital defects.⁵ For the first 5 months of life, many infants breathe only through their noses and do not open their mouths when the nasal passages are occluded; consequently, bilateral choanal atresia often results in respiratory distress shortly after birth. Bilateral choanal atresia (Figure 44-1) is diagnosed through examination of the naris with the mouth closed. If no airflow is present, a presumptive diagnosis of choanal atresia is established. Some

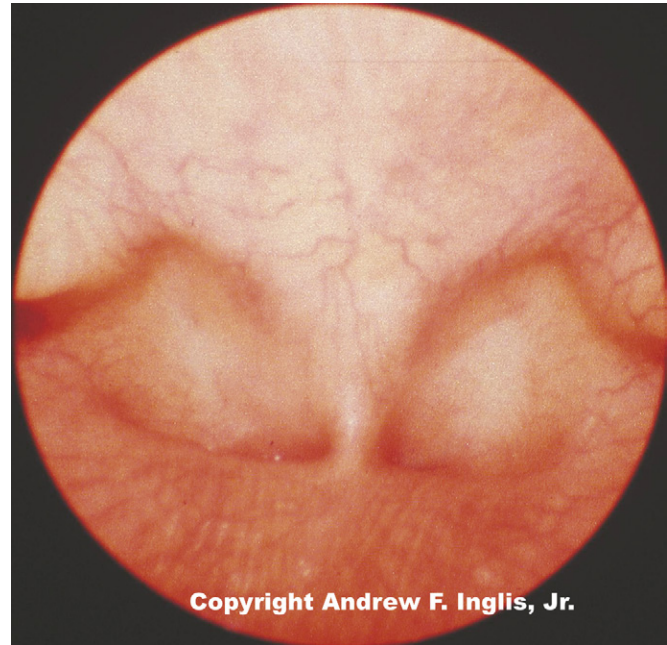

Figure 44-1. Choanal atresia before repair. View of choanal atresia from posterior nasopharynx. There is complete absence of choanae. (Copyright Andrew F. Inglis Jr.)

authorities advocate passing a thin, flexible catheter through the naris. This will confirm the diagnosis of choanal atresia; however, if the symptoms are resulting from choanal stenosis, edema formation following even minor trauma of the nasal mucosa after catheter placement may lead to complete occlusion of the nasal airway and worsening of respiratory distress. Surgery is indicated for the correction of bilateral choanal atresia if the infant has symptoms⁶ (Figure 44-2). Infants with bilateral choanal atresia generally have surgery within the first 3 months of life, while infants with unilateral choanal atresia typically have surgery after the second year of life.⁷ Topical application of mitomycin to inhibit fibroblast proliferation has been shown to be an effective adjunct to surgical repair of choanal atresia.⁸ Although choanal atresia is the most common cause of nasal airway obstruction, midline nasal masses such as meningoencephaloceles, gliomas, or dermoid tumors can also cause obstruction. Because these lesions may originate from within the cranial vault, computed tomography (CT) scanning or magnetic resonance imaging (MRI) should be performed before a biopsy or surgical correction of the abnormality is attempted.⁹



Copyright Andrew F. Inglis, Jr.

Figure 44-2. Choanal atresia after repair. View from the posterior of the nasopharynx demonstrating patency of choanae following surgery. (Copyright Andrew F. Inglis Jr.)

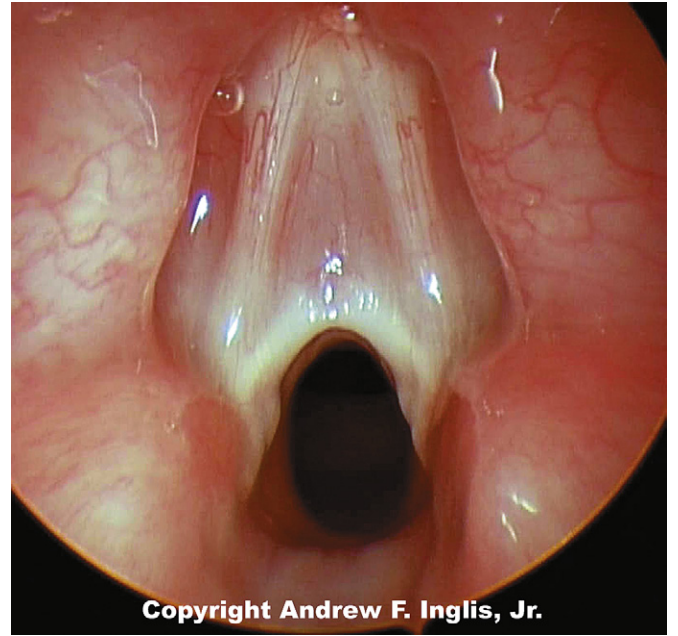
Laryngomalacia

Laryngomalacia is the most common congenital anomaly of the larynx. The infant has inspiratory stridor that is exacerbated by crying or distress. Although no gross anatomic abnormalities are present, the laryngeal cartilages lack their usual rigidity. When the larynx is observed during fiberoptic examination of the glottis, the arytenoid cartilages and supra-glottic structures collapse inward (toward the glottis) during inspiration, leading to inspiratory stridor. The negative intrathoracic pressure generated during inspiration contributes to a high incidence of gastroesophageal reflux¹⁰ and pulmonary aspiration.^{11,12}

These abnormalities can be graphically observed with fiberoptic laryngoscopy, which shows the dynamic component, with obstruction during inspiration and full airflow during expiration. In some patients with laryngomalacia, gastroesophageal reflux may be the primary cause of the airway compromise, whereas in others it may be a significant cofactor exacerbating preexisting neurologic or anatomic abnormality.¹³ The respiratory embarrassment associated with this problem is usually minor and self-limited, although hypoxia and hypercapnia have been documented.¹⁴ Infants tend to outgrow this problem during the first year of life; however, the condition may be severe enough in some infants that activities such as feeding are compromised. In the most severe cases, surgical intervention may be necessary.¹⁵ The goal is to relieve airway obstruction by excision of tissue that collapses into the glottis during inspiration.

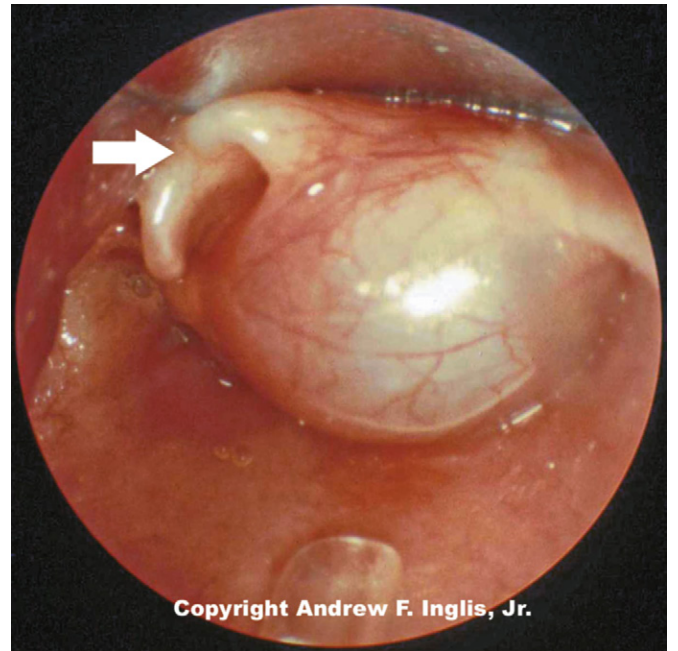
Laryngeal Webs, Stenosis, and Tumors

Laryngeal webs usually occur at the level of the glottis and are usually located anteriorly. These may be congenital or acquired and are generally thin membranes of soft tissue that



Copyright Andrew F. Inglis, Jr.

Figure 44-3. A laryngeal web occludes most of the tracheal lumen in this patient. This web, which is a thin membrane of soft tissue at the level of the glottis, has many of the features typical of this class of lesions. (Copyright Andrew F. Inglis Jr.)



Copyright Andrew F. Inglis, Jr.

Figure 44-4. A large laryngeal cyst protrudes from the lateral wall of the trachea, just below the level of the glottis. (Copyright Andrew F. Inglis Jr.)

partially occlude the tracheal opening, producing symptoms of feeble cry and dyspnea shortly after birth (Figure 44-3).¹⁶ Surgical lysis of these lesions corrects the problem. Laryngeal cysts and laryngoceles are soft tissue masses that protrude into the glottic lumen (Figure 44-4). The resulting respiratory compromise is usually recognized as inspiratory stridor. Treatment is surgical excision of the lesion.¹⁷

Another lesion presenting as inspiratory stridor is congenital laryngotracheal (subglottic) stenosis. This is the second most frequent cause of stridor in infants.¹⁸ The infant with this

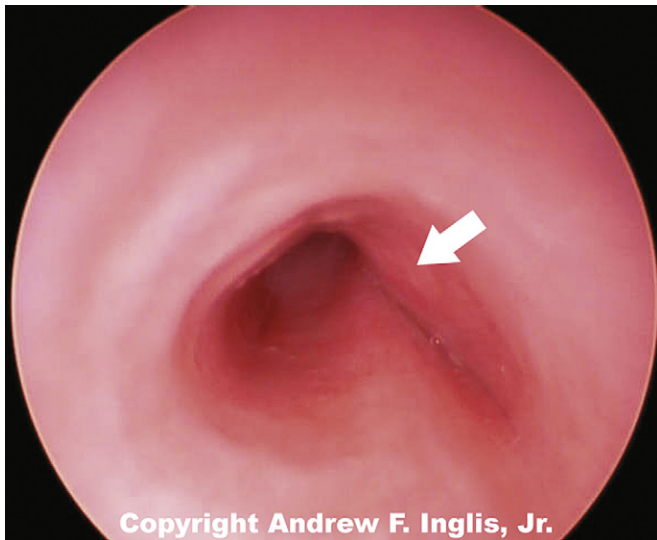


Figure 44-5. The lateral portion of the tracheal lumen is severely compressed by the impingement of the vascular ring. (Copyright Andrew F. Inglis, Jr.)

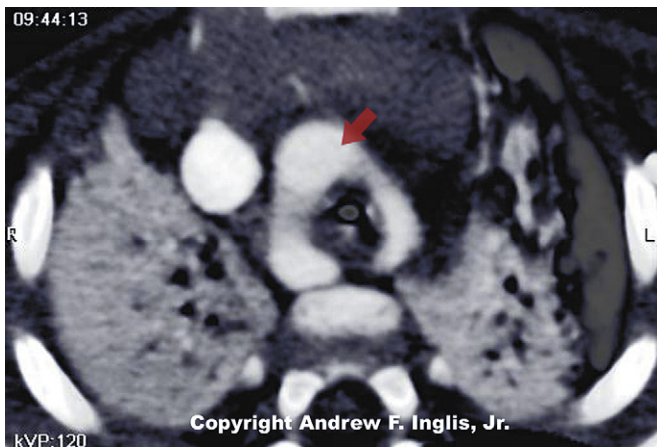


Figure 44-6. Contrast CT scan showing vascular ring encircling and compressing the trachea (arrow indicates vascular ring encircling trachea). (Copyright Andrew F. Inglis Jr.)

problem may have symptoms when newborn but often comes to medical attention later when the tracheal edema produced by a minor respiratory infection causes severe inspiratory stridor. This may be initially diagnosed as croup (laryngotracheobronchitis) but is noted to recur with each subsequent upper respiratory infection. Although the diagnosis of laryngotracheal stenosis may be made radiographically, it is usually established with bronchoscopy. If endotracheal intubation is necessary, a smaller than normal endotracheal tube should be used to reduce trauma and ischemia of the subglottic tissues. Depending on the severity of the lesion, surgical intervention may be necessary (see the discussion about acquired laryngotracheal [subglottic] stenosis for details of the surgical procedures).

Soft tissue masses may reduce the caliber of the tracheal lumen, either by extrinsic compression, as happens with a cystic hygroma, or by growth into the tracheal lumen from the tracheal wall, as happens with a hemangioma. Although these lesions may be present at birth, they often do not produce symptoms for the first few months until the growing

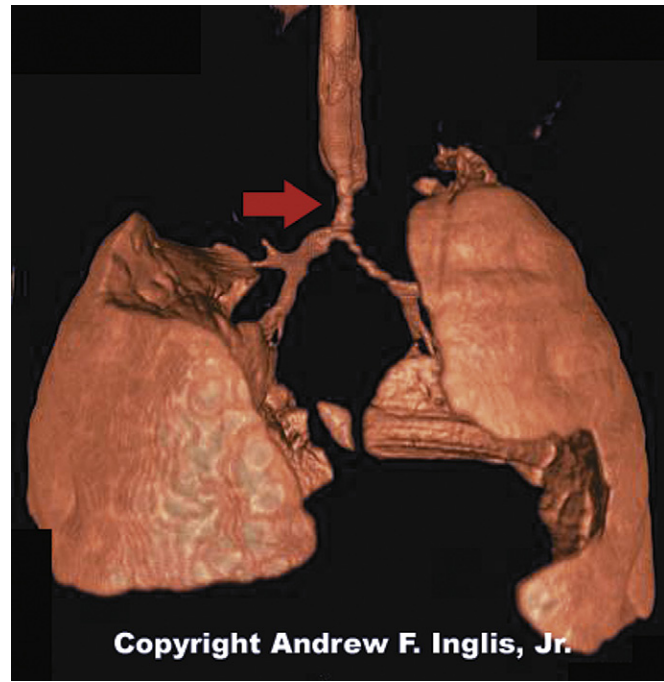

Figure 44-7. High-resolution three-dimensional reconstruction of CT scans clearly shows severe tracheal compression caused by vascular ring (arrow indicates tracheal narrowing caused by vascular ring). (Copyright Andrew F. Inglis Jr.)

lesion further impinges on the trachea. Although surgery is frequently used for treatment of tracheal hemangiomas,¹⁹ pioneering work by Judah Folkman was instrumental in demonstrating that some of these lesions respond to steroid therapy.²⁰

Vascular Impingement on the Trachea

The trachea may be compressed by the presence of an abnormal vascular structure (Figure 44-5). The innominate artery is the most common vessel causing tracheal compression. Vascular rings and enlarged pulmonary arteries are also known to cause tracheal compression, as are a variety of other vascular abnormalities.²¹ These lesions may present with physical findings such as stridor or wheezing. Alternatively, the patient may be symptom-free, but may suffer respiratory problems such as recurrent lobar atelectasis or frequent pulmonary infections. Because of this, it is difficult to recognize a vascular ring as the underlying cause of illness.²² Careful inspection of the chest radiograph may reveal indentation of the trachea, but often this sign is absent. Barium swallow has been the historic method of diagnosing vascular impingement of the trachea. CT scanning and MRI have become the diagnostic modalities of choice (Figures 44-6 and 44-7).^{23,24} These noninvasive methods are effective at showing complex three-dimensional cardiovascular anatomy, especially the extracardiac morphology. Treatment involves surgical correction of the vascular anomaly, in severe cases. Respiratory distress may persist postoperatively because prolonged compression of the trachea has made the affected segment softer and collapsible. In severe cases, the tracheomalacia may severely compromise the patient and may be improved by surgical intervention to prevent tracheal collapse.²⁵

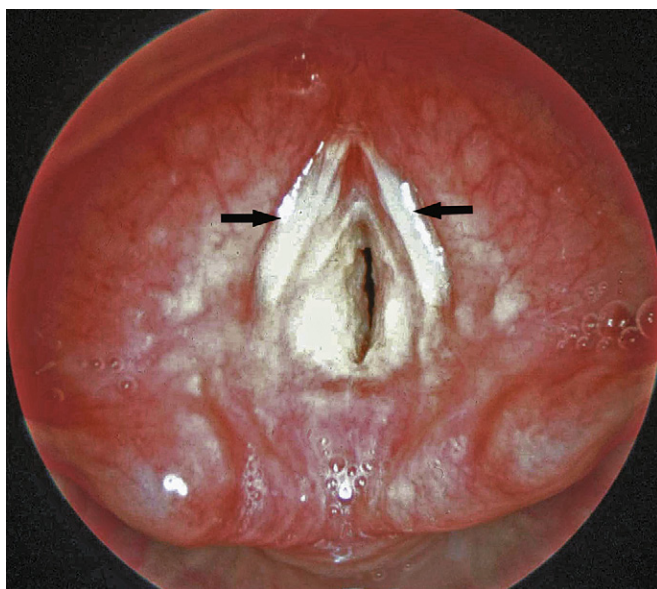


Figure 44-8. Laryngotracheobronchitis: below the level of the vocal cords the trachea appears swollen and the tracheal walls are covered with purulent material (vocal cords are indicated by arrows).

Bronchomalacia and Intrathoracic Tracheomalacia

During normal respiration, the upper airway is subject to cycles of positive and negative intraluminal pressure. The cartilaginous components of the upper airway are rigid ringlike structural elements that resist the tendency to collapse caused by the cycling of pressure within the airway lumen. When these structures lack their characteristic rigidity, the mechanics of breathing are altered.²⁶ The symptoms produced by these changes depend on the location of the damaged cartilages. Characteristically, intrathoracic cartilaginous lesions such as bronchomalacia or tracheomalacia impede exhalation. Diagnosis of this problem may be made through observation of collapse of the upper airways during active exhalation, such as occurs while crying. Collapse can be observed with several diagnostic modalities including fluoroscopy, flexible or rigid bronchoscopy, and ultrafast CT scanning.²⁷

Although these lesions may be congenital, many of the cases of tracheomalacia and bronchomalacia seen in the pediatric intensive care unit (PICU) are the result of an infectious or mechanical insult to the trachea. Infants with bronchopulmonary dysplasia and persistent respiratory problems may be affected by bronchomalacia alone or in combination with tracheomalacia.²⁸ The obstructive symptoms produced by these lesions may be relieved by continuous positive airway pressure to maintain patency of the airway during exhalation.²⁹ The level of continuous positive airway pressure necessary to improve respiratory function may be assessed clinically (relief of obstructive symptoms), mechanically (measurement of flow-volume loops), or bronchoscopically (maintenance of airway patency throughout the respiratory cycle).³⁰ With sufficient time, many of these infants outgrow their respiratory difficulties. As an alternative to tracheostomy and positive airway pressure, some have advocated surgical intervention with pericardial flap aortopexy³¹ or, in extreme situations, metallic airway stents.³²

Infectious Processes

A variety of infectious processes may affect the pediatric airway. Poiseuille's law dictates that airway compromise from the swelling that accompanies an infectious process is greater in infants and young children than it is in adults. A small reduction in the caliber of the smaller child's airway may lead to a life-threatening reduction of airflow.

Laryngotracheobronchitis

Laryngotracheobronchitis (croup) is a common childhood infection. It is caused by a variety of infectious agents; parainfluenza virus, coronavirus, and rhinovirus are the most common.³³ This is a seasonal illness, occurring predominately during winter months, and most commonly affecting children from age 6 months to 3 years. There is frequently a history of prodromal infection accompanied by an unusual cough (described as sounding like the bark of a seal). Swelling of the tracheal mucosa in the subglottic region causes airway compromise (Figure 44-8). Medical attention is usually sought when the child develops inspiratory stridor and respiratory distress. Various scales have been devised to quantify the severity of the stridor to document the progression of the illness and the response to therapy. One of the most commonly employed scales is the Westley scale,³⁴ which has been validated (see Table 44-1).³⁵

When a chest radiograph is obtained during an episode of laryngotracheobronchitis, the trachea is seen to have a gradual progressive narrowing of its lumen, reaching the narrowest point just below the vocal cords (the "steep sign") (Figure 44-9). The upper glottis, as seen on a lateral neck radiograph, is normal.

Many care providers believe that exposing the child to cold or misty air often dramatically improves the symptoms; although evidence in support of this therapy is lacking.^{36,37} When the illness is refractory to these measures, racemic epinephrine has been shown to produce dramatic reduction of airway obstruction. This probably is accomplished by stimulation of the α -adrenergic receptors, producing vasoconstriction and resulting in diminished tracheal edema. Rebound tracheal edema may occur several hours later as the effect of the racemic epinephrine dissipates. Because this problem is unpredictable, the child should be admitted to the hospital for observation after racemic epinephrine has been used.

The practice of treating laryngotracheobronchitis with corticosteroids is widespread, especially for hospitalized patients.³⁸ Oral, intramuscular, and nebulized corticosteroids have been shown to be beneficial in randomized, blinded trials.^{39,40} Meta-analyses in which the efficacy of corticosteroids was evaluated suggest that corticosteroids reduced the need for endotracheal intubation or inhaled epinephrine, hasten improvement in the first 24 hours of illness, shorten the duration of hospitalization, and reduce the frequency of readmission.⁴¹⁻⁴⁴

Mixtures of 70% helium and 30% oxygen (heliox) may be beneficial because the characteristics of this mixture permit greater gas flow past areas of airway narrowing. Some authors suggest that this therapy is as efficacious as racemic epinephrine⁴⁵; however, this therapy has not been conclusively demonstrated to be superior to the administration of supplemental oxygen by itself.⁴⁶

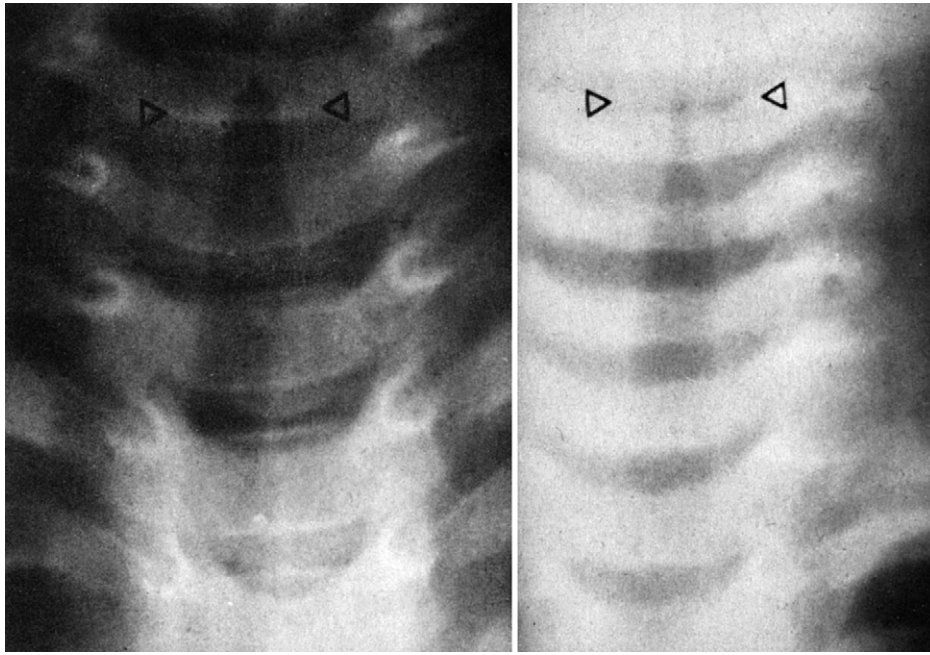


Figure 44-9. Anteroposterior radiograph of the neck. *Left*, A normal tracheal air column (between the arrows). *Right*, Trachea narrowed by laryngotracheobronchitis.

Table 44-2 Characteristics of Laryngotracheobronchitis, Bacterial Tracheitis, and Epiglottitis

	Laryngotracheobronchitis	Bacterial Tracheitis	Epiglottitis
Age	3 mo to 3 yr	6 mo to 12 yr	12 yr (average)
Onset	Gradual	Intermediate	<24 hr
Fever	Usually low	Usually high	High
Cough	Characteristic “barking”	Characteristic “barking”	None
Sore throat	None	Usually absent	Often severe
Drooling	No	No	Usually
Posture	Any position	Any position	Sitting forward, mouth open, drooling
Voice	Normal	Normal or hoarse	Muffled
Appearance	Nontoxic	Toxic	Toxic
Seasonal distribution	Usually winter, epidemic	Throughout the year	Throughout the year

Endotracheal intubation is occasionally necessary when laryngotracheobronchitis proves refractory to medical intervention. Unless merited by special circumstances, such as severe subglottic stenosis in association with laryngotracheobronchitis, tracheostomy offers no advantages over endotracheal intubation. The endotracheal tube should be of a smaller size than would normally be used, to avoid additional injury to the swollen tracheal mucosa. If the tracheal edema is severe, even a small tube may fit tightly in the trachea.

Later, when an audible leak around the endotracheal tube is present, the trachea may be extubated with a high probability that reintubation will not be necessary.⁴⁷ If a leak does not become audible after 2 to 4 days, it is our practice to extubate the trachea, because prolonged intubation may increase the risk for subglottic injury. Racemic epinephrine is commonly needed to treat stridor after extubation. If a patient should have especially severe or recurrent laryngotracheobronchitis, an anatomic lesion causing tracheal narrowing should be suspected.

Epiglottitis

Epiglottitis caused by *Haemophilus influenzae* type B was once a common cause of serious respiratory illness in pediatric patients, but the widespread use of *H. influenzae* type B vaccine has reduced the frequency of this problem by more than 90% in young children.⁴⁸ Patients who present with epiglottitis are now older, with an average age of 11.6 years, as opposed to an average age of 5.8 years before the advent of Hib vaccination.⁴⁹ Although cases of *H. influenzae* epiglottitis continue to occur, even among vaccinated patients,⁵⁰ other causes of epiglottitis have assumed greater importance in the postvaccination era. Group A β -hemolytic *Streptococcus* is now identified as the cause of epiglottitis in many patients and is clinically indistinguishable from epiglottitis caused by *H. influenzae* type B.⁵¹ Thermal injury to the epiglottis from ingesting hot liquids can also cause epiglottitis.⁵² Several points serve to distinguish epiglottitis from laryngotracheobronchitis (Table 44-2).

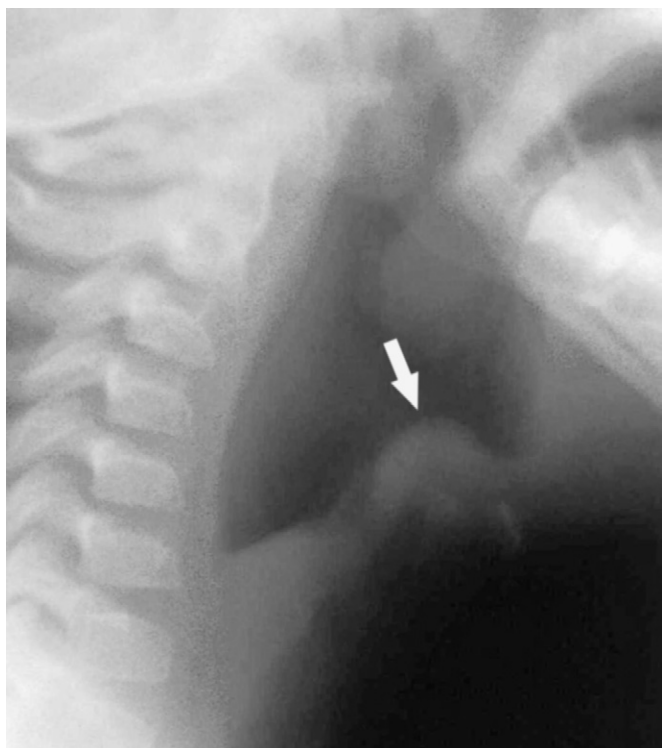

Figure 44-10. Lateral radiograph of the neck of a patient with epiglottitis. Note the large, swollen epiglottis.

Management of epiglottitis in young children is a multidisciplinary undertaking, involving pediatric intensive care specialists, anesthesiologists, and otolaryngologists. When a child with presumed epiglottitis is admitted to the emergency department, this team should be notified in anticipation of taking the child to the operating room to secure his or her airway. As the team members are being notified, lateral radiographs of the neck may be obtained if tolerated by the patient. This may be done with the child sitting on the parent's lap to minimize the child's anxiety. In epiglottitis, the anteroposterior view of the trachea appears normal, but a lateral neck radiograph shows a markedly swollen and edematous epiglottis (Figure 44-10). The diagnostic evaluation of the patient should proceed expeditiously, while care is taken to disturb the patient as little as possible. For this reason, fiberoptic examination of the epiglottis in the awake patient is usually not advisable. Attempts to examine the oropharynx directly or to start an intravenous line should be discouraged. The apprehension caused by these events may lead to tracheal obstruction by the enlarged epiglottis. If the patient will tolerate it, humidified oxygen should be administered, preferably through a plastic hose held by the parent.

If the diagnosis of epiglottitis is strongly suspected or confirmed on the lateral neck x-ray film, the child should go to the operating room as quickly as possible. In the operating room, the patient is anesthetized with an inhaled anesthetic (sevoflurane) and oxygen while the patient is spontaneously breathing. Once the patient has been anesthetized, an intravenous catheter is inserted. Laryngoscopy is then performed (Figure 44-11). It may be exceedingly difficult to obtain a direct view of the glottis and trachea because of the large swollen epiglottis. Nevertheless, it is almost always possible to pass an endotracheal tube through the edematous tissues and into

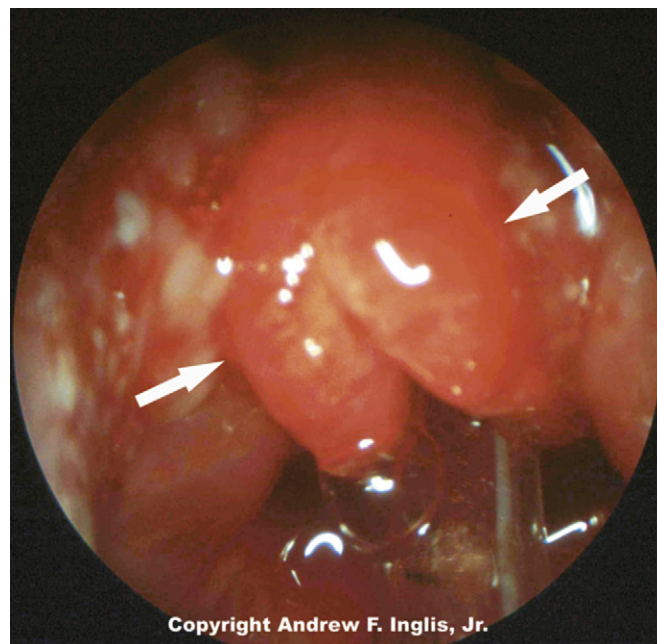


Figure 44-11. Epiglottitis causing a severely swollen epiglottis (between the arrows). In the lower portion of the picture, the endotracheal tube can be seen. (Copyright Andrew F. Inglis Jr.)

the trachea. Nasotracheal intubation is preferred to orotracheal intubation because the tube is more readily secured to the face, the patient cannot bite the tube, and salivation is decreased. An otolaryngologist should be in the operating room and ready to do an emergency tracheostomy if an airway cannot be secured by endotracheal intubation, although this is rarely necessary. As with laryngotracheobronchitis, endotracheal intubation is preferred to tracheostomy because it has been shown that complications are more common when a tracheostomy has been routinely used to treat epiglottitis. After the airway is secured, blood cultures and cultures of the epiglottis are obtained, and antibiotic therapy is initiated with a penicillinase-resistant antibiotic because of the high incidence of *H. influenzae* resistance to ampicillin.⁵³

In the PICU, patients usually require endotracheal intubation for 24 to 72 hours while the swollen epiglottis returns to normal size. The patient may be allowed to breathe spontaneously through the endotracheal tube or may undergo mechanical ventilation. Variable amounts of sedation are usually necessary. Extraepiglottic sites of *H. influenzae* infection are common. In one series, pneumonia occurred in 25% of patients with epiglottitis.⁵⁴

The management of epiglottitis depends upon the patient's age. Adults and teenagers with epiglottitis usually present with severe pharyngitis, but usually have mild or absent airway obstruction. In contrast to younger unsedated children, teenagers and adults may tolerate examination of the airway with a small fiberoptic bronchoscope. This procedure may have superior diagnostic sensitivity compared to lateral neck radiographs. Although the management of epiglottitis in young children is almost always accomplished with placement of an endotracheal tube, teenagers and adult patients may be admitted to the hospital for close observation and expectant airway management. Endotracheal intubation is reserved for those patients who develop respiratory compromise.^{55,56}

Peritonsillar Abscess

The initial presentation of peritonsillar abscess may resemble that of epiglottitis. The child usually has a severe sore throat and may also have a muffled voice and drooling. If the abscess is of sufficient size, the child may also experience respiratory distress. Unlike epiglottitis, children with peritonsillar abscess often experience trismus and usually do not have respiratory embarrassment. If the abscess is fluctuant, surgical incision and drainage may be indicated. Although trismus may be of concern in evaluation of the patient for anesthesia, there is usually no anatomic restriction of jaw movement. Once the patient has been anesthetized, the mouth may be easily opened. Extubation is almost always possible after the abscess has been drained, unless there is severe inflammation and swelling extending well beyond the tonsillar bed. Intraoral ultrasound examination has been suggested to be a useful test to differentiate abscess from cellulitis.⁵⁷ The most commonly encountered microorganism is Group A *Streptococcus*.⁵⁸

Retropharyngeal Abscess

Almost 90% of children with retropharyngeal abscess are younger than 6 years.⁵⁹ Patients may have fever, stiff neck, sore throat and, in severe cases, respiratory distress. During examination of the oropharynx, the posterior pharyngeal wall may be observed to bulge, but most commonly, the findings are unremarkable. Palpation of the posterior pharyngeal wall should be avoided because it may cause rupture of the abscess with possible spillage of the contents into the tracheobronchial tree. An inspiratory radiograph of the lateral neck may show thickening of the prevertebral soft tissue, and occasionally an air-fluid level may be present (Figure 44-12). A chest radiograph should be obtained to evaluate possible mediastinal extension of the infection. CT scanning is commonly employed to evaluate these infections; however, evidence of abscess on CT scan does not reliably predict the quantity of purulent material obtained at the time of surgical drainage.⁶⁰

A trial of antibiotic therapy is often indicated before any decision is made to proceed with surgical drainage of the abscess,⁶¹ as between 30% and 90% of patients treated with antibiotic therapy can be cured without surgical intervention.^{62,63} Surgical treatment of this lesion is drainage of the abscess, after the patient has been anesthetized and an endotracheal tube has been inserted to protect the patient from pulmonary aspiration of the purulent fluid. The organisms most often isolated are group A β -hemolytic *Streptococci* and *Staphylococcus aureus*.^{59,64}

Bacterial Tracheitis

The peak incidence of this infection occurs in the fall and winter and tends to affect children between 6 months and 8 years of age. Bacterial tracheitis is a secondary infection that begins during a viral upper respiratory infection.⁶⁵⁻⁶⁷ Frequently, but not always, bacterial tracheitis will resemble viral laryngotracheobronchitis (croup). Children will frequently complain of a severe sore throat or pain during coughing. In contrast to viral laryngotracheobronchitis, patients with bacterial tracheitis usually have a high fever and may appear very ill at the time of presentation (see Table 44-2). Because of the clinical similarity between bacterial tracheitis and viral

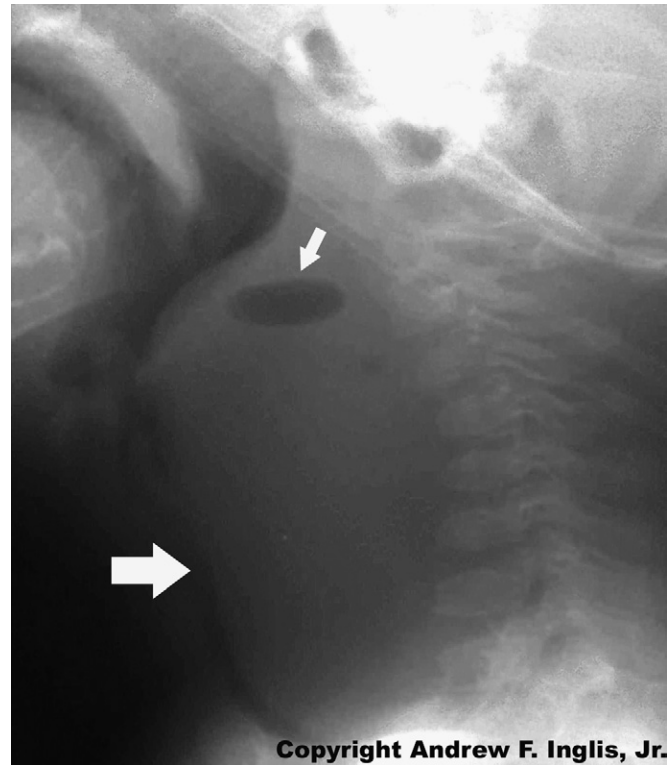


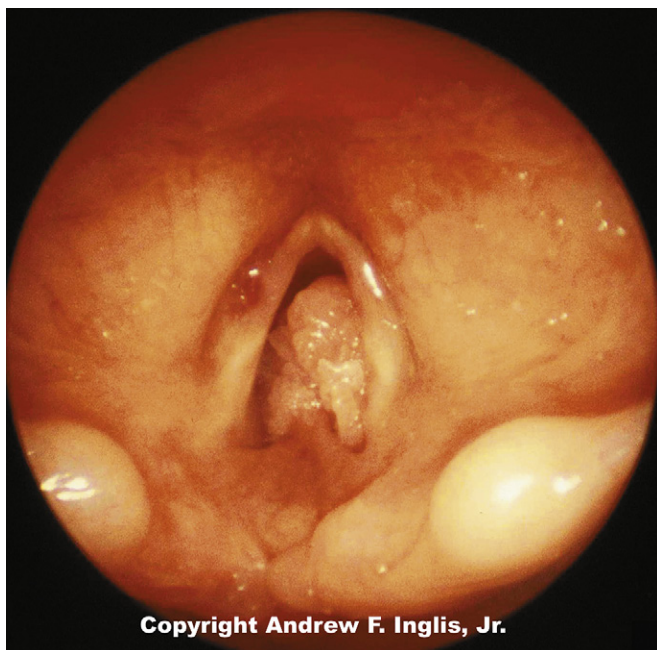
Figure 44-12. Lateral radiograph of the neck of a patient with retropharyngeal abscess. Note the thickening of the prevertebral soft tissue and the radiolucent area caused by the presence of air in the tissue. (Copyright Andrew F. Inglis Jr.)

laryngotracheobronchitis, these patients are treated with racemic epinephrine but fail to respond. If bronchoscopy is performed, it shows normal supraglottic structures, and diffuse inflammation of the larynx, trachea and bronchi,⁶⁸ with adherent or semiadherent purulent membranes in the trachea.⁶⁹ Endotracheal intubation is often necessary because of severe, progressive respiratory distress. Following endotracheal intubation, aggressive tracheobronchial toilet may be necessary because thick, tenacious purulent debris may rapidly occlude the endotracheal tube.

A variety of bacterial agents have been reported in association with this illness, including *Moraxella catarrhalis*, *Staphylococcus aureus*, *Haemophilus influenzae* type B, and *Pneumococcus*.^{70,71} The injury to the respiratory epithelium caused by the virus may predispose the patients to bacterial superinfection. The most common complication of bacterial tracheitis is pneumonia, which is observed in approximately 60% of patients with this illness. Antibiotics are an important aspect of therapy and should be directed by the results of bacterial cultures obtained during bronchoscopy or immediately after endotracheal intubation.

Laryngeal Papillomatosis

The laryngeal papilloma is the most common benign tumor of the larynx during childhood. The agent causing this disease is human papilloma virus, with types 6 and 11 causing the vast majority of cases.⁷² Despite its nonmalignant structure, the propensity of this tumor to cause respiratory obstruction may result in injury to the patient or death. The onset of symptoms occurs between infancy and 4 years of age. New onset of



Copyright Andrew F. Inglis, Jr.

Figure 44-13. Large, pedunculated papilloma is seen just below the vocal cords. These papillomae almost completely occluded the tracheal lumen and produced marked respiratory distress. (Copyright Andrew F. Inglis Jr.)

infection is less frequent after age 5 years. The most common medical complaint in these children is voice change, which occurs in more than 90% of the patients. Airway obstruction is present in almost half of the patients, although it is mild in many of these. The presence of inspiratory stridor may misdirect the diagnostician to think that the child has laryngotracheobronchitis. The diagnosis is typically made with laryngoscopy (Figure 44-13).

Little is known about the immunological mechanisms involved in laryngeal papillomavirus infection, but cellular immunity is considered a more important mechanism than humoral immunity.⁷³ Better understanding of human papillomavirus infection is hampered by the lack of a good experimental model in which the entire viral life cycle can take place.

The treatment for this illness is surgical excision of the polyps. Induction of anesthesia in the child with severe airway obstruction may be hazardous, because it may be difficult or impossible to ventilate the child's lungs after loss of consciousness. Although patients characteristically require multiple surgical resections of these lesions (an average of 11 resections over the course of the disease), the mortality with this illness is low. Carbon dioxide laser vaporization of the papillomata is widely used. During laser excision of lesions caused by a similar viral agent, anogenital condylomas, medical personnel have become infected with the virus, presumably from viable virus particles carried in the smoke plume.⁷⁴ Although this has caused concerns about the spread of infection after excision of laryngeal papillomatosis, test results of the smoke plume have been negative for viral DNA.⁷⁵ Despite this, careful scavenging of the plume is routine in most centers where this operation is performed.

Despite modern surgical treatments, recurrence of laryngeal papillomata is relatively common and has prompted the search for other treatment options. Adjunctive treatment with interferon- α has been shown to reduce the relapse rate in

both children and adults.⁷⁶ Molecular analysis has shown that patients infected with human papillomavirus-11 were sensitive to interferon treatment as opposed to those with human papillomavirus-6.⁷⁷

Vocal Cord Paralysis

The bulk of the motor innervation to the larynx is supplied by the recurrent laryngeal nerves. These nerves originate in the nucleus ambiguus in the brainstem, travel to the chest with the vagus nerve, and then loop back up to the larynx in the tracheoesophageal groove. The left recurrent laryngeal nerve loops under the ductus arteriosus in the chest, and thus is vulnerable to injury during ligation of this vessel, and with other thoracic vascular procedures.⁷⁸

Symptoms associated with even complete unilateral vocal cord paralysis vary greatly in severity. In infants, they may range from merely a mildly diminished cry up to a severely disabled larynx with significant stridor, feeding difficulties from aspiration, and loss of voice.⁷⁹ Bilateral vocal cord paralysis almost always produces significant stridor with varying degrees of airway distress. Stridor in these instances is typically inspiratory, and may be confused with laryngomalacia, a much more common entity. Diagnosis can usually be made at the bedside by fiberoptic laryngoscopy.⁸⁰

Congenital vocal cord paralysis is usually idiopathic, and often resolves spontaneously over several months. This is the most common cause of bilateral vocal cord paralysis in children.⁸¹ Other neurological causes, such as Arnold-Chiari malformation, are occasionally seen, and workup usually includes an MRI. The cause of acquired vocal cord paralysis is usually obvious, with most cases coming after thoracic or cervical surgery.⁸²

The treatment of vocal cord paralysis in the critical care setting is primarily supportive. Airway support may include temporizing with high-flow nasal oxygen or continuous positive airway pressure/biphasic positive airway pressure (CPAP/BiPAP). Longer-term interventions include tracheotomy, or various procedures aimed at enlarging the glottic airway, including vocal cordotomy, arytenoidectomy, vocal cord lateralization, and posterior cricoid split and cartilage grafting.⁸⁰ If a specific lesion may be addressed medically or surgically (such as decompression of the brainstem in Arnold-Chiari malformation), such therapy should be undertaken.

Intrathoracic Mass Lesions Causing Respiratory Obstruction

The intrathoracic trachea may be compressed by a variety of anterior mediastinal masses. Because the symptoms produced by a malignant mass impinging on the trachea can worsen dramatically over several days, the child with respiratory compromise resulting from a mediastinal mass deserves rapid evaluation and aggressive medical therapy.

Before caring for a child with this problem, the parents should be asked if the child refuses to lie in certain positions. The child's reluctance to recline in a given position may be caused by airway compromise from the mass. Forcing the child to lie down may result in airway obstruction or even cardiac arrest.⁸³ Endotracheal intubation is indicated only if respiratory function becomes severely compromised. Unfortunately,

this measure may be of little benefit, because the lesion may compress the bronchi distal to the tip of the endotracheal tube requiring advancing the endotracheal tube into the mainstem bronchi.⁸⁴ In addition, it may be impossible to ventilate the child's lungs after muscle relaxants have been administered to facilitate placement of the endotracheal tube. Mechanical support with ECMO has been used to support patients with large mediastinal masses; however, the mass may distort the great vessels and pose unusual challenges for the ECMO team.⁸⁵ Obtaining tissue for a pathologic diagnosis can be a challenge, as these patients are at significant risk for anesthetic complications.⁸⁶ Factors associated with airway compromise are (1) anterior location of the mediastinal mass, (2) histological diagnosis of lymphoma, (3) symptoms and signs of superior vena cava syndrome, (4) radiological evidence of vessel compression or displacement, (5) pericardial effusion, and (6) pleural effusion.⁸⁷

Trauma

Postextubation Stridor

After endotracheal intubation that lasts more than a few hours, postextubation stridor is a relatively common problem in small children and is most frequently caused by laryngeal edema. Estimates of the frequency of postextubation stridor in children vary widely. Most authors cite figures of less than 2% to 9%,^{88,89} although the incidence may be as high as 37% in patients with trauma or burns.⁹⁰

In addition to audible stridor, patients with this problem show decreased air movement; flaring of the alae nasi; and in more severe cases, decreased arterial oxygen saturation and mental status changes. The severity of these signs reliably indicates the severity of airway obstruction.⁹¹

Several risks are associated with the development of postextubation stridor. Endotracheal tube size plays an important role, because too large an endotracheal tube may compress the tracheal mucosa, causing submucosal ischemia. When the endotracheal tube is removed, the injured tissue may swell and partially obstruct the larynx. Endotracheal tube movement within the trachea may produce trauma to the tracheal mucosa, resulting in tissue injury and swelling. Whether stridor occurs depends on the extent of the swelling and the diameter of the child's airway. Small patients are more likely to have postextubation stridor because a larger proportion of their airway is obstructed with a given degree of swelling and because of the unfavorable characteristics of turbulent flow through small passages. Lack of an audible leak of air around the endotracheal tube is frequently used as a predictor of postextubation stridor in children; however, one study suggests that this measure may be valid only in children ages 7 years and older.⁹²

Uncuffed endotracheal tubes are often recommended for children younger than 8 years because of concern that the presence of an endotracheal tube cuff may contribute to the risk of postextubation stridor. The subglottic region is the narrowest portion of the airway in this age group and will often provide an adequate seal around the endotracheal tube. Although historically, cuffed endotracheal tubes were not frequently used in children younger than 8 years, there are increasing data suggesting the safety of such endotracheal tubes. Data regarding the harmful effects of cuffed endotracheal tubes were derived from tubes with high-pressure,

low-volume cuffs, which are likely to cause submucosal tracheal ischemia. These endotracheal tubes have been replaced by low-pressure, high-volume cuffs that seal the trachea by providing a larger area of contact with the mucosa at a lower pressure, resulting in less submucosal ischemia. When such endotracheal tubes are used, the risk of postextubation stridor appears no greater than when uncuffed endotracheal tubes are used.^{88,89,93} Because cuffed endotracheal tubes may provide a better seal than uncuffed endotracheal tubes, they can be useful in delivering higher pressures needed in patients with non-compliant lungs who require mechanical ventilation. A large multicenter randomized control trial also suggests there is a significant reduction in endotracheal tube exchanges when cuffed tubes are used.⁸⁸

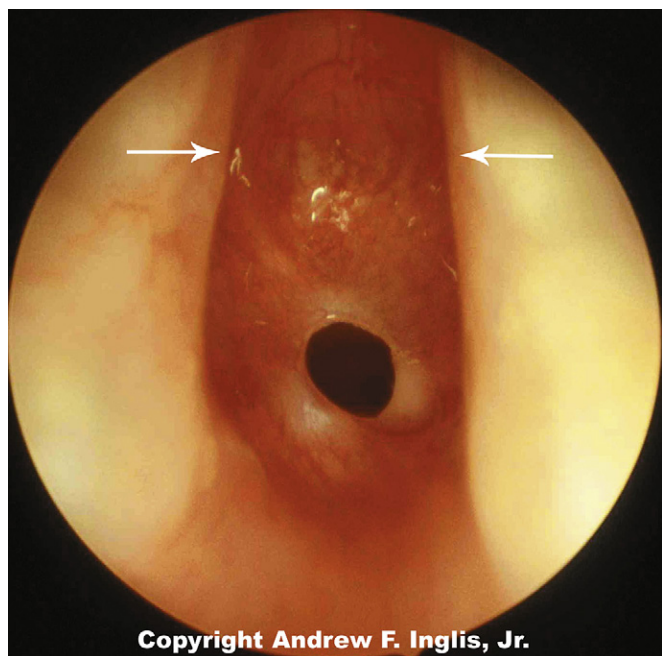
Postextubation stridor has a greater risk of developing in children with trisomy 21; as many as one third of these patients have stridor after extubation. There appear to be several causes for this problem, including hypotonia and facial abnormalities, such as a large tongue.

Although most cases of postextubation stridor are caused by laryngeal edema, when this problem persists, other causes should be sought. Anatomical airway anomalies, which may not be visible during endotracheal intubation (such as tracheal hemangioma), may cause persistent postextubation stridor. Vocal cord paralysis is one of the more common causes of persistent postextubation stridor and may be caused by increased intracranial pressure, brainstem compression,⁹⁴ trauma to the brainstem after neurosurgery, or recurrent laryngeal nerve during thoracic surgery.⁹⁵

The therapy of postextubation stridor is aimed at reducing airway edema. Racemic epinephrine and dexamethasone are the most widely used therapeutic agents. Racemic epinephrine, delivered by aerosol nebulizer, probably works by stimulation of α -adrenergic receptors; this stimulation causes vasoconstriction, which, in turn, reduces tracheal edema. Racemic epinephrine works rapidly, so improvement, when it occurs, should be observed within a few minutes of completion of therapy. Mixtures of helium and oxygen have also proven helpful in the treatment of postextubation stridor.⁹⁶

The practice of using dexamethasone to treat postextubation stridor is widespread,⁹⁷ although the efficacy of this therapy remains controversial. Although data from animal studies suggest that corticosteroid use at the time of extubation may reduce tracheal edema, inflammation, and capillary dilation, a recent meta-analysis of prior studies has failed to show reduction of postextubation stridor after corticosteroid use.⁹⁸ Nevertheless, many practitioners think that dexamethasone (or an equivalent dose of another steroid) will ameliorate postextubation stridor, especially if the medication is administered several hours before extubation.

In most cases, postextubation stridor is self-limited, but occasionally, endotracheal intubation may be necessary. If the degree of airway obstruction before reintubation was severe, postobstructive pulmonary edema may be observed and should be treated with positive end-expiratory pressure. When reintubation is contemplated, the size of the previous endotracheal tube should be determined, and a smaller endotracheal tube should be selected in the hope of preventing additional tracheal injury. Ideally, the trachea should remain intubated until a leak around the endotracheal tube is observed, indicating resolution of the laryngeal edema.



Copyright Andrew F. Inglis, Jr.

Figure 44-14. A cicatricial ring is demonstrated just below the glottis. This was caused by trauma from prolonged endotracheal intubation. (Copyright Andrew F. Inglis Jr.)

Laryngotracheal (Subglottic) Stenosis

Laryngotracheal stenosis is most commonly seen as a complication of prolonged endotracheal intubation, and as such is of special interest to the critical care practitioner (Figure 44-14). Injury most commonly occurs in the larynx at the level of the cricoid cartilage, just below the vocal cords, the only part of the airway below the nose that is surrounded by a complete circumferential ring of cartilage. This region cannot expand under pressure and is thus more susceptible to pressure necrosis and scarring (subglottic stenosis). Airway stenosis also can occur at the level of the vocal cords (glottic stenosis) when scarring occurs within the cricoarytenoid joints (cricoarytenoid ankylosis) or between the arytenoid cartilages (interarytenoid fibrosis). Glottic stenosis prevents vocal cord abduction and occasionally may be confused with bilateral vocal cord paralysis. Rarely, tracheal stenosis may be seen as a result of endotracheal tube (ETT) cuff injury, often in the setting of infection requiring high pressure ventilation.

Laryngeal intubation injury appears to result from an interaction of several elements, including individual susceptibility, movement of the endotracheal tube, size of the ETT, presence of infection, and duration of intubation. Fortunately, the incidence of this complication in neonates appears to be decreasing.⁹⁹ The odds of prevention will be enhanced by choosing the smallest tube that allows adequate ventilation and pulmonary care; this reduces the risk of subglottic stenosis. It is also thought that nasotracheal intubation may reduce movement of the ETT within the airway and thus diminish trauma, although this benefit comes with an increased risk of sinusitis secondary to obstruction of drainage from the sinus cavities. Gastroesophageal reflux is frequently present, and perhaps plays a significant role in the development of laryngotracheal stenosis.⁹⁹ The role of early intervention with a tracheotomy for the prevention of laryngeal stenosis is controversial.¹⁰⁰

Clinically, laryngeal stenosis presents initially as postextubation stridor. It may be successfully managed with steroids or racemic epinephrine. Some patients may benefit from non-invasive positive-pressure breathing therapies such as BiPAP or CPAP. If reintubation is necessary, the larynx may heal successfully if a smaller endotracheal tube is used. Multiple failed attempts at extubation may require treatment with either an anterior cricoid split and cartilage graft, or tracheotomy.

Chronic laryngeal stenosis can be managed a variety of ways.¹⁰¹ The obstruction may be bypassed with a tracheotomy, or may be managed with endoscopic excision of scar, cricoid expansion via cricoid split and cartilage grafts, and excision of the stenotic segment and reanastomosis via partial cricotracheal resection. Postoperative management of these patients is frequently complicated by the need to allow the larynx to heal for 5 to 14 days while maintaining a patent airway with an endotracheal tube. Management of the patient during this critical period is controversial. Some favor heavy sedation including the use of neuromuscular blocking agents to minimize the chance of movement of the ETT and accidental extubation. Others favor the opposite, actually allowing the patient to be alert and active with the ETT in place.¹⁰² Fortunately, improvements in postoperative care have resulted in improved outcomes after laryngotracheal reconstruction.¹⁰³

Ideally, reconstruction will be performed at a young age (younger than 25 months) to minimize the time period the child is exposed to the hazards of being dependent on the tracheotomy airway, and so that the child's speech and language development is not impaired.¹⁰⁴ Earlier laryngotracheal reconstruction may, however, be more prone to failure and requirement for revision procedures.

Foreign Body Aspiration

Airway obstruction may be produced by aspiration of a variety of foreign bodies, with nuts being one of the most frequent offenders in children.¹⁰⁵ Most of the patients aspirating foreign bodies are aged 1 to 3 years, with more than 95% being younger than 10 years. Fewer than 30% of patients aspirating foreign bodies receive medical attention within the first 24 hours, with many patients experiencing a significant delay before seeking medical attention. A clear history of foreign body aspiration may be elicited from 40% to 80% of the patients.¹⁰⁶ Patients with an aspirated foreign body may initially be symptom-free or may have a cough, wheezing, and evidence of respiratory embarrassment. Patients without symptoms who do not seek medical attention may have a persistent cough and may develop pneumonia distal to the obstructed bronchus. Recurrent bouts of pneumonia may lead to bronchiectasis if the foreign body is not removed.

Foreign bodies may become lodged in the airway anywhere from the posterior pharynx to the bronchi. The symptoms produced by foreign body aspiration vary according to the site of the foreign body and the degree of obstruction it produces. Foreign bodies of the extrathoracic airway characteristically produce inspiratory stridor. Foreign bodies lodged in the intrathoracic trachea and bronchi tend to produce expiratory stridor and wheezing.

Radiographic evaluation should include inspiratory and expiratory radiographs because a single anteroposterior radiograph will be unremarkable in 18% of children with an aspirated foreign body (Figure 44-15).¹⁰⁶ If the foreign body

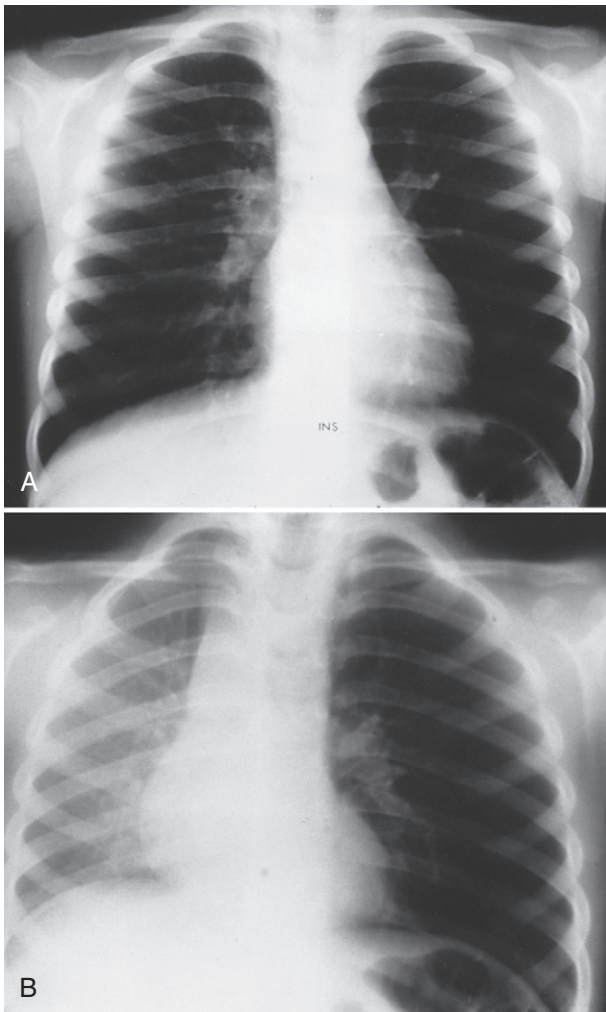


Figure 44-15. **A**, Inspiratory chest radiograph with foreign body present in left mainstem bronchus. The left lung is slightly hyperinflated but could be considered normal. **B**, Expiratory chest radiograph with foreign body present in left mainstem bronchus. The left lung is clearly hyperinflated because of air trapping by the foreign body. (**A** and **B**, Courtesy Eric Effmann, MD.)

is producing ball-valve bronchial obstruction, hyperinflation of the involved lung will be seen during the expiratory radiogram. Many foreign bodies are not radiopaque,¹⁰⁷ so failure to see a foreign body on the chest radiograph cannot exclude this diagnosis. If a suspicion of an aspiration is high, a bronchoscopy is warranted (Figure 44-16).

Foreign bodies are removed from the tracheobronchial tree with a bronchoscope.¹⁰⁸ Depending on the material, this may be a difficult procedure, although improvement in bronchoscopes in recent years has greatly facilitated this undertaking. Cardiopulmonary bypass has been successfully used to support a patient who had extensive foreign body aspiration. Occasionally, bronchoscopic extraction is unsuccessful, and a pulmonary lobectomy is required.

Traumatic Injury to the Airway

Traumatic injury to the upper airway may be divided into two broad categories: oral facial trauma and laryngeal/tracheal trauma. Patients with obvious oral facial trauma may be at

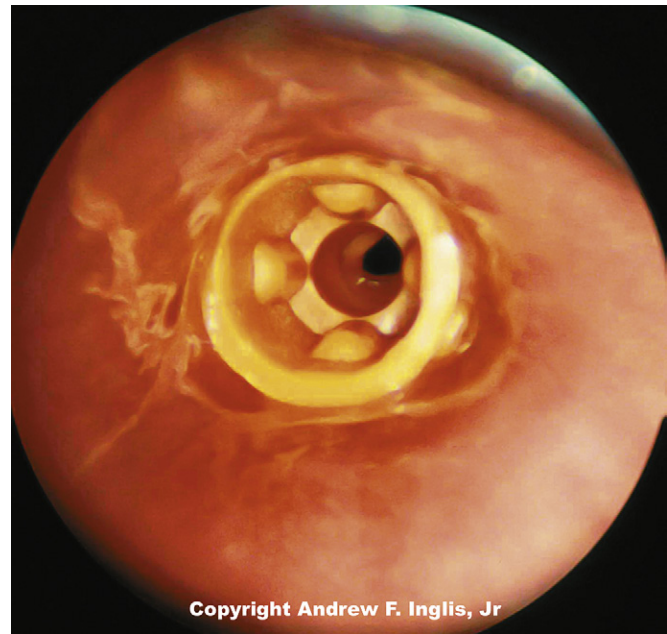


Figure 44-16. Hollow plastic foreign body in patient's trachea. Because the lumen of the foreign body was aligned with the tracheal lumen, severe respiratory embarrassment did not occur. (Copyright Andrew F. Inglis, Jr.)

risk for upper airway obstruction. Even if the patients have no sign of respiratory distress at the time of presentation, swelling of soft tissues and hemorrhaging to the airway may lead to airway compromise.

Patients who must undergo operative intervention to treat their traumatic injuries need careful evaluation of their airway, including radiographs and CT scan examination. Traumatic injuries may make intubations in the trachea difficult in these patients. For this reason, sedation is to be avoided and endotracheal intubation with the patient awake should be considered. This may be accomplished with direct laryngoscopy after local anesthesia has been applied to the patient's oropharynx. In more difficult cases, it may be necessary to use a fiberoptic bronchoscope to guide the ETT into the trachea.

Postoperatively, patients undergoing repair of facial trauma may have their jaw wired shut and the ETT sutured in place to prevent accidental extubation. These patients should undergo extubation only when fully awake, and after resolution of their airway and facial edema. Instruments to open the wires should always be kept at the patient's bedside. Emesis may present a grave hazard in these patients.

Injury to the larynx and trachea may occur after blunt trauma such as automobile accidents, after penetrating trauma, or with crush injuries such as hanging. Blunt trauma to the neck may lead to fracture of the cartilaginous rings supporting the trachea or to disruption of the tracheal mucosa. In the latter case, attempted endotracheal intubation may worsen a partial tracheal transection and create an airway emergency.¹⁰⁹ Signs of laryngeal injury include dyspnea, altered phonation, pain on swallowing, hoarseness, swelling, and subcutaneous emphysema of the neck. The development of subcutaneous emphysema after blunt trauma to the neck suggests that a laryngeal fracture or tracheal tear has occurred. The quantity of air in the subcutaneous tissues does not correlate with the severity of the injury. Establishment of an adequate airway is

an essential consideration. Acute trauma of the larynx is often treated with placement of a tracheostomy before surgical repair of the larynx.

Blunt thoracic trauma can cause tracheal or bronchial disruption. Most commonly, these are “blowout” injuries that result in tracheobronchial disruption. These injuries usually occur near the carina, and most involve mainstem bronchi.¹¹⁰ Because children have flexible ribs, severe intrathoracic injuries can occur without rib fractures. The signs of tracheobronchial disruption include persistent air leak, failure to expand the lung with thoracostomy tube drainage, and massive atelectasis (from failure to conduct gas through an injured bronchus). Diagnosis of these injuries is usually made with bronchoscopy. Although small tracheobronchial disruptions may be managed conservatively, most of these lesions require surgical repair.¹¹⁰

Burn Injury to the Upper Airway

Thermal injury to the upper airway may complicate the management of a patient with burns. The presence of facial burns and singed nasal hairs, hoarseness, or inspiratory stridor should suggest the possibility of burn injury to the upper airway. Although respiratory compromise may not be present at the time of admission, it may develop later as swelling of the injured airway becomes more severe. Because of the efficient cooling capacity of the upper air passages, thermal injury to the airway below the vocal cords is uncommon, occurring in less than 5% of all hospitalized patients with burns.

Evidence of respiratory embarrassment in a patient with burns should be rapidly evaluated. Neck radiographs and fiberoptic examination of the larynx may show swelling of the soft tissues of the airway. If these findings are present, endotracheal intubation should be expeditiously performed to secure the airway before obstruction occurs. Because of the risk of infection, attempts are made to avoid tracheostomy placement in the patient with burns, and data suggest this is a safe practice.¹¹¹ Upper airway embarrassment is often accompanied by smoke inhalation injury to the lower airway, resulting in hypoxemia and hypercapnia. The products of combustion result in severe carbon monoxide intoxication or cyanide poisoning, both of which have nonspecific symptoms but require prompt medical therapy.¹¹²

Angioedema

Angioedema is a well-demarcated localized edema involving the deep layers of skin, including the subcutaneous tissue. Angioedema may occur in response to a variety of systemic disorders, including allergic reactions that are mediated with immunoglobulin E, anaphylactic and anaphylactoid reactions, and other illnesses. Angioedema may lead to swelling of the soft tissue of the face, particularly the eyes and lips. If this should involve the soft tissues of the upper respiratory tract, laryngeal obstruction may result. Administration of subcutaneous epinephrine may dramatically reduce swelling caused by this condition. Compared to adults, children often have a rapid response to antihistamines and steroids.¹¹³ Occasionally, respiratory embarrassment caused by this condition is so severe that endotracheal intubation is warranted. The evaluation of patients with this disorder should be directed at (1) the identification of the causative agents so that the patients

can avoid these in the future and (2) the anatomic site of presentation to allow stratification of airway risk and planning of appropriate triage for airway intervention.¹¹⁴

Tracheostomy

Indications for the placement of a tracheostomy fall into three broad, frequently overlapping categories: airway obstruction, assisted ventilation, and pulmonary toilet. Pediatric anatomical anomalies that may necessitate tracheostomy are most often manifested in the neonatal period or in infancy, although some may not appear until childhood. The most common abnormalities include vocal cord paralysis (congenital and postbirth injury), subglottic stenosis, tracheal stenosis, cystic hygroma, tracheal hemangioma, and laryngeal cyst. The accurate diagnosis of these problems is frequently made during bronchoscopic examination of the larynx and trachea while the patient is anesthetized. If the obstruction is of sufficient magnitude, consideration should be given to doing a tracheostomy at the time of bronchoscopy.

Infants may require a tracheostomy because of the need for prolonged periods of assisted ventilation. The advent of neonatal intensive care has enabled small preterm infants to survive despite severe respiratory illness. Many of these patients will need lengthy periods of mechanical ventilation to treat infant respiratory distress syndrome and bronchopulmonary dysplasia. Prolonged intubation may lead to subglottic stenosis.¹¹⁵ For a reduction in the frequency of this complication, a tracheostomy may be performed. The optimal timing of tracheostomy for children who need long-term intubation is controversial. In many neonatal ICUs, infants needing mechanical ventilatory support for more than 30 to 45 days will undergo a tracheostomy. Placement of a tracheostomy is not a trivial matter, with several large studies showing a tracheostomy-related mortality rate of 0.5% to 0.7%.^{116,117} One recent study provided evidence that long-term tracheostomy is associated with airway inflammation (number of cells, neutrophils), more frequent bacteria, and reduced concentration of surfactant protein-D.¹¹⁸ The decline of polio in the United States during the decade following 1950 dramatically decreased the number of tracheostomies performed to facilitate mechanical ventilation and pulmonary toilet. Nevertheless, several pediatric diseases predictably lead to prolonged neuromuscular failure. Infants with infant botulism may have prolonged neuromuscular weakness and may undergo a tracheostomy to simplify management of mechanical ventilation. Similarly, older children with Guillain-Barré syndrome and respiratory failure may need a tracheostomy if a lengthy course of mechanical ventilation is expected. The use of tracheostomy has been advocated to promote pulmonary toilet and improve ventilation during the treatment of flail chest.

The timing of the tracheostomy will depend on several issues, including the patient's underlying illness and the severity of the condition that makes tracheostomy necessary. If possible, emergency tracheostomy under unfavorable conditions should be avoided because the complications are more common in this setting. Percutaneous placement of a tracheostomy has been widely used in the adult population; however, experience in children remains limited. One small retrospective series suggests that placement in the ICU can be done safely with adherence to sound techniques and prudent patient selection.¹¹⁹

Postoperative Nursing Care

Care from attentive, trained nurses is essential for the well-being of the patient with a tracheostomy. Until a tract of granulation tissue has formed in the stoma between the cervical and tracheal epithelium, precautions should be taken to prevent the accidental displacement of the tracheostomy tube. Although stay sutures simplify replacement of the tracheostomy tube, this procedure may be difficult, especially in an emergency situation with a struggling patient. A hastily replaced tube may be incorrectly located in the pretracheal soft tissue, resulting in asphyxiation. If positive-pressure ventilation is attempted with the tube in this position, subcutaneous and mediastinal emphysema may be followed by a life-threatening tension pneumothorax. Because of these risks, patients routinely stay in the ICU for 5 to 7 days postoperatively. Smaller children have arm restraints placed to prevent them from pulling at the tracheostomy tube. If necessary, sedation is given until the child grows accustomed to the tracheostomy and the tract matures with the formation of granulation tissue. If accidental displacement of the tracheostomy tube does occur, replacement may be facilitated with a gentle insertion of a 0 Miller laryngoscope blade into the stoma and the identification of the tracheal lumen before the tube is passed.

Besides avoiding accidental displacement of the tracheostomy, the nurse must constantly monitor the patient for obstruction of the tracheostomy tube. The tube may be obstructed by dried tracheal mucus. Sometimes the patient's chin may obstruct the tube. Humidified gas may be administered to prevent drying and inspissation of secretions.

Complications

Any operation on the airway involves risk. The complication rate after tracheostomy has been reported to be 10% to 30%, with a death rate of 3%. Early postoperative complications include air leak, hemorrhage, and aspiration. Air leak is seen more often in children than in adults and may be life-threatening. The risk of complications declines as the patient ages. Some life-threatening complications, such as accidental

decannulation or tracheostomy tube obstruction, may occur anytime after the placement of a tracheostomy. The safety and well-being of patients with a tracheostomy require constant vigilance to prevent these mishaps.

Swallowing dysfunction after tracheostomy may lead to aspiration of saliva and food. This may be due in part to anchoring of the trachea to the skin of the neck, preventing the cephalad movement of the trachea during swallowing. Children who have a tracheostomy often have difficulty learning to eat. The high frequency of pneumonia observed after tracheostomy may be in part due to the problem of recurrent aspiration. Aerophagia, another form of swallowing dysfunction, occurs with modest frequency in pediatric patients after tracheostomy.

Late complications include granulation tissue formation, tracheal stenosis, infection of the stoma, pneumonia, fused vocal cords, and distal tracheomalacia. Although infection of the stoma and distal tracheomalacia may be evident before decannulation, granulation formation and fused vocal cords may not be apparent until decannulation is attempted. An uncommon, but particularly dangerous late complication is erosion of the tracheostomy tube into the innominate artery.

Decannulation

Problems at the time of decannulation occur in up to 36% of children. These difficulties are most frequent in patients younger than 1 year. Structural abnormalities that result in decannulation problems include subglottic stenosis, tracheomalacia at the tracheostomy site, granuloma tissue obstructing the trachea, and fused vocal cords. If respiratory distress is encountered during decannulation, it should not be attributed to the patient's psychological dependence on the tracheostomy tube. Evaluation of the airway with bronchoscopy or a lateral neck radiograph is important. Psychological factors should not be considered until structural causes of respiratory embarrassment have been eliminated.

References are available online at <http://www.expertconsult.com>.