

Modified inexpensive needle for suprachoroidal triamcinolone acetonide injections in pseudophakic cystoid macular edema

Avadhesh Oli, Shrikant Waikar

Pseudophakic cystoid macular edema (PCME) is one of the leading causes of reduced vision, after cataract surgery. Topical steroids and nonsteroidal anti-inflammatory drops are frequently used in the management; however, intravitreal injections may be required for chronic cases. Suprachoroidal injection of preservative free Triamcinolone acetonide is a recent addition to the therapeutic armamentarium of ophthalmologists for treatment of cystoid macular edema of varied etiology. Though the drug is commercially available at a reasonable cost, the microneedle is not commonly available. We modified a 26 G needle for safe and cost-effective delivery of preservative-free suprachoroidal triamcinolone acetonide (SCT). In the current series of three patients with non-resolving PCME, macular edema resolved and vision improved over 3 months.

Key words: Cataract surgery complications, pseudophakic macular edema, suprachoroidal injection, suprachoroidal steroids, triamcinolone

Pseudophakic cystoid macular edema (PCME) is one of the leading cause of reduced vision, after cataract surgery, and the incidence is reported from 0.5 to 2.4% in various studies.^[1] In a study on cost analysis of bill payments by patients who developed PCME, it was reported that the patients with PCME paid 41% higher than patients who did not develop.^[2] The PCME is caused by inflammation leading to the break in the outer blood-retinal barrier. Topical steroids and nonsteroidal anti-inflammatory (NSAID) drops are the mainstays of therapy; however, chronic PCME requires periocular or intravitreal injections. Although peri-ocular or intravitreal steroids are used for the treatment of PCME, significant side effects like glaucoma are reported.^[3]

Steroid implants, which are sustained released drug-eluting devices, are used to overcome these side effects. Although the steroid implants have lesser side effects and prolonged duration of action, yet, the high prohibitory cost is a major limiting factor. Recent studies on outcomes of depot steroid injection of triamcinolone into suprachoroidal space have shown favorable results in terms of improved efficacy, lesser side effects and longer duration of action on CME due to uveitis and retinal vein occlusion.^[4-6] The micro-needle used for injection is short and does not enter the vitreous cavity, and the chances of accidental retinal tear and endophthalmitis are avoided. Besides, the

procedure can be performed in an office setting under sterile precautions. However, the critical limitation is the high cost and non-availability of the specialized microneedle.

Surgical Technique

We innovated a needle for safe and cost-effective delivery of preservative-free Triamcinolone acetonide (TA) into the suprachoroidal space.

Institutional ethical committee clearance was taken for the study. Patients with chronic PCME on topical NSAIDs for more than 3 months were enrolled after informed consent. A separate consent to publish these findings, images, OCT, and surgical video was gathered from the patient.

A 22 G intracath (used for intravenous injections) with a dimension of 25 mm length and 0.9 mm outer diameter (Anina India) was taken. The plastic sheath of 22 G intracath was cut into two halves after removing the stylet, using scissors. A 26-gauge needle (length 13 mm, diameter of 0.45 mm, Safe way, Med devices Ltd, UK) was mounted on 1 CC insulin syringe with preservative-free triamcinolone 4 mg/0.1 ml (AuroLab). The 26 G needle was passed through the lumen of this hollow sheath of intracath, and final adjustment in the

Video Available on:
www.ijo.in

Access this article online

Website:
www.ijo.in

DOI:
10.4103/ijo.IJO_1464_20

Quick Response Code:



Post Graduate Department of Ophthalmology, INHS Asvini, Colaba Mumbai, Maharashtra, India

Correspondence to: Dr. Avadhesh Oli, Post Graduate Department of Ophthalmology, Institute of Naval Medicine, Indian Naval Hospital Ship Asvini, Near RC Church Colaba, Mumbai - 400 005, Maharashtra, India. E-mail: olieye@rediffmail.com

Received: 13-May-2020
Accepted: 12-Aug-2020

Revision: 25-Jul-2020
Published: 17-Feb-2021

This is an open access journal, and articles are distributed under the terms of the Creative Commons Attribution-NonCommercial-ShareAlike 4.0 License, which allows others to remix, tweak, and build upon the work non-commercially, as long as appropriate credit is given and the new creations are licensed under the identical terms.

For reprints contact: WKHLRPMedknow_reprints@wolterskluwer.com

Cite this article as: Oli A, Waikar S. Modified inexpensive needle for suprachoroidal triamcinolone acetonide injections in pseudophakic cystoid macular edema. *Indian J Ophthalmol* 2021;69:765-7.

length of the outer sheath was made to expose terminal 1 mm of the bevelled needle tip which was reconfirmed with a calliper. Each half of the intracath sheath (length of 12 mm) was used to prepare two separate injections [Fig. 1a and b].

The eye was cleaned, draped, and a lid speculum was applied. The 26 G needle with an outer sheath of intracath and exposed 1 mm tip was held perpendicularly to the sclera with the bevel pointing posteriorly away from the limbus [Video 1]. Perpendicular entry with the needle was made at the marked point (4 mm from the limbus in superotemporal quadrant), on the sclera and sufficient pressure was applied to create a dimple on the sclera [Fig. 1c]. 4 mg of triamcinolone in 0.1 ml was injected slowly by pressing the plunger of the syringe. A cotton bud was used to avoid the reflux of the drug after the needle was withdrawn. One drop of betadine was instilled at the end of the procedure. Any intraoperative injection-related complications were documented. Patients were followed up to 12 weeks for change in visual acuity, intraocular pressure, central macular thickness (CMT), and any complications [Fig. 1d-f].

The mean baseline visual acuity in this series of three patients was 1 log MAR which improved to 0.3 log MAR at the end of 4 weeks. The central macular thickness reduced from a mean of 473.5 microns to 287 microns. The intraocular pressure remained within normal limits. No significant side effect like uveitis or glaucoma were noted. This innovative method of suprachoroidal injection was successful in all patients without any procedure-related complications. At the end of 6 months, the visual acuity was maintained.

Discussion

PCME is a known complication of cataract surgery. Topical NSAIDs, along with steroids, are the first-line drugs used; however, intravitreal anti-VEGFs are used for severe non-responsive cases. The other alternatives are the steroid implants due to lesser side effects, but the cost is exorbitantly high. A recent phase 3 trial has proven efficacy of SCT in macular edema of uveitis and retinal vein occlusion.^[4,6,7] In animal studies, SCT has been found to reach a high concentration in the posterior segment with lesser side effects of glaucoma and cataract. The concentration of drug in the posterior segment is reported to be 10 times greater than the anterior segment.^[5] SCT concentration remains high near to the site of activity, which improves efficacy and prolongs the duration of action.

The limitation of broader applicability of SCT is non-availability of an appropriate needle for the safe injection procedure. This innovated needle was designed from inexpensive sterile material available in the operating room. The outer sheath of one intracath was utilized to make two separate SCT injections making it further economical. The outer sheath of intracath exposes only 1 mm of bevelled end of the needle which pierces the sclera and remains in suprachoroidal space. The SCT diffuses into the suprachoroidal space, which is a potential space and opens up while injecting the drug.

The only precaution to be exercised while injecting SCT is that the bevelled end of the needle at terminal 1 mm should not be covered with outer sheath otherwise the drug may

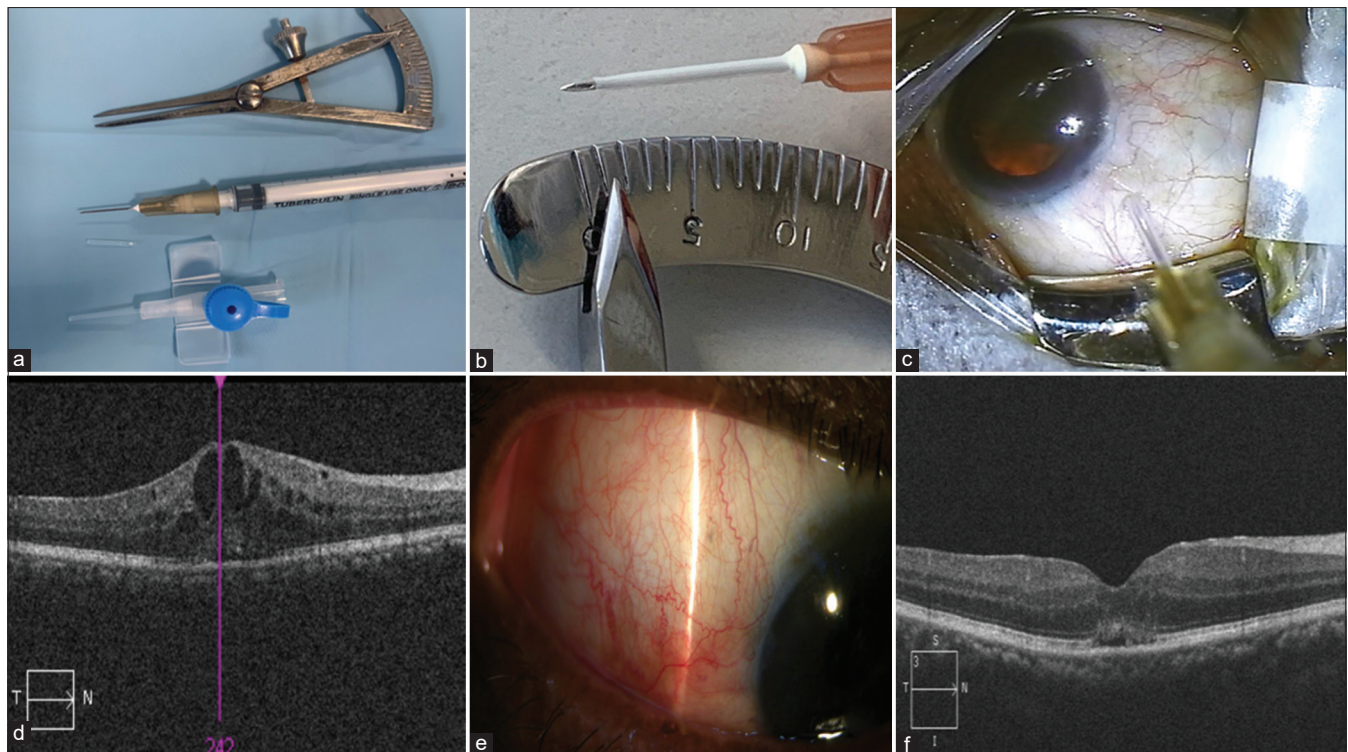


Figure 1: (a) The outer sheath of intracath is cut and used to cover the 26-gauge needle till the bevelled edge. (b) The outer sheath of intracath expose 1 mm bevelled end of the needle reconfirmed by measuring with calipers. (c) Intraoperative photograph showing the needle in suprachoroidal space at 4 mm from the limbus. (d) Baseline optical coherence tomography with prominent cystic spaces and macular edema. (e) Slit-lamp photograph showing injection site with minimal congestion. (f) Optical coherence tomography with reduction in intraretinal cysts and resolving macular edema

leak out through the gap between outer sheath and needle, instead of going into suprachoroidal space [Fig. 1b]. It is also emphasized to apply firm pressure with the needle to create a small dimple on the sclera to ensure adequate penetration of the needle length into suprachoroidal space. The bevel of the needle should be pointing away from limbus so that the drug diffuses posteriorly.

Risk of injury to intraocular structures, retinal tear, retinal detachment, and endophthalmitis is less likely as compared to intravitreal injections since the vitreous cavity is not entered. The injection is given under direct visualization of the needle unlike posterior sub-tenon triamcinolone and chances of inadvertent globe perforation would be lesser.

One patient reported mild pain immediately after the procedure, which subsided after 1 h without any specific treatment. Pain is possible because of the expansion of suprachoroidal space with SCT. Mild congestion at the site of injection was noted, which subsided after 2-3 days [Fig. 1e].

The long duration of action of the drug, as confirmed by pharmacokinetic studies on animals may have a sustained effect on the macular edema. It may aid in stabilizing the vision in the long term.^[8] Less frequent injections would also drastically cut down the cost of repeated injections. This innovative method of SCT will be useful for patients in developing world where the cost of health care is a concern.

However, the patients in this series were not on treatment for glaucoma at baseline, and none of the patients had raised IOP or required any medication to reduce the IOP.

Conclusion

We present a technique of suprachoroidal injection of Triamcinolone with a 26 G needle and sleeve of intracath. This new technique is cost-effective and safe in patients with post-cataract surgery PCME with good functional and anatomical outcomes.

Financial support and sponsorship

Nil.

Conflicts of interest

There are no conflicts of interest.

References

1. Hoffman RS, Braga-Mele R, Donaldson K, Emerick G, Henderson B, Kahook M, *et al.* Cataract surgery and nonsteroidal antiinflammatory drugs. *J Cataract Refract Surg* 2016;42:1368-79.
2. Schmier JK, Covert DW, Hulme-Lowe CK, Mullins A, Mahlis EM. Treatment costs of cystoid macular edema among patients following cataract surgery. *Clin Ophthalmol (Auckland, NZ)* 2016;10:477-83.
3. Han JV, Patel DV, Squirrell D, McGhee CN. Cystoid macular oedema following cataract surgery: A review. *Clin Exp Ophthalmol* 2019;47:346-56.
4. Campochiaro PA, Wykoff CC, Brown DM, Boyer DS, Barakat M, Taraborelli D, *et al.* Suprachoroidal triamcinolone acetonide for retinal vein occlusion: Results of the tanzanite study. *Ophthalmol Retina* 2018;2:320-28.
5. Gilger BC, Abarca EM, Salmon JH, Patel S. Treatment of acute posterior uveitis in a porcine model by injection of triamcinolone acetonide into the suprachoroidal space using microneedles. *Invest Ophthalmol Vis Sci* 2013;54:2483-92.
6. Yeh S, Kurup SK, Wang RC, Foster CS, Noronha G, Nguyen QD, *et al.* Suprachoroidal injection of triamcinolone acetonide, CLS-TA, for macular edema due to noninfectious uveitis: A randomized, Phase 2 study (DOGWOOD). *Retina* 2019;39:1880-8.
7. Wykoff CC, Khurana RN, Lampen SIR, Noronha G, Brown DM, Ou WC, *et al.* Suprachoroidal triamcinolone acetonide for diabetic macular edema: The HULK Trial. *Ophthalmology Retina* 2018;2:874-7.
8. Chen M, Li X, Liu J, Han Y, Cheng L. Safety and pharmacodynamics of suprachoroidal injection of triamcinolone acetonide as a controlled ocular drug release model. *J Control Release* 2015;203:109-17.