

CLINICAL IMAGE

Steroid Cell Ovarian Tumor in a Case of von Hippel-Lindau Disease: Demonstrating Lipid Content of the Mass with MR Imaging

Ajaykumar C. Morani^{1*}, Ahmad Iyad Mubarak¹, Hrishabh R. Bhosale², Nisha S. Ramani³, Steven G. Waguespack⁴, and Anita Ying⁴

Keywords: lipid cell tumor, lipoid cell tumor, magnetic resonance imaging, steroid cell tumor, von Hippel-Lindau disease

Steroid cell tumors of the ovary are rare, functioning sex cord-stromal ovarian tumors.¹ Previously, they were called lipid cell tumors because of their high lipid content.^{1,2} Two cases demonstrating occurrence of this rare ovarian tumor within the context of von Hippel-Lindau (VHL) disease have been reported.^{2,3} VHL disease is an autosomal dominant familial inherited syndrome, with varied manifestations depending on the specific mutation. Pancreatic neuroendocrine tumors in association with pheochromocytoma are a classic phenotype of VHL disease,³ but association with steroid tumor of the ovary is a very rare occurrence.

A 17-year-old female with VHL, who had previously undergone adrenal sparing surgeries for bilateral pheochromocytomas, presented to our institution with hirsutism and menstrual irregularity. Serum testosterone was elevated at 269 ng/dL. She received regular screening per VHL alliance guidelines,² which included imaging of her abdomen, but not the pelvis. MRI showed a hypervascular pancreatic mass with central low signal, corresponding to a calcified pancreatic mass on CT, presumably the neuroendocrine tumor. No virilizing etiology was identified. So, MRI of the pelvis was performed, and this showed an enhancing right adnexal mass not seen separate from the ovary (Fig. 1). It showed drop of signal on pre-contrast T₁-weighted (T₁W) opposed phase (Fig. 2) compared to T₁W in-phase imaging consistent with lipid content within the mass. The mass was later pathologically proven to be steroid cell tumor.

Although germ cell tumors (teratomas) are the most common lipid containing ovarian tumors, they rarely cause virilization. Lipid containing metastasis from clear cell renal cell cancer which can occur with VHL, is a rare possibility. However, these do not cause virilization, and the kidneys were normal in our case. Virilization and menstrual irregularity in our patient raised the suspicion of an androgen-producing ovarian tumor, with the differential diagnosis including Sertoli-Leydig cell tumors, Leydig cell tumors, steroid cell tumors, and less frequently, granulosa-theca tumor.¹ Rarely, nonfunctional ovarian tumors like epithelial cystadenomas or cystadenocarcinomas stimulate steroid production in the adjacent normal ovarian stroma and present with hyperandrogenism.¹ The combination of lipid content within the ovarian mass (as demonstrated by loss of signal on out-of-phase chemical shift imaging) with virilization pointed to the diagnosis of a steroid cell tumor. There is very little literature on the MRI features of lipid content within such a tumor, which in the setting of virilization and VHL, pointed to the diagnosis in our case. The treatment of

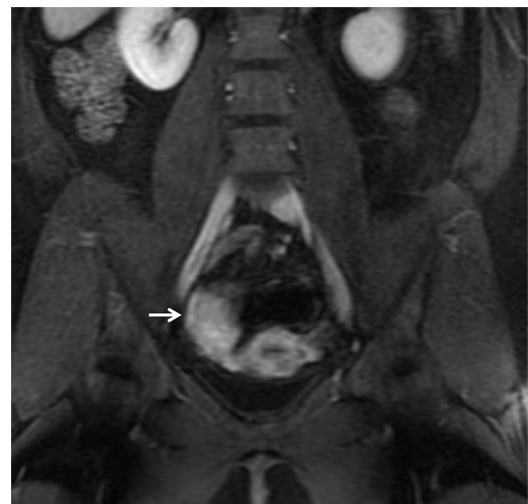


Fig. 1 Coronal post-contrast T₁WI MRI of the pelvis showed an enhancing mass in the right adnexa (arrow), not seen separate from the right ovary. The uterus was normal. T₁WI, T₁-weighted image.

¹Department of Diagnostic Radiology, The University of Texas MD Anderson Cancer Center, 1515 Holcombe Blvd, Houston, TX 77030, USA

²St. John's School, TX, USA

³Department of Pathology, SUNY Upstate Medical University, NY, USA

⁴Department of Endocrine Neoplasia, The University of Texas MD Anderson Cancer Center, TX, USA

*Corresponding author, Phone: +1-713-563-1412,
E-mail: amorani@mdanderson.org

©2018 Japanese Society for Magnetic Resonance in Medicine

This work is licensed under a Creative Commons Attribution-NonCommercial-NoDerivatives International License.

Received: May 30, 2018 | Accepted: December 19, 2018

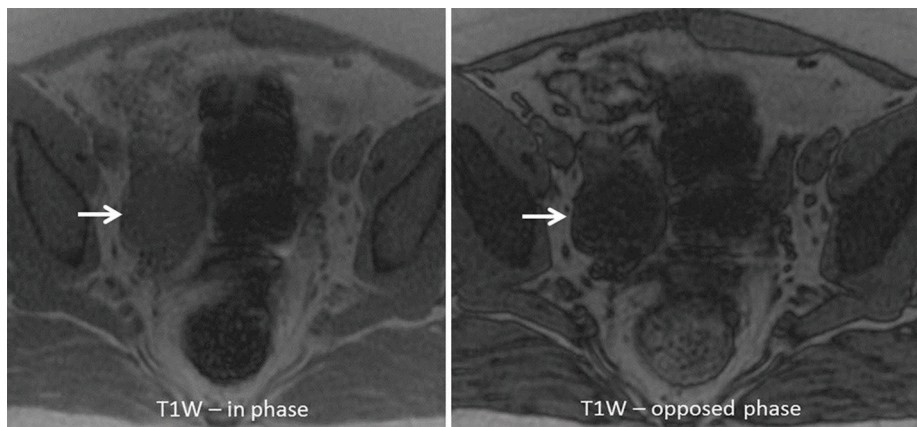


Fig. 2 Axial pre-contrast T₁WI MRI of the pelvis demonstrating the same mass (arrows) seen on Fig. 1. It showed drop of signal on T₁W opposed phase (right image) compared to T₁W in-phase imaging (left image), consistent with lipid content within the mass. T₁WI, T₁-weighted image.

choice for symptomatic abdominal tumors in VHL is generally organ sparing resection. Unfortunately, for this young patient with a genetic condition likely predisposing her to such ovarian tumors, she developed a second tumor in her contralateral ovary eventually needing resection of both ovaries.

In conclusion, as most steroid cell ovarian tumors demonstrate high lipid content, exploiting the chemical shift artifact on dual echo gradient-echo (GRE) MRI due to this lipid content may help to clinch the diagnosis in the appropriate clinical context of virilizing features in a case of VHL disease with adnexal mass, as demonstrated in our case.

Conflicts of Interest

The authors declare that they have no conflicts of interest.

References

1. Swain J, Sharma S, Prakash V, Agrawal NK, Singh SK. Steroid cell tumor: a rare cause of hirsutism in a female. *Endocrinol Diabetes Metab Case Rep* 2013; 2013:130030.
2. Wagner M, Browne HN, Marston Linehan W, Merino M, Babar N, Stratton P. Lipid cell tumors in two women with von Hippel-Lindau syndrome. *Obstet Gynecol* 2010; 116 Suppl 2:535–539.
3. Griffiths DF, Williams GT, Williams ED. Duodenal carcinoid tumours, phaeochromocytoma and neurofibromatosis: islet cell tumour, phaeochromocytoma and the von Hippel-Lindau complex: two distinctive neuroendocrine syndromes. *Q J Med* 1987; 64: 769–782.