

Gastric phytobezoars as a very unusual cause of gastric outlet obstruction

Elham Tabesh¹, Amin Dehghan², Marzieh Tahmasebi³, Niloofar Javadi²

¹Department of Internal Medicine, School of Medicine, Isfahan University of Medical Sciences, Isfahan, Iran, ²Student Research Committee, School of Medicine, Isfahan University of Medical Sciences, Isfahan, Iran, ³Health Information Technology Research Center, Clinical Informationist Research Group, Isfahan University of Medical Sciences, Isfahan, Iran

Bezoars are collections of indigestible foreign material found in the gastrointestinal tract. Phytobezoars are the most common among the types of bezoars. Treatment of phytobezoars is categorized into four types: chemical dissolution, endoscopic removal, adjuvant prokinetics, and surgery. Complications from phytobezoars can include gastric outlet obstruction (GOO), ileus, ulcerations, gastrointestinal bleeding, and perforation. Herein, we present an 86-year-old woman with refractory postprandial vomiting. Then, exploratory laparotomy was performed and the diagnosis was gastric phytobezoar. Phytobezoars-induced GOO is rare and its diagnosis is still a challenge.

Key words: Bezoars, case report, gastric outlet obstruction, gastric phytobezoars, laparotomy

How to cite this article: Tabesh E, Dehghan A, Tahmasebi M, Javadi N. Gastric phytobezoars as a very unusual cause of gastric outlet obstruction. *J Res Med Sci* 2021;26:25.

INTRODUCTION

Bezoars are collections of indigestible foreign material found in the gastrointestinal tract of humans and animals.^[1] Bezoars are divided into four groups according to their combination, including phytobezoars (fibers, fruit remnants, and skins of vegetables), trichobezoars (ingested hair), pharmacobezoars (medications), and lactobezoars (milk protein in milk-fed babies and infants).^[2] Phytobezoars are the most common among the types of bezoars. Some foods contain high amounts of cellulose, hemicellulose, lignin, and tannins, which are the main components of phytobezoars.^[3] Complications from phytobezoars include gastric outlet obstruction (GOO), ileus, ulcerations due to pressure necrosis, and subsequent gastrointestinal bleeding (GIB) and perforation.^[4,5]

Here, we report a very unusual case of GOO due to gastric phytobezoars, whose diagnosis and treatment were done by laparotomy. A comprehensive search

of the electronic databases (PubMed, Scopus, Web of Science, and Google Scholar) was conducted. Searches were confined to literature using the following search terms: (bezoars or phytobezoars) and gastric obstruction outlet.

CASE REPORT

An 86-year-old woman with a chief complaint of postprandial vomiting for 20 days came to Khorshid Hospital Clinic in Isfahan City. She was carrying a multidetector computerized tomography (MDCT) with contrast from a week ago that reported an unknown soft tissue lesion adjacent to gastric antrum and duodenum; therefore, she was admitted to the gastroenterology ward, Khorshid Hospital. She described her vomiting as projectile and nonbloody, which had been occurred 5–10 min after swallowing solid foods but not liquids. Her last episode of defecating was the previous night of admission. She also noted colicky abdominal pain in the right upper quadrant, which was not associated

Access this article online

Quick Response Code:



Website:
www.jmsjournal.net

DOI:
10.4103/jrms.JRMS_115_20

This is an open access journal, and articles are distributed under the terms of the Creative Commons Attribution-NonCommercial-ShareAlike 4.0 License, which allows others to remix, tweak, and build upon the work non-commercially, as long as appropriate credit is given and the new creations are licensed under the identical terms.

For reprints contact: WKHLRPMedknow_reprints@wolterskluwer.com

Address for correspondence: Dr. Niloofar Javadi, School of Medicine, Isfahan University of Medical Sciences, Isfahan, Iran.
E-mail: javadi.niloofar75@gmail.com

Submitted: 02-Feb-2020; **Revised:** 15-Mar-2020; **Accepted:** 22-Dec-2020; **Published:** 31-Mar-2021

with eating and defecation. No sign and symptoms of GIB were detected. There was a history of loss of appetite but no evidence of weight loss.

She had been suffered from hypertension and right-sided heart failure due to chronic obstructive pulmonary disease, but there was no history of other comorbidities such as diabetes mellitus. We found a history of cholecystectomy surgery from her medical record. On physical examination, the abdomen was soft with no tenderness and organomegaly. Three plus (3+) lower extremities edema was measured that was supposed as a result of right-sided heart failure. The rest of her examinations were unremarkable. Her electrocardiogram had normal sinus rhythm with the normal axis. Q-wave was detected in inferior leads (III, avf). It also had poor R progression, prolong PR, and low-voltage QRS. Her chest X-ray was in the supine position. Mild hyperinflation, mild bilateral hilar prominence, and mild right pleural effusion were detected. Cardiothoracic ratio was increased, but due to the supine position, it was not judicable.

Serum creatinine concentration was 1.1 mg/dL, which classified her in 3A stage of chronic kidney disease (CKD),^[6] but there was no proof of CKD in her medical record. Her echocardiogram showed elevated pulmonary artery pressure and normal left ventricular ejection fraction. Other laboratory findings are shown in Table 1.

MDCT reported a hypodense lesion, measuring 68 mm × 52 mm adjacent to the gastric antrum and duodenum [Figure 1], which can be a soft tissue lesion or chronic collection. To investigate the cause of her persistent vomiting and due to the MDCT report, we decided to perform an endoscopy. Subsequently, these findings were determined by endoscopy: (1) circumferential mucosal ulcers were seen in the distal part of the esophagus, which was classified as esophagitis LA Class D, (2) food remnant was seen in body, fundus of the stomach, and entrance of the pylorus, (3) prominent pylorus was seen due to external pressure. Due to external pressure, GOO was diagnosed which resulted in not passing the endoscope into the first part of the duodenum (D1). Endoscopic images are shown in Figure 2.

Due to endoscopy findings and MDCT report, surgical consultation was done and strongly recommended exploratory laparotomy to accurately diagnose the problem. Since she had a history of elevated pulmonary artery pressure and its related cardiomyopathy, the anesthetic team evaluated her anesthesia at high risk. However, she underwent general anesthesia because of surgery necessity. The patient provided informed consent for expedited laparotomy.

Table 1: Patient laboratory findings at admission time

Laboratory finding	Result	Reference value
Hemoglobin (g/dL)	12.7	12.5-16
Leukocytes ($\times 10^3/\mu\text{L}$)	5.3	4-10
Platelets ($\times 10^3/\mu\text{L}$)	128	150-450
Blood urea nitrogen (mg/dL)	11	7-20
Creatinine (mg/dL)	1.1	0.5-1.0
ESR (mm/h)	53	0-48*
C-reactive protein	2+	Qualitative
Sodium (mEq/L)	142	135-145
Potassium (mEq/L)	4.2	3.5-5

*Upper limit of normal ESR in women older 50 years are calculated as follows: $(\text{age}+10)/2$. ESR: Erythrocyte sedimentation rate

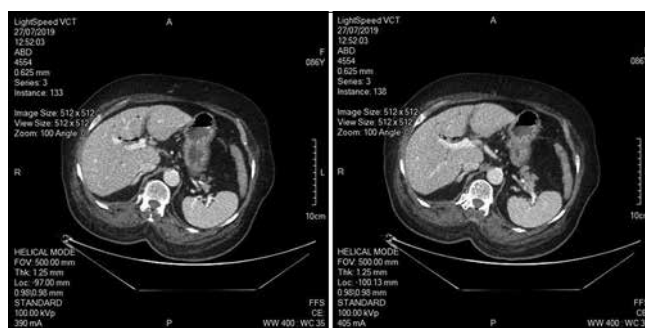


Figure 1: Multidetector computed tomography with contrast showed a hypodense lesion measuring 68 mm × 52 mm adjacent to gastric antrum and duodenum

On the 4th day after hospitalization, an exploratory laparotomy was performed and a huge foreign body was detected in the distal part of the pylorus and bulb. The surgeon did gastrotomy in which they found a bulk of phytobezoars that was the cause of GOO. To remove these phytobezoars, the surgeon smashed them and anastomosed stomach to the proximal jejunum.

After surgery, the anesthetic team could not extubate her because of respiratory distress. Furthermore, her cardiorespiratory function was impaired and she was faced with episodes of cardiopulmonary arrest during recovery, as well as elevated creatinine serum concentration to 2.11 mg/dL. To provide intensive care, she transferred to the intensive care unit. Cardiopulmonary resuscitation was successful at the first and second time of cardiopulmonary arrest on the 3rd day after surgery. Nevertheless, 2 days later, cardiorespiratory arrest occurred again and she expired nine days after admission to the hospital.

DISCUSSION

Bezoars are divided into four main types, including phytobezoars, trichobezoars, and lactobezoars, and medication bezoars. Trichobezoars, known as hairballs, are lump of swallowing hairs common among mentally disabled women and children. Lactobezoars are a pathological condition that occurred in low-birth-weight and premature

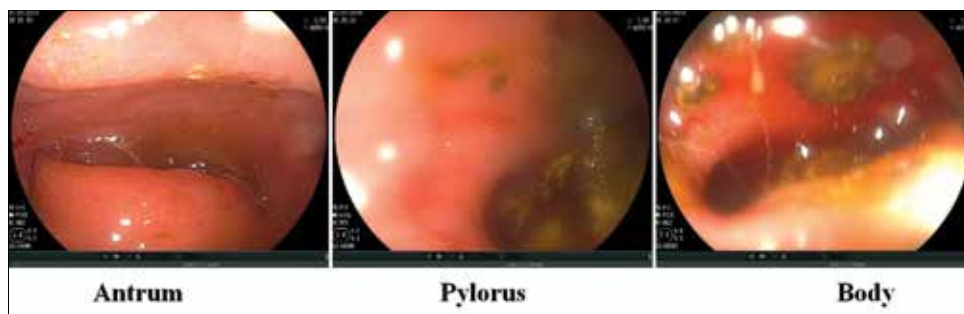

Figure 2: Gastric endoscopy showing food remnant in proximal pylorus

Table 2: The studies on the diagnosis and treatment of patients with phytobezoars, which cause GOO

No	Year	Sex	Age	Symptoms	Diagnostic	Location	Therapeutic technique	Outcome
1	2008	F	62	Epigastric pain, vomiting	Laparotomy	Gastrojejunal anastomosis site	Surgery	Survive
2	2012	M	67	Epigastric pain, vomiting	Endoscopy	Efferent limb of gastrojejunostomy	Endoscopy	Survive
3	2014	M	76	Vomiting	Endoscopy	Pylorus	Endoscopy	Survive
4	2014	M	80	Vomiting, epigastric pain, early satiety	Endoscopy	Pylorus	Endoscopy	Survive
5	2017	M	89	Epigastric pain, vomiting	Endoscopy	Pylorus	Endoscopy	Survive
6	2019	M	57	Abdominal pain, vomiting	Endoscopy	Pylorus	Surgery	Survive
7	2020	F	24	Abdominal pain and vomiting	Endoscopy	Gastric fundus to the pylorus	Surgery	Survive

neonates, and it is the accumulation of highly concentrated preterm formula. Medication bezoars are the aggregation of undigested solid and semi-liquid drugs.^[7] Phytobezoar, the most common type of bezoars, is a concretion formed in the gastrointestinal tract and composed chiefly of undigested compacted plant fiber. Gastric bezoars are relatively rare. A study of Romanian reported 49 gastric bezoars cases in 20 years (0.068% from all endoscopies).^[8]

A variety of risk factors such as partial gastrectomy, vagotomy and pyloroplasty, peptic ulcer disease, chronic gastritis, Crohn’s disease, cancers of the gastrointestinal tract, gastroparesis, diabetes mellitus, aging, and dietary habits are associated with increased chance of phytobezoar formation.^[2,9] Our patient just had only one risk factor, i.e., aging. Phytobezoars could lead to ulceration, ileus, bleeding intussusception, obstruction, and perforation.^[3-5,10] GOO, one of the uncommon complications of phytobezoars, presents with nausea and/or vomiting, postprandial fullness, epigastric abdominal pain, weight loss, and anorexia.^[11,12] This patient had nausea, vomiting, and loss of appetite.

We found seven cases that are reported GOO due to phytobezoars; one woman and five men [Table 2].^[9,10,12-16] The most common symptom among these cases was nausea and vomiting, and endoscopy was the main diagnostic and therapeutic modality. In two cases, past gastrojejunostomy procedures were mentioned. For one of these cases, the proposed diagnosis was a stricture at the gastrojejunostomy site, but during laparotomy, obstruction due to bezoars was observed.^[10]

In the case of suspects to diagnose phytobezoars, upper gastrointestinal endoscopy is a method of choice to establish the diagnosis of a gastric bezoar and determine its composition.^[5] In endoscopy, typically, single masses in various colors, related to composition, are directly seen. In patients evaluated by CT scan due to suspicion to obstruction or other indications, round or ovoid mass with air bubbles and a mottled appearance is a mark of bezoars.^[4] In our case, when the patient was admitted, she was carrying a CT scan, which reported suspicion to soft lesion or chronic collection adjacent to the gastric outlet and duodenum. Endoscopic findings in our patient were wrongly considered as food remnants in the result of GOO. However, those findings were the cause of GOO. Therefore, definite diagnosis was not made and the patient was undergone exploratory laparotomy.

Treatment of phytobezoars is categorized into four types, including chemical dissolution, endoscopic removal, adjuvant prokinetics, and surgery.^[4,17] The first-line treatment is making use of chemical dissolvent, for example, cola, unless the phytobezoar is large. The amount of cola that affects phytobezoars is at least 3 liters consumed by patient to patient, the treatment may fail. The next choice to remove phytobezoars is endoscopic removal. In this method, initially, phytobezoars are fragmented into smaller parts using water jet, direct suction through a large channel endoscope, forceps, or snares. These small parts could then be removed through endoscopic, large-bore nasogastric tube or passed through the gastrointestinal tract. Finally, if the above treatments are inefficient, then laparoscopic

or laparotomy surgery is recommended. In our case, the diagnosis was not made till exploratory laparotomy surgery; thus, our removal method was immediately done after diagnosis through laparotomy surgery. Old age, high pulmonary artery pressure, and cardiac problems (ischemic changes) were the risk factors for surgery and were important factors in patient death.

CONCLUSION

Phytobezoar-induced GOO is rare;^[12] therefore, its diagnosis is still a challenge. Following suspicion to phytobezoars, endoscopic investigation and CT scan are the methods of choice to diagnose. Phytobezoars removal is done by chemical dissolvent, adjuvant prokinetics, endoscopic devices, or surgery. Phytobezoars is a curable condition, but late diagnosis or misdiagnosis could lead to significant morbidity or mortality. Physicians are advised to put bezoars in their differential diagnosis list if CT scan report soft tissue lesion adjacent to stomach or bowel.

Consent

Written informed consent was obtained from the patient for publication of this case report and any accompanying images.

Declaration of patient consent

The authors certify that they have obtained all appropriate patient consent forms. In the form, the patient has given her consent for her images and other clinical information to be reported in the journal. The patient understand that name and initials will not be published and due efforts will be made to conceal identity, but anonymity cannot be guaranteed.

Financial support and sponsorship

Nil.

Conflicts of interest

There are no conflicts of interest.

REFERENCES

1. Ben-Porat T, Sherf Dagan S, Goldenshluger A, Yuval JB, Elazary R. Gastrointestinal phytobezoar following bariatric surgery: Systematic review. *Surg Obes Relat Dis* 2016;12:1747-54.

2. Iwamuro M, Tanaka S, Shiode J, Imagawa A, Mizuno M, Fujiki S, *et al.* Clinical characteristics and treatment outcomes of nineteen Japanese patients with gastrointestinal bezoars. *Intern Med* 2014;53:1099-105.
3. Paschos KA, Chatzigeorgiadis A. Pathophysiological and clinical aspects of the diagnosis and treatment of bezoars. *Ann Gastroenterol* 2019;32:224-32.
4. Iwamuro M, Okada H, Matsueda K, Inaba T, Kusumoto C, Imagawa A, *et al.* Review of the diagnosis and management of gastrointestinal bezoars. *World J Gastrointest Endosc* 2015;7:336-45.
5. Eng K, Kay M. Gastrointestinal bezoars: History and current treatment paradigms. *Gastroenterol Hepatol (N Y)* 2012;8:776-8.
6. Decreased G. Definition and classification of CKD. *Kidney Int* 2013;3:19-62.
7. Sharma D, Srivastava M, Babu R, Anand R, Rohtagi A, Thomas S, *et al.* Laparoscopic treatment of gastric bezoar. *JLS* 2010;14:263-7.
8. Mihai C, Mihai B, Drug V, Cijevschi Prelipcean C. Gastric bezoars-diagnostic and therapeutic challenges. *J Gastrointest Liver Dis* 2013;22:111.
9. Tan F, Mo H, He X, Pei H. An unusual case of gastric outlet obstruction caused by multiple giant persimmon phytobezoars. *Gastroenterol Rep (Oxf)* 2019;7:74-6.
10. Leung E, Barnes R, Wong L. Bezoar in gastro-jejunostomy presenting with symptoms of gastric outlet obstruction: A case report and review of the literature. *J Med Case Rep* 2008;2:323.
11. McCarty TR, Garg R, Thompson CC, Rustagi T. Efficacy and safety of EUS-guided gastroenterostomy for benign and malignant gastric outlet obstruction: A systematic review and meta-analysis. *Endosc Int Open* 2019;7:E1474-82.
12. Zin T, Maw M, Pai DR, Paijan RB, Kyi M. Efferent limb of gastrojejunostomy obstruction by a whole okra phytobezoar: Case report and brief review. *World J Gastrointest Endosc* 2012;4:197-200.
13. Honda H, Ikeya T, Kashiwagi E, Okada S, Fukuda K. Successful emergency endoscopic treatment of gastric outlet obstruction due to gastric bezoar with gastric pneumatosis. *Case Rep Gastroenterol* 2017;11:718-23.
14. Dhakal OP, Dhakal M, Bhandari D. Phytobezoar leading to gastric outlet obstruction in a patient with diabetes. *BMJ Case Rep* 2014;2014:bcr2013200661.
15. Andreadis I, Chrisakopoulos G, Papadaki K, Tzias V. Benign gastric outlet obstruction by a large phytobezoar. *Ann Gastroenterol* 2014;27:89-90.
16. Mahir S, Salih AM, Ahmed OF, Kakamad FH, Salih RQ, Mohammed SH, *et al.* Giant phytobezoar; an unusual cause of gastric outlet obstruction: A case report with literature review. *Int J Surg Case Rep* 2020;67:154-6.
17. Akbulut S, Değer KC, Duman M, Yol S. Gastric bezoars. *Przegląd Gastroenterol* 2016;11:60.