

Received: 2021.04.18

Accepted: 2021.07.28

Available online: 2021.08.03

Published: 2021.09.11

Anal Atresia in a Patient Who Had Undergone Hartmann Procedure

Authors' Contribution:
 Study Design A
 Data Collection B
 Statistical Analysis C
 Data Interpretation D
 Manuscript Preparation E
 Literature Search F
 Funds Collection G

ABCDEF 1 **Hiroyuki Sawada**
 AEF 1 **Kazuhiro Toyota**
 AE 1 **Masahiro Ikeda**
 AE 1 **Keishi Hakoda**
 AE 1 **Ryuichi Hotta**
 AE 1 **Masashi Inoue**
 AE 1 **Ichiro Ohmori**
 AE 1,2 **Tadateru Takahashi**

1 Department of Surgery, National Hospital Organization, Higashihiroshima Medical Center, Hiroshima, Japan
 2 Department of Gastrointestinal and Transplant Surgery, Applied Life Sciences, Institute of Biomedical and Health Sciences, Hiroshima University, Hiroshima, Japan

Corresponding Author: Hiroyuki Sawada, e-mail: dannte5426@yahoo.co.jp

Conflict of interest: None declared

Patient: Female, 84-year-old
Final Diagnosis: Anal atresia
Symptoms: Incomplete evacuation
Medication: —
Clinical Procedure: Surgery
Specialty: Surgery

Objective: Rare disease

Background: Hartmann procedure can be necessary for the treatment of rectal cancer and colonic perforation. The distal diverted intestinal tract is usually disregarded, while the proximal colon is diverted with a stoma. Most of the reported complications related to a diverted intestinal tract following Hartmann procedure include inflammation and intestinal tumors; however, there are only a few reports about postoperative anal complications. Herein, we report a rare case of anal atresia following Hartmann procedure. Anal atresia is generally considered as a congenital malformation; therefore, this was an extremely rare case, as there are no previous reports about anal atresia following Hartmann procedure.

Case Report: An 84-year-old woman presented to our hospital with a persistent feeling of incomplete evacuation. She had undergone Hartmann procedure for diverticular disease of the sigmoid colon, with perforation, 5 years ago and had no major complications after the surgery. She had no history of anal disorders such as hemorrhoids or anal fissures. On examination, her anus was found to be closed by a thin skin, and computed tomography revealed stool retention in the diverted rectum. The anus was surgically opened to remove the stool, after which the feeling of incomplete evacuation resolved with no subsequent recurrence.

Conclusions: This is the first report of anal atresia in a patient following Hartmann procedure. The surgical intervention was effective in resolving the blockage and relieving the patient's feeling of incomplete evacuation.

Keywords: Anal Atresia, Hypospadias, and Penoscrotal Inversion • Colorectal Surgery • Colostomy

Full-text PDF: <https://www.amjcaserep.com/abstract/index/idArt/932764>



847



—



2



14



Background

Hartmann procedure can be used to treat rectal cancer and colonic perforation. The distal diverted intestinal tract is usually disregarded, while the proximal colon is diverted with a stoma. Postoperative risks associated with Hartmann procedure include inflammation and development of tumors in the diverted intestinal tract [1-4].

However, anal atresia has not been previously reported as a complication following Hartmann procedure. Anal atresia is usually accompanied by congenital malformations. Therefore, the occurrence of this complication after surgery is extremely rare. In fact, we could not find any previous case reports of acquired anal atresia. Herein, we report a very rare case of anal atresia following Hartmann procedure.

Case Report

An 84-year-old woman was admitted to our hospital with a persistent feeling of incomplete bowel evacuation. She had undergone Hartmann procedure for perforation of the sigmoid colon caused by a diverticulum at the age of 79 years without any major postoperative complications. After the surgery, there was no defecation or passing of flatus through the anus. She did not receive rectal stump washout. She had no history of

anal disorders such as hemorrhoids or anal fissures. Physical examination revealed that the anus was closed and covered with normal, thin skin. Although labial adhesions were observed, neither the vagina nor the urethra was closed (**Figure 1A**) and the patient had no urinary symptoms. An abdominal computed tomography (CT) scan revealed gas and stool retention in the diverted rectum (**Figure 1B**). We presumed that closure of the anus was the main reason for the feeling of incomplete evacuation, and surgery was considered necessary to open the closed anus. Surgery was performed in the lithotomy position under spinal anesthesia. The skin covering the anus was incised and a probe was inserted. Digital examination of the rectum revealed normal mucosa and the presence of stool, which was extracted (**Figure 2A-2C**). At the end of the surgery, the anus was open and unobstructed (**Figure 2D**). The patient's feeling of incomplete evacuation resolved immediately following the surgery, and there has been no recurrence of the symptoms. Despite labial adhesions, no urinary tract symptoms were observed during follow-up.

Discussion

Hartmann procedure can be performed for rectal cancer and perforation of the colon. About 40% of the patients who undergo Hartmann procedure have a permanent stoma either because of their condition or the progression of the disease

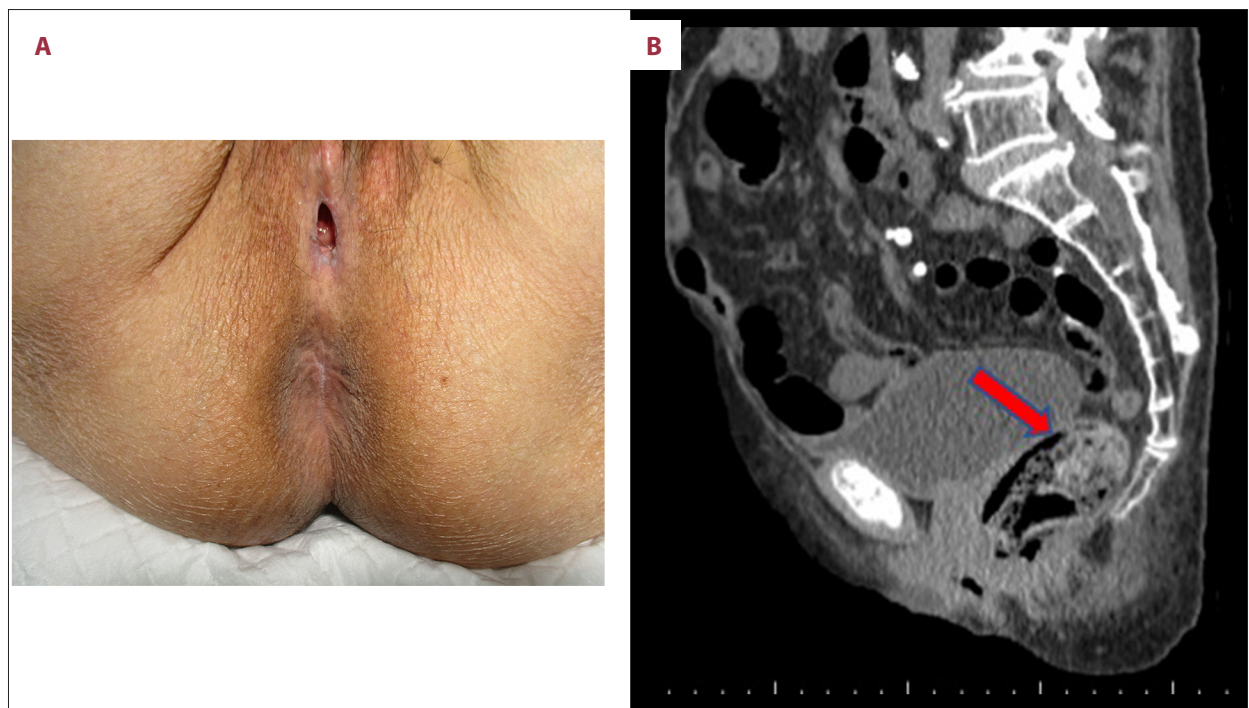


Figure 1. The patient's anus covered with normal skin and fully obstructed. The patient's labia show adhesions. The vagina and external urethral openings are not obstructed (**A**). Sagittal view CT scan with arrow pointing toward the diverted rectum filled with stool and gas (**B**).

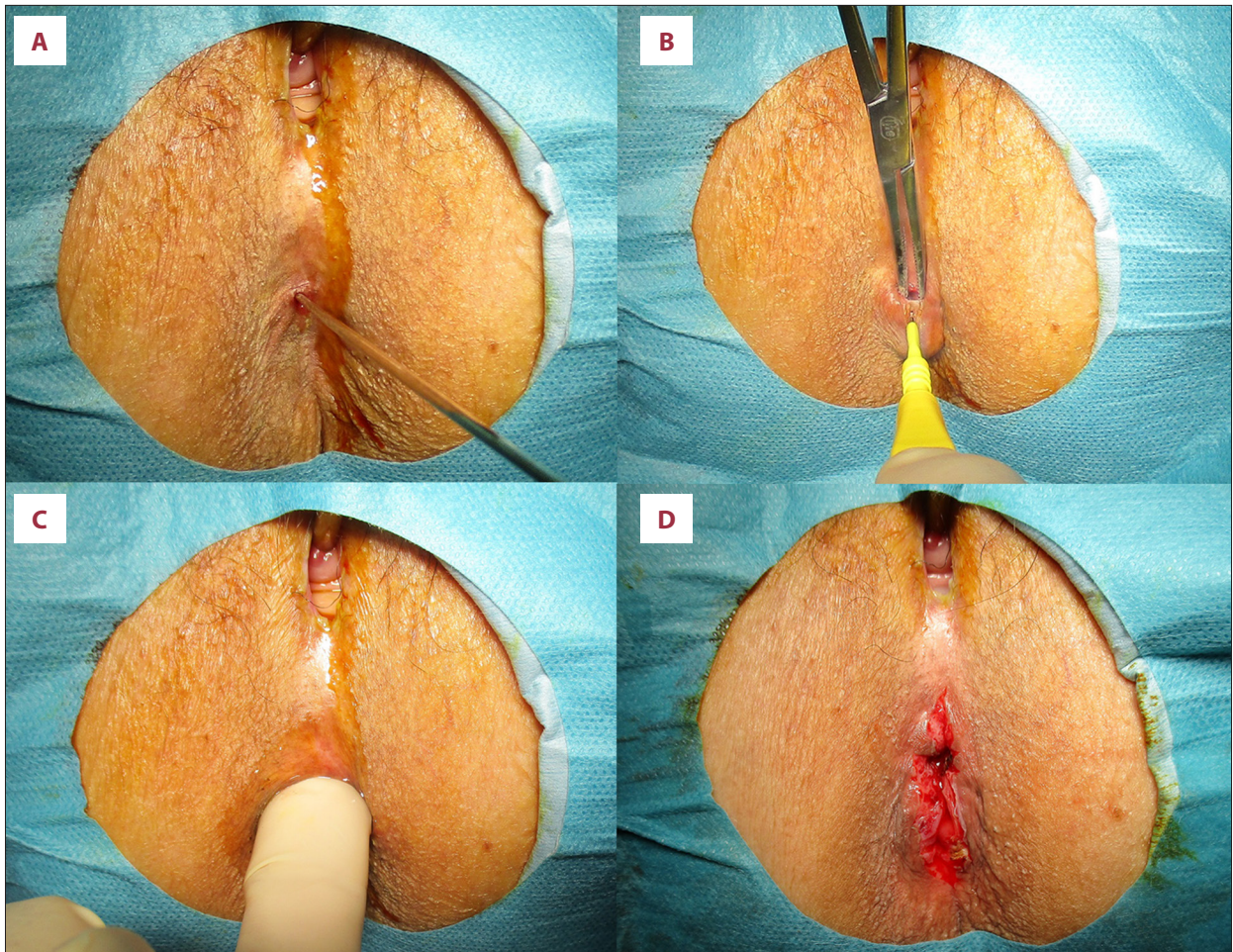


Figure 2. A probe was passed through the anal skin into the rectum (A). An incision was made in the anal skin (B). The index finger was inserted into the anus (C). The anus was confirmed to be unobstructed (D).

or because of the patients' request [5,6]. The distal diverted intestinal tract is usually disregarded, while the proximal colon is diverted with a stoma. Complications like inflammation and tumors of the diverted distal intestinal tract have been reported [1-4]. Diversion colitis, a histological diagnosis supported by endoscopic findings, is one of the relatively common and expected conditions of the diverted distal intestinal tract, and most cases are asymptomatic. It has been postulated that such chronic inflammation might increase the risk of malignancy. Hence, some authors have advocated periodic endoscopic evaluation of the Hartmann's pouch even in asymptomatic patients [3,6-8]. However, there have been no reports of anal atresia following Hartmann procedure. Anal atresia is usually considered as a congenital malformation; therefore, this was an extremely rare case, as there are no previous reports of acquired anal atresia. Cases of labial adhesions have previously been reported [9], which can lead to obstruction of the urethra or vagina and cause dysuria or sexual dysfunction requiring treatment.

Patients with congenital anal atresia have thicker adhesions, and accompanying genitourinary abnormalities are often seen [10]. Non-congenital labial adhesions are usually caused by estrogen deficiency and usually occur in postmenopausal women and infants [11-14]. Chronic inflammation is another cause of labial adhesions, which can cause denudation of the epithelium and subsequent fusion of the labia during healing [8,9]. The labia can be separated by blunt or sharp dissection along the line of fusion under anesthesia to expose the vagina and urethral meatus [10].

In this case, we suspected that the skin of the anus might have contracted and closed the anus because the stoma obstructed the bowel passage to the anus. Moreover, elderly patients with estrogen deficiency and reduced physical function might have difficulty in maintaining perineal hygiene, potentially leading to inflammation-induced labial adhesions, which could have also caused both anal adhesions and atresia. Estrogen ointments are known to prevent the recurrence of labial adhesions [8,9]; hence, they might be effective in preventing anal atresia.

We followed up on this case for 6 only months after the surgery. Insertion of a finger bougie is likely the best treatment if anal constriction recurs; however, if recurrence occurs within a short interval, anoplasty might be necessary. Hence, long-term follow-up is important in this situation.

Conclusions

The patient's feeling of incomplete evacuation resulting from anal atresia led to a reduced quality of life. The patient was immediately relieved of the symptoms after surgical intervention. Therefore, we consider this surgery to be an effective treatment for acquired anal atresia.

References:

1. Nathanson DR, Sheahan M, Chao L, Wallack MK. Intracolonic use of vancomycin for treatment of clostridium difficile colitis in a patient with a diverted colon: Report of a case. *Dis Colon Rectum*. 2001;44(12):1871-72
2. Glotzer DJ, Glick ME, Goldman H. Proctitis and colitis following diversion of the fecal stream. *Gastroenterology*. 1981;80(3):438-41
3. Al Maksoud AM, Ahmed I. Advanced rectal cancer in a long-term Hartmann's pouch: A forgotten organ revisited. *BMJ Case Rep*. 2016;2016:bcr2015213405
4. Lafreniere R, Ketcham AS. Hartmann's pouch carcinoma. *J Surg Oncol*. 1985;29(1):26-27
5. Banerjee S, Leather AJ, Rennie JA, et al. Feasibility and morbidity of reversal of Hartmann's. *Colorectal Dis*. 2005;7(5):454-59
6. Haas PA, Fox TA. The fate of the forgotten rectal pouch after Hartmann's procedure without reconstruction. *Am J Surg*. 1990;159(1):106-10; discussion 110-11
7. Cherukuri R, Levine MS, Maki DD, et al. Hartmann's pouch: Radiographic evaluation of postoperative findings. *Am J Roentgenol*. 1998;171(6):1577-82
8. Weinstein S, Osei-Bonsu S, Aslam R, Yee J. Multidetector CT of the postoperative colon: Review of normal appearances and common complications. *Radiographics*. 2013;33(2):515-32
9. Watanabe T, Matsubara S, Ikeda T, et al. Labial adhesion causing voiding but not sexual problems in a married woman. *J Obstet Gynaecol Res*. 2013;39(1):415-19
10. Kutlu O, Koksall IT. Labial adhesion in a reproductive aged girl. *Saudi Med J*. 2010;31(2):202-3
11. Takemaru M, Aramaki-Hattori N, Tsue C, Kishi K. Labial adhesions causing recurrent urinary-tract infections in an elderly woman. *Case Rep Med*. 2019;2019:7584983
12. Singh P, Han HC. Labial adhesions in postmenopausal women: Presentation and management. *Int Urogynecol J*. 2019;30(9):1429-32
13. Capraro VJ, Greenberg H. Adhesions of the labia minora. A study of 50 patients. *Obstet Gynecol*. 1972;39(1):65-69
14. Webster JJ, Williams G. Adhesions of the labia minora. *Br J Urol*. 1996;78(1):146-47

Conflict of Interests

None declared.

Declaration of Figures Authenticity

All figures submitted have been created by the authors who confirm that the images are original with no duplication and have not been previously published in whole or in part.