

Case Report

# A Complete Response Case in a Patient with Multiple Lung Metastases of Rectal Cancer Treated with Bevacizumab plus XELIRI Therapy

Hiroki Hashida<sup>a</sup> Hironaga Satake<sup>b</sup> Satoshi Kaihara<sup>a</sup>

<sup>a</sup>Department of Surgery, Kobe City Medical Center General Hospital, Kobe, Japan;

<sup>b</sup>Department of Medical Oncology, Kobe City Medical Center General Hospital, Kobe, Japan

## Keywords

Colorectal cancer · Lung metastasis · Chemotherapy · Bevacizumab+XELIRI

## Abstract

It has been reported that many patients with lung metastasis of colorectal cancer (CRC) underwent chemotherapy with fluorouracil, folinic acid, oxaliplatin, irinotecan, or capecitabine. There is a small number of reports about the capecitabine and irinotecan (XELIRI) plus bevacizumab (BV) therapy for patients with metastatic CRC in Japan. We report a case of successful BV+XELIRI therapy for rectal cancer with multiple lung metastases as first-line chemotherapy. A 53-year-old female presented with advanced rectal cancer and metastatic lung tumors. Following surgery, the patient was treated with XELIRI+BV. After 6 courses, a computed tomography scan showed complete response of the lung metastases. No recurrence has occurred for 3 years after chemotherapy was stopped.

© 2017 The Author(s)  
Published by S. Karger AG, Basel

## Introduction

Colon cancer is one of the most common causes of cancer deaths worldwide. In recent years, new regimens for colon cancer combining chemotherapy and biological agents have improved the overall survival and progression-free survival (PFS) [1].

One of them, the combination of bevacizumab and capecitabine plus irinotecan (XELIRI) chemotherapy is feasible despite adverse effects. Moreover, this treatment improved PFS and overall survival in untreated metastatic colorectal cancer (mCRC). Biweekly treatment with XELIRI +bevacizumab (BV) should be considered one of the first-line regimens for mCRC patients [2].

Both the XELIRI and FOLFIRI regimens had a similar efficacy to first-line treatment in patients with mCRC showing similar adverse event profiles. XELIRI+BV has an acceptable tolerability profile and improves the efficacy outcomes compared with XELIRI as a first-line treatment of mCRC [3].

Herein, we present a curative case of XELIRI+BV therapy for multiple lung metastases of rectal cancer.

## Case Presentation

A 53-year-old female presented with advanced rectal cancer and metastatic lung tumors. The advanced rectal tumor was located in the lower rectum. The carcinoembryonic antigen level was 4.0 ng/mL, and CA19-9 was 383.3 U/mL. Lung tumors were confirmed by a computed tomography (CT) scan that showed multiple nodules in both lobes (Fig. 1). Laparoscopic low anterior resection for rectal cancer was performed, and a local rectal tumor was resected completely. The pathologic findings showed that it was a well-differentiated adenocarcinoma. According to the TNM classification, the tumor was T3N1M1 and Stage IV. KRAS codon 12 showed TGT mutation.

After the surgery, the patient was treated with XELIRI+BV on day 1 plus capecitabine twice a day on days 1–14, every 3 weeks (BV: 7.5 mg/m<sup>2</sup>, CPT-11: 200 mg/m<sup>2</sup>, and capecitabine: 1,600 mg/m<sup>2</sup>/day).

After 6 courses, a CT scan showed complete response of the lung metastases (Fig. 2), and the CA19-9 level improved to within normal limits (Fig. 3). Grade 1 hand-foot syndrome occurred as an adverse effect. XELIRI+BV therapy was continued to a total of 8 courses. Then, the chemotherapy was stopped on request of the patient. No recurrence has occurred for 3 years after chemotherapy was stopped.

## Discussion

Several reports show that chemotherapy for mCRC improved in the last decade. Patients receiving FOLFIRI treatment showed a longer PFS than those with XELIRI in the BICC trial [4]. On the other hand, the median PFS was 9.0 months with FOLFIRI+BV and 9.3 months with XELIRI+BV [3]. Similar results were found in a phase III trial [5]. This report suggests that XELIRI+BV is more effective than FOLFIRI+BV.

As chemotherapy for CRC with liver metastasis leads to tumor reduction and a safe margin of the liver tumor, radical resection can often be performed [2].

However, chemotherapy for unresectable multiple lung metastases is often difficult. The oxaliplatin resistance rate is approximately 20% in all colon cancer cases [6]. Therefore, irinotecan-based chemotherapy was selected in the present case with the aim of prolonging survival. The XELIRI+BV regimen led to complete response in our patient with multiple lung metastases.

### Conclusion

Herein, we reported a case of successful chemotherapy with XELIRI+BV for CRC with multiple lung metastases and its complete response.

### Statement of Ethics

Written informed consent for the publication of this paper was obtained from the patient.

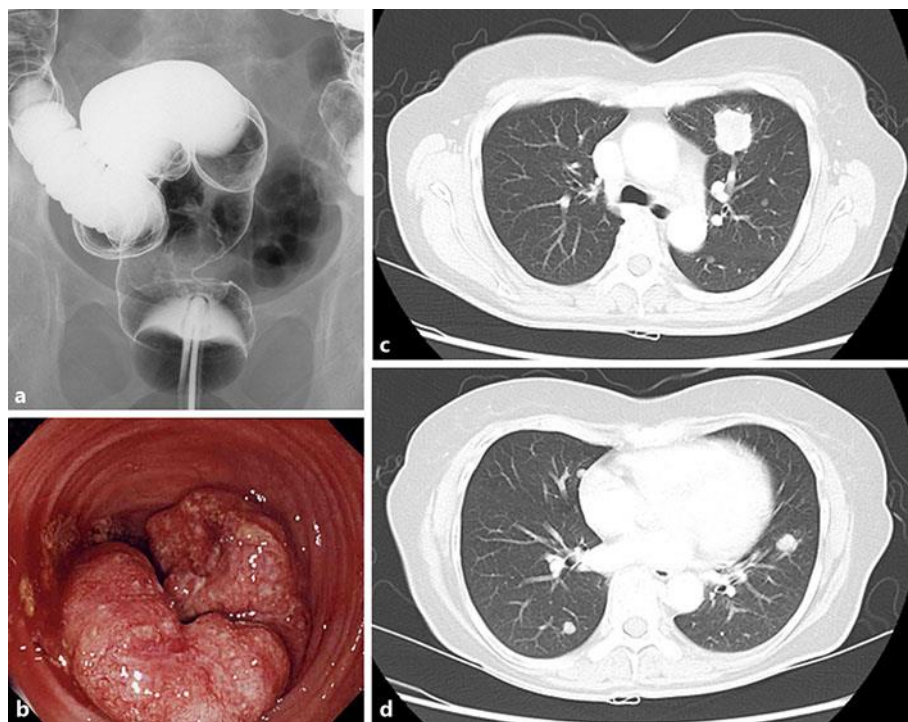
### Disclosure Statement

The authors declare that they have no conflicts of interest to disclose.

### References

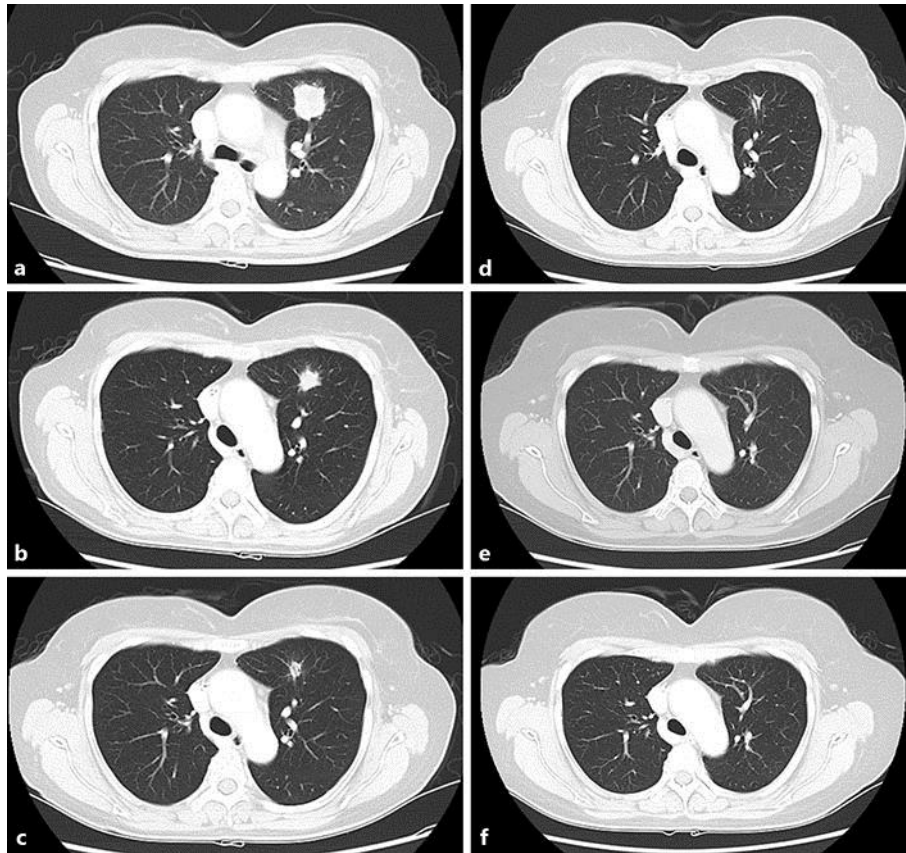
- 1 Van Cutsem E, Cervantes A, Adam R, et al: ESMO consensus guidelines for the management of patients with metastatic colorectal cancer. *Ann Oncol* 2016;27:1386–1422.
- 2 Adam R, Wicherts DA, de Haas RJ, et al: Patients with initially unresectable colorectal liver metastases: is there a possibility of cure? *J Clin Oncol* 2009;27:1829–1835.
- 3 Ducreux M, Adenis A, Pignon JP, et al: Efficacy and safety of bevacizumab-based combination regimens in patients with previously untreated metastatic colorectal cancer: final results from a randomised phase II study of bevacizumab plus 5-fluorouracil, leucovorin plus irinotecan versus bevacizumab plus capecitabine plus irinotecan (FNCLCC ACCORD 13/0503 study). *Eur J Cancer* 2013;49:1236–1245.
- 4 Fuchs CS, Marshall J, Mitchell E, et al: Randomized, controlled trial of irinotecan plus infusional, bolus, or oral fluoropyrimidines in first-line treatment of metastatic colorectal cancer: results from the BICC-C Study. *J Clin Oncol* 2007;25:4779–4786.
- 5 Pectasides D, Papaxoinis G, Kalogeras KT, et al: XELIRI-bevacizumab versus FOLFIRI-bevacizumab as first-line treatment in patients with metastatic colorectal cancer: a Hellenic Cooperative Oncology Group phase III trial with collateral biomarker analysis. *BMC Cancer* 2012;12:271.
- 6 Yoshida Y, Hasegawa J, Nezu R, et al: Clinical usefulness of mitochondrial transcription factor a expression as a predictive marker in colorectal cancer patients treated with FOLFOX. *Cancer Sci* 2011;102:578–582.

Hashida et al.: A Complete Response Case in a Patient with Multiple Lung Metastases of Rectal Cancer Treated with Bevacizumab plus XELIRI Therapy

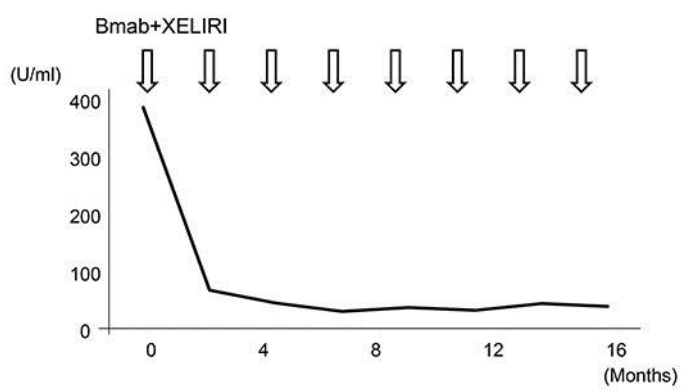


**Fig. 1.** **a** Barium enema revealing a rectal tumor. **b** Colonoscopy showing advanced rectal cancer. **c, d** CT scans revealing multiple lung tumors.

Hashida et al.: A Complete Response Case in a Patient with Multiple Lung Metastases of Rectal Cancer Treated with Bevacizumab plus XELIRI Therapy



**Fig. 2.** CT scans showing complete response after chemotherapy. **a–f** Size reduction of the lung tumors in 2-month steps.



**Fig. 3.** Serum CA19-9 level improved to within normal limits after chemotherapy.