

# Recurrent Kaposi sarcoma associated with Koebner phenomenon in two HIV-seronegative patients

## Two case reports and a review of the literature

Dario Marino, MD, PhD<sup>a</sup>, Fiorella Calabrese, MD<sup>b</sup>, Giancarlo Ottaviano, MD<sup>c</sup>, Fabio Biagio La Torre, MD<sup>c</sup>, Mattia Vicario, PhD<sup>d</sup>, Mauro Alaibac, MD, PhD<sup>e,\*</sup>, Maria Luisa Calabrò, BScD<sup>d</sup>

### Abstract

**Rationale:** Koebner phenomenon is occasionally reported in patients affected by classic Kaposi sarcoma (KS).

**Patient concerns:** Here, we report 2 cases of KS associated with Koebner phenomenon and the correlation of human herpesvirus 8 molecular analysis with the clinical outcome.

**Interventions:** In the first case, a patient with a history of sporadic cutaneous KS developed a recurrent lesion at the laryngeal tract, the site of a previous nodulectomy. In our second case, immunodeficiency induced by chemotherapy triggered the development of KS and Koebner phenomenon was limited to the skin at the site of safenectomy.

**Lessons:** Our observations suggest that careful planning of surgical treatment is required in immunocompetent and immunocompromised patients with a medical history of KS. Moreover, mucosal sites (both respiratory and in the gastrointestinal tract) should be considered as potential sites for KS development.

**Abbreviations:** AIDS = acquired immunodeficiency syndrome, CT = computerized tomography, GE = genome equivalents, HAART = highly active antiretroviral therapy, HBV = hepatitis B virus, HIV = human immunodeficiency virus, KS = Kaposi sarcoma, PBMC = peripheral blood mononuclear cells.

**Keywords:** Kaposi sarcoma, Koebner phenomenon

## 1. Introduction

Kaposi sarcoma (KS) is a rare malignancy derived from vasoformative mesenchyme, characterized by single or simultaneous multiple inflammatory angiogenic lesions with predominant involvement of the skin. It may be cutaneous or mucosal, nodal, or visceral and is often associated with immunosuppression, such as following infection with *human immunodeficiency virus* (HIV) or immunosuppressive treatment after organ transplantation. Before the acquired immunodeficiency syn-

drome (AIDS) epidemic, KS was a relatively rare neoplasm affecting elderly men in certain Mediterranean countries (classic/Mediterranean form), adults and children in sub-Saharan Africa (endemic/African form), and transplant recipients undergoing immunosuppressive therapy (post-transplant/iatrogenic form). In the early 1980s, KS was detected in people infected with HIV-1 and, prior to the introduction of highly active antiretroviral therapy, it became one of the most frequent malignancies in AIDS patients (epidemic/AIDS-associated form).<sup>[1]</sup> Human herpesvirus 8 (HHV8) is implicated in the etiopathogenesis of KS. The virus is present in virtually all cases of KS, although not all infected individuals develop KS.<sup>[2]</sup> Nowadays, KS diagnosis in bioptic lesion specimens usually requires not only histological and immunohistochemical characterization but also HHV8 detection using molecular biology techniques. Thus, surgical biopsy is highly recommended to provide sufficiently large samples to allow for adequate morphological and molecular investigations. Moreover, detection and measurement of HHV8-specific antibodies and DNA sequences through serological and molecular assays performed in blood samples and other biological fluids may further delineate the virological status (latent versus active infection) of patients.<sup>[2]</sup>

KS tumors often progress soon after a systemic inflammatory condition, and KS lesions may arise precisely at sites of previous local injury, such as surgical or traumatic wounds, a characteristic known as the Koebner phenomenon. Indeed, the tissue repair process can recruit circulating HHV8-infected endothelial precursors and promote spindle cell proliferation. Different skin diseases present this complication, notably psoriasis, lichen planus, cutaneous sarcoidosis, vitiligo, lupus erythematosus, and viral warts, although its etiopathogenesis is not fully under-

Editor: N/A.

Patient consent was not obtained as patient's anonymity was maintained in both written text and photographs.

The authors have no conflicts of interest to disclose.

<sup>a</sup> Department of Clinical and Experimental Oncology, Veneto Institute of Oncology, IOV IRCCS, <sup>b</sup> Department of Cardiac, Thoracic and Vascular Sciences, Section of Pathology, <sup>c</sup> Department of Neurosciences, Otolaryngology Section, University of Padua, <sup>d</sup> Immunology and Molecular Oncology, Veneto Institute of Oncology, IOV IRCCS, <sup>e</sup> Dermatology Unit, Department of Medicine, University of Padua, Padua, Italy.

\* Correspondence: Mauro Alaibac, Dermatology Unit, Department of Medicine, University of Padua, Via Gallucci 4, 35128, Padua, Italy (e-mail: mauro.alaibac@unipd.it).

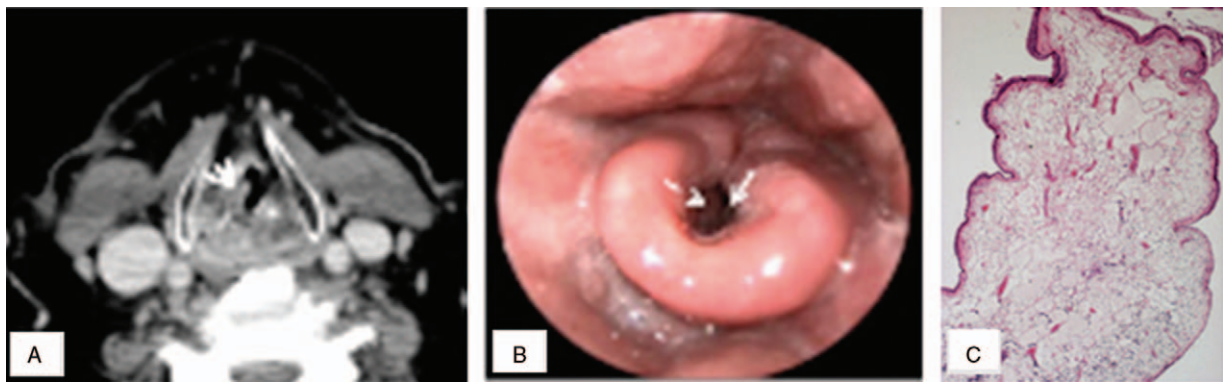
Copyright © 2017 the Author(s). Published by Wolters Kluwer Health, Inc. This is an open access article distributed under the Creative Commons Attribution-NoDerivatives License 4.0, which allows for redistribution, commercial and non-commercial, as long as it is passed along unchanged and in whole, with credit to the author.

Medicine (2017) 96:52(e9467)

Received: 13 November 2017 / Received in final form: 4 December 2017 /

Accepted: 6 December 2017

<http://dx.doi.org/10.1097/MD.0000000000009467>

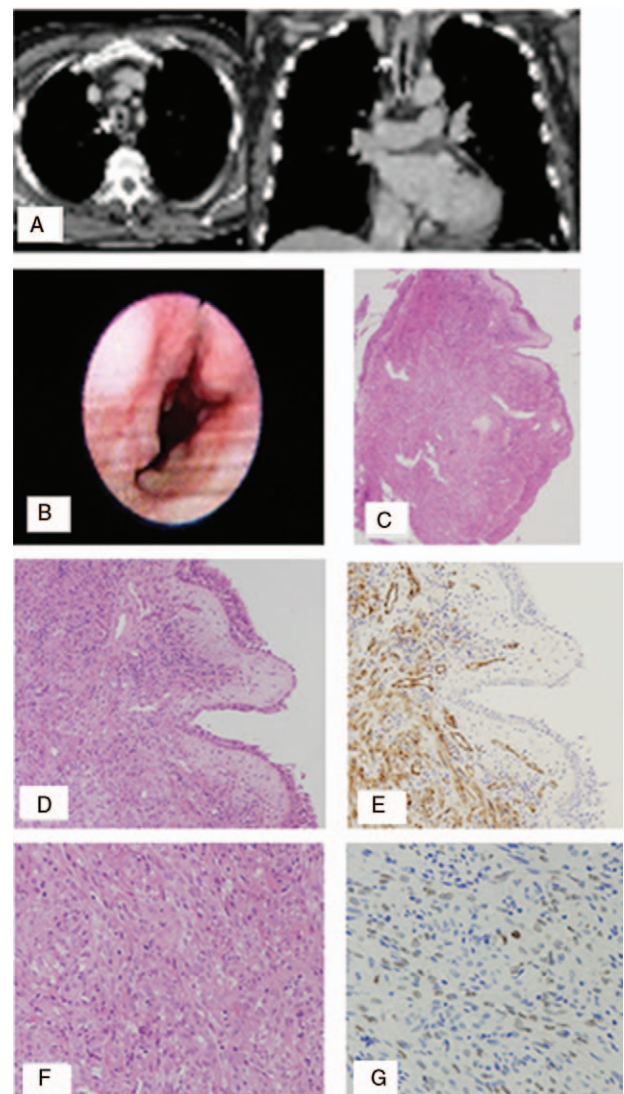


**Figure 1.** Computed tomography image (A), microlaryngoscopy showing thickening and hyperdensity (arrows) of the laryngeal vestibule and the right vocal cord (B), and hematoxylin and eosin (HE) staining of the laryngeal polyp showing thin-walled dilated vessels and fibrinous exudates in edematous mucosa (C). HE= hematoxylin and eosin.

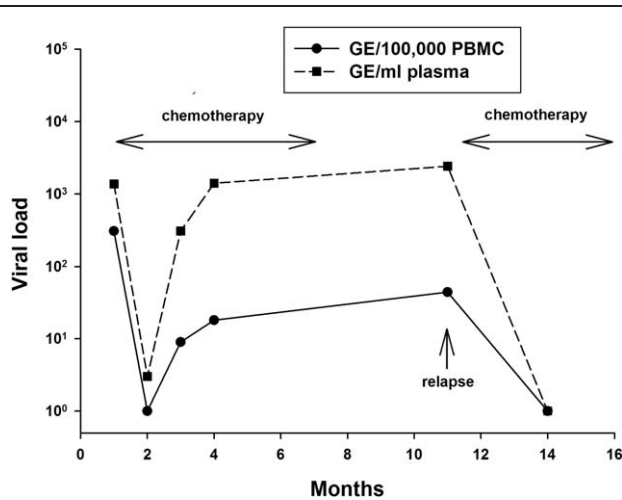
stood.<sup>[3]</sup> In this article, we report 2 cases of Koebner phenomenon associated with KS and review the literature concerning this complication in KS patients.

## 2. Case 1

In 2005, a 61-year-old HIV-negative man who is a hepatitis B virus (HBV) occult carrier developed bilateral lesions on the legs. KS was histologically/immunohistochemically proven and clinical and instrumental examinations confirmed a stage IA cutaneous involvement. The disease remained localized in the lower limbs for almost 5 years and no therapy was administered. In 2010, the patient developed hoarseness, dry cough, and dyspnea due to a right true vocal fold swelling associated with a reduced right vocal fold motility and with a significant reduction of the respiratory glottis space (Fig. 1B). After a contrast-enhanced computerized tomography (CT) scan of the neck showed a thickening hyperdensity of the laryngeal vestibule and the right vocal fold (Fig. 1A), the lesion was biopsied under microlaryngoscopy control. The final histological diagnosis was consistent with laryngeal polyp (Fig. 1C). Given the reduced glottis lumen, a temporary tracheostomy was also performed. During the following year, the patient underwent 2 CO<sub>2</sub> laser-assisted excisions of the laryngeal lesions and treatment with high-dose corticosteroids. Fifteen months later the patient progressively developed a granulomatous tissue involving large areas of the tracheal tract (Fig. 2A and B); high-dose corticosteroids were administered and a debulking of the mass under rigid tracheoscopy control was performed. Histological investigation of the granulomatous tissue revealed the presence of KS and HHV8 was detected by immunohistochemistry (Fig. 2C–G). The life-threatening site of the disease required antitubercular treatment using chemotherapy according to ABV schedule (Adriamycin, 10 mg/m<sup>2</sup>, Bleomycin, 15 UI; and Vincristine, 1 mg; every 2 weeks for 12 cycles). Antiviral prophylaxis with lamivudine and valacyclovir was also administered due the status of occult HBV carrier and the elevated risk of opportunistic herpesvirus infection. Complete remission was achieved. HHV8 molecular analysis was performed before treatment and a high viral load was detected, with a cell-associated burden of 308 genome equivalents (GE) per 100,000 cells and a cell-free plasmatic load of 1370 GE/mL (Fig. 3). HHV8 load decreased initially during chemotherapy and antiviral prophylaxis, but subsequently increased progressively suggesting a reactivation of the lytic



**Figure 2.** Computed tomography image (A), microlaryngoscopy showing granulomatous tissue involving large areas of trachea (B). Polypoid granulomatous tissue (HE) (C). Abundant vascular spaces associated with inflammatory cells and numerous spindle cells (HE) (D). Positive CD31 immunohistochemistry (E). Atypical endothelial proliferation (F). Many nuclei immunoreactive for HHV8 (G). HE= hematoxylin and eosin.



**Figure 3.** Trend of HHV8 load in the peripheral blood compartment (case 1). HHV8 load in peripheral blood mononuclear cells (PBMC) and in plasma specimens is expressed in genome equivalents (GE). Four months after the end of chemotherapy, the patient presented with aggressive KS relapse (arrow), characterized by high plasmatic HHV8 load, extended cutaneous involvement and a new KS lesion at the site of tracheostomy. HHV8 = human herpesvirus 8, KS = Kaposi sarcoma, PBMC = peripheral blood mononuclear cells.

cycle. Indeed, high plasmatic HHV8 viremia (1411 GE/mL) was measured 3 months after the end of treatment (Fig. 3). One month later, a new lesion was documented at the site of the tracheostomy and recurrent KS was confirmed histologically. In this setting, plasmatic HHV8 load was high (2422 GE/mL) indicating persistent viral replication. The patient was admitted to our hospital due to progressive dyspnea. Chest x-ray and echocardiography revealed a pleuro-pericardial effusion. Pericardiocentesis was performed with blood-serum fluid drainage and a cytological examination revealed the presence of malignant mesenchymal cells. Cell-free and cell-associated virus was also detected in the pericardial fraction (3511 GE/mL and 9 GE/100,000 cells) suggesting that viral replication also occurred in the pericardial cavity (Fig. 3). Cytofluorimetric analysis was negative for clonal B lymphocytes excluding the development of a primary effusion lymphoma. At this stage, KS was extensively disseminated as the patient presented with papular red lesions on the legs, limbs, and trunk. Intrapericardial bleomycin chemotherapy (15 IU) was administered without adverse events. Second-line chemotherapy with paclitaxel (100 mg/m<sup>2</sup> every 2 weeks) was started. The patient received 16 bi-weekly paclitaxel doses achieving complete disappearance of cutaneous lesions and involvement of pericardial fluid. Viral load measurement after 8 cycles of chemotherapy showed an undetectable HHV8 load in the peripheral compartment (Fig. 3). The chemotherapy was stopped due to peripheral G3 neuropathy. Two years after the end of chemotherapy the patient presented in good clinical condition and in complete remission with no evidence of cutaneous lesions or pericardial effusion. A recent total body CT scan was negative for KS involvement and the tracheostomy was removed (data not shown).

### 3. Case 2

A 65-year-old man with a pT3pN1M0 colorectal carcinoma was treated with radical colectomy followed by adjuvant chemotherapy according to FOLFOX4 regimen for 12 cycles. Six months

after the end of chemotherapy he developed a cutaneous papular red nodule on the left leg and scrotum, with bilateral inguinal lymphadenopathy. He underwent surgical excision and the histological diagnosis was consistent with nodular KS; immunohistochemical analyses showed strong and specific reactivity for CD34, HHV8, S100, and factor VIII. The patient was HIV-negative and HHV8 molecular analysis revealed high circulating viremia (plasmatic 3154 GE/mL and 93 GE/100,000 cells in peripheral blood mononuclear cells [PBMC]). The patient was in complete remission until May 2010 when he developed new nodular lesions at the site of the scar of a safenectomy performed 2 months before. Histological diagnosis after surgical excision confirmed the diagnosis of KS. At this time, HHV8 viral load decreased to 22 genomic copies/100,000 PBMC and undetectable plasma levels, in the absence of therapy. At present, the patient is in complete remission.

### 4. Discussion

Since 1987, only 12 cases of KS occurring as Koebner phenomenon were reported in the literature: 5 cases occurred in transplant recipients,<sup>[4-8]</sup> 4 in HIV-positive patients,<sup>[9-12]</sup> and only 3 in classic KS.<sup>[13-15]</sup> The typical site of Koebner phenomenon is the skin, but Sachsenberg-Studer et al<sup>[6]</sup> described a KS of the skin and of a lung graft localized to sites of a previous trauma, suggesting that not only immunodeficiency but also trauma and physical stimuli may lead to the development of KS as Koebner phenomenon.

The Koebner phenomenon, one of the most well-known entities in dermatology, has been documented in several skin diseases, including psoriasis, vitiligo, lichen planus, and viral warts.<sup>[3]</sup> In susceptible individuals, koebnerization can be induced by a variety of triggers, all of which cause predominantly epidermal cell injury or inflammation. Numerous factors are known to trigger Koebner phenomenon, including trauma, animal or insect bites, burns, needle scarification, pressure, skin grafts, surgical incision, allergic and drug reactions, vaccinations, tattoos, and various dermatoses. In addition, both epidermal cell injury and inflammation of the papillary dermis are necessary for the induction of Koebner phenomenon.

The development of KS associated with Koebner phenomenon represents an example of inflammatory oncotaxis. Basic fibroblast growth factor released from traumatized keratinocytes may also play a role in the pathogenesis of KS. During inflammatory reactions, other angiogenic cytokines, such as interleukin-1 and -6, tumor necrosis factor- $\alpha$ , vascular endothelial growth factor, platelet-derived growth factor, and granulocyte colony-stimulating factor, may also play a part in koebnerization along with an increased expression of cell-adhesion molecules.

In the first case, a patient with a history of sporadic cutaneous KS developed a recurrent lesion at the laryngeal tract, the site of a previous nodulectomy. To the best of our knowledge, this is the first case described in the literature of Koebner phenomenon with mucosal involvement. Laryngeal biopsies and high-dose corticosteroids could have caused a rapid and exuberant KS recurrence requiring tracheostomy followed by chemotherapy due to visceral involvement.

In our second case, there was a temporal correlation between the cytotoxic treatment for colorectal cancer and development of KS as well as between scar formation and disease relapse after four years of indolent natural history. In this patient, immunodeficiency induced by chemotherapy triggered the



development of KS, and the Koebner phenomenon was limited to the skin at the site of the safenectomy. The patient did not require any specific oncologic treatment as the lesion was limited to the skin without visceral involvement.

In conclusion, our observations suggest that careful planning of surgical treatment is required in immunocompetent and immunocompromised patients with a medical history of KS. Moreover, mucosal sites (both respiratory and in the gastrointestinal tract) should be considered as potential sites for KS development.

### Acknowledgments

We thank Christina Drace for help in preparing the manuscript. This study was supported by 5X1000-IOV2010 (fellowship to MV).

### References

- [1] Jakob L, Metzler G, Chen K, et al. Non-AIDS associated Kaposi's sarcoma: clinical features and treatment outcome. *PLoS One* 2011;12: e18397.
- [2] Sarid R, Calabrò ML. Kaposi's sarcoma-associated herpesvirus: Epidemiology, Biological Characteristics and Pathogenesis. In: Kaslow RA, Stanberry LR, LeDuc JW, eds. *Viral Infections of Humans: Epidemiology and Control* 5th ed. New York, NY: Springer, 2014;897–931.
- [3] Sagi L, Trau H. The Koebner phenomenon. *Clin Dermatol* 2011;29:231–6.
- [4] Micali G, Gasparri O, Nasca MR, et al. Kaposi sarcoma occurring de novo in the surgical scar in a heart transplant recipient. *J Am Acad Dermatol* 1992;27:273–4.
- [5] Seçkin D, Ozcan G, Demirağ A, et al. The Koebner phenomenon in Kaposi sarcoma in a renal transplant recipient. *Br J Dermatol* 1998;139:346–8.
- [6] Sachsenberg-Studer EM, Dobrinski N, Sheldon J, et al. Human herpesvirus 8 seropositive patient with skin and graft Kaposi's sarcoma after lung transplantation. *J Am Acad Dermatol* 1999;40:308–11.
- [7] Maral T. The Koebner phenomenon in immunosuppression-related Kaposi sarcoma. *Ann Plast Surg* 2000;44:646–8.
- [8] Stoebner PE, Fabre C, Kabbaj NEL, et al. Koebnerizing Kaposi sarcoma mimics a laparotomic hypertrophic scar in a liver transplant recipient. *Liver Transpl* 2009;15:994–6.
- [9] Niedt GW, Prioleau PG. Kaposi sarcoma occurring in a dermatome previously involved by herpes zoster. *J Am Acad Dermatol* 1988;18:448–51.
- [10] Plettenberg A, Engelmann L, Meigel W. Pathogenesis of HIV-associated Kaposi sarcoma—the Koebner phenomenon as a possible pathogenetic mechanism. *Z Hautkr* 1990;65:684–6.
- [11] Janier M, Morel P, Civatte J. The Koebner phenomenon in AIDS-related Kaposi sarcoma. *J Am Acad Dermatol* 1990;22:125–6.
- [12] French PD, Harris JRW, Mercey DE. The Koebner phenomenon and AIDS-related Kaposi sarcoma. *Br J Dermatol* 1994;131:746–7.
- [13] Webster-Cyriaque J. Development of Kaposi's sarcoma in a surgical wound. *N Engl J Med* 2002;346:1207–10.
- [14] Brambilla L, Boneschi V, Fossati S, et al. Recurrence of Kaposi's sarcoma at the site of a graft for radiodermatitis ulcer. *G Ital Dermatol Venereol* 1987;122:655–7.
- [15] Potouridou I, Katsambas A, Pantazi V, et al. Koebner phenomenon in classic Kaposi's sarcoma. *Acta Derm Venereol* 1997;77:481.