

Treatment of Acute Psychosis Caused by Isotretinoin: Systematic Review

Tijana Stanojkovic^{1,2}, Radica Zivkovic Zaric¹, Ivana Lesnjak^{1,3}, Milan Gajic^{1,4}, Srecko Markovic^{1,5}, Aleksandar Canovic^{1,6}, Katarina Jankovic Jovanovic^{1,3}

¹Department of Pharmacology and Toxicology, University of Kragujevac, Faculty of Medical Sciences, Kragujevac, Serbia; ²Medical Military Academy, Belgrade, Serbia; ³Clinical Center Kragujevac, Kragujevac, Serbia; ⁴General Hospital Pancevo, Pancevo, Serbia; ⁵Institute for Cardiovascular Diseases Dedinje, Belgrade, Serbia; ⁶Clinical Center Pristina-Gracanica, Serbia

ABSTRACT

Background: Isotretinoin is an oral medicine prescribed for the management of severe acne that is insensitive to conventional therapy, including systemic antibiotics. Acute psychosis refers to a severe mental illness characterized by a loss of touch with realism, visions, delusions, confused thinking, and abnormal behaviors. The study aims to analyze and document these cases to better understand the potential relationship between isotretinoin use and the development of acute psychosis, as well as to find out which therapy is best for treating this problem.

Methods: We searched the following electronic databases independently with no linguistic or date limit: PubMed/MEDLINE, Scopus, Web of Science, Google Scholar, and Serbian Citation Index (SCIndeks).

Results: Our results included 14 studies (13 case reports and 1 cohort study) with 18 individual cases. The oldest patient was 27 years old, and the youngest was 13 years old. Both genders were represented with 9 individuals each.

Conclusion: We can conclude that, in addition to discontinuation of isotretinoin, therapy with olanzapine and eventually risperidone could improve the symptoms of psychosis caused by isotretinoin.

ARTICLE HISTORY

Received: October 04, 2023

Revision Requested:
December 10, 2023

Last Revision Received:
December 28, 2024

Accepted: January 15, 2024
Publication Date: May 08, 2024

INTRODUCTION

Isotretinoin is an oral medicine prescribed for the management of severe acne that is indifferent to conventional treatment, together with systemic antibiotics. This type of acne is characterized by its severity, resistance to standard treatments, and the presence of nodules, which are large, painful, and deep-rooted lesions.^{1,2,3} Adverse effects linked with isotretinoin usage include cheilitis, or dry lips, which occurs in approximately 90% of patients taking the medication. Along with dry lips, individuals may also experience dry skin (xerosis), dry mouth (xerostomia), dry nose, and heightened sensitivity to sunlight. Hypertriglyceridemia and elevated erythrocyte sedimentation rate are other side effects observed during isotretinoin therapy, necessitating laboratory checking throughout the treatment duration. Additional possible adverse effects include itching (pruritis), irritation, hair weakening, skin delicacy, dehydrated eyes, skin infections, rash, bone or joint discomfort, muscle aches, etc. Isotretinoin may also cause certain laboratory abnormalities such as reduced high-density lipoproteins, enlarged liver function exams, elevated creatinine phosphokinase, decreased levels of hemoglobin and

hematocrit, reduced erythrocyte and leukocyte counts, and elevated platelet counts. If the rare occurrence of neutropenia or agranulocytosis arises, isotretinoin should be dropped.^{4,5} The US Food and Drug Administration (FDA) approved isotretinoin in 1982.⁶

Isotretinoin is among the top 10 drugs associated with a high number of reported cases of depression and suicide attempts. Between 1982 and 2000, there were 37 documented cases of suicide among patients using isotretinoin, and an additional 110 patients required hospitalization for the treatment of depression.⁷ The most frequently observed psychiatric side effect has been depression, but there have also been occasional proven cases of psychosis associated with isotretinoin use.⁸

Acute psychosis (AP) refers to a serious mental illness characterized by a loss of touch with reality, hallucinations, misbeliefs, disorganized thinking, and abnormal behaviors. It is important to note that the occurrence of acute psychosis with isotretinoin use is rare. The majority of patients who take isotretinoin do not experience any psychiatric issues.⁵

Corresponding author: Radica Zivkovic Zaric, e-mail: radica_zivkovic@yahoo.com

Cite this article as: Stanojkovic T, Zivkovic Zaric R, Lesnjak I, et al. Treatment of acute psychosis caused by isotretinoin: Systematic review. *Psychiatry Clin Psychopharmacol.* 2024;34(2):103-108.



Content of this journal is licensed under a Creative Commons Attribution-NonCommercial 4.0 International License.

While the precise mechanism of how isotretinoin works remains unclear, research conducted using animal models (in vivo) has revealed significant levels of retinoid receptors and cellular binding proteins in areas of the brain associated with dopamine pathways, notably the striatum. This observation suggests a potential link between these molecular components and their potential role in the development of various psychiatric disorders.⁹ Depression resulting from isotretinoin usage may be attributed to factors such as reduced neurogenesis (the formation of new nerve cells) and disrupted serotonin signaling within the brain. However, when it comes to the origins of psychosis induced by isotretinoin, our understanding is limited, and no established hypotheses currently exist to explain this phenomenon.¹⁰

This scientific work aims to present a series of cases of patients who underwent isotretinoin treatment and experienced acute psychosis as an adverse reaction. The study aims to analyze and document these cases to better understand the potential relationship between isotretinoin use and the development of acute psychosis, as well as to find out which therapy is best for treating this problem.

MATERIAL AND METHODS

The International Prospective Register of Systematic Reviews registered our review with number CRD42023427092.

Three authors (KJJ, TS, and ILj) searched the following electronic databases independently with no linguistic or date limit: PubMed/MEDLINE, Web of Science, Scopus, Google Scholar, and the Serbian Citation Index (SCIndeks). This was the search strategy: (“isotretinoin”[MeSH Terms] OR “isotretinoin”[All Fields]) AND (“acute psychosis”[MeSH Terms] OR (“acute”[All Fields] AND “psychosis”[All Fields]) OR “acute psychosis”[All Fields] OR (“acute psychosis”[MeSH Terms] OR (“acute”[All Fields] AND “psychosis”[All Fields]) OR (“isotretinoin”[MeSH Terms] OR “isotretinoin”[All Fields]) AND (“affective psychosis”[MeSH Terms] OR (“affective”[All Fields] AND “psychosis”[All Fields]) OR “affective psychosis”[All Fields] OR (“affective psychosis”[MeSH Terms] OR (“affective”[All Fields] AND “psychosis”[All Fields]) OR (“isotretinoin”[MeSH Terms] OR “isotretinoin”[All Fields]) AND (“depressive psychosis”[MeSH Terms] OR (“depressive”[All Fields] AND “psychosis”[All Fields]) OR “depressive psychosis”[All Fields] OR (“depressive

psychosis”[MeSH Terms] OR (“depressive”[All Fields] AND “psychosis”[All Fields]) OR (“isotretinoin”[MeSH Terms] OR “isotretinoin”[All Fields]) AND (“psychotic disorder”[MeSH Terms] OR (“psychotic”[All Fields] AND “disorder”[All Fields]) OR “psychotic disorder”[All Fields] OR (“psychotic disorder”[MeSH Terms] OR (“psychotic”[All Fields] AND “disorder”[All Fields])). In this study, case reports or case series with open, complete text that included full clinical records of the individuals identified with AP thought to be caused by isotretinoin were used. Age, sex, the identification of the alleged substance (isotretinoin), the manifestations of the response, the medical course, the management, and the outcome at the very least had to be available for all patients to take in a publication in the review. Case series or case reports were eliminated if they (1) failed to include a thorough clinical report for every patient and (2) discussed individuals who received isotretinoin together with other medications and whose precise cause of AP was unknown or in whom isotretinoin was ruled out as a potential cause.

Firstly, the suitability of studies based on the title and abstract was screened by 2 authors (RZZ and IL) autonomously. The full text of the publication was saved and analyzed to determine if it was likely to evaluate whether the publication completely agreed with the research topic related to the title and information provided in the abstract. If all authors agreed that the appropriateness criterion had been met, studies were included in the systematic review. If there were disagreements between distinct judgments, compromise was necessary. The following information was independently extracted for each example given by 2 authors (RZZ and TS): demographic information (age, sex), study origin (country), dosage of the drug, indication, concurrent medications, diagnostic procedures used (echocardiography, electrocardiography, laboratory analyses, coronary angiography, myocardial perfusion scintigraphy, etc.), timing of the onset of the first symptoms, location of the reaction, clinical manifestations, complications, management, length of hospital stay, and outcome.¹¹

RESULTS

Our results included 14 studies (13 case reports and 1 cohort study) with 18 individual cases (Figure 1). The oldest patient was 27 years old, and the youngest was 13 years old. Both genders were represented with 9 individuals each.

Most of the cases were reported in both Israel (n=5; 27%), Turkey (n=5; 27%), and India (n=2; 11%). One case each was reported in Saudi Arabia, Qatar, Canada, Germany, Italy, and Colombia. Half of the patients were hospitalized when symptoms of psychosis started. The longest duration of the study was 2 years. The characteristics of individual cases are shown in Table 1.

MAIN POINTS

- In some cases isotretinoin can cause acute psychosis.
- In proven cases acute psychosis caused by isotretinoin, firstly we need to stop using isotretinoin.
- We can give to the patients olanzapine or risperidone.

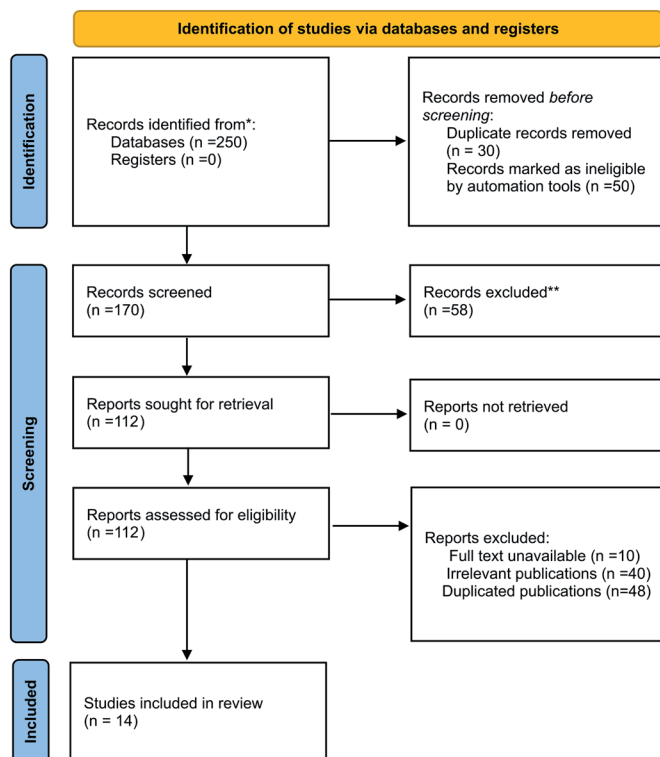


Figure 1. Selection of studies.

Three patients had obsessive-compulsive disorder, and it was treated before they started with isotretinoin. In 9 patients (50%), morphological diagnostics (electroencephalogram, computed tomography, magnetic resonance, etc.) were performed. Also, in 9 patients, a laboratory examination was performed. Manic irritability was the most common symptom described (n=9; 50%). Insomnia was described in 8 patients (44%). Also, delusional disorder was described in 4 patients (22%). All symptoms of psychosis are shown in Figure 2.

The longest duration of isotretinoin therapy before symptoms started was 11 months, and the shortest duration was 2 days. The highest dose of isotretinoin that caused symptoms of psychosis was 80 mg/day, and the lowest dose was 10 mg/day. Discontinuation of therapy with isotretinoin was necessary in all but 1 patient. In 1 patient, methylphenidate was excluded, so the symptoms of psychosis stopped.

In 3 cases, therapy for the psychosis was not needed (16%), and in 3 cases, a combination of drugs was needed (16%). In most cases, olanzapine was used for treatment (n=7; 38%), followed by risperidone (n=5; 27%) and quetiapine (n=3; 16%). Additionally, haloperidol, oxcarbamazepine, clonazepam, carbamazepine, fluvoxamine, and zolpidem. Only 1 patient was partially cured; all others were completely cured. In 1 patient, haloperidol caused acute dystonia, so it was stopped.

DISCUSSION

Isotretinoin is a form of vitamin A that is used to manage severe nodular acne, usually when patients have not responded to other treatments, including antibiotics. It inhibits the function of the sebaceous gland and keratinization. In the blood, isotretinoin has protein bounds of about 99.9% (primarily it binds to albumin), and its metabolism is by liver oxidation via hepatic isoenzymes CYP3A4, CYP2C8/9, and CYP2B6. The elimination half-life is about 18 hours, and 65-83% of the excretion of the drug is excreted in urine and feces in fairly equivalent amounts. There are a lot of side effects of isotretinoin (on the dermatological, skeletal, ocular, hematological, and neuropsychiatric systems). Psychiatric adverse effects include depression, thoughts about suicide, and psychosis. There are many studies linking isotretinoin and depression, while there are fewer that link it to psychosis. Isotretinoin-induced psychiatric symptoms have an obscure mechanism, but some studies say that isotretinoin can induce apoptosis in various cells, such as the meibomian glands,²⁶ hypothalamus compartments,²⁷ hippocampus compartments,²⁸ and sebaceous glands.²⁹ Additional studies say that, after 8 weeks of management, isotretinoin suggestively transformed the appearance of hundreds of genes in the skin.²⁸ During any period of isotretinoin treatment, psychiatric side effects can occur, and they are independent of the dose. Depressive symptoms could be caused by acne itself, due to the psychological burden it creates.³⁰ Still, the mania-inducing consequence does not seem to be simply attributable to the psychological problem of acne.

We presented a systematic review of 12 studies in which patients with a diagnosis of acne who used isotretinoin developed acute psychosis. We reviewed 11 case reports and 1 cohort study, totaling 16 patients in total. No one had a history of psychosis before the treatment, and all but 1 were cured after discontinuing the drug. Based on these facts, all studies concluded that treatment with isotretinoin was the reason for psychiatric symptoms. In 50% of all patients, morphological diagnostics and laboratory tests were performed, and all results were normal. Manic irritability, insomnia, delusional disorder, irrelevant speech, and loss of appetite accounted for the majority of symptoms.

An excessive diet of vitamins may induce psychosis.³¹ Barak et al¹³ reported that 5 of 500 soldiers cured with isotretinoin for severe acne established manic psychosis within 8 months of their introduction to isotretinoin. None of them had any prior history of psychiatric diagnosis. In this study, the patients were 3 men and 2 women, and in our study, there were a total of 16 cases—8 were men and 8 were women. The psychotic chapter persisted longer than 3 months (in all cases), and, in 3 of the cases, psychosis persisted longer than 6 months. Three of them

Table 1. Characteristics of Included Cases

Publication ID	Study Design	Age	Gender	Isotretinoin Doses	Isotretinoin Therapy Lasting	Therapy for Psychosis	Outcome
Assiri et al, 2023 ¹²	Case report	21	M	40 mg/day	5 months	Reduced doses of isotretinoin to 10 mg/day	Cured
Barak et al, 2005 ¹³	Case series	20	F	NA	3 months	Risperidon	Cured
Barak et al, 2005 ¹³	Case series	19	M	NA	8 months	Risperidon	Cured
Barak et al, 2005 ¹³	Case series	19	F	NA	7 months	Olanzapine	Cured
Barak et al, 2005 ¹³	Case series	20	F	NA	11 months	Olanzapine	Cured
Barak et al, 2005 ¹³	Case series	20	M	NA	10 months	Olanzapine	Partially cured
Demirci S, 2021 ¹⁴	Case report	17	F	First 10 mg/day then 20mg/day	1 month	Excluded isotretinoin	Cured
Elhusein et al, 2020 ¹⁵	Case report	17	M	30 mg/day	3 months	Excluded isotretinoin; olanzapine 30 mg/day	Cured
Ersoy et al, 2014 ¹⁶	Case report	18	F	30 mg/day	NA	Excluded methylfenidate	Cured
Fornnaro M, 2010 ¹⁷	Case report	25	M	10 mg/day	NA	Fluvoxamine 20 mg/day and carbamazepine 1200 mg/day then fluvoxamine 300 mg/day and olanzapine 15 mg/day	Cured
Jensen et al, 2020 ¹⁸	Case report	24	M	First 40 mg/day then 80 mg/day	NA	Excluded isotretinoin; quetiapine 100 mg	Cured
Kurhan et al, 2021 ¹⁹	Case report	18	M	20 mg/day	2 days	Excluded isotretinoin; Olanzapine 10 mg/day	Cured
Lucca et al, 2014 ²⁰	Case report	20	F	First 20 mg/day then 60 mg/day	2 months	Excluded isotretinoin; Quetiapine 100 mg at night, tablets of oxcarbamazepine 300 mg in 2 divided doses, and tablets of risperidone 2 mg at night	Cured
Özkan et al, 2020 ²¹	Case report	16	F	First 20 mg/day then 40 mg/day	2 months	Excluded isotretinoin; risperidone 1 mg	Cured
Rajagopal et al, 2014 ²²	Case report	27	M	NA	2 weeks	Excluded isotretinoin, risperidone 1 mg/night and clonazepam 0.25 mg twice a day and zolpidem 5 mg/night.	Cured
Saadet D, 2021 ²³	Case report	17	F	First 10 mg/day then 20 mg/day	2 months	Excluded isotretinoine	Cured
Segmiller et al, 2013 ²⁴	Case report	25	F	20 mg/day	3 weeks	Excluded isotretinoin and quetiapine was initiated a few days later and titrated up to 400 mg	Cured
Valderrama et al, 2017 ²⁵	Case report	13	M	20 mg/day	2 months	Excluded isotretinoin; Haloperidol 2 mg/night, but because of acute dystonia associated with the use of haloperidol, the drug was discontinued and started with olanzapine 5 mg/day.	Cured

F, female; M, male; NA, not available.

attempted suicide. In 3 cases, they established in a first-degree relative a family history of psychosis, and also, 3 individuals had a personal history of obsessive-compulsive disorder. All patients were treated with second-generation antipsychotic medicines (3 cases of olanzapine, and 3 cases of risperidone). This group of medications was the majority of treatment in our results—in 5 cases risperidone, in 6 cases olanzapine, and in 3 cases quetiapine. One patient was cured only by a reduced dose of the drug and one by its exclusion. We included this study in ours.

There are an increasing number of case reports that could connect isotretinoin and psychotic symptoms. However, 1 retrospective cohort study excluded the relationship between the use of isotretinoin and an enlarged risk for psychiatric symptoms. Jick et al³² used the Saskatchewan

and UK public health files and composed data from 7195 patients who used isotretinoin in Saskatchewan (plus 340 in the UK) and 13700 oral antibiotic users in Saskatchewan (plus 676 in the UK). They analyzed whether or not psychotic disorders and depression were more possible in these patients. Isotretinoin dosages in most cases were 20 mg/day in the UK and 40 mg/day in Saskatchewan, and the usual treatment period before symptoms started was 3-6 months. In our study, the highest dose of isotretinoin that caused symptoms of psychosis was 80 mg/day, and the lowest dose was 20 mg/day. The longest duration of isotretinoin therapy before symptoms started was 11 months, and the shortest duration was 2 days. Increasing age and female sex have been related to an increased risk for psychosis, and this was seen in both the Saskatchewan

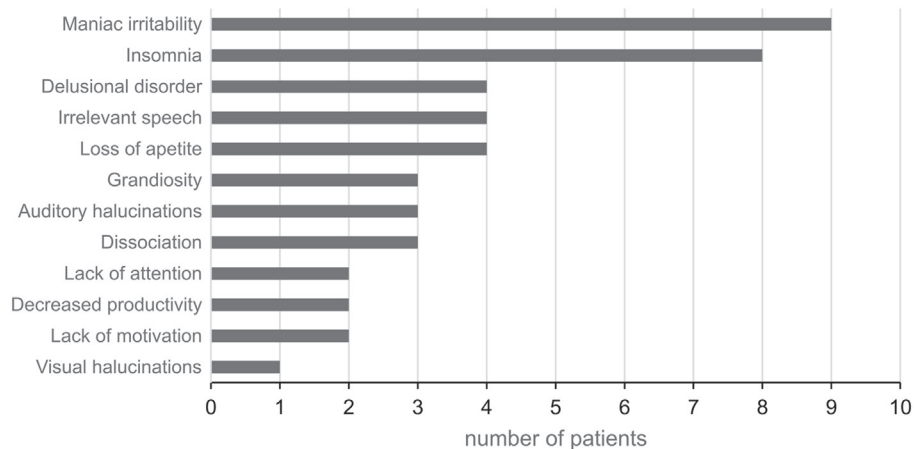


Figure 2. Symptoms of psychosis.

and UK groups. However, the relative risk for all the following outcomes (depression, other psychiatric disorders, and suicidal behavior) was all close to 1.0.

One of the cases in our study was a patient with severe insomnia. Additionally, there is a retrospective cohort study by Gupta et al.^{33,34} They collected data from the U.S. Food and Drug Administration Adverse Event Reporting System (aka FAERS). Out of 218594 individual safety reports, 1095 were concerned about insomnia. There was a significant correlation between insomnia and isotretinoin treatment.

Then, in one of the cases, they linked the presence of manic symptoms with a combination of isotretinoin and methylphenidate, so they excluded only methylphenidate., and the patient's symptoms were cured. There is 1 more study that can provide us with the same conclusion. Gupta et al³⁵ in a study on 55825 patients who were hospitalized with acne and other dermatologic difficulties, stated that attention deficit hyperactivity disorder was 2 times higher in patients with a diagnosis of acne who were treated with a combination of methylphenidate and isotretinoin when sex, age, and other factors were controlled.

The limitation of our study was the relatively small number of investigations included in the manuscript. But this is related to the small number of described cases in the literature.

Our results remind us of the significance of taking a complete medical history during the primary evaluation. The interval between isotretinoin intake and the onset of psychotic symptoms is variable, so patients on isotretinoin therapy must be followed up with neuropsychiatric side effect monitoring. After we examined our results, we concluded that in cases of psychosis caused by isotretinoin, we need to discontinue the use of isotretinoin and start therapy with olanzapine, eventually risperidone.

Peer-review: Externally peer-reviewed.

Author Contributions: Concept - R.Z.Z.; Design - T.S.; Supervision - K.J.J.; Resources - I.L.; Materials - R.Z.Z., A.C.;

Date collection - S.M.; Analysis - M.G.; Literature Search - K.J.J., T.S.; Writing - R.Z.Z.; Critical Review - T.S.

Declaration of Interests: The authors have no conflicts of interest to declare.

Funding: The authors declare that this study received no financial support.

REFERENCES

- Zaenglein AL, Pathy AL, Schlosser BJ, et al. Guidelines of care for the management of acne vulgaris. *J Am Acad Dermatol.* 2016;74(5):945-73.e33. [CrossRef]
- On SC, Zeichner J. Isotretinoin updates. *Dermatol Ther.* 2013;26(5):377-389. [CrossRef]
- Strauss JS, Krowchuk DP, Leyden JJ, et al. Guidelines of care for acne vulgaris management. *J Am Acad Dermatol.* 2007;56(4):651-663. [CrossRef]
- Christiansen JV, Gadborg E, Ludvigsen K, et al. Topical tretinoin, vitamin A acid (Ainol) in acne vulgaris. A controlled clinical trial. *Dermatologica.* 1974;148(2):82-89. [CrossRef]
- Pile HD, Sadiq NM. Isotretinoin. In: *StatPearls*. Treasure Island (FL): StatPearls Publishing; 2023.
- Huang YC, Cheng YC. Isotretinoin treatment for acne and risk of depression: A systematic review and meta-analysis. *J Am Acad Dermatol.* 2017;76(6):1068-1076.e9. [CrossRef]
- Wysowski DK, Pitts M, Beitz J. An analysis of reports of depression and suicide in patients treated with isotretinoin. *J Am Acad Dermatol.* 2001;45(4):515-519. [CrossRef]
- Bremner JD, Shearer KD, McCaffery PJ. Retinoic acid and affective disorders: the evidence for an association. *J Clin Psychiatry.* 2012;73(1):37-50. [CrossRef]
- Zetterström RH, Lindqvist E, Mata de Urquiza A, et al. Role of retinoids IN THE CNS: differential expression of retinoid binding proteins and receptors and evidence for presence of retinoic acid. *Eur J Neurosci.* 1999;11(2):407-416. [CrossRef]
- Ng CH, Schweitzer I. The association between depression and isotretinoin use in acne. *Aust N Z J Psychiatry.* 2003;37(1):78-84. [CrossRef]

11. Pejcic AV, Milosavljevic MN, Jankovic S, Davidovic G, Folic MM, Folic ND. Kounis syndrome associated with the use of diclofenac. *Tex Heart Inst J*. 2023;50(1):e217802. [\[CrossRef\]](#)
12. Assiri SH, Alosaimi AK, Alharbi EA. Severe insomnia induced by isotretinoin use for the management of acne vulgaris: A rare side effect. *Cureus*. 2023;15(1):e33658. [\[CrossRef\]](#)
13. Barak Y, Wohl Y, Greenberg Y, et al. Affective psychosis following Accutane (isotretinoin) treatment. *Int Clin Psychopharmacol*. 2005;20(1):39-41. [\[CrossRef\]](#)
14. Demirci Saadet E. Isotretinoin-induced visual hallucinations in a patient with acne vulgaris. *Pediatr Dermatol*. 2021;38(5):1349-1350. [\[CrossRef\]](#)
15. Elhusein B, Elkhaled W, Khodoruth MAS, Kumar R, Al Abdulla M. Isotretinoin-induced psychotic episode in a 17-year-old adolescent male. *SAGE Open Med Case Rep*. 2020;8:2050313X20931342. [\[CrossRef\]](#)
16. Ersoy MA, Ersoy HT. Manic symptoms associated with isotretinoin and methylphenidate combination: a case report. *Psychiatry Clin Psychopharmacol*. 2014;24(3):261-264. [\[CrossRef\]](#)
17. Fornaro M. Obsessive-compulsive disorder with bipolar diathesis following isotretinoin therapy remitting upon treatment with olanzapine and fluvoxamine. *Neuropsychiatr Dis Treat*. 2010;6:719-722. [\[CrossRef\]](#)
18. Jensen KV, Abba-Aji A. Isotretinoin-induced delusional disorder, somatic subtype. *Case Rep Dermatol Med*. 2020;2020:8853167. [\[CrossRef\]](#)
19. Kurhan F, Kamiş GZ. Isotretinoin induced psychotic mania: A case report. *Turk Psikiyatr Derg*. 2021;32(3):214-218. [\[CrossRef\]](#)
20. Lucca JM, Varghese NA, Ramesh M, Ram D. A case report of isotretinoin-induced manic psychosis. *Indian J Dermatol*. 2016;61(1):120. [\[CrossRef\]](#)
21. Özkan S, et al. Psychosis Induced by Isotretinoin: In an Adolescent Case. *Front Med Case Rep*. 2020;1(4):1-04.
22. Rajagopal S. Acute psychosis induced by isotretinoin. *Indian J Psychiatry*. 2014;56(3):295-297. [\[CrossRef\]](#)
23. Demirci Saadet E. Isotretinoin-induced visual hallucinations in a patient with acne vulgaris. *Pediatr Dermatol*. 2021;38(5):1349-1350. [\[CrossRef\]](#)
24. Segmiller FM, Rüter T, Linhardt A, Dehning S, Möller HJ, Zetzsche T. Psychosis during treatment with isotretinoin. *Ther Adv Psychopharmacol*. 2013;3(4):244-245. [\[CrossRef\]](#)
25. Valderrama F, Gómez A, Restrepo D. Primer episodio psicótico en adolescente con acné vulgar y tratamiento con isotretinoína [Isotretinoin therapy for acne vulgaris and first episode psychosis in an adolescent patient]. *Rev Colomb Psiquiatr*. 2017;46(1):50-54. [\[CrossRef\]](#)
26. Lambert RW, Smith RE. Effects of 13-cis-retinoic acid on the hamster Meibomian gland. *J Invest Dermatol*. 1989;92(3):321-325. [\[CrossRef\]](#)
27. Griffin JN, Pinali D, Olds K, et al. 13-cis-retinoic acid decreases hypothalamic cell number in vitro. *Neurosci Res*. 2010;68(3):185-190. [\[CrossRef\]](#)
28. Sakai Y, Crandall JE, Brodsky J, McCaffery P. 13-cis retinoic acid (Accutane) suppresses hippocampal cell survival in mice. *Ann N Y Acad Sci*. 2004;1021:436-440. [\[CrossRef\]](#)
29. Crandall J, Sakai Y, Zhang J, et al. 13-cis-retinoic acid suppresses hippocampal cell division and hippocampal-dependent learning in mice. *Proc Natl Acad Sci U S A*. 2004;101(14):5111-5116. [\[CrossRef\]](#)
30. Nelson AM, Zhao W, Gilliland KL, Zaenglein AL, Liu W, Thiboutot DM. Temporal changes in gene expression in the skin of patients treated with isotretinoin provide insight into its mechanism of action. *Derm Endocrinol*. 2009;1(3):177-187. [\[CrossRef\]](#)
31. Halvorsen JA, Stern RS, Dalgard F, Thoresen M, Bjertness E, Lien L. Suicidal ideation, mental health problems, and social impairment are increased in adolescents with acne: a population-based study. *J Invest Dermatol*. 2011;131(2):363-370. [\[CrossRef\]](#)
32. O'Reilly K, Bailey SJ, Lane MA. Retinoid-mediated regulation of mood: possible cellular mechanisms. *Exp Biol Med (Maywood)*. 2008;233(3):251-258. [\[CrossRef\]](#)
33. Strahan JE, Raimer S. Isotretinoin and the controversy of psychiatric adverse effects. *Int J Dermatol*. 2006;45(7):789-799. [\[CrossRef\]](#)
34. Gupta MA, Vujcic B, Gupta AK. Isotretinoin use in acne is associated with a higher odds of the adverse effect of insomnia: results from the US FDA Adverse Events Reporting System. *J Am Acad Dermatol*. 2020;83(6):121. [\[CrossRef\]](#)
35. Gupta MA, Gupta AK, Vujcic B. Increased frequency of attention deficit hyperactivity disorder (ADHD) in acne versus dermatologic controls: analysis of an epidemiologic database from the US. *J Dermatolog Treat*. 2014;25(2):115-118. [\[CrossRef\]](#)