

# Giant renal vein aneurysm

Nicholas J. Madden, DO, Keith D. Calligaro, MD, Douglas A. Troutman, DO, Krystal Maloni, MD, and Matthew J. Dougherty, MD, Philadelphia, Pa

## ABSTRACT

A 37-year-old asymptomatic man presented with incidentally identified intra-abdominal venous aneurysms. Workup, which included venography, demonstrated an absent segment of the inferior vena cava between the inferior right and superior left renal vein, resulting in a 4.4-cm right renal vein aneurysm, dilated common iliac veins, and left external iliac vein aneurysm. Collateralization was robust. Given the limited natural history data and complexities of open reconstruction, we opted to observe this asymptomatic patient with serial imaging, which demonstrated no interval change. We present our case and a review of the literature pertaining to intra-abdominal venous aneurysms. (*J Vasc Surg Cases and Innovative Techniques* 2019;5:365-8.)

**Keywords:** Renal vein aneurysm; Absent IVC; Venous aneurysms

## CASE REPORT

A 37-year-old healthy white man presented to the emergency department with left flank pain. A computed tomography (CT) scan was obtained and was notable for large venous aneurysms involving the right renal vein (RV) and left external iliac vein (EIV), with ectasia of bilateral common iliac veins (CIVs; Fig 1). There were multiple large venous collaterals throughout the abdomen. There was no evidence of venous thrombus. The patient had resolution of his symptoms in the emergency department and was referred to us for further vascular evaluation.

At the follow-up visit, the patient remained asymptomatic. Physical examination was unremarkable, without evidence of abdominal pain or lower extremity varicosities or edema. We performed an abdominal venous duplex ultrasound scan, CT venography, and bilateral common femoral vein (CFV) and right internal jugular vein (IJV) catheterizations in our hybrid endovascular suite to better delineate venous anatomy and potentially to intervene.

Venography performed through both CFV catheters confirmed a 4.4-cm right RV aneurysm, a 3.8-cm left EIV aneurysm, dilated bilateral CIVs, and normal-diameter inferior vena cava (IVC) that terminated immediately superior to the right RV origin. We were unable to establish wire continuity through the absent IVC from below. Multiple large collaterals were visualized (Figs 2 and 3), namely, dilated lumbar, azygos, and gonadal veins.

We accessed the right IJV but could not advance a guidewire through the absent IVC immediately inferior to the draining left

RV. Venography demonstrated that the left RV was of normal caliber (Fig 4). A simultaneous injection of contrast material through the right CFV catheter and the right IJV catheter confirmed a 2-cm segment of absent IVC between the left and right RVs (Fig 5).

Intravascular ultrasound (IVUS) through the femoral veins ruled out significant narrowing of the left CIV and May-Thurner syndrome. IVUS revealed the following transverse diameters: IVC, 2.0 cm; right CIV, 1.8 cm; left CIV, 1.9 cm; and left EIV, 3.8 cm. All were consistent with the CT findings. Venous pressure measurements failed to show any significant gradient between the aneurysms and the superior or inferior portion of the IVC (all pressures, 17-20 mm Hg).

Consultation with the rheumatology service, serologic studies, and skin biopsy ruled out inflammatory conditions and congenital connective tissue disorders.

The patient was seen for follow-up at 6 months. A repeated venous duplex ultrasound examination showed stability in size of the venous aneurysms. We opted to observe him with serial duplex ultrasound studies in our noninvasive vascular laboratory, given the lack of symptoms, paucity of natural history data, and significant perioperative risk that would be associated with surgical repair.

The patient's permission was obtained for publication of this report and images.

## DISCUSSION

Venous aneurysms are rarely encountered by vascular surgeons. It is estimated that just >500 cases of venous aneurysm have been reported, with most involving veins in the extremities ( $n = 279$ ).<sup>1</sup> Next most frequently reported are intra-abdominal venous aneurysms ( $n = 152$ ), most of which are reported to involve the portal vein ( $n = 128$ ).<sup>1,2</sup> To date, we are unaware of any reports involving an RV aneurysm.

In a literature review previously reported by our group, intra-abdominal venous aneurysms have been noted in the IVC, superior mesenteric vein, splenic vein, iliac veins, and most commonly the portal vein.<sup>3</sup> The natural history of these lesions is not clear, but these patients appear to

---

From the Section of Vascular Surgery, Pennsylvania Hospital.

Author conflict of interest: none.

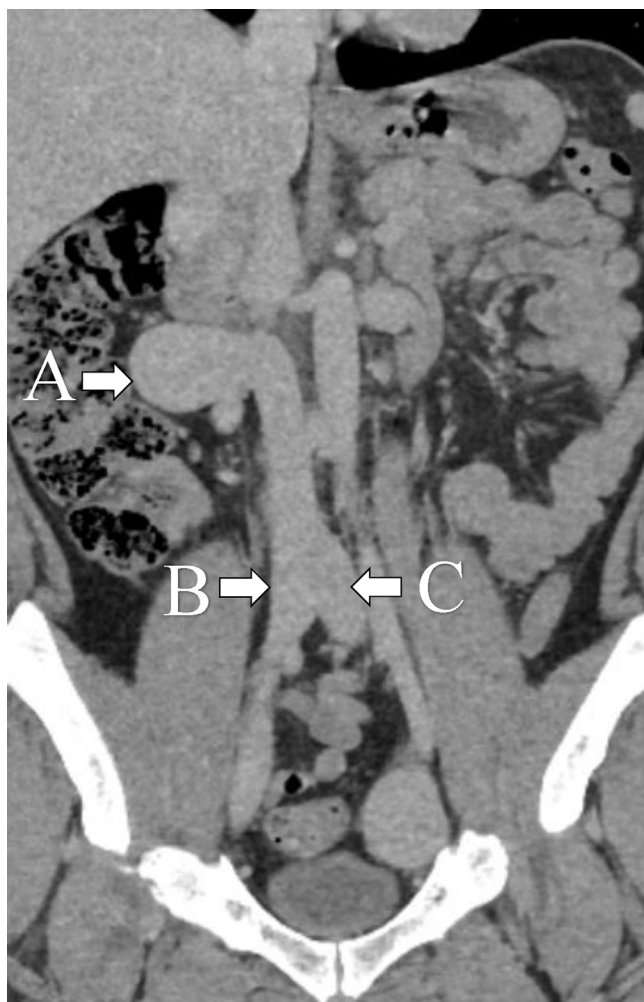
Correspondence: Nicholas J. Madden, DO, Section of Vascular Surgery, Pennsylvania Hospital, 700 Spruce St, Ste 101, Philadelphia, PA 19106 (e-mail: [njmadden@gmail.com](mailto:njmadden@gmail.com)).

The editors and reviewers of this article have no relevant financial relationships to disclose per the Journal policy that requires reviewers to decline review of any manuscript for which they may have a conflict of interest.

2468-4287

© 2019 The Authors. Published by Elsevier Inc. on behalf of Society for Vascular Surgery. This is an open access article under the CC BY-NC-ND license (<http://creativecommons.org/licenses/by-nc-nd/4.0/>).

<https://doi.org/10.1016/j.jvscit.2019.06.007>

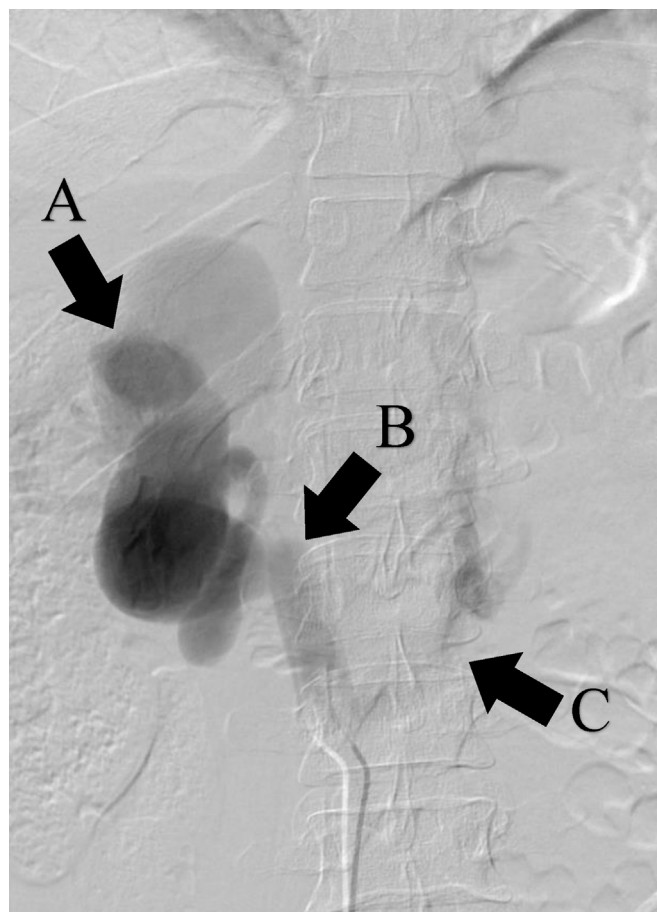


**Fig 1.** Coronal reconstruction of noncontrast-enhanced computed tomography (CT) scan. Right renal vein (RV) aneurysm, 4.4 cm (A), right (1.8 cm) and left (1.9 cm) common iliac vein (CIV) ectasia (B and C, respectively).

be at an increased risk of gastrointestinal bleeding (particularly portal and splenic vein aneurysms), rupture, and fistula formation.<sup>3,4</sup> Thromboembolic complications, although more frequent in extremity venous aneurysms, have also been reported in ilio caval aneurysms.<sup>5</sup>

Intra-abdominal venous aneurysms can be congenital or acquired. Secondary causes include portal hypertension, liver disease, trauma, and other inflammatory conditions.<sup>6</sup> An additional rare but recognized cause of venous aneurysms is Parkes Weber syndrome, a rare congenital condition similar to Klippel-Trénaunay syndrome except that it is associated with arteriovenous fistulas that can cause venous aneurysm formation. Our patient had no personal or family history of this autosomal dominant condition. Moreover, he had no evidence of other connective tissue disorders or vasculitis.

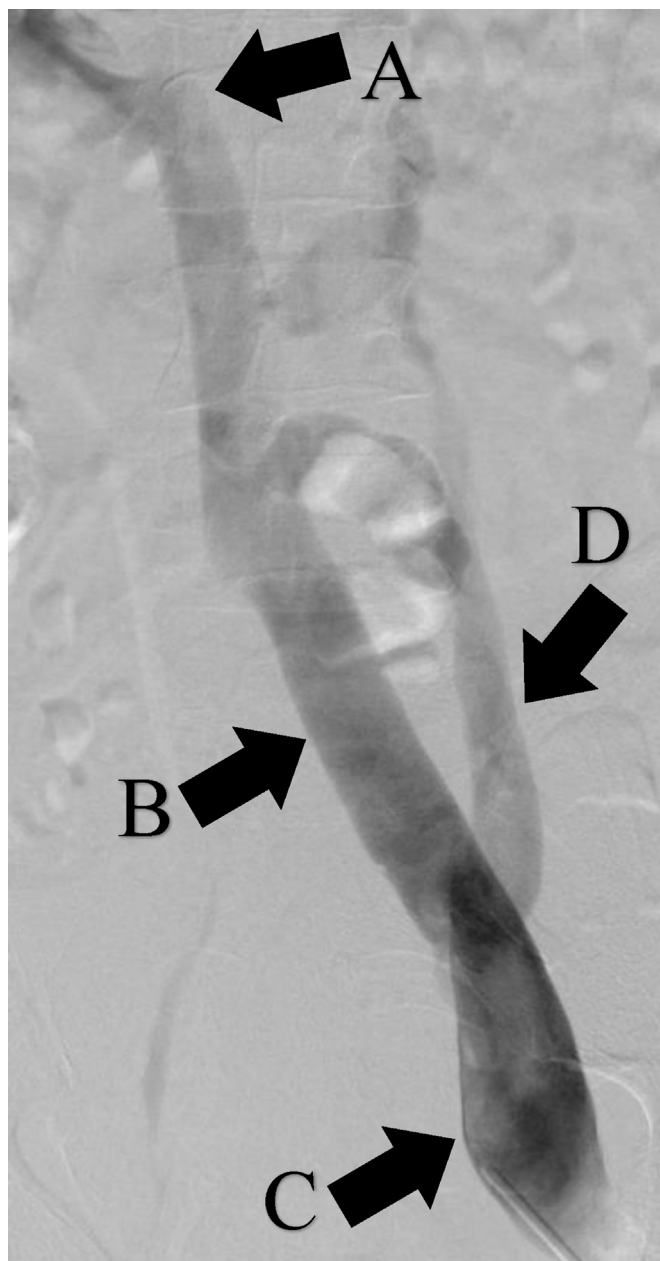
Our patient appeared to have a congenital 2-cm-long absence of the IVC between the inferior right RV (which



**Fig 2.** Right transfemoral venogram. A, Right renal vein (RV) aneurysm. B, Absent inferior vena cava (IVC) just cranial to takeoff of right RV. C, Large lumbar vein collateral.

drained into the vena cava below the absent segment) and superior left RV (which drained into the vena cava above the occlusion). Aneurysms involving the IVC have been reported in instances of a congenitally absent IVC, but to our knowledge, this congenital anomaly has not been associated with aneurysmal dilation of the RV. Moreover, an absent IVC or aneurysmal IVC typically is manifested with thromboembolic events involving lower extremity swelling and deep venous thrombosis, which was not the case in our patient.<sup>5,7-9</sup> We presume the congenitally absent segment of our patient's IVC predisposed him to aneurysmal dilation and ultimately the extensive collateralization through the lumbar, azygos, and gonadal veins seen on CT and venography.

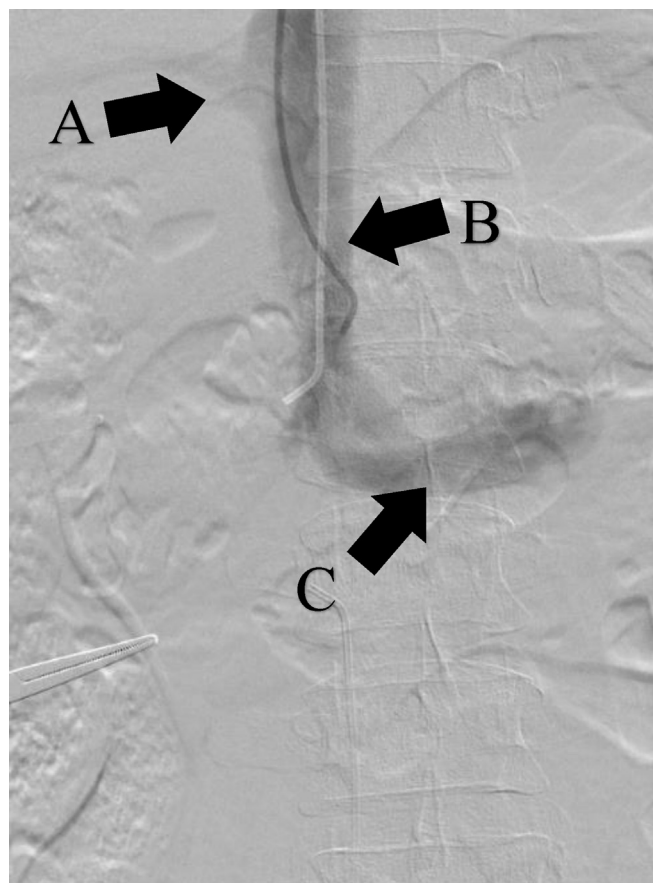
Contrary to previous reports of rupture, intraoperative pressure measurements in our patient failed to demonstrate a pressure gradient between the left RV (normal caliber) and right RV (aneurysmal) or between the superior and inferior IVC segments.<sup>4</sup> We believe the patient's extensive collateral network, similar to that seen with chronic iliofemoral deep venous thromboses, served to decompress these aneurysms over



**Fig 3.** Left transfemoral venogram. A, Absent segment of inferior vena cava (IVC) at level of right renal vein (RV). B, Left common iliac vein (CIV). C, Left external iliac vein (EIV). D, Gonadal vein.

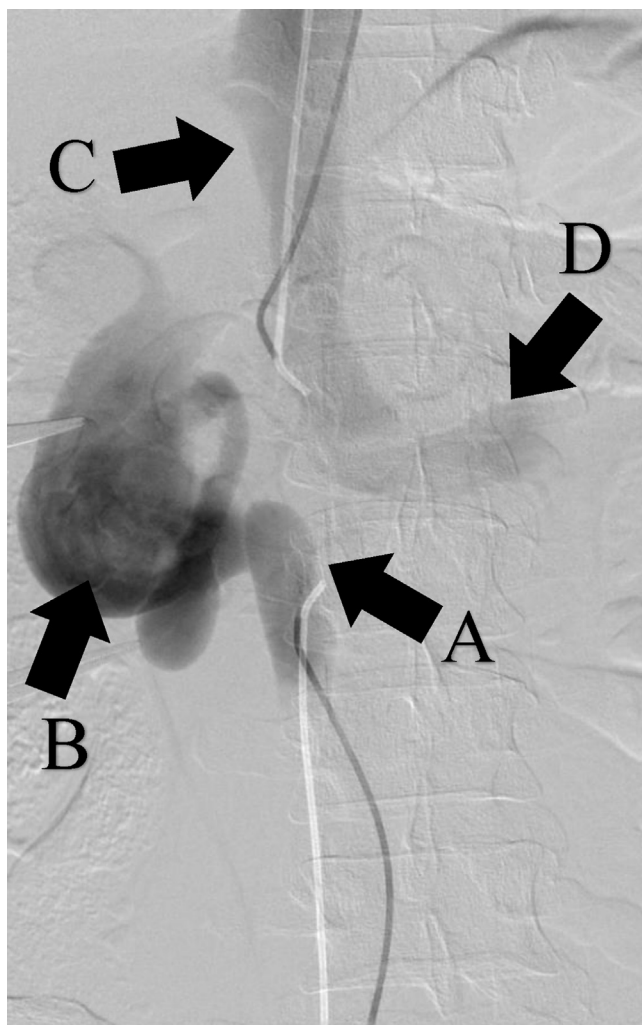
time. In the absence of elevated venous pressures, there may be diminished risk of rupture, which eliminates this reason for repair as long as the venous aneurysms remain stable and free of thrombus. Similarly, IVUS demonstrated no evidence of extrinsic compression to account for the asymmetry between the left and right iliofemoral systems.

Although we have previously recommended repair of intra-abdominal venous aneurysms in “low-risk” patients,<sup>5</sup> this case illustrates the significant potential perioperative



**Fig 4.** Right transjugular venogram. A, Hepatic vein. B, Inferior vena cava (IVC; above blind segment). C, Left renal vein (RV), normal caliber, draining into IVC above blind segment.

morbidity and mortality that could be associated with ilio caval and RV reconstruction. We are unaware of any reports of such an extensive abdominal venous aneurysmal pattern. Some authors have advocated for decompressive shunts in the case of portal venous aneurysms or excision and venorrhaphy with primary repair or patch reconstruction for ilio caval aneurysms.<sup>5,10,11</sup> Direct caval repair would prove difficult in terms of exposure around a large, potentially thin-walled right RV aneurysm with potential for significant blood loss. There have been successful reports of endovascular management for isolated iliac vein aneurysms (associated with arteriovenous malformations), but open surgical reconstruction is still considered standard of care when treatment is elected.<sup>1,3,12,13</sup> We plan to reserve intervention for the development of symptoms or thromboembolic complications or if there is evidence of fistula formation or aneurysmal growth. New endovascular techniques, such as sharp recanalization of chronic caval occlusions, are proving to be a viable alternative to more invasive open options and may eventually become the new standard for these rare entities.<sup>14</sup>



**Fig 5.** Simultaneous transfemoral and transjugular venogram. A, Inferior vena cava (IVC) terminates at level of right renal vein (RV). B, Large right RV aneurysm. C, Normal IVC above blind segment. D, Normal-caliber left RV draining into IVC above blind segment.

## CONCLUSIONS

Intra-abdominal venous aneurysms are a rare entity. To our knowledge, there are no prior reports of an RV aneurysm in the setting of a congenitally absent segment of the IVC. Despite our previous recommendation of prophylactically intervening on low-risk patients with intra-abdominal venous aneurysms, this case poses significant

risk in an asymptomatic patient when the natural history of this unusual entity is ill-defined. For patients who do require intervention, newer endovascular techniques for recanalization may become the new standard.

## REFERENCES

1. Teter KA, Maldonado TM, Adelman MA. A systematic review of venous aneurysms by anatomic location. *J Vasc Surg Venous Lymphat Disord* 2018;6:408-13.
2. Laurenzi A, Ettorre GM, Lionetti R, Meniconi RL, Colasanti M, Vennarecci G. Portal vein aneurysm: what to know. *Dig Liver Dis* 2015;47:918-23.
3. Calligaro KD, Ahmad S, Dandora R, Dougherty MJ, Savarese KJ, Doerr KJ, et al. Venous aneurysms: surgical indications and review of the literature. *Surgery* 1995;117:1-6.
4. Park JS, Kim JY, Kim M, Park SC, Lee KY, Won YS. Ruptured aneurysm of the external iliac vein. *J Vasc Surg Venous Lymphat Disord* 2016;4:92-4.
5. Gradman WS, Steinberg F. Aneurysm of the inferior vena cava: case report and review of the literature. *Ann Vasc Surg* 1993;7:347-53.
6. Lerch R, Wolfle KD, Loeprecht H. Superior mesenteric venous aneurysm. *Ann Vasc Surg* 1996;10:582-8.
7. Singh K, Poliquin J, Syversten G, Kohler DO. A rare cause of venous thrombosis: congenital absence (agenesis) of the inferior vena cava. *Int J Angiol* 2010;19:e110-2.
8. Leitao A, Esteves JM, Abreu JP, Pereira AF, Boncoraglio MT, Certo M, et al. Deep venous thrombosis and a very rare finding: inferior vena cava infra-renal segment agenesis. *Eur J Case Rep Intern Med* 2019;6:001063.
9. Dougherty MJ, Calligaro KD, DeLaurentis DA. Congenitally absent inferior vena cava presenting in adulthood with venous stasis and ulceration: a surgically treated case. *J Vasc Surg* 1996;23:141-6.
10. Sakai T, Katoh T, Asada K, Yagi K, Yoshida R. Portal hepatic venous shunt via an intrahepatic portal vein aneurysm. *Intern Med* 1992;32:899-903.
11. Taki M, Miura T, Kobayashi T, Kasai T, Maruyama T, Hayakawa M, et al. Primary external iliac venous aneurysm: a case report. *Ann Vasc Dis* 2018;11:143-7.
12. DeWane M, Quencer K, Ochoa Char CI. Endovascular treatment of a large iliac vein aneurysm and high flow arteriovenous fistula. *J Vasc Surg* 2016;64:859.
13. Thompson PC, Ullery BW, Fleischmann D, Chandra V. Novel approach to a giant external iliac vein aneurysm secondary to posttraumatic femoral arteriovenous fistula. *Vasc Endovasc Surg* 2015;49:148-51.
14. Chick JF, Srinivasa RN, Cooper KJ, Jairath N, Hage AN, Spencer B, et al. Endovascular iliocaval reconstruction for chronic iliocaval thrombosis: the data, where we are, and how it is done. *Tech Vasc Interv Radiol* 2018;21:92-104.

Submitted May 4, 2019; accepted Jun 19, 2019.