


SURGICAL TECHNIQUE

Cervical Flexion Osteotomy through One-Stage Posterior-Anterior-Posterior Approach for Cervical Extension Deformity in Ankylosing Spondylitis: A Novel Surgical Technique

Zhi-wei Wang, MD[†] , Jia-wei Shu, MD[†], Fang-cai Li, MD, Wei-shan Chen, MD, Qi-xin Chen, MD, Gang Chen, MD, Jun Li, MD

Orthopedics Department, Second Affiliated Hospital, School of Medicine, Zhejiang University, Hangzhou, China

The present study was to introduce a new surgical technique of cervical flexionosteotomy, with an emphasis on the clinical and radiographic outcomes. Two male patients aged 45 and 21 years presented with cervical extension deformity in ankylosing spondylitis (AS). Both patients exhibited upward deviation of the forward gaze. The chin brow vertical angle (CBVA) were 15° upward and 5° downward, respectively; and the sagittal vertical axis (SVA) were -13.2mm and 195.7mm, respectively. Aposterior transverse release was performed at C₇-T₁, exposing the theca and C8 nerve roots to facilitate closure of the osteotomy site. Then, an anterior closing-wedgeosteotomy of C₇-T₁ was performed followed with anterior internal fixation with a locking plate to prevent any translation. After closure and anterior fixation, patients were returned to the prone position, and posterior screw-rod instrumentation was used for further stabilization. The follow-up periods were 20 and 10 months, respectively. At the last follow-up, CBVA and SVA of Patient 1 were 14° downward and -12.6mm; and CBVA and SVA of Patient 2 were 1° downward and 75.6mm respectively, indicating the visual angle and sagittal balance were significantly improved. No intraoperative or postoperative complications were encountered. Full-spine radiographs of each patient at the last visit confirmed successful bony union. The present study was the first report introducing a novel flexion osteotomy for cervical extension deformity in AS through a posterior-anterior-posterior approach in one-stage. The improved forward gaze and no complications demonstrated the effectiveness and safety of the novel technique, suggesting that it might provide a more feasible method for the correction of cervical extension deformity.

Key words: Ankylosing spondylitis; Cervical deformity; Extension deformity; Hyperlordosis; Osteotomy

Introduction

Ankylosing spondylitis (AS) involves the whole spine and can cause spinal deformity. Most of the spinal deformity is thoracolumbar kyphosis, which would affect forward gaze and global balance¹. When the deformity involves the cervical spine it is possible that cervical kyphosis or flexion deformity could develop^{2,3}. Cervical extension osteotomy is widely used to correct cervical kyphotic deformity for the purpose of recovering sagittal imbalance and improving forward gaze³⁻⁶.

Compared with kyphotic deformity, cervical hyperlordosis or extension deformity is rare in clinic, and the surgical treatment of cervical extension deformity has rarely been reported in relevant literature^{7,8}. Therefore, cervical flexion osteotomy is technically demanding, carrying the potential risk of devastating neurological injury. This study reported two cases of AS with cervical extension deformity treated with a novel surgical technique through a one-stage posterior-anterior-posterior approach. Our

Address for Correspondence Fang-cai Li, MD, Orthopedics Department, Second Affiliated Hospital, School of Medicine, Zhejiang University, No.88, Jiefang Road, Hangzhou, China 310000 Tel: +86-571-56055934; Fax: +86-571-56055934; Email: 2505004@zju.edu.cn

[†]Zhi-wei Wang and Jia-wei Shu contribute equally to the manuscript.

Disclosure: This work was supported by National Natural Science Foundation of China (Grant No.81702220).

Received 24 October 2019; accepted 12 March 2020

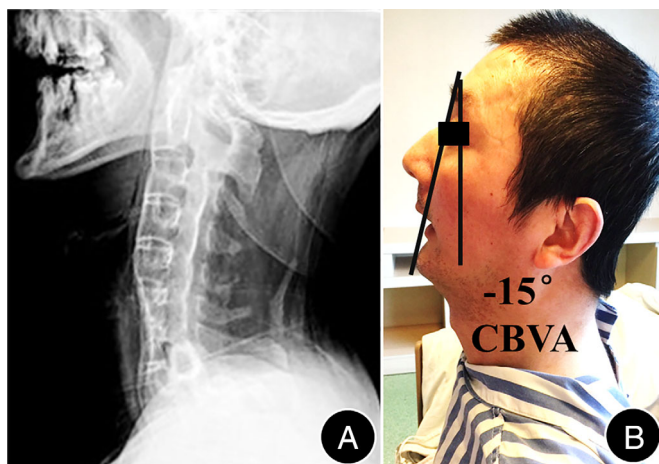


Fig. 1 The preoperative condition of Case One (45-year-old-male patient). (A) The cervical lateral radiograph. (B) The cervical lateral photograph, showing the preoperative visual field of 15° upward chin-brow vertical angle (CBVA).

objective was to introduce a novel surgical technique of cervical flexion osteotomy through a one-stage posterior-anterior-posterior approach with emphasis on the clinical and radiographic outcomes.

Case Presentation

Case One

Case One was a 45-year-old-male patient with AS for 30 years who was bedridden for 18 years due to ankylosis of hips and knees. He was able to sit up by himself after bilateral hip replacements 2 years ago, but was unable to see the floor within 4 meters of his feet. He had difficulties with eating and personal hygiene. Physical examination showed no cervical motion in any direction and no more than 45° of hip flexion. Anteroposterior and lateral full-spine radiographs obtained in the sitting position revealed 25° of cervical lordosis, 43° of thoracic kyphosis, 62° of lumbar lordosis, -13.2 mm of sagittal vertical axis (SVA) backward, and -3° of T₁-spinopelvic incidence (T₁-SPI). The chin-brow vertical angle (CBVA)^{9,10} was 15° upward (Fig. 1).

Case Two

Case Two was a 21-year-old male with AS for 15 years. He complained of progressive thoracolumbar kyphosis and intractable back pain for 5 years. Bilateral hip replacements were performed 7 years ago. The radiographs showed 49° of cervical lordosis, 72° of thoracolumbar kyphotic deformity, 36° of thoracic kyphosis, and -8° of lumbar lordosis. SVA and T₁-SPI were 195.7 mm forward and 12°, respectively. CBVA was 5° downward. His thoracolumbar kyphotic deformity required corrective osteotomy, but this would lead to

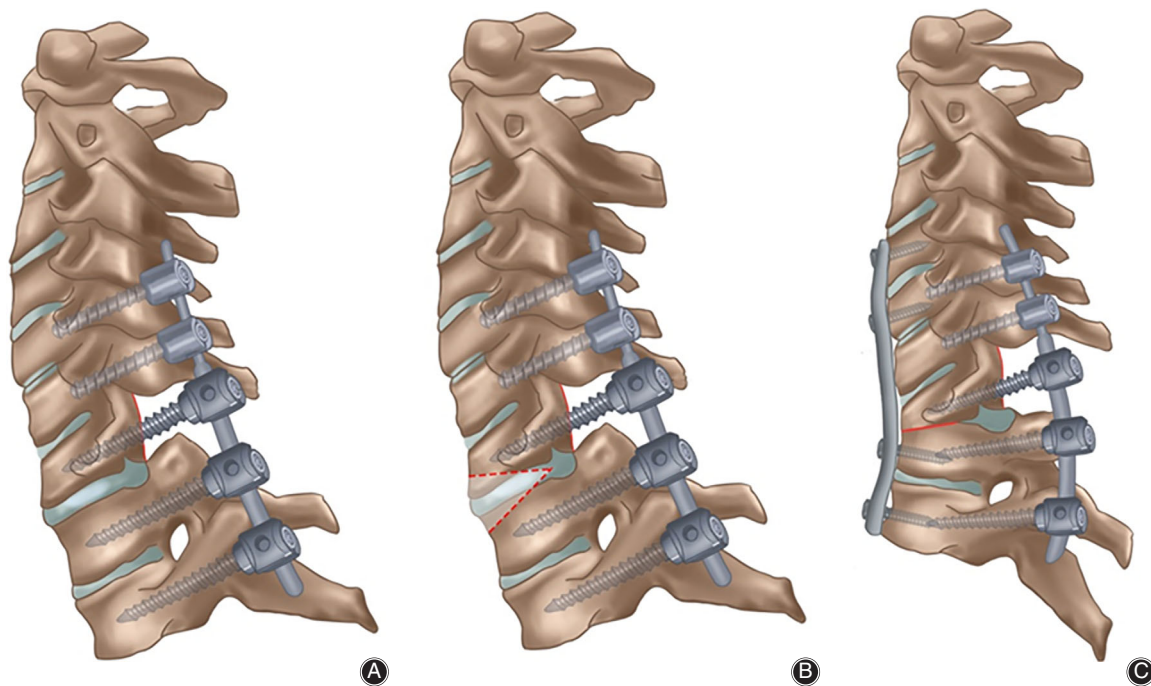


Fig. 2 The schematic illustration of the operative procedure of cervical flexion osteotomy. (A) In the prone position, a posterior transverse osteotomy of lamina and bilateral facet joints was performed at C₇-T₁ with a chisel; then pedicle screws (C₇-T₂) and lateral mass screws (C_{5,6}) were placed and connected with rods without locking tightly. (B) In the supine position, C₇-T₁ closing-wedge osteotomy was performed. (C) After achieving the desired correction, an anterior plate (C₄-T₂) was applied for further fixation.

the secondary cervical extension deformity and make the visual angle deviate upward before the staged cervical operation¹¹, resulting in him not being able to look after himself during this time. Thus, cervical flexion osteotomy was determined before the correction of thoracolumbar kyphosis.

Operative Procedure of Cervical Flexion Osteotomy

A novel cervical flexion osteotomy was performed to correct the cervical deformity through one-stage posterior-anterior-posterior approach. Firstly, the patient was prepared and draped in the prone position. The posterior region from C₄ to T₂ was approached by midline incision. A posterior transverse osteotomy of lamina and bilateral facet joints was performed at C₇-T₁ with a chisel until the theca and C₈ nerve roots were exposed. Pedicle screws (C₇-T₂) and lateral mass screws (C₅₋₆) were placed and connected with rods, without being locked tightly (Fig. 2A).

Then the patient was moved to the supine position. A longitudinal incision was used to expose the anterior vertebral column. According to the preoperative design, C₇-T₁ closing-wedge osteotomy was performed with the posterior margin of disc space as a hinge. After completing the osteotomy, the head was raised by an assistant in a controlled manner to close the osteotomy wedge. Then, the position of the head and neck was checked by fluoroscopy, and the neurological status was determined by a neuromonitor. When the desired correction was achieved, an anterior plate (C₄-T₂) was applied for further fixation (Fig. 2B-C).

The patient was then returned to the prone position, and the posterior incision was reopened. Posterior fixation was performed after checking that there was no compression of the theca and C₈ nerve roots.

Spinal cord monitoring was used throughout the procedure, and no wake-up test was performed. The total operation duration was about 7.0 hours, and blood loss in operation was about 200 mL. After surgery, cervical immobilization was maintained with a molded collar for 8 weeks.

Measurements

The radiological parameters, including the cervical lordosis, thoracic kyphosis, lumbar lordosis, CBVA, SVA, and T₁-SPI¹², were measured with Surgimap Spine software (Nemaris Inc., New York, NY).

Results

No intraoperative or postoperative complications were encountered in both patients. For Case One, the postoperative cervical lordosis was -8° , and CBVA was 18° downward with cervical lordosis correction of 33° . He could sit up by himself, and the abilities of forward gaze and personal hygiene were improved significantly. The thoracic kyphosis and lumbar lordosis were 43° and 62° , and SVA and T₁-SPI in the sitting position were -12.6 mm backward and -3° , respectively. The follow-up period was 20 months, and the full-spine radiograph at the last visit showed -8° of cervical lordosis and 14° of CBVA downward, indicating no

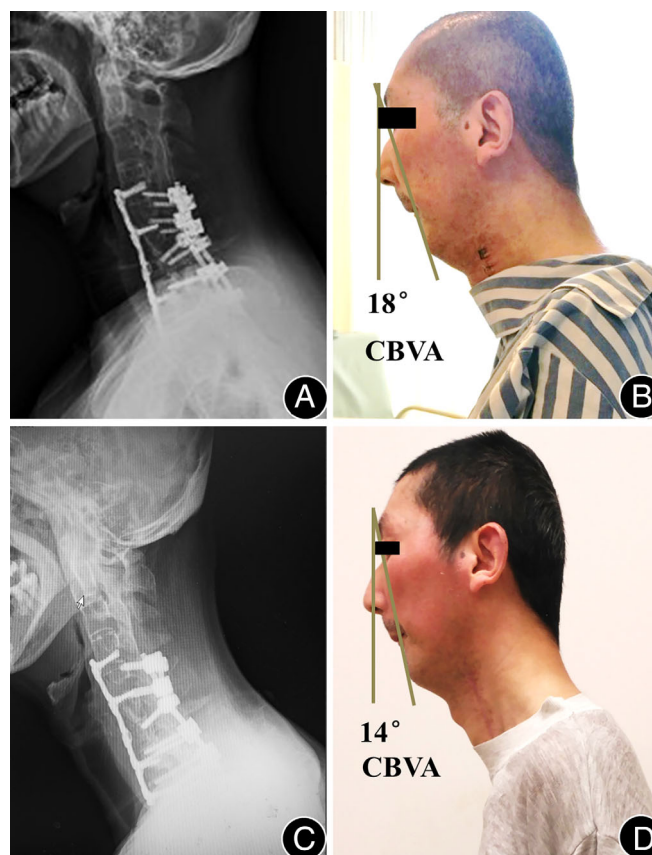


Fig. 3 The postoperative condition of Case One (45-year-old-male patient). (A) The immediate postoperative cervical radiograph. (B) The immediate postoperative cervical photograph, showing the visual angle had improved, with an 18° downward chin-brow vertical angle (CBVA). (C) The 20-month-postoperative cervical radiograph. (D) The 20-month-postoperative cervical photograph, confirming the good correction of visual angle with a 14° downward CBVA.

significant loss of correction and successful bony union (Fig. 3).

For Case Two, the cervical lordosis was 16° , and CBVA was 38° downward with cervical correction of 33° . He underwent further correction of thoracolumbar kyphotic deformity 3 weeks after cervical osteotomy, with pedicle subtraction osteotomy at L₂. After surgery, the thoracolumbar kyphotic deformity was 35° with 37° of correction. Finally, the postoperative cervical lordosis was 16° and CBVA was 1° downward with normal visual angle. The thoracic kyphosis was 52° , and lumbar lordosis was 40° . SVA and T₁-SPI were 75.6 mm and 0° (Fig. 4). The follow-up period was 10 months, and the radiograph at the last visit showed no significant loss of correction and successful bony union.

Discussion

Cervical hyperlordosis or extension deformity in AS is rare in clinic; however, it has more effects on the quality

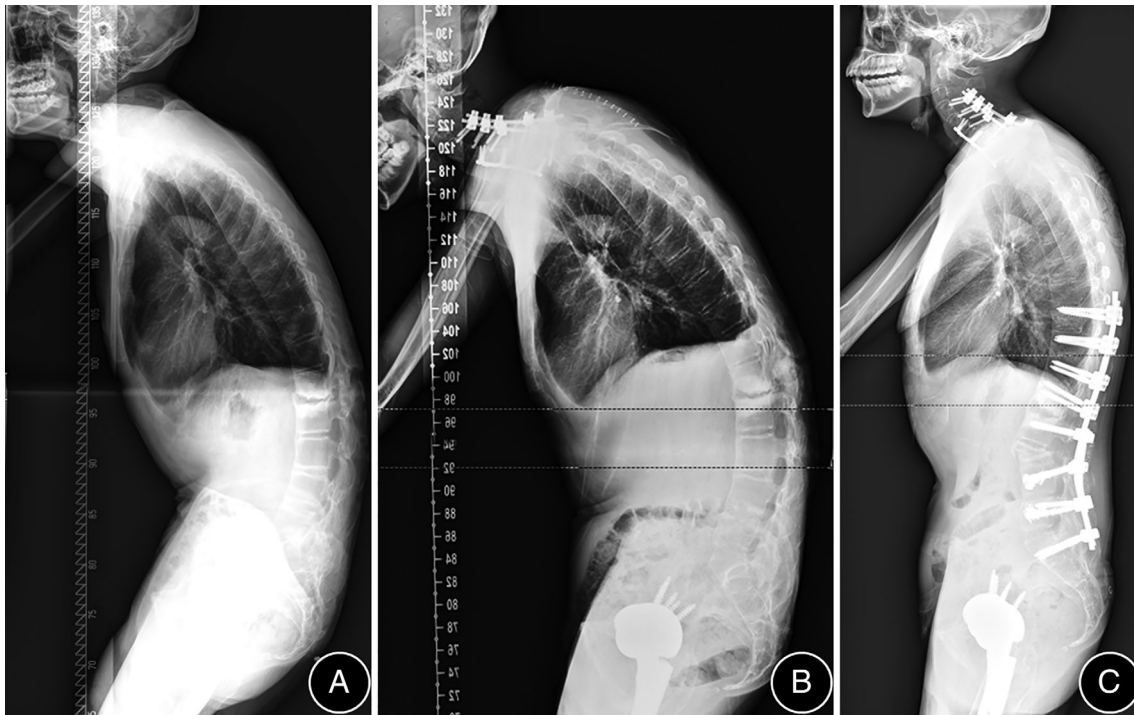


Fig. 4 The pre- and post-operative radiographs of Case Two (21-year-old male). (A) The preoperative standing lateral radiograph. (B) The 1st postoperative standing lateral radiograph. (C) The 2nd postoperative standing lateral radiograph, showing the forward gaze and sagittal alignment were both improved significantly.

of life of patients than cervical kyphotic deformity. In severe cases, cervical flexion osteotomy was required. In 2001, Sengupta *et al.*⁷ reported the first flexion osteotomy for the iatrogenic cervical extension deformity in a kyphotic AS patient. The treatment of posterior osteotomy for the thoracolumbar kyphosis altered the visual angle deviated upward. Thus, the patient underwent further cervical flexion osteotomy, and the deviated visual angle was improved significantly. Kose *et al.*⁸ reported three cases of cervical extension deformity in Becker-type muscular dystrophy. Due to spinal deformity, the patients had to keep flexion of hips and knees for compensation of global imbalance⁹. After cervical flexion osteotomy, the symptoms were improved significantly. In the present study, the cervical extension deformity in Case One was mainly attributed to the long-term bedridden and ankylosing spondylitis¹³. For Case Two, cervical extension deformity would be caused by correction of thoracolumbar kyphosis. Therefore, cervical flexion osteotomy should be followed by thoracolumbar pedicle subtraction osteotomy.

In the first case reported by Sengupta *et al.*⁷, the cervical flexion osteotomy was performed through the posterior-anterior in the lateral decubitus position. After releasing the posterior column, an anterior wedge osteotomy was performed at the C₇-T₁ level and then stabilized by the anterior locking plate. However, performing in the lateral decubitus position is unfamiliar to surgeons and technically demanding. Kose *et al.*⁸ further developed the surgical procedure through

anterior-posterior-anterior approach. Anterior closing-wedge osteotomy at C₇-T₁ was followed by a posterior osteotomy and fixation. Then, the patient was returned to the supine position, and the osteotomy site was stabilized with an anterior plate. For the anterior-posterior-anterior approach technique, the correction procedure was mainly performed in posterior approach. By exploring the anterior-posterior-anterior technique, Wang *et al.*¹⁴ also treated a thoracolumbar kyphosis with cervical extension deformity in AS with a staged osteotomy strategy. However, it was dangerous during manually closing the osteotomy wedge in the posterior procedure in anterior-posterior-anterior approach, because the osteotomized cervical spine at this moment was unstable and likely at risk of sagittal displacement. McMaster⁵ reported subluxation in four of 15 cervical osteotomy cases, and quadriplegia developed in one of them after 1 week¹⁵.

Thereafter, we changed the procedure to posterior-anterior-posterior approach technique. In this technique, the osteotomy procedure is mainly performed in anterior approach, thus we can check if there is sagittal displacement at the osteotomy site under direct visualization. Moreover, it is easier to reduce the sagittal displacement in anterior approach than in posterior approach. Meanwhile, we selected the C₇-T₁ level as the osteotomy site, as in previous studies^{7,8}. At this level, the spinal canal is relatively wide, leaving space for the cord and the C₈ nerve root; meanwhile, the vertebral arteries are not in the transverse foramina, which is an

advantage that protects against kinking or traction when closing the osteotomy wedge^{7,8}.

The major limitation of the present study was that there were only two cases included. Fewer patients limited the application of the new technique in clinic. However, the improved forward gaze and lack of complications demonstrated its safety and feasibility. A larger series should be included in future studies to investigate the outcome.

To the best of our knowledge, the present study was the first to introduce flexion osteotomy for cervical extension deformity in AS through a one-stage posterior-anterior-posterior approach. The improved forward gaze and lack of intraoperative or postoperative complications demonstrated the effectiveness and safety of the novel technique, suggesting that it could provide a more feasible method for the correction of cervical extension deformity.

References

- Mehdian S, Arun R. A safe controlled instrumented reduction technique for cervical osteotomy in ankylosing spondylitis. *Spine (Phila Pa 1976)*, 2011, 36: 715–720.
- Langeloo DD, Journee HL, Pavlov PW, de Kleuver M. Cervical osteotomy in ankylosing spondylitis: evaluation of new developments. *Eur Spine J*, 2006, 15: 493–500.
- Kim HJ, Piyaskulkaew C, Riew KD. Anterior cervical osteotomy for fixed cervical deformities. *Spine (Phila Pa 1976)*, 2014, 39: 1751–1757.
- Wollowick AL, Kelly MP, Riew KD. Pedicle subtraction osteotomy in the cervical spine. *Spine (Phila Pa 1976)*, 2012, 37: E342–E348.
- McMaster MJ. Osteotomy of the cervical spine in ankylosing spondylitis. *J Bone Joint Surg Br*, 1997, 79: 197–203.
- Simmons ED, DiStefano RJ, Zheng Y, Simmons EH. Thirty-six years experience of cervical extension osteotomy in ankylosing spondylitis: techniques and outcomes. *Spine (Phila Pa 1976)*, 2006, 31: 3006–3012.
- Sengupta DK, Khazim R, Grevitt MP, Webb JK. Flexion osteotomy of the cervical spine: a new technique for correction of iatrogenic extension deformity in ankylosing spondylitis. *Spine (Phila Pa 1976)*, 2001, 26: 1068–1072.
- Kose KC, Caliskan I, Bal E, Inanmaz ME, Isik C. C7-T1 anterior closing wedge bone-disc-bone osteotomy for the treatment of cervical hyperlordosis in muscular dystrophy: a new technique for correction of a rare deformity. *Spine (Phila Pa 1976)*, 2014, 39: E1066–E1072.
- Roussouly P, Nnadi C. Sagittal plane deformity: an overview of interpretation and management. *Eur Spine J*, 2010, 19: 1824–1836.
- Schwab F, Lafage V, Boyce R, Skalli W, Farcy JP. Gravity line analysis in adult volunteers: age-related correlation with spinal parameters, pelvic parameters, and foot position. *Spine (Phila Pa 1976)*, 2006, 31: E959–E967.
- Koller H, Koller J, Mayer M, Hempfing A, Hitzl W. Osteotomies in ankylosing spondylitis: where, how many, and how much? *Eur Spine J*, 2018, 27: 70–100.
- Mac-Thiong JM, Roussouly P, Berthonnaud E, Guigui P. Age- and sex-related variations in sagittal sacropelvic morphology and balance in asymptomatic adults. *Eur Spine J*, 2011, 20: 572–577.
- Lafage V, Schwab F, Skalli W, et al. Standing balance and sagittal plane spinal deformity: analysis of spinopelvic and gravity line parameters. *Spine (Phila Pa 1976)*, 2008, 33: 1572–1578.
- Wang T, Song D, Zheng G, Wang Y. Staged cervical osteotomy: a new strategy for correcting ankylosing spondylitis thoracolumbar kyphotic deformity with fused cervical spine. *J Orthop Surg Res*, 2019, 14: 108.
- Hoh DJ, Khoeir P, Wang MY. Management of cervical deformity in ankylosing spondylitis. *Neurosurg Focus*, 2008, 24: E9.