

<b>Access this article online</b>
Quick Response Code:

Website: www.e-tjo.org
DOI: 10.4103/tjo.tjo_25_22

# A case of aseptic bilateral cavernous sinus thrombosis following a recent inactivated SARS-CoV-2 vaccination

Syntia Nusanti<sup>1#</sup>, Ikhwanuliman Putera<sup>1#</sup>, M. Sidik<sup>1</sup>, Lukman Edwar<sup>1</sup>, Sukanto Koesnoe<sup>2</sup>, Andhika Rachman<sup>2</sup>, Mohammad Kurniawan<sup>3</sup>, Tri Juli Edi Tarigan<sup>2</sup>, Reyhan Eddy Yunus<sup>4</sup>, Indah Saraswati<sup>1</sup>, Siti Halida Zoraida Soraya<sup>1</sup>, Tiara Grevillea Pratomo<sup>1</sup>, Rina La Distia Nora<sup>1,5\*</sup>

<sup>1</sup>Department of Ophthalmology, Faculty of Medicine Universitas Indonesia - Cipto Mangunkusumo Kirana Eye Hospital, Jakarta, Indonesia, <sup>2</sup>Department of Internal Medicine, Faculty of Medicine Universitas Indonesia - Cipto Mangunkusumo General Hospital, Jakarta, Indonesia, <sup>3</sup>Department of Neurology, Faculty of Medicine Universitas Indonesia - Cipto Mangunkusumo General Hospital, Jakarta, Indonesia, <sup>4</sup>Department of Radiology, Faculty of Medicine Universitas Indonesia - Cipto Mangunkusumo General Hospital, Jakarta, Indonesia, <sup>5</sup>Department of Immunology, Erasmus Medical Center, Rotterdam, The Netherlands

<sup>#</sup>Both authors contributed equally to this work.

## \*Address for correspondence:

Dr. Rina La Distia Nora,  
Department of Ophthalmology, Faculty of Medicine Universitas Indonesia—Cipto Mangunkusumo Kirana Eye Hospital, Jl. Kimia No. 8 Menteng Central Jakarta, Jakarta, 10320, Indonesia.  
E-mail: rina.ladistia@ui.ac.id

Submission: 10-04-2022  
Accepted: 18-04-2022  
Published: 15-06-2022

## Abstract:

This case report aims to describe the first report of bilateral aseptic cavernous sinus thrombosis (CST) with a recent history of severe acute respiratory syndrome coronavirus 2 (SARS-CoV-2) vaccination. A 50-year-old woman presented with bilateral proptosis, decreased vision, and ophthalmoplegia 16 days following CoronaVac<sup>®</sup> vaccine. The visual acuity of the left eye was 20/150, while the right eye was no light perception with a hyperemic optic nerve head. She had a history of hyperthyroidism and currently on warfarin consumption. Laboratory results depicted elevated free T4, free T3, international normalized ratio, and low protein S and C. Magnetic resonance imaging showed bilateral CST, and high-dose methylprednisolone along with fondaparinux was given. The symptoms were significantly resolved, with the visual acuity of the left eye being improved to 20/20 but not the right eye. Bilateral CST has not been previously reported following inactivated SARS-CoV-2 vaccination. The underlying systemic conditions should be taken into consideration for the possibility of the inactivated SARS-CoV-2 vaccine-related event.

## Keywords:

Cavernous sinus thrombosis, hyperthyroidism, severe acute respiratory syndrome coronavirus 2, vaccines, warfarin

## Introduction

Ever since its emergence in December 2019, COVID-19 remains a challenge for clinicians and scientists worldwide. Varieties of vaccines have been developed, including CoronaVac<sup>®</sup> (Sinovac Life Sciences, Beijing, China), derived from inactivated severe acute respiratory syndrome coronavirus 2 (SARS-CoV-2). The efficacy and safety profile of the distributed vaccines have been studied, showing a well-tolerated result, and weighing more benefits than the risk.<sup>[1]</sup>

Despite its tolerability and safety, several cases of coagulopathy leading to venous thrombosis, including cerebral venous

sinus thrombosis (CVST), following COVID-19 vaccinations, have been reported, particularly due to the viral vector vaccines.<sup>[2]</sup> Even though the direct causality has not been established yet, a thorough investigation is still ongoing, and vigilance upon this should always be made. CVST might manifest as a cavernous sinus thrombosis (CST) from not only septic but also aseptic causes.<sup>[3]</sup>

To date, there is no current report of severe coagulopathy that leads to aseptic bilateral CST following inactivated SARS-CoV-2 vaccination. We aim to describe a case of a middle-aged female who developed this particular condition which might warrant further research in the future.

This is an open access journal, and articles are distributed under the terms of the Creative Commons Attribution-NonCommercial-ShareAlike 4.0 License, which allows others to remix, tweak, and build upon the work non-commercially, as long as appropriate credit is given and the new creations are licensed under the identical terms.

For reprints contact: WKHLRPMedknow\_reprints@wolterskluwer.com

**How to cite this article:** Nusanti S, Putera I, Sidik M, Edwar L, Koesnoe S, Rachman A, *et al.* A case of aseptic bilateral cavernous sinus thrombosis following a recent inactivated SARS-CoV-2 vaccination. *Taiwan J Ophthalmol* 2022;12:334-8.

## Case Report

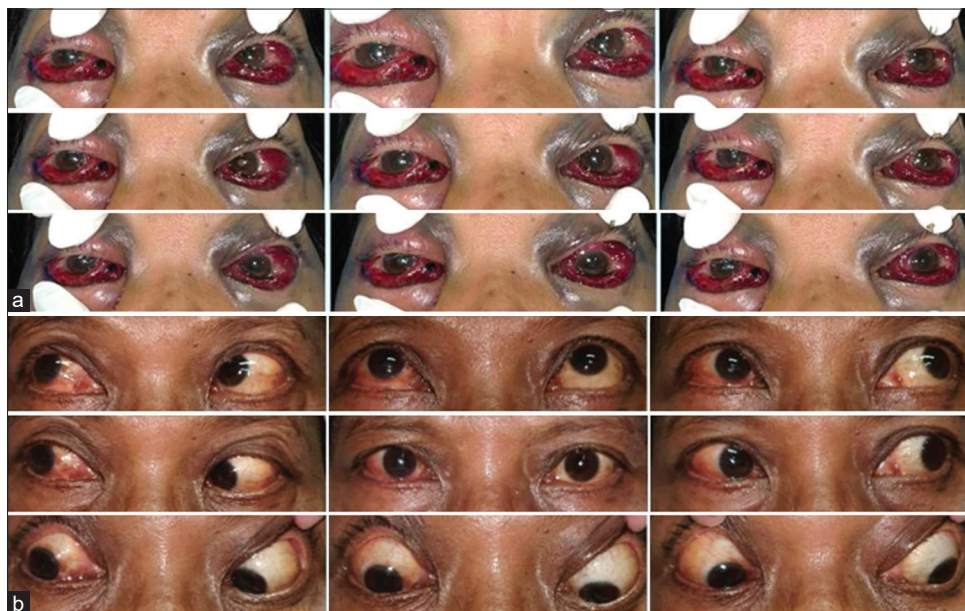A 50-year-old female patient presented to our emergency room with sudden bilateral acute proptosis along with decreased vision and ophthalmoplegia for 2 days. She was previously hospitalized for nausea and inadequate nutritional intake for 5 days before being referred to our hospital. One day before the ophthalmic symptoms occurred, the patient experienced a right-sided headache but not fever. The right eye suddenly became proptosis and totally blurred upon awakening on the following day. The left eye started to experience the same about 12 h apart, but the vision only partially blurred.

The patient has been diagnosed with Grave's disease for the last 2 years. However, the patient was reluctant to regular treatment because of an allergic response to propylthiouracil, and the thyroid hormone level was not regularly checked. The substituted prescribed drug, methimazole, was not taken regularly. Meanwhile, the patient was routinely consuming warfarin for the last 3 months due to atrial fibrillation. No prior diabetes or systemic infection was noted. Sixteen days before the ophthalmic manifestation, the patient got the first dose of CoronaVac®.

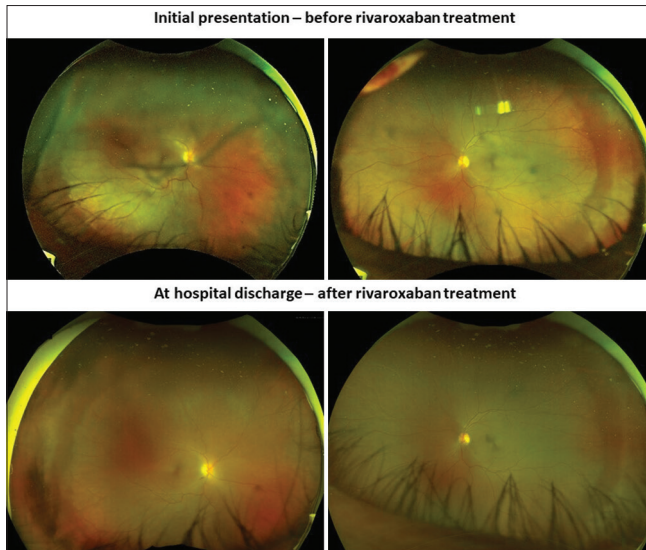
On examination, the visual acuity of the right and left eyes was no light perception and 20/150, respectively. Bilateral total ophthalmoplegia, proptosis, ptosis, and 7-mm lagophthalmos were prominent. Conjunctival chemotic with subconjunctival bleeding was also noted [Figure 1a]. A hyperemic optic nerve head was noticed on the right eye [Figure 2] without noticeable consensual reflex on the left eye. A laboratory

evaluation revealed normal leukocyte ( $8560/\mu\text{L}$ ) and thrombocyte ( $233,000/\mu\text{L}$ ) counts, elevated international normalized ratio (INR; 3.79), and slightly elevated fibrinogen ( $466.3\text{ mg/dL}$ ) with normal d-dimer ( $240\text{ }\mu\text{g/L}$ ). The hyperthyroid state revealed: elevated free T3 ( $6.19\text{ pg/mL}$ ), free T4 ( $>5.00\text{ ng/dL}$ ), and very low TSH ( $<0.003\text{ }\mu\text{IU/mL}$ ). The protein S (37%) and C (61.90%) were deficient but not antithrombin III (88.3%). Emergent contrast-enhanced brain and orbital magnetic resonance imaging (MRI) was performed. Bilateral CST with a minimal enhancement of bilateral optic nerves and posterior sclera, especially on the right side, was revealed. Besides, dilated superior ophthalmic vein caliber was more pronounced on the right side [Figure 3]. SARS-CoV-2 polymerase chain reaction test from the nasal and oropharyngeal swabs was negative.

The patient was then hospitalized and treated with fondaparinux subcutaneously once daily ( $0.1\text{ mg/kg BW}$ ) and  $1000\text{ mg/day}$  methylprednisolone intravenously for 5 days. The INR value was normalized to 1.22. Rivaroxaban  $10\text{ mg/day}$  along with oral methylprednisolone with tapered off dose was given after hospital discharge. A significant clinical improvement was seen following treatment, particularly in the resolution of ophthalmoplegia [Figure 1b]. The visual acuity of the left eye was restored to 20/20, whereas the right eye was still no light perception. Based on Humphrey's visual field 24-2 examination, an improvement was also observed (initial presentation: visual field index 91%, mean deviation  $-6.42\text{ dB}$ ; after treatment: visual field index 97%, mean deviation  $-5.93\text{ dB}$ ) [Figure 4].



**Figure 1:** The ophthalmic presentation (a) on the day of admission and (b) 2 weeks after discharge with rivaroxaban + oral methylprednisolone therapy showing ophthalmoplegia resolution

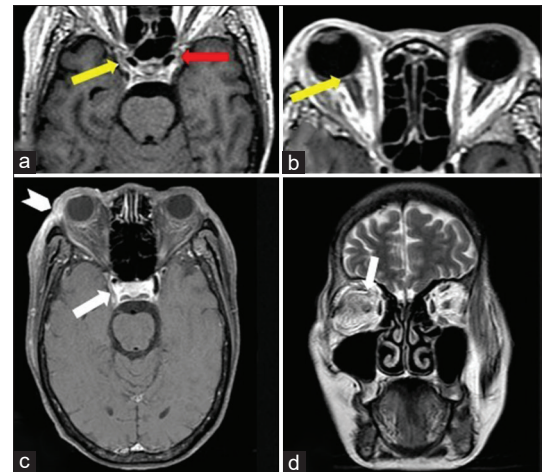


**Figure 2:** Optos® wide-field fundus photographs of both eyes. Edematous optic nerve with tortuous vein were noted on the right eye and decreased following rivaroxaban treatment. No optic nerve and retinal abnormalities noted in the left eye

## Discussion

The underlying process of aseptic CST in our case is not easy to be elucidated. However, the possible link between SARS-CoV-2 and coagulopathy has been tried to be explained elsewhere. In patients infected with SARS-CoV-2, a study showed a 4.8% rate of venous thromboembolism, whereas the mean thrombotic complication rate was 9.5%. Viral infection, including COVID-19, might possess a thrombotic risk due to injury toward the host's endothelial cells. SARS-CoV-2 invades through the angiotensin-converting enzyme (ACE)-2 receptors. The interaction between the virus and the ACE-2 receptors yields an imbalanced shift, inducing inflammation, vasoconstriction, and coagulation cascade.<sup>[4]</sup>

Although extrapolation from the hypothesized pathophysiology of coagulopathy COVID-19 is still not even close in our case, which only had a recent inactivated vaccine, several mechanisms might be of concern. In COVID-19, IL-6 was considered associated with thromboinflammation condition. This is further escalated by the hypoxic state, which promotes the thrombotic cascade through angiogenesis and apoptosis. The vascular endothelial growth factor (VEGF) activation is also known to induce prothrombotic events. VEGF itself is found to be in high amount in COVID-19 patients compared with healthy subjects. Furthermore, IL-6 and hypoxia are also responsible for protein S deficiency, which normally acts as a vital anticoagulant.<sup>[5]</sup> Besides, three proteins, VKORC1, SERPING1, and PABPC4, might affect coagulation and interact with one of the SARS proteins, ORF7a. The ORF7a-VKORC1 interaction



**Figure 3:** Orbital and brain magnetic resonance imaging: (a) bilateral cavernous sinus thrombosis (right: yellow arrow; left: red arrow), (b) enhanced right optic nerve head with contrast, (c) axial T1-weighted fat saturation postcontrast sequence showing a filling defect in the right cavernous sinus (white arrow) and periorbital soft tissue enhancement consistent for inflammation (white arrowhead), and (d) coronal T2-weighted sequence showing slight enlargement of the right superior ophthalmic vein (white arrow) and right intraorbital fat stranding

theoretically could lead to insufficient carboxylation of Vitamin K-dependent coagulation factors, which cause impairment of the host's coagulation and immune response.<sup>[6]</sup>

The earlier report of coagulopathy from the SARS-CoV-2 vaccine possesses a different feature from our case. CVST following Vaxzevria, a recombinant adenoviral vaccine, had a thrombotic with thrombocytopenia characteristic. The reported case is hypothesized of having heparin-induced thrombocytopenia, which is proved by the presence of platelet factor 4 antibodies.<sup>[7]</sup> Our report demonstrates a thrombotic event accompanied by downregulation of protein S and C in a female patient taking anticoagulant warfarin within the last 3 months. Haran *et al.* described a case of thrombosis during warfarin treatment with a significant decrease of protein S that showed improvement after its discontinuation.<sup>[8]</sup> Albeit it occurred in the arteries, while ours in the veins, it can be suggested that warfarin consumption might partially involve in the aseptic CST formation. Of note, warfarin impacts not only Vitamin-K procoagulant factors (II, VII, IX, and X) but also natural anticoagulants (protein S and C). Ideally, as happen in most patients, the effect of warfarin is remarkably more potent on procoagulants than anticoagulants. However, a minority of patients can experience an imbalance of pro- and anti-coagulants, reflected by protein S deficiency, leading to severe or recurrent thrombosis,<sup>[8,9]</sup> as happened in our case. Unfortunately, we do not have a baseline profile of protein S and C in our patient to explain the time-dependent change in protein S and C levels affected by warfarin. Still, the mechanism underlying this phenomenon has not been

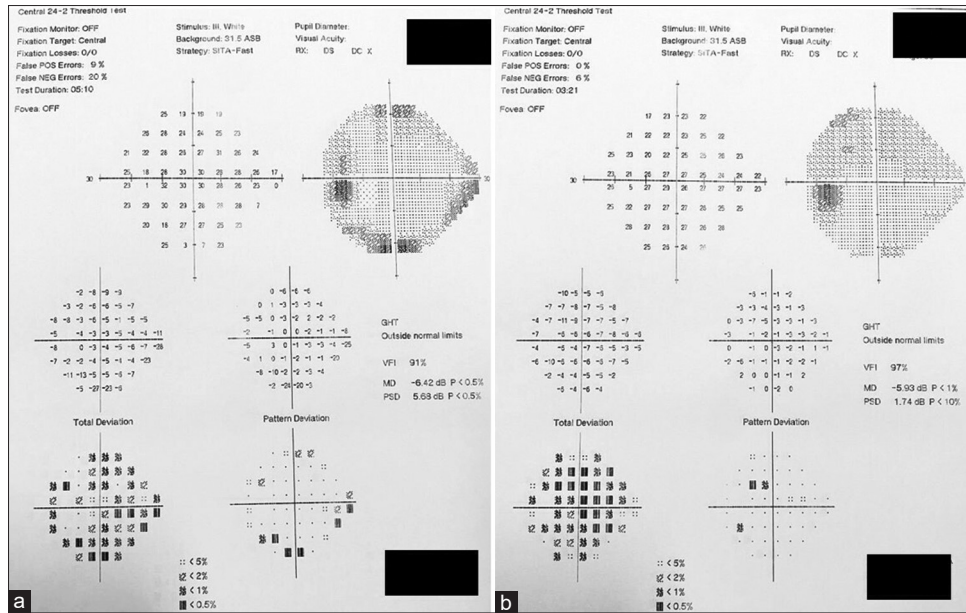


Figure 4: The improvement of visual field of the left eye from the initial presentation (a) and after therapy (b) using Humphrey's visual field 24-2 test

clearly explained but may be related to predisposed genetic susceptibility.<sup>[8,9]</sup>

Preexisting Grave's disease in our patient might also be suggested to increase the risk of a hypercoagulable state. Franchini *et al.* described that hyperthyroidism-induced venous thrombosis was more common in females, with cerebral venous being the most frequently affected site.<sup>[10]</sup> In addition, two previously healthy females were reported to develop Grave's disease as an autoimmune syndrome induced by adjuvants (ASIA) post-COVID-19 vaccination.<sup>[11]</sup> Recently, three cases of subacute thyroiditis among patients without previous history of thyroid disease following CoronaVac<sup>®</sup> have been reported and classified as ASIA.<sup>[12]</sup> The authors suggested that aluminum hydroxide as the adjuvant contained in CoronaVac<sup>®</sup> might induce this phenomenon,<sup>[12]</sup> even there are still no large data to suggest vaccine of choice for patient with coexisting thyroid disease.

To our knowledge, this is the first report describing a case of bilateral CST following inactivated SARS-CoV-2 vaccination. We do not know the precise relationship between the vaccination, the patient's underlying systemic conditions, and the occurrence of severe bilateral ophthalmic manifestation. The explanation of unrestored visual acuity in our case has not been fully identified. Although a recent report described a CST case with secondary central retinal artery occlusion,<sup>[13]</sup> we assumed that ischemic optic neuropathy is more likely to occur, given the lack of cherry-red spot appearance in our case. Ischemic optic neuropathy may complicate CST and results in permanent visual loss.<sup>[14]</sup> However, we lacked sufficient angiographic

images to support this argument. Besides, we presumed that if the hypercoagulable state was related to the recent vaccination, prolonged INR due to warfarin consumption and hyperthyroidism conditions could also lead to thrombotic events. As a direct causality is not easily elucidated, the vaccination program should be continued. However, the potency of vaccine-related events compromising ophthalmic conditions should not be overlooked.

## Conclusion

In this report, we described a case of aseptic bilateral CST with prior history of recent inactivated SARS-CoV-2 vaccination (CoronaVac<sup>®</sup>). Hypercoagulable state in this patient may be related to hyperthyroidism and prolonged INR due to warfarin consumption, resulting in protein S and C deficiency. The precise mechanism of thrombus formation was difficult to confirm. Still, there is a possibility of a vaccine-related event that leads to aseptic CST in a patient with an underlying systemic condition, as in our case.

## Declaration of patient consent

The authors certify that they have obtained all appropriate patient consent forms. In the form, the patient has given her consent for her images and other clinical information to be reported in the journal. The patient understands that name and initials will not be published and due efforts will be made to conceal identity, but anonymity cannot be guaranteed.

**Financial support and sponsorship**  
Nil.

## Conflicts of interest

The authors declare that there are no conflicts of interests of this article.

## References

1. Zhang Y, Zeng G, Pan H, Li C, Hu Y, Chu K, *et al.* Safety, tolerability, and immunogenicity of an inactivated SARS-CoV-2 vaccine in healthy adults aged 18-59 years: A randomised, double-blind, placebo-controlled, phase 1/2 clinical trial. *Lancet Infect Dis* 2021;21:181-92.
2. Merchant HA. CoViD vaccines and thrombotic events: EMA issued warning to patients and healthcare professionals. *J Pharm Policy Pract* 2021;14:32.
3. Brismar G, Brismar J. Aseptic thrombosis of orbital veins and cavernous sinus. *Clinical symptomatology. Acta Ophthalmol (Copenh)* 1977;55:9-22.
4. Goyal A, Prasad R, Goel P, Pal A, Prasad S, Rani I. An integrated approach of the potential underlying molecular mechanistic paradigms of SARS-CoV-2-mediated coagulopathy. *Indian J Clin Biochem* 2021;36:1-17.
5. Chatterjee S, Sengupta T, Majumder S, Majumder R. COVID-19: A probable role of the anticoagulant Protein S in managing COVID-19-associated coagulopathy. *Aging (Albany NY)* 2020;12:15954-61.
6. Holcomb D, Alexaki A, Hernandez N, Hunt R, Laurie K, Kames J, *et al.* Gene variants of coagulation related proteins that interact with SARS-CoV-2. *PLoS Comput Biol* 2021;17:e1008805.
7. Mehta PR, Apap Mangion S, Bengier M, Stanton BR, Czuprynska J, Arya R, *et al.* Cerebral venous sinus thrombosis and thrombocytopenia after COVID-19 vaccination-A report of two UK cases. *Brain Behav Immun* 2021;95:514-7.
8. Haran MZ, Lichman I, Berebby A, Weinmann E, Rosenberg N. Unbalanced protein S deficiency due to warfarin treatment as a possible cause for thrombosis. *Br J Haematol* 2007;139:310-1.
9. Hackeng TM, Seré KM, Tans G, Rosing J. Protein S stimulates inhibition of the tissue factor pathway by tissue factor pathway inhibitor. *Proc Natl Acad Sci U S A* 2006;103:3106-11.
10. Franchini M, Lippi G, Targher G. Hyperthyroidism and venous thrombosis: A casual or causal association? A systematic literature review. *Clin Appl Thromb Hemost* 2011;17:387-92.
11. Vera-Lastra O, Ordinola Navarro A, Cruz Domiguez MP, Medina G, Sánchez Valadez TI, Jara LJ. Two cases of Graves' disease following SARS-CoV-2 vaccination: An autoimmune/inflammatory syndrome induced by adjuvants. *Thyroid* 2021;31:1436-9.
12. İremli BG, Şendur SN, Ünlütürk U. Three cases of subacute thyroiditis following SARS-CoV-2 vaccine: Post-vaccination ASIA syndrome. *J Clin Endocrinol Metab* 2021;106:2600-05.
13. Raj A, Kaur N, Kaur N. Cavernous sinus thrombosis with central retinal artery occlusion in COVID-19: A case report and review of literature. *Indian J Ophthalmol* 2021;69:1327-9.
14. Ng EM, Othman O, Chan LY, Bahari NA. Cavernous sinus thrombosis and blindness complicating dental infection. *Cureus* 2022;14:e21318.