

CONCISE COMMUNICATION

Novel mutations in one allele in a Chinese family with neurofibromatosis type 1: Including a complex insertion–deletion mutation

Lude ZHU,¹ Lei SHI,¹ Bo WANG,² Mingye BI,³ Jie PU,³ Linglin ZHANG,¹ Yunfeng ZHANG,¹ Xiuli WANG,¹ Guolong ZHANG¹

¹Institute of Photomedicine, Shanghai Skin Disease Hospital, Tongji University School of Medicine, ²Department of Dermatology, Ruijin Hospital, Shanghai Jiaotong University School of Medicine, Shanghai, ³Department of Dermatology, Nanjing Medical University, Affiliated Wuxi People's Hospital, Wuxi, China

ABSTRACT

Neurofibromatosis type 1 (NF1) is a hereditary disease with variable clinical manifestations. This study was performed in a Chinese three-generation family containing two members with NF1. Two novel mutations, c.853_854insTC and c.1975_1976delinsTA, were identified in the same allele in both patients by direct sequencing. By reverse transcription polymerase chain reaction, we found that the *NF1* transcript contained the first mutation instead of the second mutation, suggesting a pathological role of c.853_854insTC mutation. Case reports of patients with two *NF1* mutations in the same allele have not been reported. Our findings expand the known spectrum of *NF1* mutations and the ongoing recognition of different mutations may give insight into the mysterious NF1 pathogenesis.

Key words: Chinese, deletion–insertion, mutation, neurofibromatosis type 1, *NF1*.

INTRODUCTION

Neurofibromatosis type 1 (NF1; Online Mendelian Inheritance in Man no. 162200) is a progressive hereditary disorder characterized by variable clinical manifestations.¹ NF1 is diagnosed clinically based on the clinical diagnostic criteria created by the National Institutes of Health (NIH) consensus development conference in 1987.² It is caused by mutations in the *NF1* tumor suppressor gene located at chromosome 17q11.2.³ For as yet unknown reasons, the *NF1* gene exhibits one of the highest reported mutation rates in any human disorder.⁴ Additionally, half of patients with NF1 have no family history of the disorder. Genetic analysis of *NF1* is necessary because presymptomatic molecular diagnosis and genetic counseling are feasible only when the pathogenic germ line mutation is already known.

CASE REPORT

Patients and controls

A family, comprising two NF1 patients and three unaffected individuals, and 120 ethnically matched control individuals from Jiangsu Province of China were enrolled in this study. The family had no consanguineous marriages and this was consistent with an autosomal dominant mode of inheritance of the

disease (Fig. 1). Diagnosis of NF1 was clinically based on the NIH criteria established in 1987.² Written consent was taken before recruitment and sampling. Informed written consent of minors was obtained from their guardians. The current study conformed to the tenets of the Declaration of Helsinki and was approved by the ethics committee of Shanghai Skin Disease Hospital.

Mutation sequencing and analysis

Genomic DNA was extracted from peripheral blood and used as a template for the polymerase chain reaction (PCR) amplification of all 58 exons of the *NF1* gene and flanking regions. Using human genome data, Yu *et al.*⁵ obtained the full sequence of all seven *NF1* pseudogenes which are partial duplications of the functional *NF1* gene and bear large internal deletions. Based on differences between the sequences of the *NF1* gene and its pseudogenes, specific primers were designed (Table S1) to avoid pseudogenes. Some of the PCR products were too long for DNA sequencing, and sites were selected randomly to design additional specific primers to sequence long PCR products. Moreover, nested PCR protocols were adopted to amplify authentic exon 36 in the *NF1* gene. The annealing temperature for long-range PCR primer sets was 51–64 °C. A total of 20 ng of genomic DNA was

Correspondence: Guolong Zhang, M.D., and Xiuli Wang, M.D., Ph.D., Institute of Photomedicine, Shanghai Skin Disease Hospital, Tongji University School of Medicine, 1278 Baode Road, Zhabei District, Shanghai 200443, China. Emails: zglaomu@163.com (G. Z.) and wangxiuli20150315@163.com (X. W.)

Received 21 September 2015; accepted 23 May 2016.

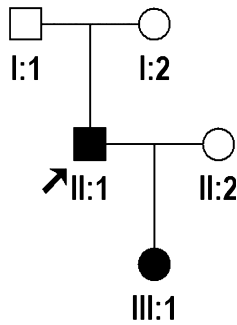


Figure 1. Pedigree of the Chinese family with neurofibromatosis type 1. In the pedigree, black squares and circles are affected males and females, respectively. White circles indicate healthy subjects. Arrow denotes proband.

amplified in a reaction volume of 20 μ L containing 0.2 U Taq, 2 mmol/L $MgCl_2$, 0.5 μ mol/L forward and reverse primers, and 200 μ mol/L deoxyribonucleotide triphosphates. Amplification conditions were as follows: 94 $^{\circ}C$ for 30 s, annealing temperature for 30 s and 72 $^{\circ}C$ for 1 min for 35 cycles. The extension for NF1-E36 was 30 s and for NF1-E55 + 56 was 2 min. PCR products were purified using a QIAquick PCR Purification Kit (Qiagen, Hilden, Germany) and were sequenced using an ABI PRISM[®] 3730 automated sequencer (Applied Biosystems, Waltham, MA, USA). Mutations were identified by comparing with

the corresponding genomic DNA reference sequence NC_000017.10. In addition, samples from unaffected parents and 120 unrelated population-match controls were sequenced for the detected mutation to exclude the possibility of polymorphisms in the *NF1* gene. In order to confirm the mutations identified in our study, reverse transcription (RT)-PCR and DNA sequencing were performed to look at the transcripts. Total RNA extraction from peripheral blood lymphocytes and RT was performed according to the manufacturers' instructions (Invitrogen [San Diego, CA, USA] and MBI Fermentas [Waltham, MA, USA]). The two pairs of cDNA primers used to amplify exons 8 and 17 are provided in Table S2. After the products were confirmed with agarose gel electrophoresis, they were purified and sequenced using dry terminator chemistry on an ABI PRISM[®] 3730 automated sequencer.

Clinical findings of the pedigree

The proband was a 38-year-old man born with café au-lait (CAL) spots without mental retardation. Axillary skin fold freckling was present at the age of 7 years. At the age of 17 years, he developed subcutaneous neurofibromas, which gradually became prominent and widespread over time (Fig. 2a,b). Another characteristic feature was a giant CAL macule of 15 cm on his right buttock (Fig. 2c). The proband's daughter was 14 months old. She was born after a normal pregnancy of 40 weeks, through an instrumented vaginal delivery with a birthweight of 3830 g . CAL spots were present on her face,

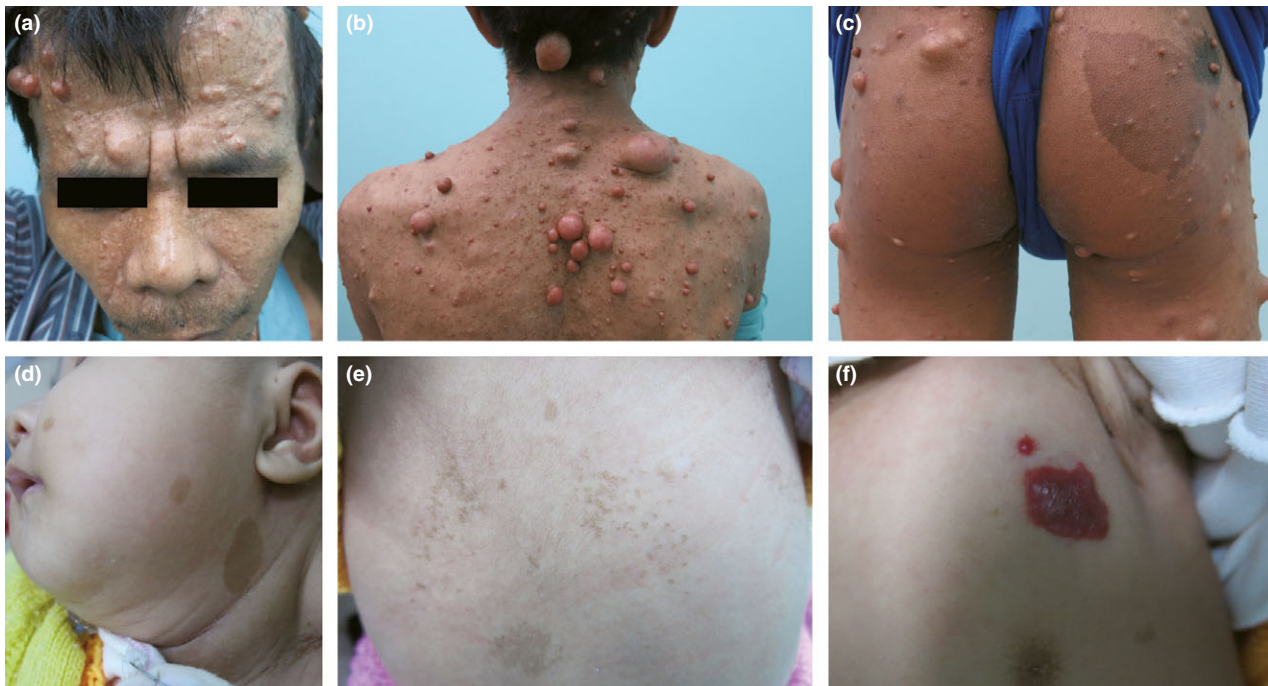

Figure 2. Clinical manifestations of patients with neurofibromatosis type 1 in the Chinese family. The 38-year-old proband of the family presented cutaneous neurofibromas on the (a) face and (b) back. (c) A giant café-au-lait (CAL) macule, with a diameter of 15 cm, on the proband's right hip. The 14-month-old girl showed CAL spots on the girl's (d) neck and (e) abdomen. (f) Hemangioma was also observed on the girl's left chest.

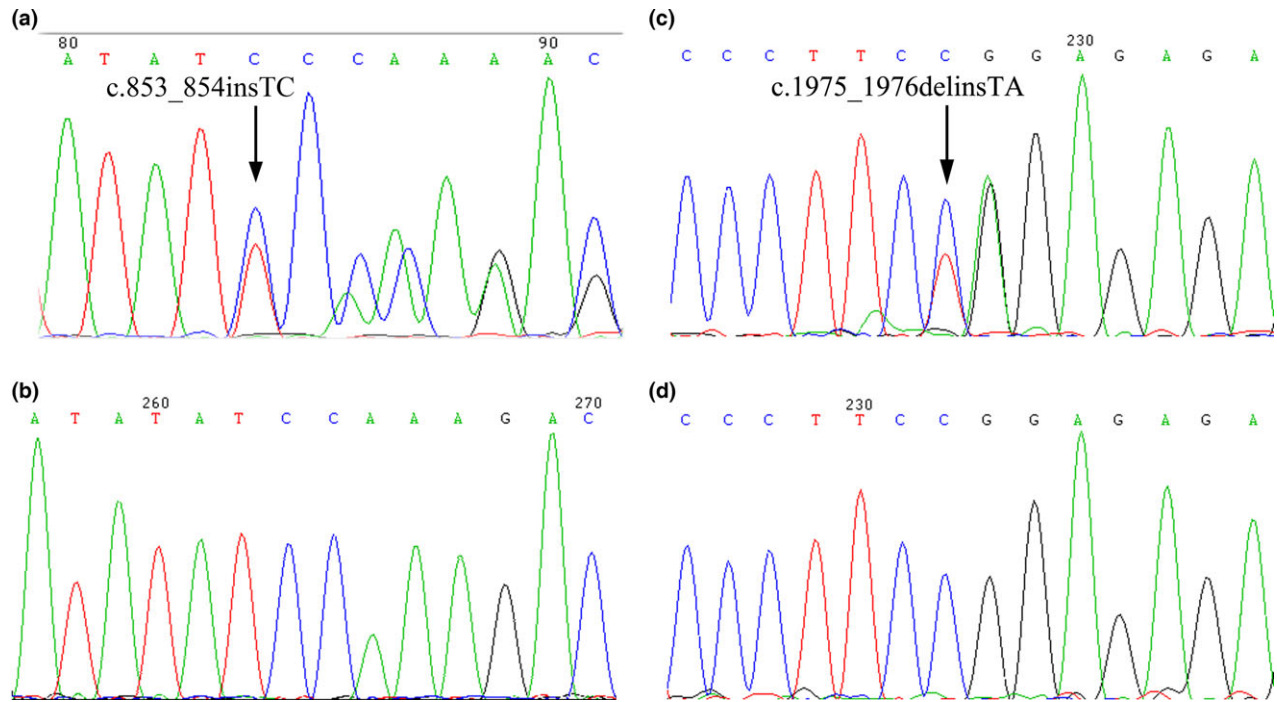


Figure 3. Sequencing results of the *NF1* gene. (a) The novel frame-shift mutation c.853_854insTC in exon 8 of the *NF1* gene (arrow) was confirmed by cDNA sequencing in the proband. (b) Wild-type sequence was from an unaffected member. (c) The novel nonsense mutation c.1975_1976delinsTA in exon 17 of the *NF1* gene (arrow) was found in the proband by direct DNA sequencing. (d) Wild-type sequence was from an unaffected member.

neck and abdomen with a diameter that varied widely from 0.5 to 3 cm (Fig. 2d,e). Hemangioma was also observed on her left chest with a diameter of approximately 2 cm (Fig. 2f). Both CAL spots and hemangioma had been present since birth. Furthermore, no neurological abnormality was observed in either patient, including a complete neurological exam, head computed tomography and brain magnetic resonance imaging.

***NF1* mutation identification and analysis**

Sequence analysis of *NF1* revealed two novel mutations, c.853_854insTC in exon 8 and c.1975_1976delinsTA in exon 17, in both patients but not in the unaffected family members (I:1, I:2 or II:2) and 120 healthy controls. Two novel mutations were in the same allele and co-segregated with disease within this family (Fig. 3).

DISCUSSION

Neurofibromatosis type 1 is an autosomal dominant inherited disease with a prevalence of 1/2500–3000 individuals.⁶ *NF1* is caused by mutations in the *NF1* gene which is located on the long arm of chromosome 17 at band 11.2 spans over 60 exons distributed over more than 300 kb.⁷

In our Chinese pedigree, two novel mutations were identified in the proband. The first mutation, c.853_854insTC in exon 8, is a frame-shift mutation that generates pre-terminating codon (PTC) at 10 codons downstream of the insertion site. The other

is a complex deletion–insertion (delins) mutation in exon 17 that leads to two continuous missense mutations and a PTC at the mutation site. Both mutations result in a truncated *NF1* protein that ensures the development of this disease. Although *NF1* is a hereditary disorder, the proband's parents did not have any phenotype. We suggest that the two mutations in the proband were spontaneous mutations. Moreover, the most striking finding was that both of the two mutations were also identified in his daughter, so we can conclude that the mutations in the girl were inherited from her father and they were in the same allele. To the best of our knowledge, case reports of patients with two *NF1* mutations in the same allele have not been reported. Also, previous published works about two mutations in one allele with other diseases are rare, except for two reports.^{8,9} So far, the mechanisms of two mutations in one allele have been unknown. In order to further confirm which one is pathogenic, RT–PCR was performed at mRNA level; the first mutation (c.853_854insTC) was detected (Fig. 3a) but the other mutation (c.1975_1976delinsTA) was not. That is to say, the mutant mRNA of the second mutation may be degraded by nonsense-mediated mRNA decay. Both pieces of evidence suggest that the c.853_854insTC mutation is pathological. Comparatively, the significance of the c.1975_1976delinsTA mutation is very limited, given no mutation-containing mRNA was identified. Further research is required to elucidate the pathogenic mechanisms of the *NF1* underlying these two mutations.

Moreover, infantile hemangiomas (IH), the most common benign vascular tumor in infancy,¹⁰ was observed in the proband's daughter. Higher risk is associated with several well-known factors, comprising female sex, prematurity, multiple gestation and white, non-Hispanic background.¹¹ So far, case reports of patients with IH with NF1 have been little reported, except for two case reports.^{12,13} So, there is no conclusive evidence that the mutation of *NF1* is sufficient to cause IH. Accordingly, we suggest that the coexistence of these two unrelated diseases is a simple coincidence more than an intrinsic mechanism, and that a large case-control study is needed to further validate.

In summary, two novel mutations, c.853_854insTC and c.1975_1976delinsTA, in the same allele in both of the patients were reported. This study described a careful analysis of the first case with two NF1 mutations on the same allele. The ongoing recognition of different mutations may give insight into the still unknown mechanisms involved in the development of NF1.

ACKNOWLEDGMENTS: We thank all members of the family for their cooperation in the study. This study was funded by grants from National Natural Science Foundation of China (no. 81201222 and 81272990).

CONFLICT OF INTEREST: None declared.

REFERENCES

- Williams VC, Lucas J, Babcock MA, Gutmann DH, Korf B, Maria BL. Neurofibromatosis type 1 revisited. *Pediatrics* 2009; **123**: 124–133.
- Stumpf DA, Alksne JF, Annegers JF *et al.* Neurofibromatosis conference statement: National Institutes of Health Consensus Development Conference. *Arch Neurol* 1988; **45**: 575–578.
- Byard RW. Forensic considerations in cases of neurofibromatosis—an overview. *J Forensic Sci* 2007; **52**: 1164–1170.
- Yohay KH. The genetic and molecular pathogenesis of NF1 and NF2. *Semin Pediatr Neurol* 2006; **13**: 21–26.
- Yu H, Zhao X, Su B *et al.* Expression of NF1 pseudogenes. *Hum Mutat* 2005; **26**: 487–488.
- Gutmann DH, Aylsworth A, Carey JC *et al.* The diagnostic evaluation and multidisciplinary management of neurofibromatosis 1 and neurofibromatosis 2. *JAMA* 1997; **278**: 51–57.
- de Goede-Bolder A, Cossen MH, Dooijes D, van den Ouweland AM, Niermeijer MF [From gene to disease; neurofibromatosis type 1]. *Ned Tijdschr Geneesk* 2001; **145**: 1736–1738.
- Xie L, Gong QH, Xie ZG *et al.* Two novel mutations of the LDL receptor gene associated with familial hypercholesterolemia in a Chinese family. *Chin Med J (Engl)* 2007; **120**: 1694–1699.
- Selvi Rani D, Nallari P, Dhandapany PS *et al.* Coexistence of Digenic mutations in both thin (TPM1) and thick (MYH7) filaments of sarcomeric genes leads to severe hypertrophic cardiomyopathy in a South Indian FHCM. *DNA Cell Biol* 2015; **34**: 350–359.
- Kilcline C, Frieden IJ. Infantile hemangiomas: how common are they? A systematic review of the medical literature. *Pediatr Dermatol* 2008; **25**: 168–173.
- Hemangioma Investigator G, Haggstrom AN, Drolet BA *et al.* Prospective study of infantile hemangiomas: demographic, prenatal, and perinatal characteristics. *J Pediatr* 2007; **150**: 291–294.
- Pascual-Castroviejo I, Cortes P, Fernandez-Cuadrado J, de la Flor-Crespo M, Pascual Pascual SI [Cutaneous haemangioma associated with a hepatic haemangioma and neurofibromatosis type 1 (NF1)]. *Rev Neurol* 2002; **34**: 652–654.
- Pascual-Castroviejo I, Parron Pajares M, Pascual-Pascual SI, Jara P, Velazquez-Fragua R. Cutaneous, mediastinal and hepatic hemangiomas in a girl followed during 12 years. *Neuropediatrics* 2011; **42**: 24–27.

SUPPORTING INFORMATION

Additional Supporting Information may be found in the online version of this article:

Table S1. DNA primers

Table S2. cDNA primers