



Case report

PJP granuloma in an Immune competent host: Case report and literature review

Chandra S. Pingili^{a,b,*}, Vel Sivapalan^{a,b,*}^a Columbia University medical center, The Affiliation at Harlem hospital, New York, USA^b Lincoln medical & mental health center, New York, USA

ARTICLE INFO

Keywords:

PJP granuloma
Non HIV patient

ABSTRACT

PJP (*Pneumocystis jirovecii*) is a fungal agent by taxonomy. Ones considered a protozoan, it is now recognized as fungi based on ribosomal RNA and other gene sequence homologies, the composition of their cell walls, and structure of key enzymes. This organism generally affects immunocompromised hosts with a CD4 count < 200 or < 15%. Review of literature does support a rare occurrence of PJP infections in immunocompetent hosts. PJP can occur at normal CD 4 levels.

Case report

53 y/o Hispanic woman was diagnosed with stage III left breast Cancer. She is now s/p chemotherapy with Paclitaxel single agent one year ago, radiation and s/p left mastectomy. She had a follow up screening CT chest that suggested new Left upper lobe nodules (LUL).

A recent MRI revealed 2 new nodules of the left breast. This prompted the oncologist to get a repeat chest CT. There was new LUL nodule, > 1 cm not seen in previous study-last done approximately 9 months prior to current presentation (Fig. 1). These lesions were surprisingly a new finding on the new imaging. The Patient however was asymptomatic. She denied any SOB, cough, fever, night sweats, chills, hemoptysis, weight loss or any other complaints. There was no recent travel or exposure to sick contacts and there is no history of exposure to tuberculosis. Her past medical history is notable only for pulmonary embolism, hypertension and breast cancer.

On physical exam she was afebrile, blood pressure was 120/76, and pulse of 78 regular, respirations of 18 with 98% oxygen saturations on room air. Her physical examination was unremarkable except for left mastectomy scar with no signs of infection or inflammation. She did not have oral thrush, lymphadenopathy, and rash and there was no visceromegaly.

Labs – please see Table 1. CT chest suggested multiple small nodules measuring up to 1.1 cm in the left upper lobe, not seen in previous study (Fig. 1). A PET scan revealed activity of new conglomerate of LUL lung nodules which may represent metastatic disease. Patient underwent Video-assisted thoracoscopic surgery (VATS) with wedge resection of the nodules. Pathological examination shows Well circumscribed fibro-caseous lesions with central core of necrotic material

surrounded by palisading rim of epithelioid histiocytes and multinucleated giant cells consistent with necrotizing granulomas. AFB stain and gram stain was negative. Biospy of the nodules were negative for malignancy. Silver methanamine stain was positive for PJP. This was confirmed with immunohistochemistry. Her HIV antibody test was negative and so was her HIV PCR. Her cd 4 count was 648. She was treated with Trimethoprim-sulfamethoxazole DS 2 pills twice a day for 2 weeks. She remained asymptomatic throughout her clinical course.

Discussion

PJP is an opportunistic pathogen affecting cellular immunocompromised hosts. It generally affects patients with CD4 count < 200 [1]. *Pneumocystis* is transmitted by the airborne route. Acquisition of new infections in humans is most likely by person-to-person spread. Individuals with normal immune systems may have asymptomatic lung colonization and may serve as a reservoir for spread of *Pneumocystis* to immunocompromised hosts [2]. PJP has been documented in non HIV hosts too. Patients on long term steroid suppression are at a high risk of developing PJP infections. This group of patients are next in the list after patients with AIDS defining illness [3]. 16–25 mg of prednisolone per day or ≥ 4 mg dexamethasone daily for ≥ 4 weeks are at risk [4]. Patients with underlying malignancies receiving chemotherapy and biological agents are at a risk of developing PJP infections if they are not on appropriate prophylaxis. Hematological malignancies lead the list. Allogenic stem cell transplant patients are at a higher risk of PJP infections compared to autologous transplants [4]. Organ transplant patients, patients with underlying immunological or rheumatological problems receiving immune modulation therapy are

* Correspondence to: Department of medicine, Div of infectious diseases, 506, Lenox avenue, Room 3101 A. New York city, Ny 10037, USA.
E-mail addresses: hospitalist10@gmail.com (C.S. Pingili), VS10@COLUMBIA.EDU (V. Sivapalan).

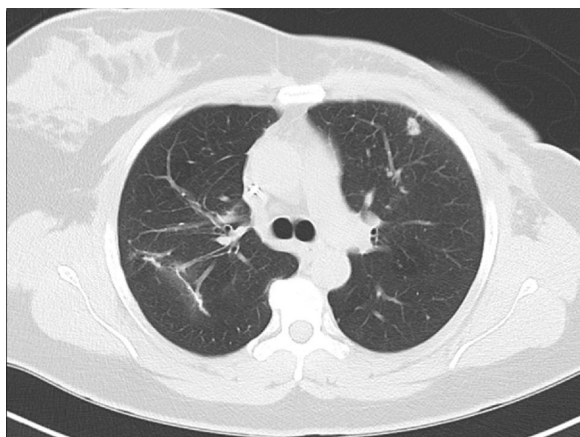


Fig. 1. XXX.

Table 1
Laboratory information at admission.

WBC	3.6	143	NA
HB	12.2	4.5	K
HCT	37	105	CL
PLT	290	28	CO2
PMN	44	13	BUN
LYMPHOCYTES	39	0.7	Cr
EOSINOPHILS	4	9.6	Ca
LDH	100	25	AST
ALB	4	40	ALT
T BILIRUBIN	0.7	71	ALK
Quantiferon	Negative	Negative	PPD
AFB stain	Negative	Negative	Gram stain
AFB culture	Negative		

Table 2
Definitive and Probable causes of PJP infection.

Patients with AIDS defining illness
Hematological malignancies like ALL,AML,all Allogenic HSCT, all children and selected high risk adults with autologous HSCT, Methotrexate, R-CHOP regimen, Lymphocyte depleting agents (qualitative and quantitative)
use of > 16 mg prednisolone or > = 4 mg dexamethasone for > = 4 weeks
Use of Temozolomide for glioblastoma multiforme
FCR (fludarabine, cyclophosphamide, rituximab)
AVBD (Adriamycin, Vincristine, Bleomycin, Dexamethasone)
Gemcitabine
Polymyositis, Dermatomyositis,SLE and Vasculopathies
Organ transplant patients

also at risk of developing PJP infections if they are not on prophylactic drugs. Polymyositis, dermatomyositis, SLE and vasculopathies all increase the risk of PJP infections when patients are managed with immunosuppressant or immune modulating agents [5–8].

Patients receiving R-CHOP14 (Rituximab, Cyclophosphamide, Adriamycin, Vincristine, Prednisolone chemotherapy on a 14-day cycle), FCR (Fludarabine, Cyclophosphamide, Rituximab), AVBD (Adriamycin, vincristine, bleomycin, dexamethasone), Gemcitabine and high-dose methotrexate all at a moderate risk of developing PJP infections. T cell blockers and depleting agents carry the highest risk for PJP infections [4]. Please see Table 2.

Fever, dyspnea with oxygen desaturation is the usual presentation. Presentation is more severe in the non HIV group of patients despite having a less biological burden with PJP. Chest x ray usually shows nonspecific infiltrates. Serum LDH is usually elevated. Non HIV individuals have a higher mortality compared to HIV individuals [4,12]. Diagnosis of PJP is generally based on suspicion from history and

physical exam. Respiratory fluids can be stained to recognize the two forms of the organism, trophozoite and cyst forms. Methenamine silver and toluidine blue preparations stain only the cyst wall and do not allow detection of trophozoites. However, Giemsa stains detect all life stages of PJP. Direct and indirect immunofluorescent assays (DFA, IFA) are specific for different life stages; depending on the antibody used. Comparative studies have shown DFA and IFA to be the most sensitive stains for *P. jirovecii* in sputum and bronchoalveolar lavage, with sensitivities of 97% and 90% respectively. PCR can replace staining studies. A meta-analysis of PCR studies has shown a pooled sensitivity of 99% and specificity of 92% in the non-HIV patient population [4,9,10]. However PCR has high negative predictive value and is reserved to rule out infection.

QPCR is quantitative PCR assay targeting the mitochondrial large subunit rRNA gene. This has been used to differentiate between active infection and colonizers with variable results but a combined qPCR in the BAL fluid {Broncho alveolar lavage} and Serum (1–3)–D-Glucan greatly enhanced the sensitivity and specificity of the study [11].

Beta-D-glucan is a cell wall component of PJP. Beta-D-glucan assays can be used to diagnose PJP infection given its high sensitivity and specificity. However Beta –D –Glucan can be elevated with invasive Aspergillosis, Candidiasis, Hemodialysis with cellulose membranes, intravenous immunoglobulin, albumin, gauze packing of serosal surfaces, Intravenous amoxicillin-clavulanic acid, Piperacillin tazobactam and infections with certain bacteria that contain cellular beta-glucans, such as *Pseudomonas aeruginosa* [12,13].

Trimethoprim-sulfamethoxazole (BACTRIM) combined with steroids in a severe and moderate to severe case is the drug of choice. Bactrim also is the drug of choice for prevention. For patients with sulfonamide allergy, Atovaquone, Dapsone and Pentamidine offer suitable alternative prophylactic regimens. Dapsone is also a sulfonamides derivative and is contraindicated in patients with severe sulfa allergy and in patients with Glucose-6-phosphate dehydrogenase (G6PD) deficiency.

Granulomatous PJP is a very rare presentation. Approximately 16 cases have been reported among patients with malignancy. Commonly reported as solitary or up to 3 nodules. Most of them were either on steroids or had underlying hematological malignancies and were on chemotherapy [14–17].

Conclusion

PJP granulomatous lesions are very rare clinical presentations. Normal human lung can act as a reservoir with colonization for PJP. When the cellular immune system is depressed, PJP can manifest as a full blown illness or a walled off granuloma as here.

References

- [1] Sepkowitz KA. Opportunistic infections in patients with and patients without acquired immunodeficiency syndrome. Clin. Infect Dis. 2002. Memorial Sloan-Kettering Cancer Center, New York, NY, 10021, USA.
- [2] Ponce CA, Gallo M, Bustamante R, Vargas SL. Pneumocystis colonization is highly prevalent in the autopsied lungs of the general population. Clin. Infect Dis. 2010;50(3):347.
- [3] Pneumocystis pneumonia in a non-HIV patient on chronic corticosteroid therapy. a question of prophylaxis. BMJ Case Rep. 2013. <http://dx.doi.org/10.1136/bcr-2012-007912>. bcr2012007912. Published online Mar 1 2013 PMID: PMC3618766.
- [4] www.mycology.adelaide.edu.au/docs/cooley-2014-anzjm.pdf.
- [5] Update on pulmonary pneumocystis jirovecii infection in non-HIV patients. Med. Mal. Infect 2014;44(May (5)):185–98. <http://dx.doi.org/10.1016/j.medmal.2014.01.007>. Epub 2014 Mar 11.
- [6] Pneumocystis jirovecii pneumonia in non-HIV-infected patients in the era of novel immunosuppressive therapies. J. Infect Chemother 2012;18(December (6)):793–806. <http://dx.doi.org/10.1007/s10156-012-0453-0>. Epub 2012 Aug 6.
- [7] Martin-Garrido I, Carmona EM, Specks U, Limper AH pneumocystis pneumonia in patients treated with rituximab. Chest 2013;144(1):258.
- [8] Kadoya A, Okada J, Iikuni Y, Kondo H. Risk factors for pneumocystis carinii pneumonia in patients with polymyositis/dermatomyositis or systemic lupus erythematosus. J. Rheumatol. 1996;23(7):1186.
- [9] Tasaka S, Hasegawa N, Kobayashi S, Yamada W, Nishimura T, Takeuchi T, et al.

- Serum indicators for the diagnosis of pneumocystis pneumonia. *Chest* 2007;31(4):1173.
- [10] Evaluation of PCR in broncho alveolar lavage fluid for diagnosis of pneumocystis jirovecii pneumonia: a bivariate meta-analysis and systematic review. *PLoS One* 2013;8(September 4(9)):e73099. <http://dx.doi.org/10.1371/journal.pone.0073099>. eCollection 2013.
- [11] Combined quantification of pulmonary pneumocystis jirovecii DNA and serum (1 - > 3)- β -D-glucan for differential diagnosis of pneumocystis pneumonia and pneumocystis colonization. *J. Clin. Microbiol.* 2013;51(October (10)):3380–8. <http://dx.doi.org/10.1128/JCM.01554-13>. Epub 2013 Jul 31.
- [12] *Pseudomonas aeruginosa* as a cause of 1, 3-beta-D-glucan assay reactivity. *Clin. Infect Dis.* 2008;46(January 15 (12)):1930–1 10.1086/588563.
- [13] Non-culture-based diagnostics for opportunistic fungi. *Infect Dis. Clin. North Am.* 2006;20(September 3):711–27. viii.
- [14] Prognostic factors for severe pneumocystis jirovecii pneumonia of non-HIV patients in intensive care unit. a bicentric retrospective study. *BMC Infect Dis.* 2016;16(528). <http://dx.doi.org/10.1186/s12879-016-1855-X>. Published online 2016 Sep 29. PMID: PMC5041573.
- [15] Granulomatous PJP presenting as a solitary lung nodule in an immune competent female. *Respir Med. Case Rep.* 2014;11:4–6. <http://dx.doi.org/10.1016/j.rmcr.2013.10.002>. Published online 2013 Oct 26. PMID: PMC3969607.
- [16] *Pneumocystis jirovecii* genotypes and granulomatous pneumocystis. *Med. Mal. Infect* 2006;36(April (4)):229–31. Epub 2006 Mar 31.
- [17] Single nodular opacity of granulomatous pneumocystis jirovecii pneumonia in an asymptomatic lymphoma patient korean. *J. Radiol.* 2015;16(March–April (2)):440–3. <http://dx.doi.org/10.3348/kjr.2015.16.2.440>. Published online 2015 Feb 27. PMID: PMC4347280.