


# A case report of anxiety disorder preceding frontotemporal dementia with asymmetric right temporal lobe atrophy

SAGE Open Medical Case Reports  
2: 2050313X13519977  
© The Author(s) 2014  
Reprints and permissions:  
sagepub.co.uk/journalsPermissions.nav  
DOI: 10.1177/2050313X13519977  
sco.sagepub.com  


**Gediminas Gliebus**

## Abstract

Behavioral variant frontotemporal dementia presents with progressive loss of social skills and cognition and is usually associated with asymmetric frontal or temporal lobe involvement. This article reports about a patient with a long history of anxiety disorder who later proceeded to develop behavioral variant frontotemporal dementia. Further discussion about selective specific network vulnerability and a possible link between these two conditions is provided.

## Keywords

Frontotemporal dementia, anxiety disorder, right temporal lobe atrophy, selective vulnerability, neurodegeneration

Date Received 7 November 2013; accepted: 18 December 2013

Frontotemporal dementia (FTD) is the second most common neurodegenerative dementia occurring in adults younger than 60 years.<sup>1</sup> Behavioral variant frontotemporal dementia (bvFTD) is used to describe a progressive condition primarily presenting with changes in behavior, loss of higher social skills and emotional perception among other symptoms. Anatomically, FTD can present with either frontal or temporal lobe atrophy, though the initial disease process probably starts in the anterior cingulate and insular regions.<sup>2</sup>

bvFTD could be difficult to diagnose initially due to symptoms being subtle and lack of objective findings on neuropsychological testing. Sometimes, the disease can present with mood or psychotic symptoms, prompting diagnosis of psychiatric disease.

The underlying pathology for this clinical syndrome is not uniform and is associated with changes in tau, transactive response (TAR) DNA-binding protein 43 or fused in sarcoma proteins.<sup>3</sup>

Anxiety symptoms are common in patient with dementia with some studies estimating the prevalence up to 70%.<sup>4</sup> There are no data available as to whether anxiety disorder is more common in a population which would develop dementia in the future, more specifically behavioral variant FTD.

This report presents a case of a middle-aged woman who was battling anxiety spectrum disorders for many years before developing and being diagnosed with bvFTD.

## Case report

A 51-year-old right-handed female presented to cognitive clinic for evaluation of worsening psychiatric and behavioral symptoms. The patient was receiving psychiatric care for generalized anxiety and obsessive compulsive disorders since her early 20s. The main symptoms of her initial conditions included significant anxiety and intermittent preoccupations with repetitive behaviors. None of these symptoms interfered with her daily living and functioning. The patient's family reports that despite psychiatric symptoms, she had no problems with memory, social judgment or functioning at home or outside the house. Historically, the patient required multiple psychiatric medications to manage her symptoms, but reported poor response to treatment. At some point, the patient became addicted to alprazolam and alcohol, requiring admission to inpatient alcohol rehabilitation facility. The patient did not use any substances for 8 years prior to presenting to our clinic.

The patient's husband reports significant changes in her behavior 1 year prior to our evaluation. The patient started

---

Alzheimer's Disease and Cognitive Neurology Center, Capital Institute for Neurosciences, Pennington, NJ, USA

### Corresponding Author:

Gediminas Gliebus, Alzheimer's Disease and Cognitive Neurology Center, Capital Institute for Neurosciences, Two Capital Way, Suite 456, Pennington, NJ 08534, USA.  
Email: ggliebus@capitalhealth.org

withdrawing from her usual activities, displaying inappropriate behaviors, using foul language and making tactless comments. She started showing psychomotor hyperactivity with frequent pacing. It was becoming more obvious that the patient's empathy is deteriorating, and the patient was becoming more self-centered. She also became preoccupied with her looks, at the same time developing marked deterioration in her personal hygiene. Her attention span and immediate memory were worsening: she was not able to multitask or pay attention to more than one subject at a time. The patient also intermittently started getting lost in a familiar environment. There were no face or object recognition deficits reported. There were no symptoms of eating disorders or changes in food preference reported. The patient's husband denied balance impairment.

Examination demonstrated a poorly kempt woman. She was very frustrated about being at the doctor's office. Her insight and judgment were very limited. She was frequently losing the track of thought, and her speech would become tangential. The patient displayed verbal perseverations, confabulations, mild intermittent word-finding deficits and rare semantic paraphasias. The patient made several inappropriate comments and displayed episodic memory impairment, which would improve with cueing. There were no recognition deficits. Neurological examination demonstrated full eye movements, normal muscle tone and strength and preserved normal deep tendon reflexes. There were no asymmetric sensory findings, tremor or ataxia.

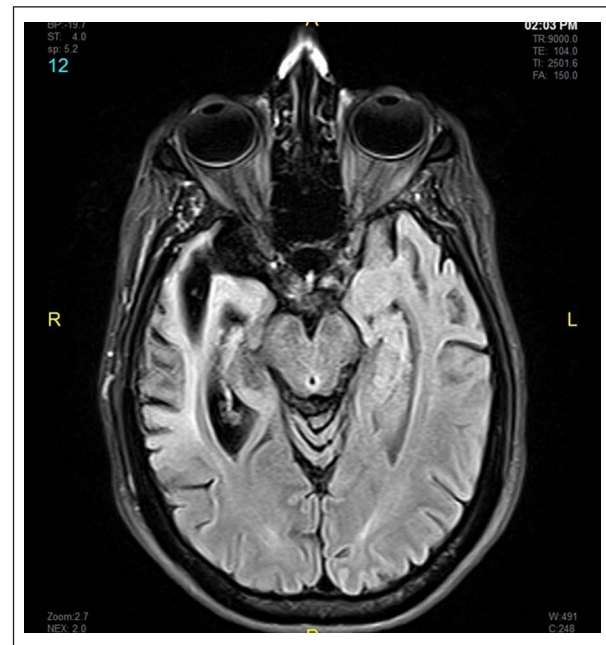Magnetic resonance imaging (MRI) of the brain demonstrated significant asymmetric right hemisphere atrophy, mostly involving the anterior right temporal lobe (Figure 1).

The diagnosis of behavioral variant FTD was made based on 2011 clinical criteria.<sup>5</sup> There was no neuropathological diagnosis available for this patient at the time of this report.

## Discussion

The issue of selective vulnerability was raised in the past, trying to explain why certain networks are more vulnerable to the neurodegenerative process, and why the same pathological process presents with different clinical presentation in different people. Understanding this could bring more insight into why neurodegenerative process affects certain networks in the initial disease stages.<sup>2</sup> This also could help to determine whether there are any specific clinical symptoms or conditions which could point to certain "weak" brain network, thus predicting the risk of certain neurodegenerative conditions.

Rogalski et al.<sup>6</sup> has identified several factors which could possibly contribute to selective vulnerability of the language network for future developing progressive language impairment, including genetic, developmental and acquired factors, while learning disability could possibly serve as a marker of biological weakness—increased susceptibility for the condition.<sup>7</sup> Primary progressive aphasia is sharing much



**Figure 1.** Brain magnetic resonance image fluid attenuated inversion recovery sequence axial image demonstrating asymmetric brain atrophy with right temporal lobe predominance.

of the same underlying neuropathology with bvFTD, raising the question whether there are any conditions which could serve as biological markers of "weak" brain network(s) in the latter condition predisposing future neurodegeneration.

bvFTD was described in patients with predominantly frontal or anterior temporal lobe involvement. FTD with predominant right temporal lobe involvement may present with psychiatric symptoms, including anxiety and mood disorders, and behavioral impairment.<sup>8</sup> Right temporal variant FTD can present with either impaired behavior or loss of semantic knowledge and recognition.<sup>9</sup> Most of the cases report psychiatric symptoms at the onset of the disease.

Functional imaging studies demonstrated that orbitofrontal, anterior cingulate, prefrontal regions and caudate nucleus are implicated in anxiety and obsessive compulsive disorders.<sup>10</sup>

The cortical regions mentioned also correspond to the regions which are implicated in the initial stages of FTD,<sup>2</sup> with right-sided predominance.<sup>11</sup> This case report demonstrated a patient with a long history of psychiatric diseases who then proceeded to develop asymmetric atrophy of the right temporal lobe with associated cognitive decline. Looking retrospectively, it is almost impossible to say at what stage the neurodegenerative condition started. It also raises the question whether anxiety disorder signifies selective vulnerability or prodromal stages of bvFTD.

While the clinical presentation depends on which network is involved rather than underlying pathology,<sup>12</sup> the available data suggest that networks involving the right temporal lobe

primarily presenting with behavioral disturbances are being preferentially affected by tau proteinopathies in FTD spectrum disorders.<sup>13</sup> The tissue diagnosis is not available for this patient at the time of this case report.

This case raises the question whether pre-existing psychiatric disorders could signify a vulnerable network which later is the first one to be affected in the neurodegenerative process—in this case, FTD, and might serve as a surrogate biological marker for it—or whether it could signify a prodromal stage of bvFTD.

The importance of cautious re-evaluation of patients with psychiatric diseases and paying attention to their behavioral and cognitive symptoms, especially if the symptoms are resistant to established treatment, is highlighted in this case report.

This report raises several important questions and opens another area for investigation, looking at whether a mental disorder might be a precursor or a prodromal stage to developing FTD, and giving a deeper understanding of the biology of both. There is no epidemiological data available to date looking into whether this connection could exist, and future studies are warranted to explore this possibility.

#### Declaration of conflicting interests

The author has reported no conflicts of interest.

#### Funding

This research received no specific grant from any funding agency in the public, commercial or not-for-profit sectors.

#### References

1. Rabinovici GD and Miller BL. Frontotemporal lobar degeneration: epidemiology, pathophysiology, diagnosis and management. *CNS Drugs* 2010; 24(5): 375–398.
2. Seeley WW. Selective functional, regional, and neuronal vulnerability in frontotemporal dementia. *Curr Opin Neurol* 2008; 21(6): 701–707.
3. Mackenzie IR, Neumann M, Bigio EH, et al. Nomenclature and nosology for neuropathologic subtypes of frontotemporal lobar degeneration: an update. *Acta Neuropathol* 2010; 119(1): 1–4.
4. Teri L, Ferretti EF, Gibbons LE, et al. Anxiety and Alzheimer's disease: prevalence and comorbidity. *J Gerontol A: Biol* 1999; 54(7): M348–M352.
5. Rascofsky K, Hodges JR, Knopman D, et al. Sensitivity of revised diagnostic criteria for the behavioural variant of frontotemporal dementia. *Brain* 2011; 134: 2456–2477.
6. Rogalski E, Weintraub S and Mesulam MM. Are there susceptibility factors for primary progressive aphasia? *Brain Lang* 2013; 127: 135–138.
7. Rogalski E, Johnson N, Weintraub S, et al. Increased frequency of learning disability in patients with primary progressive aphasia and their first-degree relatives. *Arch Neurol* 2008; 65(2): 244–248.
8. Mendez MF, McMurtry A, Chen AK, et al. Functional neuroimaging and presenting psychiatric features in frontotemporal dementia. *J Neurol Neurosurg Ps* 2006; 77(1): 4–7.
9. Chan D, Anderson V, Pijnenburg Y, et al. The clinical profile of right temporal lobe atrophy. *Brain* 2009; 132: 1287–1298.
10. Del Casale A, Kotzalidis GD, Rapinesi C, et al. Functional neuroimaging in obsessive-compulsive disorder. *Neuropsychobiology* 2011; 64(2): 61–85.
11. Liu W, Miller BL, Kramer JH, et al. Behavioral disorders in the frontal and temporal variants of frontotemporal dementia. *Neurology* 2004; 62(5): 742–748.
12. Weintraub S and Mesulam M. With or without FUS, it is the anatomy that dictates the dementia phenotype. *Brain* 2009; 132: 2906–2908.
13. Josephs KA, Whitwell JI, Knopman DS, et al. Two distinct subtypes or right temporal variant frontotemporal dementia. *Neurology* 2009; 73(18): 1443–1450.