

Available online at www.sciencedirect.com

ScienceDirect

journal homepage: www.elsevier.com/locate/radcr

Case Report

4D-flow MRI assessment of blood flow before and after endovascular intervention in a patient with pulmonary hypertension due to isolated pulmonary artery involvement in large vessel vasculitis

Hiroki Kamada, MD, PhD^{a,*}, Hideki Ota, MD, PhD^a, Tatsuo Aoki, MD, PhD^b, Koichiro Sugimura, MD, PhD^b, Nobuhiro Yaoita, MD, PhD^b, Hiroaki Shimokawa, MD, PhD, FJCC^b, Kei Takase, MD, PhD^a

^a Department of Diagnostic Radiology, Tohoku University Hospital, Tohoku University Hospital, 1-1, Seiryomachi, Aoba-ku, Sendai 980-8574, Japan

^b Department of Cardiovascular Medicine, Tohoku University Graduate School of Medicine, Sendai, Japan

ARTICLE INFO

Article history:

Received 27 October 2019

Accepted 24 November 2019

Keywords:

Pulmonary hypertension

Takayasu's arteritis

Three-dimensional phase-contrast magnetic resonance imaging (4D-flow MRI)

Endovascular intervention

ABSTRACT

A 43-year-old woman presented with dyspnea during exertion and lower leg edema. Contrast-enhanced computed tomography images demonstrated extensive proximal narrowing in the right main pulmonary artery with thickening and enhancement. Right heart catheterization revealed the presence of precapillary pulmonary hypertension with a mean pulmonary arterial pressure of 45 mm Hg. The patient was diagnosed with large-vessel vasculitis with isolated pulmonary artery involvement. Takayasu's arteritis was suspected, but histological examination was not performed. Several sessions of pulmonary arterial intervention were stratified for the right main pulmonary artery. After treatment, mean pulmonary arterial pressure had decreased to 22 mm Hg with improvement in symptoms. Thoracic 4D-flow magnetic resonance imaging was performed before and after intervention to evaluate the volume flow rates of pulmonary arteries. The rates increased at the inlet of the right pulmonary artery (before: 23 mL/s vs after: 47.5 mL/s) and the main pulmonary artery (before: 71.2 mL/s vs after: 82.5 mL/s), and decreased at the inlet of the left pulmonary artery (before: 46.2 mL/s vs after: 31.7 mL/s). The split ratio of volume flow rate between the right and left pulmonary arteries improved after treatment (before: right:left = 33.1:66.9; after: right:left = 60.0:40.0), approaching normal values. This report quantitatively describes perioperative hemodynamic changes in a patient with pulmonary hypertension using 4D-flow

Funding: This research was supported by JSPS KAKENHI grant numbers JP17K16414, JP16K10265.

Declaration of Competing Interest: None.

* Corresponding author.

E-mail addresses: hiroki@pfs1.mech.tohoku.ac.jp, hkamada@rad.med.tohoku.ac.jp (H. Kamada).

<https://doi.org/10.1016/j.radcr.2019.11.019>

1930-0433/© 2019 The Authors. Published by Elsevier Inc. on behalf of University of Washington. This is an open access article under the CC BY-NC-ND license. (<http://creativecommons.org/licenses/by-nc-nd/4.0/>)

magnetic resonance imaging. Stent placement for stenosis in the right pulmonary artery resulted in an increase in overall pulmonary blood flow and also improved blood flow balance between the right and the left pulmonary arteries.

© 2019 The Authors. Published by Elsevier Inc. on behalf of University of Washington.

This is an open access article under the CC BY-NC-ND license.

(<http://creativecommons.org/licenses/by-nc-nd/4.0/>)

Introduction

Pulmonary hypertension (PH) is defined as elevated mean pulmonary arterial pressure (PAP) > 25 mm Hg, measured via invasive right heart catheterization. Among the various etiologies of PH, PH caused by steno-occlusive lesions in the central part of pulmonary arteries can be treated with surgical and/or endovascular interventions. However, the evaluation of peritreatment hemodynamic changes in pulmonary arteries is not well-established. Transthoracic echocardiography is a common noninvasive tool for assessing PH. However, it cannot simultaneously depict blood flow in all pulmonary arteries due to its limited acoustic window. Three-dimensional phase-contrast magnetic resonance imaging (4D-flow MRI) is a less-invasive imaging procedure developed for the quantitative evaluation of blood flow through the heart and large vessels during cardiac cycles [1–6]. We investigated perioperative hemodynamic changes in a patient with PH using 4D-flow MRI.

Case presentation

A 43-year-old woman presented with a 5-month history of dyspnea during exertion and lower leg edema. Blood analyses demonstrated slight elevation of C-reactive protein levels. Contrast-enhanced computed tomography (CT) images demonstrated extensive proximal narrowing in the right main pulmonary artery, thickened walls with enhancement, and multiple steno-occlusions in the peripheral pulmonary arteries, as shown in Fig. 1. However, there was no evidence of involvement of the aorta or its major branches. Initial ¹⁸F-fluorodeoxyglucose (FDG) positron emission tomography/CT demonstrated FDG uptake in the right main pulmonary artery or its surrounding tissue. Lung perfusion scintigraphy demonstrated perfusion defects in the right upper and middle lung fields. The right/left count ratio was 35.4%:64.6%. Right heart catheterization revealed the presence of precapillary PH with mean PAP of 45 mm Hg. The patient was diagnosed with large-vessel vasculitis with isolated pulmonary artery involvement. Takayasu's arteritis was suspected, but histological examination was not performed.

Following steroid therapy, blood analyses showed resolution of inflammatory changes and positron emission tomography-CT demonstrated disappearance of FDG uptake in the mediastinum. However, proximal pulmonary artery stenosis-induced PH remained after medication; therefore, percutaneous pulmonary interventions were considered. Several sessions of pulmonary arterial intervention were stratified for the right main pulmonary artery, as shown in Fig. 2.

The first and second interventions were balloon expansion on days 35 and 51, which resulted in slight reduction of mean PAP to 35 mm Hg. The third and fourth interventions constituted balloon expandable stent placements on days 70 and 98, with stent diameters of 9 and 10 mm, respectively. After treatment, the mean PAP decreased to 22 mm Hg; the patient was subsequently discharged with improvement in symptoms.

Thoracic 4D-flow MRI and blood flow analyses

Thoracic 4D-flow MRI was performed before and 8 days after completion of the serial endovascular interventional sessions using a 3.0 Tesla scanner (MAGNETOM Trio; Siemens Healthcare, Germany). The MRI was performed using the following parameters: 3-dimensional phase-contrast MRI with 3-directional velocity encoding transverse acquisition; ECG gating; respiratory gating; repetition time/echo time, 42.6/2.54 milliseconds; flip angle, 15°; velocity encoding, 70 cm/s, spatial resolution, 2.4 × 1.8 × 3.5 mm³; time resolution, 14 phases/cardiac cycle. The streamlines in systole and diastole periods before interventions are illustrated in Fig. 3.

Blood flow analyses were used to track the centerline of the pulmonary artery. Then planes in the pulmonary arteries were set to evaluate volume flow rate in each plane. The mean volume flow rate during a cardiac cycle was calculated by the normal component of the main flow direction of each plane, the cross-sectional area, and the number of phases of 4D-flow MRI (ie, time resolution, 14 phases/cardiac cycle).

After right pulmonary arterial intervention, volume flow rates increased at the inlet of the right pulmonary artery (before: 23 mL/s vs after: 47.5 mL/s) and the main pulmonary artery (before: 71.2 mL/s vs after: 82.5 mL/s), and decreased at the inlet of the left pulmonary artery (before: 46.2 mL/s vs after: 31.7 mL/s), as shown in Fig. 4. The split ratio of volume flow rate between the right and left pulmonary arteries improved after treatment (before: R:L = 33.1:66.9 vs after: R:L = 60.0:40.0), approaching normal values.

Discussion

We encountered a patient with PH due to isolated pulmonary artery involvement in large-vessel vasculitis, and evaluated the perioperative hemodynamic changes using 4D-flow MRI. Such perioperative assessments have been reported in cardiovascular and cerebrovascular diseases, and have demonstrated the importance of hemodynamic changes in surgical planning or therapeutic effects [1–9]. In patients with

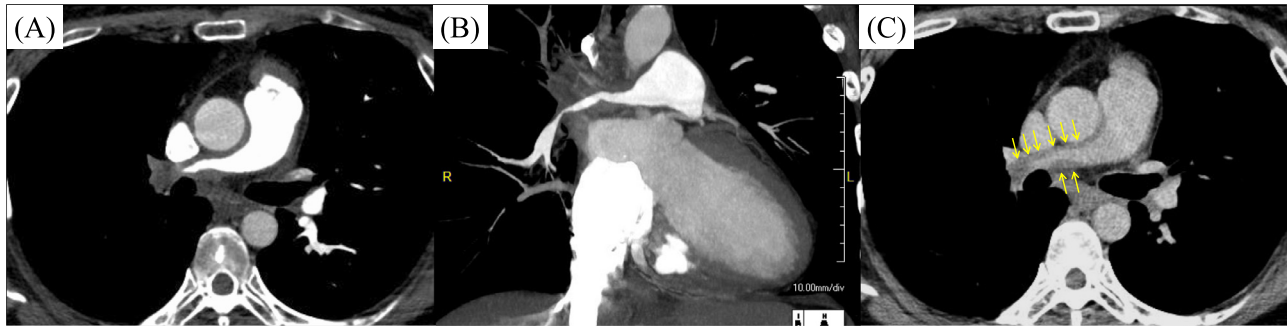

Fig. 1 – Contrast-enhanced CT images. Early phase demonstrates extensive proximal narrowing in the right main pulmonary artery (A and B). Delayed phase shows thickened walls with enhancement (C).

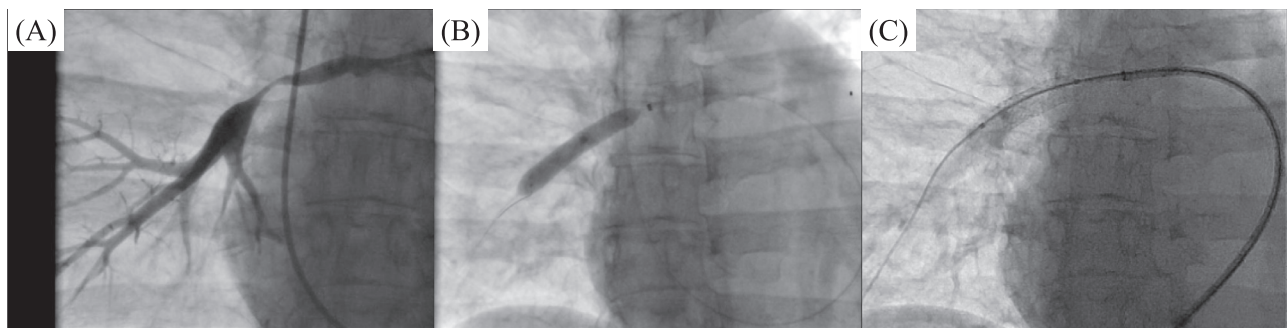


Fig. 2 – Endovascular interventions for the right pulmonary artery. Extensive proximal narrowing was demonstrated before intervention (A). The intervention included balloon angioplasty on day 51 (B) and stent placement on day 98 (C).

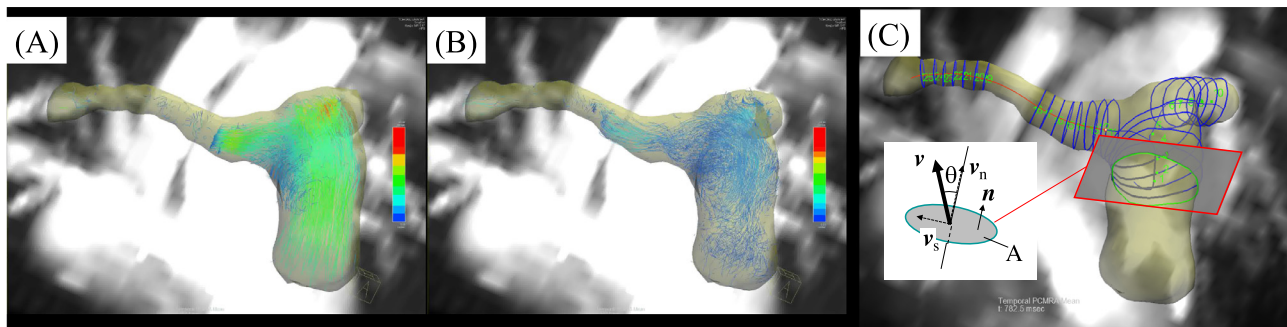


Fig. 3 – Flow streamlines of the pulmonary artery before intervention in the systole (A) and diastole (B) periods. Assessment of the pulmonary arterial blood flow by 4D-flow MRI (C). Planes in the pulmonary arteries were set to evaluate the volume flow rate. The axial direction of the aorta was defined as the normal direction of the plane. Volume flow rate (Q) was calculated as $Q = \sum^{N_p} \int v_n dA / N_p$, where N_p indicates the number of phases of 4D-flow MRI, v is the spatial averaged velocity vector in each plane, n is the normal unit vector of the plane, v_n is a normal component of v (ie, $v_n = v \cdot n$), and A is the cross-sectional area.

PH, Reiter et al demonstrated a relationship between mean PAP and vortical blood flow in the main pulmonary artery [1]. Hosokawa et al investigated the therapeutic effects of balloon pulmonary angioplasty (BPA) on pulmonary artery blood flow in patients with chronic thromboembolic PH [10]. They demonstrated that, in peripheral pulmonary artery stenosis, blood flow increased in the BPA side of the pulmonary artery and decreased in the non-BPA side, but did not significantly

change in the main pulmonary artery. For our patient, we included the right main pulmonary artery in the MRI scan area and calculated the volume flow rate. The results demonstrated an increase in overall pulmonary blood flow, as well as improvement in blood flow balance between the right and left pulmonary arteries. The split ratio of blood flow between the right and left pulmonary arteries is an important parameter, as is the overall pulmonary blood flow; quantitative

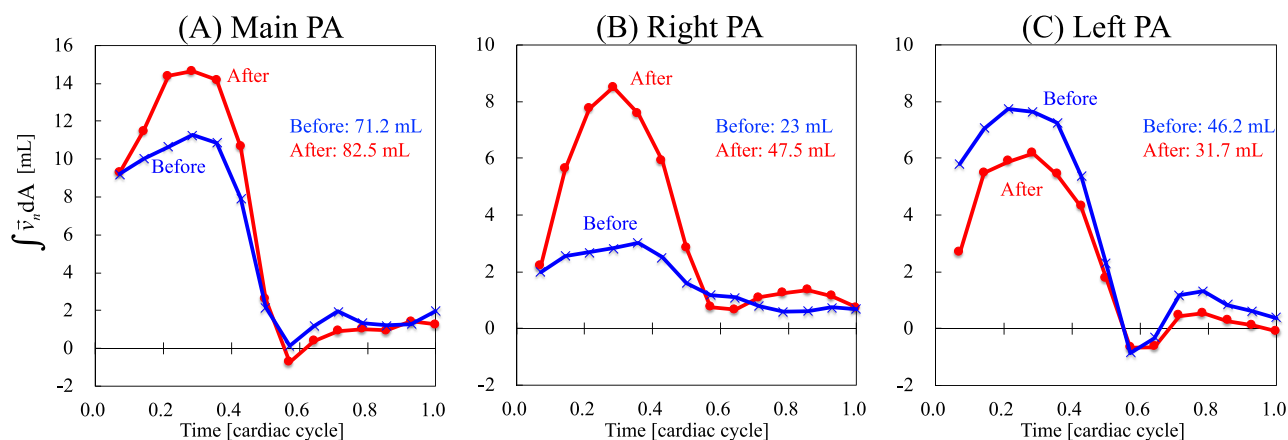


Fig. 4 – Time course of changes in volume flow rate before and after right pulmonary artery intervention. After right pulmonary artery intervention, volume flow rates increased at (A) the main pulmonary artery (before: 71.2 mL/s vs after: 82.5 mL/s) and (B) the inlet of the right pulmonary artery (before: 23 mL/s vs after: 47.5 mL/s), whereas the rate decreased at (C) the inlet of the left pulmonary artery (before: 46.2 mL/s vs after: 31.7 mL/s).

evaluations of these parameters are recommended, because they depend on the localization of pulmonary arterial lesions and/or treatment sites. In this regard, blood flow assessment using 4D-flow MRI is useful for evaluating the therapeutic effect after pulmonary arterial interventions.

Pulmonary artery involvement in Takayasu's arteritis has been reported in approximately 50%-80% of patients [11]. Isolated involvement of the pulmonary artery is rarely reported [12–17]. Patients typically show PH and right heart symptoms, due to pulmonary involvement. However, some patients show nonspecific manifestations, which lead to delayed diagnosis [15]. Surgical and/or endovascular interventional treatments are considered when conservative treatments are not effective [13–17]. As interventional treatment, BPA and stent placement have been reported for isolated pulmonary artery involvement [13,15,17]. Reperfusion respiratory edema is an important complication of BPA, which has been reported in approximately 60% of patients after BPA with acute oxygen desaturation [18,19]. The mechanism is not fully understood, but a preoperative mean PAP above 45 mm Hg is considered an important risk factor [18]. For the patient in this report, we conducted several sessions of pulmonary arterial intervention involving BPAs and stent placements; these gradually reduced the mean PAP from 45 mm Hg to 22 mm Hg. The patient did not demonstrate severe desaturation after intervention, and showed only a small amount of bloody sputum. Therefore, careful planning of serial intervention may be effective for avoiding reperfusion respiratory edema.

Conclusion

We demonstrated perioperative hemodynamic changes quantitatively in a patient with PH using 4D-flow MRI. Stent placement for stenosis in the right pulmonary artery resulted in an increase in overall pulmonary blood flow, as well as improved blood flow balance between the right and left pulmonary arteries.

REFERENCES

- [1] Reiter G, Reiter U, Kovacs G, Olschewski H, Fuchsjäger M. Blood flow vortices along the main pulmonary artery measured with MR imaging for diagnosis of pulmonary hypertension. *Radiology* 2015;275(1):71–9.
- [2] Reiter G, Reiter U, Kovacs G, Adelsmayr G, Greiser A, Stalder AF, et al. Counter-clockwise vortical blood flow in the main pulmonary artery in a patient with patent ductus arteriosus with pulmonary arterial hypertension: a cardiac magnetic resonance imaging case report. *BMC Med Imaging* 2016;16(1):45.
- [3] Takei Y, Itatani K, Miyazaki S, Shibasaki I, Fukuda H. Four-dimensional flow magnetic resonance imaging analysis before and after thoracic endovascular aortic repair of chronic type B aortic dissection. *Interact Cardiovasc Thorac Surg* 2019;28(3):413–20.
- [4] McLennan D, Schäfer M, Mitchell MB, Morgan GJ, Ivy D, Barker AJ, et al. Usefulness of 4D-flow MRI in mapping flow distribution through failing Fontan circulation prior to cardiac intervention. *Pediatr Cardiol* 2019;40(5):1093–6.
- [5] Takigami M, Itatani K, Nakanishi N, Nakaji K, Kajiyama Y, Matoba S, et al. Evaluation using a four-dimensional imaging tool before and after pulmonary valve replacement in a patient with tetralogy of Fallot: a case report. *J Med Case Rep* 2019;13(1):30.
- [6] Kamada H, Ota H, Nakamura M, Imai Y, Ishida S, Sun W, et al. Perioperative hemodynamic changes in the thoracic aorta in patients with aortic valve stenosis: A prospective serial 4D-flow MRI study. *Semin Thorac Cardiovasc Surg* 2019 pii: S1043-0679(19)30194-7. doi:10.1053/j.semctvs.2019.07.006.
- [7] MacDonald ME, Dolati P, Mitha AP, Eesa M, Wong JH, Frayne R. Hemodynamic alterations measured with phase-contrast MRI in a giant cerebral aneurysm treated with a flow-diverting stent. *Radiol Case Rep* 2016;10(2):1109.
- [8] Nakagawa S, Murai Y, Wada T, Tateyama K. 4D flow preliminary investigation of a direct carotid cavernous fistula due to a ruptured intracavernous aneurysm. *BMJ Case Rep* 2015 pii: bcr2014206084. doi:10.1136/bcr-2014-206084.
- [9] Guo B, Pirola S, Guo D, Dong Z, Xu XY, Fu W. Hemodynamic evaluation using four-dimensional flow magnetic resonance imaging for a patient with multichanneled aortic dissection. *J Vasc Surg Cases Innov Tech* 2018;4(1):67–71.

- [10] Hosokawa K, Abe K, Horimoto K, Yamasaki Y, Nagao M, Tsutsui H. Balloon pulmonary angioplasty relieves haemodynamic stress towards untreated-side pulmonary vasculature and improves its resistance in patients with chronic thromboembolic pulmonary hypertension. *EuroIntervention* 2018;13(17):2069–76.
- [11] Nakabayashi K, Kurata N, Nangi N, Miyage H, Nagasawa T. Pulmonary artery involvement as first manifestation in three cases of Takayasu arteritis. *Int J Cardiol* 1996;54S:177–83.
- [12] Hara M, Sobue R, Ohba S, Kitase M, Sasaki S, Ogino H, et al. Diffuse pulmonary lesions in early phase Takayasu arteritis predominantly involving pulmonary artery. *J Comput Assist Tomogr* 1998;22(5):801–3.
- [13] Tyagi S, Mehta V, Kashyap R, Kaul UA. Endovascular stent implantation for severe pulmonary artery stenosis in aortoarteritis (Takayasu's arteritis). *Catheter Cardiovasc Interv* 2004;61(2):281–5.
- [14] Yamazaki I, Ichikawa Y, Ishii M, Hamada T, Kajiwara H. Surgical case of isolated pulmonary Takayasu's arteritis. *Circ J* 2005;69(4):500–2.
- [15] Qin L, Hong-Liang Z, Zhi-Hong L, Chang-Ming X, Xin-Hai N. Percutaneous transluminal angioplasty and stenting for pulmonary stenosis due to Takayasu's arteritis: clinical outcome and four-year follow-up. *Clin Cardiol* 2009;32(11):639–43.
- [16] Fujita K, Nakashima K, Kanai H, Kumakura H, Minami K. A successful surgical repair of pulmonary stenosis caused by isolated pulmonary Takayasu's arteritis. *Heart Vessels* 2013;28(2):264–7.
- [17] Weinstock BS, Haim YD. Pulmonary artery stenting in a patient with Takayasu's arteritis using a novel balloon-expandable covered stent. *SAGE Open Med Case Rep* 2019;7 2050313X19841955. doi:10.1177/2050313X19841955.
- [18] Feinstein JA, Goldhaber SZ, Lock JE, Ferndandes SM, Landzberg MJ. Balloon pulmonary angioplasty for treatment of chronic thromboembolic pulmonary hypertension. *Circulation* 2001;103:10–13.
- [19] Kataoka M, Inami T, Hayashida K, Shimura N, Ishiguro H, Abe T, et al. Percutaneous transluminal pulmonary angioplasty for the treatment of chronic thromboembolic pulmonary hypertension. *Circ Cardiovasc Interv* 2012;5:756–62.