



Gel immersion endoscopy-facilitated endoscopic mucosal resection of a superficial nonampullary duodenal epithelial tumor: a novel approach

Akihiro Miyakawa, MD,¹ Toshio Kuwai, MD, PhD,² Teruaki Miyauchi, MD,¹ Haruhisa Shimura, MD,¹ Kenji Shimura, MD¹

Endoscopic resection of superficial nonampullary duodenal epithelial tumors (SNADETs) is considered highly difficult because of the technical challenges posed by the complex anatomic features of the duodenum.¹⁻³ Underwater endoscopic mucosal resection (UEMR), a water immersion method, results in high resection and low adverse event rates.¹⁻³ However, continuously maintaining water in the lumen is difficult.

A novel gelatinous liquid was developed to secure the visual field during endoscopy (Fig. 1). This gelatinous liquid is composed of xanthan gum, locust bean gum, and glycerin. The viscoelastic properties of the liquid enable continuous filling of the lumen and prevent mixing with fresh blood or feces, resulting in a favorable space for endoscopic visualization and treatment. In addition, the viscosity of the gelatinous liquid slows bleeding and leads to easy hemostasis. Yano et al⁴ reported that using gelatinous liquid during endoscopy resulted in a favorable visual field; they named this method gel immersion endoscopy. Moreover, Miyamoto et al⁵ reported that gel immersion endoscopy was useful in endoscopic ultrasonography observation. Although it is mainly used for the hemostasis of GI bleeding and EUS observation, its use in endoscopic mucosal resection has not been reported previously.

In these cases, we completely resected an SNADET using gelatinous liquid to fill the lumen and secure a favorable visual field. We have named this novel method gel immersion endoscopic resection (GIER).

Superficial 7- and 5-mm elevated lesions in the opposite side of the superior duodenal angle were resected using GIER (Figs. 2A and 3A). Butylscopolamine was administered as an antispasmodic agent. First, we gently immersed the lesions in gelatinous liquid using a syringe to secure a favorable visual field (Figs. 2B and 3B). We injected 90 mL of gelatinous liquid for the former lesion and 60 mL for the latter lesion. Similar to UEMR, endoscopic ultrasonography revealed that the lesions floated in the gelatinous liquid-filled lumen, whereas the muscular layer remained flat (Fig. 4). The lesions were

captured easily using a 10-mm snare under gelatinous liquid immersion, resulting in en bloc resection (Figs. 2C and D, 3C and D). The current was passed using a high-frequency generator (VIO300D; Erbe Elektromedizin, Tübingen, Germany). VIO300D was used with the

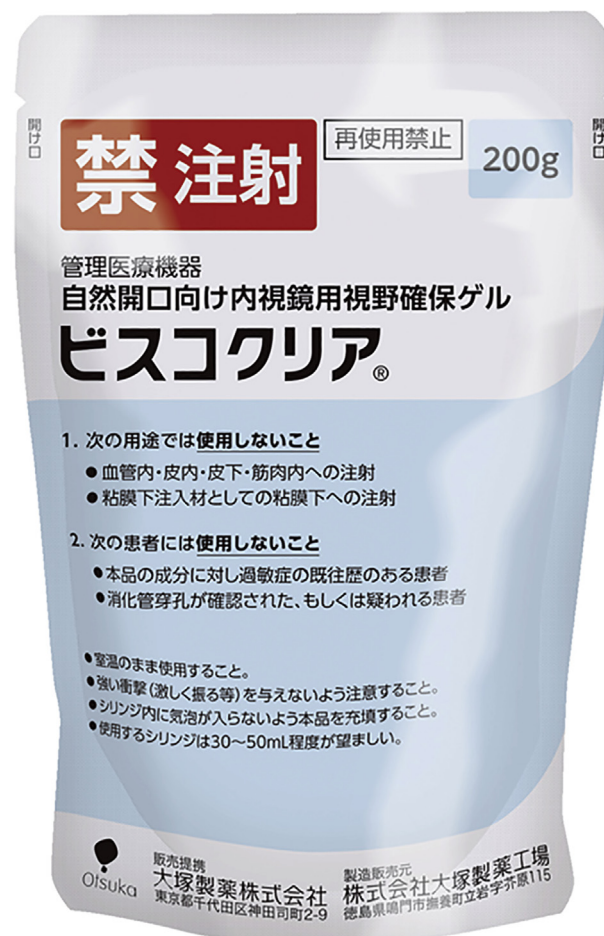


Figure 1. Gelatinous liquid.

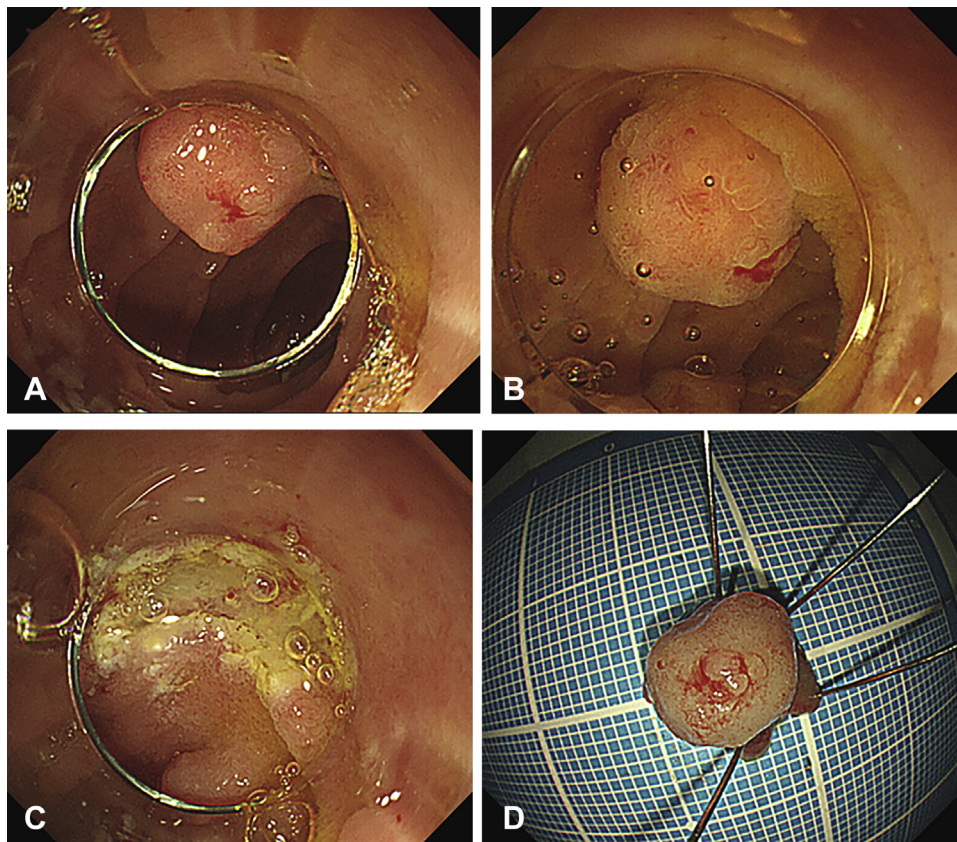


Figure 2. Case 1 (the former lesion). **A**, Superficial 7-mm elevated lesions in the opposite side of the superior duodenal angle. **B**, The lesion was immersed in gelatinous liquid to secure a favorable visual field. **C**, The resection site showed no residual lesion. **D**, The specimen size was 9 mm × 9 mm, and tumor size was 7 mm × 7 mm.

following settings: dry-cut mode (effect 4, 40 W) for mucosal resection. Prophylactic clip closure was performed after resection. The former lesion was pathologically diagnosed as intramucosal cancer with negative margins (Fig. 5A and B), and the latter lesion was diagnosed as adenoma with negative margins (Fig. 6A and B).

Case 2 had a superficial 10-mm elevated and depressed lesion in the second part of the duodenum (Fig. 7A and B). We injected 200 mL of gelatinous liquid (Fig. 7C). The lesion was easy to capture using a 15-mm snare under gelatinous liquid immersion, resulting in en bloc resection (Fig. 7D, E, and F). The specimen size was 26 mm × 16 mm (Fig. 7E and F). The diathermy setting was used and prophylactic clip closure was performed similar to that performed for case 1. The lesion was pathologically diagnosed as adenoma with negative margins (Fig. 8A and B). This case suggested that GIER could resect lesions measuring over 20 mm.

Although we have proposed GIER as a novel replacement method for UEMR, it has a drawback with regard to cost-effectiveness. The gelatinous liquid costs 2000 yen per 200 mL, which is more expensive than water.

In conclusion, gelatinous liquid enables continuous filling of the lumen and secures a favorable visual field. These characteristics result in an easy and safe procedure. Therefore, we highly recommend GIER for high-difficulty lesions such as SNADETs (Video 1, available online at www.VideoGIE.org).

DISCLOSURE

All authors disclosed no financial relationships.

Abbreviations: GIER, gel immersion endoscopic resection; SNADET, superficial nonampullary duodenal epithelial tumor; UEMR, underwater endoscopic mucosal resection.

ACKNOWLEDGMENTS

We thank Dr Yoshio Suzuki (Department of Pathology, Asahi General Hospital, Asahi, Japan) and Dr Monami Dai (Department of Gastroenterology, Asahi General Hospital, Asahi, Japan) for their insightful comments.

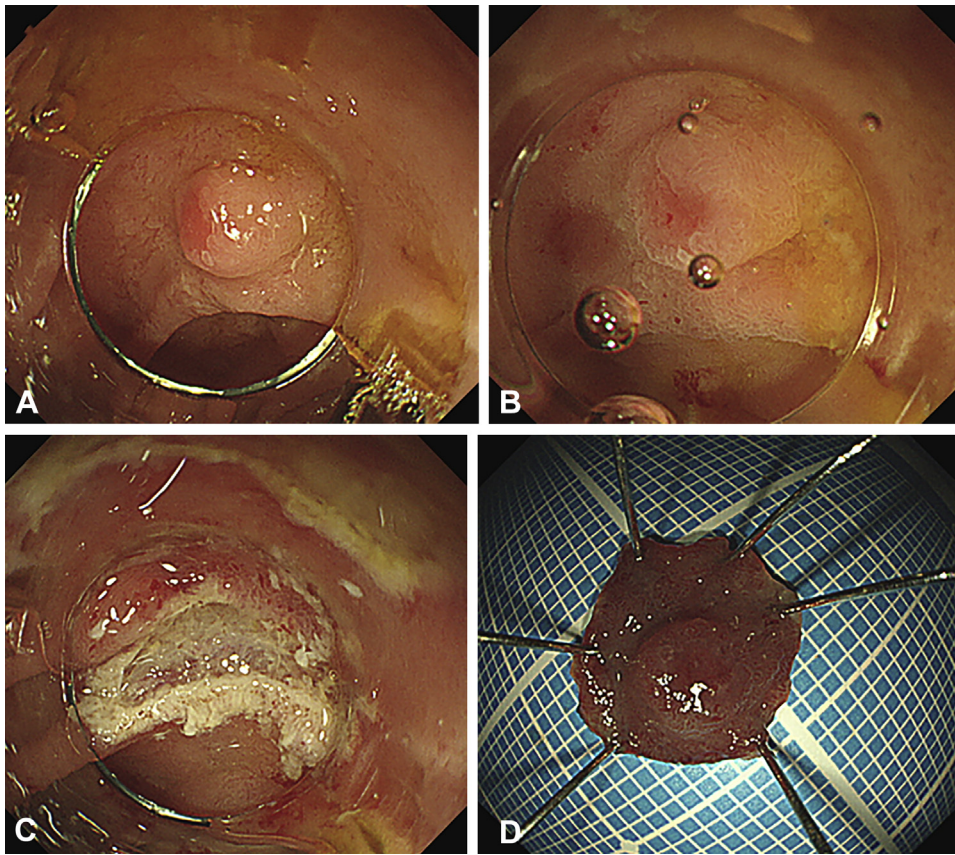


Figure 3. Case 2 (the latter lesion). **A**, Superficial 5-mm elevated lesions in the opposite side of the superior duodenal angle. **B**, The lesion was immersed in gelatinous liquid to secure a favorable visual field. **C**, The resection site showed no residual lesion. **D**, The specimen size was 10 mm × 9 mm, and tumor size was 5 mm × 5 mm.

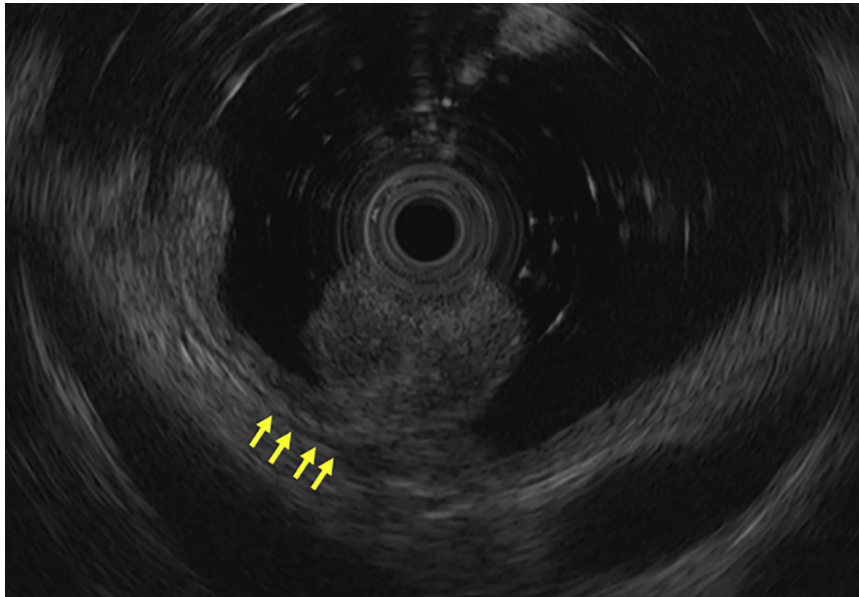


Figure 4. Endoscopic ultrasonography image of the lesions floating in the gelatinous liquid-filled lumen, whereas the muscular layer remained flat (arrows).

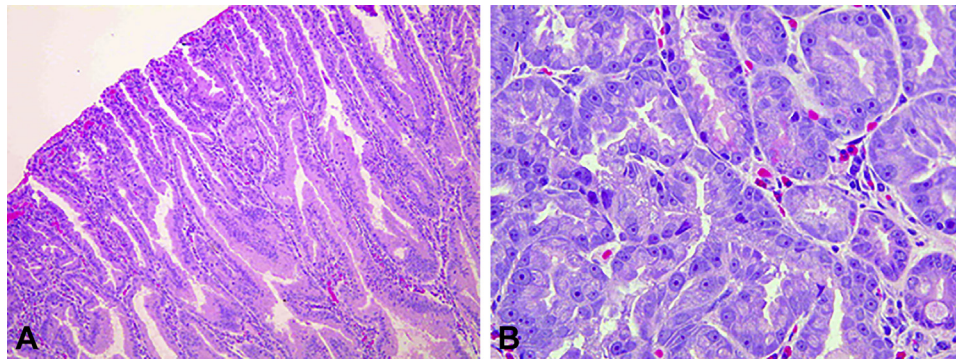


Figure 5. Pathological findings of case 1 (the former lesion). **A**, Pathologically diagnosed intramucosal cancer with negative margins (H&E, orig. mag. $\times 100$). **B**, Pathologically diagnosed intramucosal cancer with negative margins (H&E, orig. mag. $\times 400$).

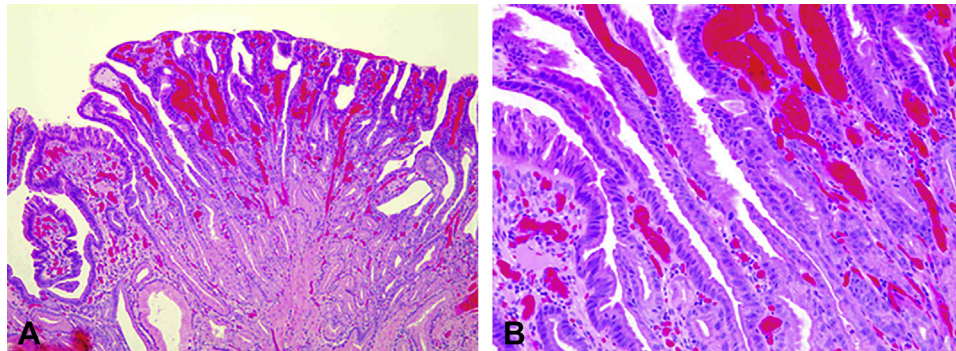


Figure 6. Pathological findings of case 1 (the latter lesion). **A**, Pathologically diagnosed adenoma with negative margins (H&E, orig. mag. $\times 40$). **B**, Pathologically diagnosed adenoma with negative margins (H&E, orig. mag. $\times 100$).

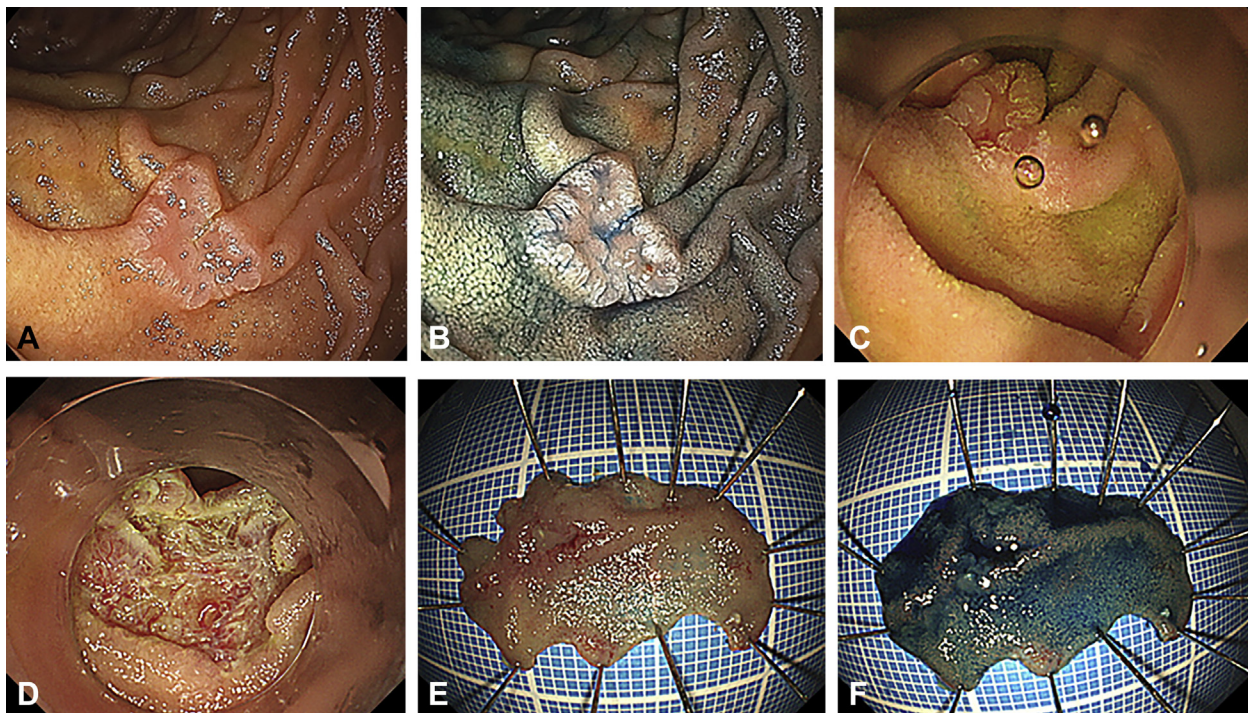


Figure 7. Case 2. **A, B**, Superficial 10-mm elevated and depressed lesion in the second part of the duodenum. **C**, The lesion was immersed in gelatinous liquid to secure a favorable visual field. **D**, The resection site showed no residual lesion. **E, F**, The specimen size was 26 mm \times 16 mm, and tumor size was 10 mm \times 8 mm.

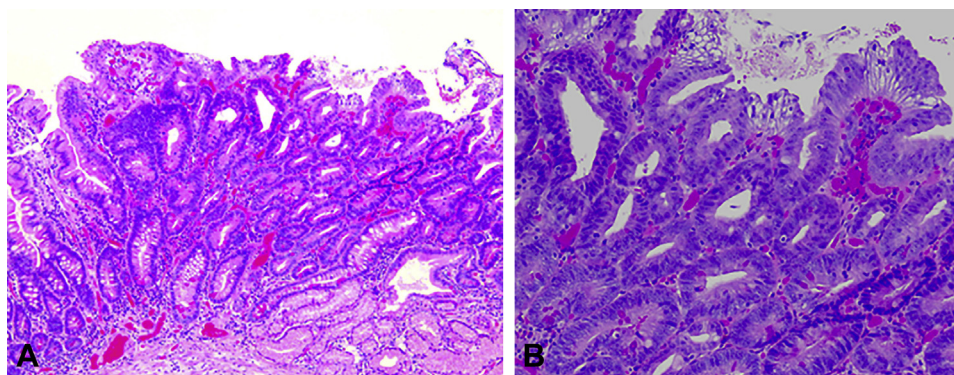


Figure 8. Pathological findings of case 2. **A.** Pathologically diagnosed adenoma with negative margins (H&E, orig. mag. $\times 40$). **B.** Pathologically diagnosed adenoma with negative margins (H&E, orig. mag. $\times 100$).

REFERENCES

1. Binmoeller KF, Shah JN, Bhat YM, et al. "Underwater" EMR of sporadic laterally spreading nonampullary duodenal adenomas (with video). *Gastrointest Endosc* 2013;78:496-502.
2. Yamasaki Y, Uedo N, Takeuchi Y, et al. Underwater endoscopic mucosal resection for superficial nonampullary duodenal adenomas. *Endoscopy* 2018;50:154-8.
3. Iwagami H, Takeuchi Y, Yamasaki Y, et al. Feasibility of underwater endoscopic mucosal resection and management of residues for superficial non-ampullary duodenal epithelial neoplasms. *Dig Endosc* 2020;32:565-73.
4. Yano T, Nemoto D, Ono K, et al. Gel immersion endoscopy: a novel method to secure the visual field during endoscopy in bleeding patients (with videos). *Gastrointest Endosc* 2016;83:809-11.
5. Miyamoto S, Takahashi K, Ohya TR. New method of esophageal endoscopic ultrasonography with injected gel: endoscopic ultrasonography-gel filling method. *Dig Endosc* 2021;33:e49-50.

Department of Gastroenterology, Asahi General Hospital, Asahi, Chiba, Japan (1), Department of Gastroenterology, National Hospital Organization Kure Medical Center and Chugoku Cancer Center, Kure, Hiroshima, Japan (2).

Copyright © 2021 American Society for Gastrointestinal Endoscopy. Published by Elsevier Inc. This is an open access article under the CC BY-NC-ND license (<http://creativecommons.org/licenses/by-nc-nd/4.0/>).

<https://doi.org/10.1016/j.vgie.2021.05.022>

Twitter

Become a follower of *VideoGIE* on Twitter. Learn when new articles are posted and receive up-to-the-minute news as well as links to our latest videos. Search @VideoGIE on Twitter.